

**Avascular necrosis of left femoral head following trivial trauma and the need  
for early Magnetic Resonance Imaging**

**ABSTRACT**

Trivial Trauma is one of the causes of avascular necrosis of the femoral head. Even trivial trauma can cause loss of blood supply to the femoral head and results in ischemia and aseptic necrosis. A 68 year old male patient came with 2 month history of left hip pain. X-ray pelvis (fig-1) with both hips which was taken immediately after the trauma, showed no significant bony abnormality and patient was managed conservatively with analgesics. Patient had persisting pain for 2 months which increased in severity and patient developed difficulty walking. Therefore a Magnetic Resonance Imaging (MRI) L hip (fig-2) was done and which showed avascular necrosis grade III of left femoral head. Total hip replacement was then carried out for the patient and patient improved symptomatically. Earlier MRI imaging following trauma could have resulted in early diagnosis and intervention to prevent progression of the disease and salvage the femoral head.

Keywords: Avascular necrosis, traumatic, total hip replacement, hip pain.

**1. INTRODUCTION**

Avascular necrosis is aseptic death of a segment of the femoral head. Traumatic avascular necrosis occurs due to severance of blood supply to the femoral head due to trauma which results in ischemia and death of bone. Dead bone is structurally and radiographically similar to live bone on plain radiograph, however lacking blood supply it does not undergo renewal after a period of repetitive stress it collapses. If the disease is diagnosed earlier it requires minor surgery such as

core decompression for treatment. If by the time the patient presents the lesion is well advanced, then it requires major surgery like total hip replacement. Core decompression with injection bone marrow aspirate concentrate or platelet rich plasma can be tried in advanced stages but results are not satisfactory and frequently patient will need total hip replacement at later date. The only reliable method of picking up early signs of osteonecrosis is by MRI (Solomon et al., 2014). Written consent was obtained from the patient to publish the clinical and radiological data.

## **2. CASE PRESENTATION**

68-year-old male patient, retired bank employee presented with a 2 month history of hip pain. Patient gives alleged history of minor trauma; patient had missed his footing while crossing a foot bridge and twisted his left hip. Patient is not a known case of diabetes, hypertension, tuberculosis or asthma. Patient initially had mild left hip pain. A plain radiograph of pelvis with both hips (fig-1) showed no significant abnormality and patient was managed conservatively with painkillers. Gradually over the course of two months pain increased in intensity and patient also developed difficulty walking. Patient gives no h/o steroid or alcohol intake. On examination of the left hip, generalized tenderness was present over the left hip and movements were painful and restricted. Differential rotation or sectorial sign was positive in the left hip. MRI L hip (fig-2) which showed avascular necrosis of left femoral head; grade III under modified Ficat and Arlet Radiological (Ficat 1985) staging with necrotic index of more than 50%.

Anaesthetic fitness was obtained and patient was posted for left total hip replacement. Under spinal anesthesia with patient in right lateral decubitus position, and after dissecting skin and sub-cutaneous tissue, a 12cm curved incision was made extending proximally to PSIS and distally to the shaft of femur via the posterior approach. Tensor fascia lata and gluteus maximus

muscle split and retracted. Short external rotators cut and retracted. Capsule was visualized and T-shaped incision was made to open the capsule. Hip joint was dislocated by internal rotation. Neck was osteotomized with the help of a saw. Head removed with the help of a cock screw and was measured to be 49mm. Acetabular labrum was resected. Serial reaming of acetabulum was done (40-52mm). Trial acetabular implant of size 52mm was placed and hold of the trial implant was found to be satisfactory. A 52mm acetabular implant was placed and fixed with 6.5mm x 30 mm screw in the poster superior quadrant. Acetabular liner of size 52mm placed. Serial reaming of femoral medullary canal done with femoral stem size 8 to 12mm. Femoral stem of size 12mm and head of size 28 (+5) was placed. Hip joint relocated by external rotation. Range of motion and stability was checked and found to be satisfactory. Wound was closed in layers over a drainage tube with sterile dressing.

### 3. DISCUSSION

This patient had persisting hip pain for a period of 2 months. Patient had a history of minor trauma 2 months back. Plain radiograph was taken and found to be normal. There can be a delay of 1-5 years between onset of symptoms and appearance of findings in plain radiographs (Stoica et al., 2009). MRI was taken 2 months after the trauma due to persisting pain and difficulty walking and the patient was diagnosed with grade III avascular necrosis and patient was treated surgically with Total Hip Replacement (THR). Post-operatively patient reported relief of pain and mobility was restored.

-An earlier MRI taken in the week or next following the trauma could have resulted in an earlier diagnosis of avascular necrosis. MRI is a sensitive and specific method for early diagnosis of femoral head necrosis (Kalunian et al., 1989). In avascular necrosis of femoral early diagnosis and intervention with head preserving procedures like core decompression is crucial in

preserving the femoral head and obviating or postponing head replacement procedures (Pierce et al., 2015). Head preserving procedures earlier in the course of avascular necrosis can aid in decreasing the morbidity and mortality from the disease. In this patient as the patient gave only a history of trivial trauma and as earlier plain radiograph was normal, MRI was not taken. This resulted in progression of the disease and the need for a replacement surgery. This underscores the need for early magnetic resonance imaging even in cases of trivial trauma if pain persists beyond a week as avascular necrosis might be the etiological factor behind the pain; Avascular necrosis is such a disease that if it is not diagnosed early on plain radiographs and diagnosis later in the course of the disease results in replacement procedures which come with high morbidity and mortality and potential need for revision arthroplasty surgeries if done in young patients (Garino et al., 1997).

#### **4. CONCLUSION**

Avascular necrosis should be suspected in patients with persisting hip pain even post trivial trauma. A normal x-ray cannot diagnose avascular necrosis in early stages and a MRI scan is indicated. In this patient MRI scan revealed a grade III avascular necrosis which necessitated a total hip replacement. An MRI scan earlier following the trauma could have diagnosed avascular necrosis at an earlier stage and an earlier intervention like a core decompression which would have helped preserve the femoral head and reduce the morbidity and mortality for the patient.

#### **REFERENCES**

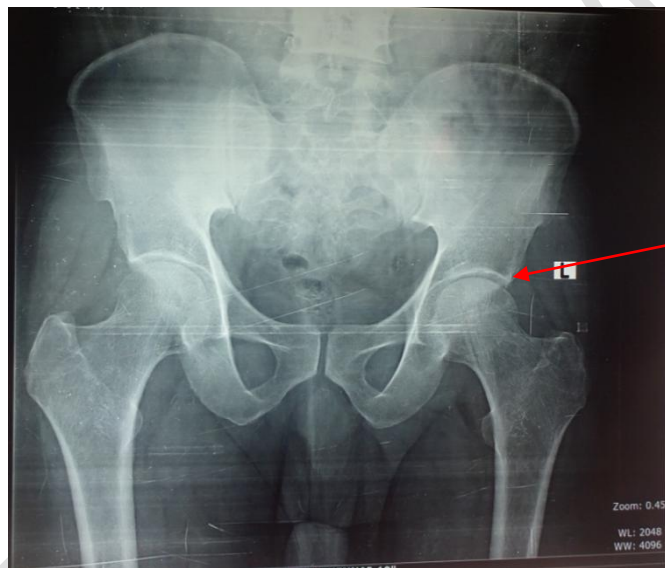
1. Solomon L, Warwick DJ, Nayagam S. Apley and solomon's concise system of orthopaedics and trauma. Crc Press; 2014: 30. 52-54.

2. Ficat RP. Idiopathic bone necrosis of the femoral head. Early diagnosis and treatment. *The Journal of bone and joint surgery. British volume.* 1985; 67:3-9.
3. Stoica Z, Dumitrescu D, Popescu M, Gheonea I, Gabor M, Bogdan N. Imaging of avascular necrosis of femoral head: familiar methods and newer trends. *Current health sciences journal.* 2009; 35:23.
4. Kalunian KC, Hahn BH, Bassett L. Magnetic resonance imaging identifies early femoral head ischemic necrosis in patients receiving systemic glucocorticoid therapy. *The Journal of rheumatology.* 1989; 16:959-63.
5. Pierce TP, Jauregui JJ, Elmallah RK, Lavernia CJ, Mont MA, Nace J. A current review of core decompression in the treatment of osteonecrosis of the femoral head. *Current reviews in musculoskeletal medicine.* 2015; 8:228-32.
6. Garino JP, Steinberg ME. Total hip arthroplasty in patients with avascular necrosis of the femoral head: a 2-to 10-year follow-up. *Clinical orthopaedics and related research.* 1997:108-15.

**Case Illustration:**

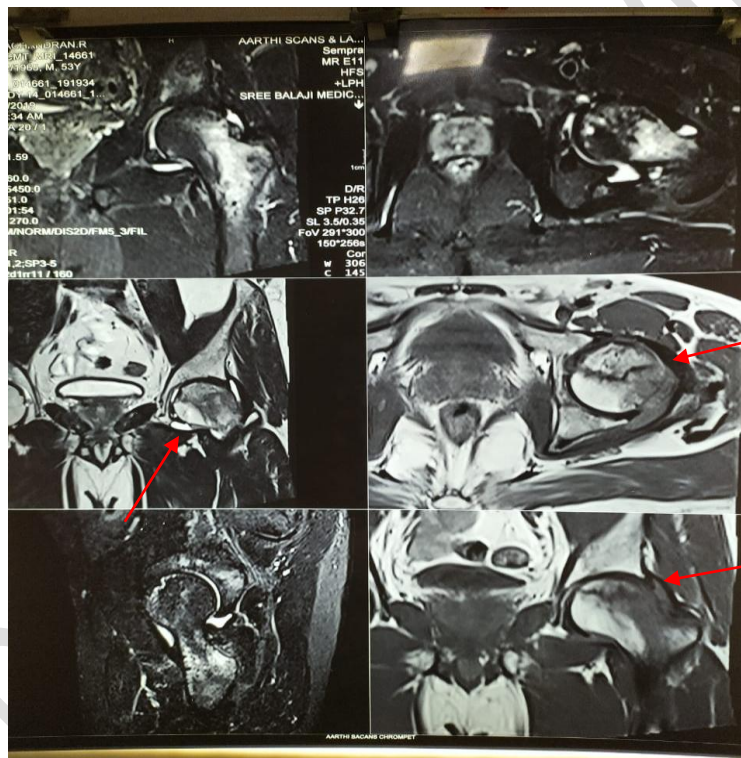
**Fig1-Plain X-ray radiograph of -Pelvis with both hips antero-posterior view:**

**Avascular necrosis of left femoral head represented by increased sclerosis (increased intensity signal) of femoral head over the superior aspect**

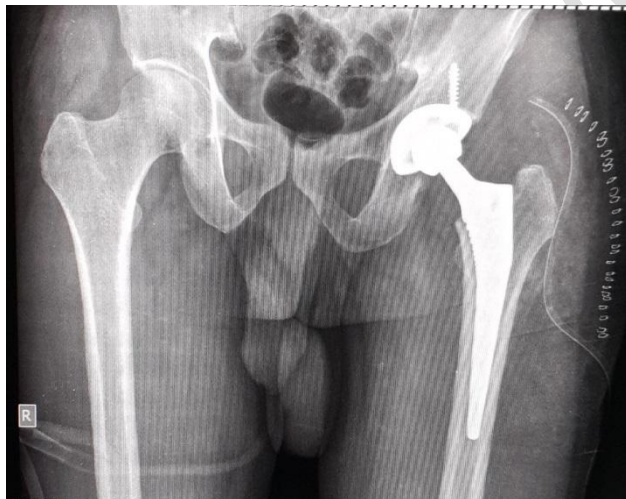


**Fig2-Magnetic Resonance Imaging (axial, coronal & sagittal sections) of Left hip:**

**Avascular necrosis of left femoral head with necrosis of >50% of femoral head represented by geographical areas (decreased intensity signals) on antero-lateral portion of the femoral head as depicted by arrows**



**Fig 3 – Plain X-ray radiograph- Pelvis with both hips Antero-Posterior view taken after surgery showing the Total Hip Replacement implant in situ.**



UNDER PEER REVIEW