

Foreign Body Aspiration In Dentistry

ABSTRACT

BACKGROUND

The foreign body aspiration is very common while performing a dental procedure. Most of the patients are from lower age group as these group of people have high amount of sugar and starch containing diet which is not good for the oral health. But it is not limited to them and several aged patients are also victim of foreign body aspiration.

SUMMARY

Foreign bodies can be anything from cloth dam, barrier techniques itself to broken tooth. Due to age related delayed gag reflex and impact of anesthesia can be possible reasons behind the foreign body aspiration. Pulmonary aspiration is a serious cause of concern and cannot be neglected. It can go unnoticed which can brought to cognizance after careful study and observation of the radiographs. Endoscopic procedures are used to locate and extract the foreign body from the lungs.

CONCLUSION

Proper guidelines regarding the extraction of foreign body extraction and identification must be followed as it is life threatening condition. Vulnerable age group must be treated with extra caution and every chance of mistake must be covered. Standard operating procedure must be strictly adhered to in order not have maximum accuracy.

KEYWORDS: FOREIGN BODY ASPIRATION, DENTISTRY, RADIOGRAPH, ENDOSCOPY, BRONCHOSCOPY, BARRIER TECHNIQUES.

INTRODUCTION

Various types' aspiration can take place in the body while performing a dental procedure. Nasal and oral openings of the human body act as a gateway for external body. Foreign body aspiration while performing a dental surgery is a very common phenomenon and regarded as most acknowledged procedural flaw. Various surgeries need to be performed inside the oral cavity which is covered under the dental medicine. Teeth's are vital organs which chew down the food while mixing saliva which is a digestive enzyme(1). If proper care is not taken of the oral cavity and teeth then many problems can arise such as rotting of teeth, bleeding gums and various other issues.

Sometimes these issues need to be resolved through dental surgery which is an elaborate process of removing dental flaw and improving the function of the organ, meanwhile various sophisticated equipment and instruments are used and allied instruments which are small in size are also used. These components can slip down through trachea to lungs and can wreak havoc inside the lungs. Sometimes the barrier instrument used to block the entry of foreign body can itself get swallowed as the reflexes are numbed down due to application of anesthesia. Various techniques are used to avoid these slippages also known as barrier techniques. The prevalence of foreign body aspiration is huge among children's aged 6 to 15 years of age(2). This age group has a high amount of consumption of sugar and starchy substances which is the reason behind a high rate of rotting of teeth's. The revelation of the foreign body can be critical as sometimes patients' dentist does not know that the foreign body has slipped down to lungs. The detection can happen through chest or lung X-ray or radiograph. In some cases the radiograph of the foreign body is extremely faint and may go unnoticed.

Therefore careful observation and study of the compilation of the radiographs of the other foreign bodies which were aspirated earlier must be studied. Fiber optic bronchoscopy is used to extract the foreign body from the lungs. Although sometimes other methods are also used which give some more leeway such as forceps. Various case studies are also discussed below in detail to show the manifestation of the foreign body among various age groups.

PULMONARY ASPIRATIONS

Aspiration in medical terminology suggests the inhalation or ingestion of certain material which are known as foreign bodies into our body through bodily openings such as nose and mouth especially while performing any medical procedure but not limited to it. Aspiration also means to remove or collect certain material such as liquid or gas from the body, but here it is neglected. Aspirations of joints or arthrocentesis also is a procedure to remove liquid from the joints of the person(3). Suction or vacuum aspiration deals with birth of a child where embryo is pulled out from womb with the help of suction instrument during labor period. Pulmonary aspirations on the other hand refer to inhalation or taking in certain material which does not belong there in lungs through nasopharyngeal openings. Substances such as beverages and eatables, along with various secretions of the body or any other foreign object can enter into lungs through gastrointestinal track or oropharynx, sound box that is larynx, trachea. It can be accidentally

inhaled by the person or it may slipped through the above said path through bronchial tree structure. Sometimes we eat fast or drink too much water in less time giving almost no time to epiglottis to close the path of wind pipe resulting in gag reflex by the body as soon as it touches the epiglottis. Severe coughing may follow till all the food or liquid material is thrown out through two nasal and oral openings. It is extremely important to eat slowly so that epiglottis gets enough time to react and close the respiratory tract. Speaking while eating and drinking can also cause the above stated phenomenon.

The medical outcome post pulmonary aspirations includes no effect at all to difficulty in breathing or changed breathing patter to pneumonia and death if the foreign body causes the path way for the oxygen to choke which leads to asphyxiation, a life threatening condition. All these consequences are depend upon size of the particle, its density, volume, chemical and physical composition, whether carrying any pathogens or not and so on. Upper respiratory tract which constitutes nasal cavity, pharynx and larynx act as a gateway for the foreign body and lower respiratory tract takes it to the lungs. Lower respiratory tract includes trachea or wind pipe, bronchioles, lungs(4).

FOREIGN BODY ASPIRATION IN DENTISTRY

Dental medicine or dentistry is branch of medicine which deals with oral cavity care, prevention and cure of any oral and dental diseases and teeth related and gums related ailments and so on. Development and arrangement of the tee also comes under the ambit of dentistry. Along with this, it is also associated with maxillofacial area which is roughly the area of jaws and mouth of a human being. It is closely linked with stomatology which is why is why both the terms are used in place of one another occasionally. Evidenced based research and empirical data based practice has helped to evolve the life sciences and hence the dentistry or dental medicine. Specialties in the dental medicine includes orthodontics, maxillofacial and oral radiology and pathology, oral implantology and medicine, cosmetic dentistry for aesthetic purposes, anesthesiology and so on(5).

Various procedures are carried out in the field of dental medicine to give relief to the patients having complain about dental ailments. These ailments includes congenital and acquired type of diseases. Anodontia is an oral disease which is congenital disorder of are category in which the permanent teeth are absent along with temporary teeth's in some cases. It is also subdivided into amount of teeth present in the patient. In case of acquired diseases which includes dental caries and dental abscess are the diseases or the dental ailments which are acquired over the due course of time mainly due to bad oral hygiene and unhealthy eating pattern. Dental caries mainly consists of decay of tooth enamel due to bacteria that released acid upon consuming the foods containing starch and sugar. The gaps in the teeth's are filled with tiny particle of food which then gets rotted.

Therefore it is important to floss and rinse the mouth post lunch and dinner. It is a chronic disease and last long, generally over a decade. It is prevalent among children and young adults among which consumption of sugar and confectionary items have found to be high. Dental abscess as the name suggests is an event of pus formation due to bacterial action and it is foiled by throbbing pain in the abscess(6). Poor dental hygiene and consuming high starch and high sugar content food can lead to such situation. Various procedures regarding dental medicine has been done since ages due to either preventive measure or as a curative measure post dental illness. These includes, teeth cleaning and whitening, extractions, veneer, fillings, crown adjustments, dental fillings, root canal, brace implant, bonding of teeth's and dentures are some of the common procedures. These procedures are done by train and expert dentist and auxiliary staffs under competent supervision. One must acquire a license to start practicing the profession of dentist and auxiliary dentist. Many instruments and sophisticated medical equipment's are necessary to carry out such procedures to ensure maximum efficiency and error free work. But sometimes due to various reasons, any component of the procedural equipment may get inhaled or ingested by the patient resulting it ending into the lungs which can also be life threatening. This is commonly known as aspirations of foreign body into lungs. This can happen a lot as patient concern are mostly opt for procedures to get rid of excruciating pain which is given by dental illness such as root canal, dental caries and so on.

These procedure requires anesthesia as teeth's or tissue removal is involved. Therefore patient have almost no feeling around maxilla facial are if the anesthesia is applied locally or no sensation in the whole body if general anesthesia is administered. The choice of anesthesia depends on procedure. More complex the procedure, higher is the dose of anesthesia. This render patient helpless and chance of inhaling or ingesting foreign object without knowing it is high. Especially in the older age group where sensory and motor nerve are already lacking the appropriate response and anesthesia makes it worse. Improper following of standard operating procedure, lack of attention during procedure and negligence are some of the reasons of aspirations in the dental surgery patients. It may or may not be noticed immediately and it can persist as unknown mistake for very long time resulting in wrong diagnosis and other complications. Patients also may or may not know about their situation and its severity(7).

Many complications can arise during or after the various above stated dental procedures. Because these procedures are carried out inside the oral cavity from where various parts of instruments or equipment's which are being used while operating can slip inside the patients. The anesthetics patients may or may not notice and health care professionals may also neglect it under various circumstances. Various drugs while doing procedures are administered to the concerned so that it can aid the procedure. Although these drugs can sometimes have adverse reaction among some patients. Contraindications are extremely necessary to follow to ensure safety of the patient. Slippage or breaking of an object which is generally followed by swallowing of an object which is also known as aspiration of the foreign object. The position of the patient while operating is also important as in most of the cases the position of the patients has aided the aspiration process which then complicate the things further. The objects which are

widely considered as most found objects in aspirations are restorative material, teeth taken out, damp cloth, surgical instruments, material used for impression and so on(8).

The reasons are wide ranging behind the possibility of the aspirations among dental patients while performing any kind of surgeries. Mostly these are observed among patients who are elderly who needs regular dental clinic visits. Also the reaction to entry of unwanted foreign body also known as gag reflex might become slow and dull in case of old aged population. The delay in responses is natural as one ages and these needs to be taken into account while operating on patients. Also the anesthesia which is applied generally or locally depending upon the procedure being carried out. Some dental procedures are complicated and required multidisciplinary expertise and hence the anesthesia is chosen accordingly by the anesthesiologist. But simple procedures like root canal or removing rotten tooth can be done by using local anesthesia. This anesthesia numbs the applied area so that patient does not feel the excruciating pain. This can facilitate the slippage of objects or aspiration. Some of the preexisting medical conditions or phenomenon which is prevalent among old aged patients are dementia, Parkinson's diseases which can also influence the aspiration of foreign body(9).

This is an anticipated phenomenon and dentist and allied health care professionals take utmost care not to leave scope for any mistake. Various types of stopping techniques for foreign bodies which prohibits it from entering into the body has been categorized under barrier techniques which are an essential part of standard operating procedure of the dental outpatient department. The most widely used process of prohibiting the foreign object from entering into the body is rubber dam. Its efficacy regarding stoppage of foreign body has been tested and it has proven its efficacy in various dental procedures. It is very effective against the impression material, implants or broken tooth to enter in to the respiratory pathway but sometimes the danger of swallowing the rubber dam looms around the procedure. To safeguard the rubber dam usage of dental floss is suggested do that the chance of getting the rubber dam aspirated is decreased significantly(10). But usage of rubber dam as a barrier technique is precluded in many dental surgeries.

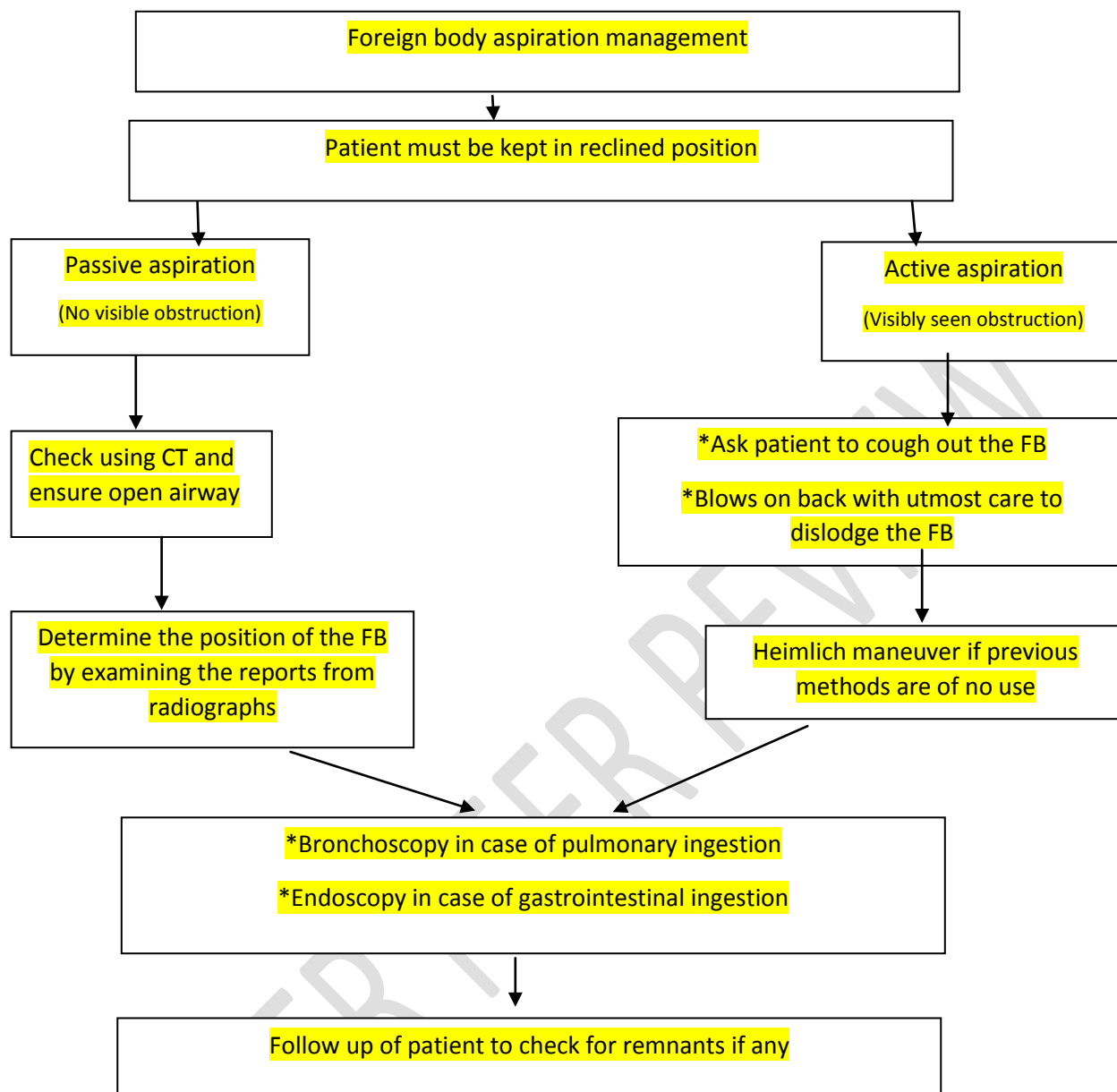
Therefore another barrier technique has been evolved in which a 4 by 4 inch gauze protective barrier is installed in the oral cavity which also act as anti-aspiration methods. A standard operating procedure suggests that dentist and allied health care professionals working in the dental clinic must told the patient beforehand some important points which includes curbing he sensation of swallowing if anything falls on the tongue while operating. Human being has natural tendency to swallow the objects which falls in to mouth and on tongue. This can safeguard the person from being victim of accidental aspiration. Certain procedures such as full arch impression in dentistry does not allow the barrier technique to work. In such cases the equipment's or the substances accompanied by the dentist to treat the patient can be small and easily swallowed by the patient unknowingly. If the procedure is being carried in the posterior region of the oral cavity then the chance of happening the aspiration increases manifold. Two

case studies regarding how aspiration manifests itself over the course of time. In patient one who was 85 years old man was being operated for amalgam replacement when the amalgam got aspirated in to its lungs(11).

Thankfully it was noticed immediately and the procedure of removing the foreign object from the lungs which is also known as bronchoscopy was performed on the 85 years old man. This involved various risks which includes not noticing that the amalgam being aspirated by the subject and second the vulnerability of the patient regarding surgeries like bronchoscopy especially among senior and old aged patients. In second such instance of aspiration, a 45 year old army veteran came with complain of asthmatic conditions and it persisted for more than 3 years prior to the reporting of the instances. The said patient was taking all the medications relating to the asthma. After careful analysis of the available facts and corroborating the medical examinations report, it was observed that the condition which was considered as asthma was actually relating to the aspiration of the foreign body while a dental surgery which was just before the complain of asthma like symptoms started 3 years back. The second case study is a cause of concern as the aspiration was completely unknown for more than 3 years which is another cause of concern. That much stay of a foreign body inside of the human body can be extremely dangerous and can create various medical complications which can be difficult to manage. Also radiograph of the chest and lungs have been found to have extremely minute impression of the foreign body on the radiograph which was difficult to identify and spot. Further the nuisance making power of the foreign body especially inside the sensitive organs like lungs can wreak havoc and chance of patient falling to severe medical condition cannot be neglected.

The density of the foreign object can have impact on its visibility in radio graph. Various foreign body materials have various impressions in the radio graph which includes carbon, aluminum, silicone. It is cross examined with other elements present in the lungs such as oxygen and then it is compared. Some minor brightness of extremely small diameter can be identified as foreign body if checked with keen eye. The anticipation of the ingestion or the aspiration of the foreign body objects has been considered and given due weightage while performing any orthodontic procedures(12).

Various technologies are used to extract the foreign body from the patient's lungs. These includes fiber optic bronchoscopy which is widely regarded as one of the best practices among others. Although removal of foreign body has long history and it dates back to 18th century where one of the first foreign body removal procedure was carried out by Louis in 1759(13). The modern technology of the endoscopy was evolved around late 19th century and early 20th century and first documented event was occurred in 1897. The latest technology being the fiber optic bronchoscopy has a considerable amount of success rate ranging from 60 percent to 90 percent. Although decision of the usage of technology on the patients having foreign body inside its air pathway and lungs is taken according to the position of the foreign body.



Management of patient in case of foreign body aspiration

If the FB is located in the upper parts of the lungs then the procedure is easy while more complex procedure has to be followed if the FB is wedged inside bronchioles or in deep lungs. Fiber optic bronchoscopy has gained traction in recent times for removing FB but it has its limitations. Fiber optic bronchoscopy provides less grasp on the FB as compared to rigid bronchoscopy forceps in which it gives more leeway to the dental surgeon to perform the procedure more precisely and accurately(14).

CONCLUSION

Foreign body aspiration is a widely prevalent procedural flaw which is very much anticipated. Aspiration of foreign body inside the lungs can be extremely dangerous as the result of the same can vary a lot. Also in some dental procedures the barrier techniques don't work and therefore becomes extremely critical. Aspirations and the size and nature of the aspirated foreign body can also vary. Standard operating procedure must provide strict direction for doing the dental procedure as the damage done by the foreign body can be tremendous and life threatening. Choice of procedure of removing foreign body from the lungs can be game changer as some of the procedure have its own advantages although they are vintage procedures. The age of the patient also matters as the elderly patients need more caution and attention as their reflexes as mellowed down due to ageing effects. Application of anesthesia is inevitable as these procedures involves incisions which can induce pain. But it numbs the patients and gag reflexes won't work properly post application of the same. More study is needed to evolve more accurate methodologies to prevent the aspirations as well to remove it from the lungs.

COMPETING INTERESTS DISCLAIMER:

Authors have declared that no competing interests exist. The products used for this research are commonly and predominantly use products in our area of research and country. There is absolutely no conflict of interest between the authors and producers of the products because we do not intend to use these products as an avenue for any litigation but for the advancement of knowledge. Also, the research was not funded by the producing company rather it was funded by personal efforts of the authors.

REFERENCES

1. Hashimoto K, Uchimura K, Hara S, Manabe T, Morimoto T, Nakamura K, et al. [A Case of a Bronchial Foreign Body (Artificial Tooth) in the Right Middle Bronchus Without Respiratory Symptoms]. J UOEH. 2020;42(4):347–52.

2. Yadav RK, Yadav HK, Chandra A, Yadav S, Verma P, Shakya VK. Accidental aspiration/ingestion of foreign bodies in dentistry: A clinical and legal perspective. *Natl J Maxillofac Surg* [Internet]. 2015 [cited 2021 Oct 14];6(2):144–51. Available from: <https://www.ncbi.nlm.nih.gov/pmc/articles/PMC4922223/>
3. Yadav RK, Yadav HK, Chandra A, Yadav S, Verma P, Shakya VK. Accidental aspiration/ingestion of foreign bodies in dentistry: A clinical and legal perspective. *Natl J Maxillofac Surg*. 2015 Dec;6(2):144–51.
4. Dionysopoulos D. Accidental ingestion and aspiration of foreign objects during dental practice. *Stomatological Disease and Science* [Internet]. 2017 Sep 29 [cited 2021 Oct 14];1:87–9. Available from: <https://sdsjournal.com/article/view/1717>
5. Handa A, Handa JK. Accidental Ingestion of a Foreign Body of Orthodontic Origin - A Review of Risks, Complications and Clinical Recommendations. *Int J Orthod Milwaukee*. 2016;27(1):41–4.
6. Prasad. Accidental ingestion of foreign body in dental practice and its management [Internet]. [cited 2021 Oct 14]. Available from: <https://ijpedor.org/article.asp?issn=2468-8932;year=2018;volume=3;issue=1;spage=5;epage=7;aulast=Prasad>
7. Venkataraghavan K, Anantharaj A, Praveen P, Rani SP, Krishnan BM. Accidental ingestion of foreign object: Systematic review, recommendations and report of a case. *The Saudi Dental Journal* [Internet]. 2011 Oct 1 [cited 2021 Oct 15];23(4):177–81. Available from: <https://www.sciencedirect.com/science/article/pii/S1013905210000957>
8. Bodini A, Pecoraro L, Catalano F, Aricò MO, Tenero L, Piazza M, et al. Can inhaled foreign body mimic asthma in an adolescent? *Pan Afr Med J*. 2020;36:38.
9. Definition of aspirate - NCI Dictionary of Cancer Terms - National Cancer Institute [Internet]. 2011 [cited 2021 Oct 14]. Available from: <https://www.cancer.gov/publications/dictionaries/cancer-terms/def/aspirate>
10. Hong Q. [Foreign body aspiration and ingestion during oral disease treatment]. *Hua Xi Kou Qiang Yi Xue Za Zhi*. 2016 Aug 1;34(4):329–31.
11. Cameron SM, Whitlock WL, Tabor MS. FOREIGN BODY ASPIRATION IN DENTISTRY: A REVIEW. *The Journal of the American Dental Association* [Internet]. 1996 Aug 1 [cited 2021 Oct 14];127(8):1224–9. Available from: <https://www.sciencedirect.com/science/article/pii/S0002817715610029>
12. Mann R, Srinivasan B, Baker A. Managing aspiration. *Br Dent J* [Internet]. 2012 May [cited 2021 Oct 14];212(10):464–5. Available from: <https://www.nature.com/articles/sj.bdj.2012.425>
13. Blanco Ramos M, Botana-Rial M, García-Fontán E, Fernández-Villar A, Gallas Torreira M. Update in the extraction of airway foreign bodies in adults. *J Thorac Dis*. 2016 Nov;8(11):3452–6.

14. Vranić DN, Jurković J, Jeličić J, Balenović A, Stipančić G, Čuković-Bagić I. Medical Emergencies in Pediatric Dentistry. *Acta Stomatol Croat.* 2016 Mar;50(1):72–80.

UNDER PEER REVIEW