

## Review Article

# Overview on the causes and Updated Management of Impetigo

### Abstract :

Impetigo is the most common bacterial skin infection in children two to five years of age. There are two principal types: nonbullous (70% of cases) and bullous (30% of cases). Nonbullous impetigo, or impetigo contagiosa, is caused by *Staphylococcus aureus* or *Streptococcus pyogenes*, and is characterized by honey-colored crusts on the face and extremities. Impetigo primarily affects the skin or secondarily infects insect bites, eczema, or herpetic lesions. Bullous impetigo, which is caused exclusively by *S. aureus*, results in large, flaccid bullae and is more likely to affect intertriginous areas. Both types usually resolve within two to three weeks without scarring, and complications are rare, with the most serious being poststreptococcal glomerulonephritis. Treatment includes topical antibiotics such as mupirocin, retapamulin, and fusidic acid. Oral antibiotic therapy can be used for impetigo with large bullae or when topical therapy is impractical. Amoxicillin/clavulanate, dicloxacillin, cephalexin, clindamycin, doxycycline, minocycline, trimethoprim/sulfamethoxazole, and macrolides are options, but penicillin is not.

**Key words:** Impetigo, skin, skin infection in children, management of impetigo.

### Introduction:

Impetigo is a common infection of the superficial layers of the epidermis that is highly contagious and most commonly caused by gram-positive bacteria. Normal skin is colonized by large numbers of bacteria that live as commensals in its surface or in hair follicles. (1) Sometimes, the overgrowth of these bacteria causes skin diseases, and in other occasions, bacteria that are normally found on the skin can colonize it and cause diseases. Skin microflora consists mainly of aerobic diphtheroids (*Corynebacterium* spp.), anaerobic diphtheroids (*Propionibacterium acnes*) and coagulase negative

staphylococci (*Staphylococcus epidermidis*). Recent genetic studies have shown a large quantity of *Pseudomonas* spp. and *Janthinobacterium* spp. in diseasefree skin. (2) These bacteria form biofilms on the cutaneous surface. Biofilms are complex and sessile aggregates comprising one or more bacterial species associated with an extracellular polymeric substance. Bacteria in biofilms are 50 to 500 times more resistant to antibiotics than bacteria in plankton (organisms that have little or no ability to move). Besides inducing antibiotic tolerance, biofilms can increase bacterial virulence. Newborns are usually aseptic and colonization starts in the first two weeks of life. (3)

The act of handwashing, with antiseptic soap or even regular soap, especially amongst children caretakers, severely decreased their chance of acquiring infections such as pneumonia, diarrhea and impetigo. In a controlled study, the authors observed a 34% lower incidence of impetigo in the group that underwent an orientation program on the act of handwashing. (4)

Bullous impetigo is caused almost exclusively by *S aureus*. Sometimes a deep ulcerated infection may occur known as ecthyma, which is a complication of bullous impetigo.

### **Study objectives:**

This review aimed to determine the causes and Updated Management of Impetigo.

### **Materials and Methods:**

**Study Design:** Review article.

**Study duration:** Data collected during the period from 1– 29 September, 2021.

**Data collection:** PubMed and EBSCO Information Services was chosen as the search databases for the publications used within the study, as they are high-quality sources. PubMed being one of the largest digital libraries on the internet developed by the National Center for Biotechnology Information (NCBI) which is a part of the United States National Library of Medicine. Topics concerning the causes and Updated Management of Impetigo, published in English around the world. The keyword search headings included “Impetigo, causes, Updated Management of impetigo”, and a combination of these was used. References list of each included study will be searched

for further supportive data. Double revision of each member's outcomes was applied to ensure the validity. During articles selection, studies were doubled-reviewed, and their results were used to assure that we enrolled the studies related to the objective of our study, and to avoid or minimize errors in the results. No software was utilized to analyze the data.

## **Epidemiology**

There are two main types of impetigo, known as non-bullous and bullous impetigo. Nonbullous impetigo is most commonly caused by *S. aureus* which is responsible for 80% of cases. Group A beta-hemolytic Strep (**GABHS**) accounts for 10% of cases and the causative agent is a combination of *S. aureus* and **GABHS** 10% of the time. Methicillin-resistant *S. aureus* (**MRSA**) has become more prevalent, especially in hospitalized patients. Today, community-acquired **MRSA** is rapidly increasing. The condition is more common in populations living in close quarters, daycare centers and prisons. (6)

## **Etiology:**

Impetigo is primarily caused by *Staphylococcus aureus*, and sometimes by *Streptococcus pyogenes*. Both bullous and nonbullous are primarily caused by *S. aureus*, with *Streptococcus* also commonly being involved in the nonbullous form. When considering all age ranges, the incidence is the same in males and females. In adults, men are more commonly affected. It is most prevalent in children aged 2-5 years old but can occur at any age. The peak incidence is during summer and fall. Bullous impetigo is more common in infants. Children younger than two account for 90% of cases of bullous impetigo. (7) Host factors, such as integrity of the skin barrier with its acidic pH, presence of sebaceous secretion (fatty acids, particularly oleic acid), lysozyme and production of defensins and adequate nutritional status, play an important role in resistance to infection. The presence of maceration, humidity, previous skin lesions, obesity, corticosteroid or chemotherapy treatments, dysglobulinemias, leukocyte disorders such as leukemia and chronic granulomatous disease, diabetes, malnutrition, other congenital or acquired

immunodeficiencies, such as **AIDS**, are predisposing factors. Most bacteria grow best in a neutral pH and a temperature of 37°C. (8)

### **Clinical presentation:**

There are two presentations of impetigo: nonbullous (also known as impetigo contagiosa) and bullous.

**Nonbullous impetigo:** is the most common presentation, it can be further classified as primary or the more prevalent secondary (common) form. Primary impetigo is a direct bacterial invasion of intact healthy skin. Secondary (common) impetigo is a bacterial infection of disrupted skin caused by trauma, eczema, insect bites, scabies, or herpetic outbreaks and other diseases. (9) Diabetes or other underlying systemic conditions also increase susceptibility. Impetigo starts as maculopapular lesions that transition into thin-walled vesicles that rapidly rupture, leaving superficial, sometimes pruritic or painful erosions covered by the classic honey-colored crusts. The course of infection can last two to three weeks if untreated. (10) Once the crust dries, the remaining area heals without scarring. The exposed skin of the face (e.g., nares, perioral region) and the extremities are the most commonly affected sites. Regional lymphadenitis may occur, but systemic symptoms are unlikely. Nonbullous impetigo is usually caused by *S. aureus*, but *S. pyogenes* can also be involved, especially in warmer, more humid climates.

**Bullous impetigo:** is caused only by *S. aureus* and is characterized by large, fragile, flaccid bullae that can rupture and ooze yellow fluid. It usually resolves within two to three weeks without scarring. The pathognomonic collarette of scales on its periphery develops after the bullae rupture, leaving a thin, brown crust on the remaining erosions. These larger bullae form because of exfoliative toxins produced by *S. aureus* strains that cause loss of cell adhesion in the superficial epidermis. Bullous impetigo is typically found on the trunk, axilla, and extremities, and in intertriginous (diaper) areas. It is the most common cause of ulcerative rash on the buttocks of infants. Systemic symptoms are uncommon but can include fever, diarrhea, and weakness. (11)

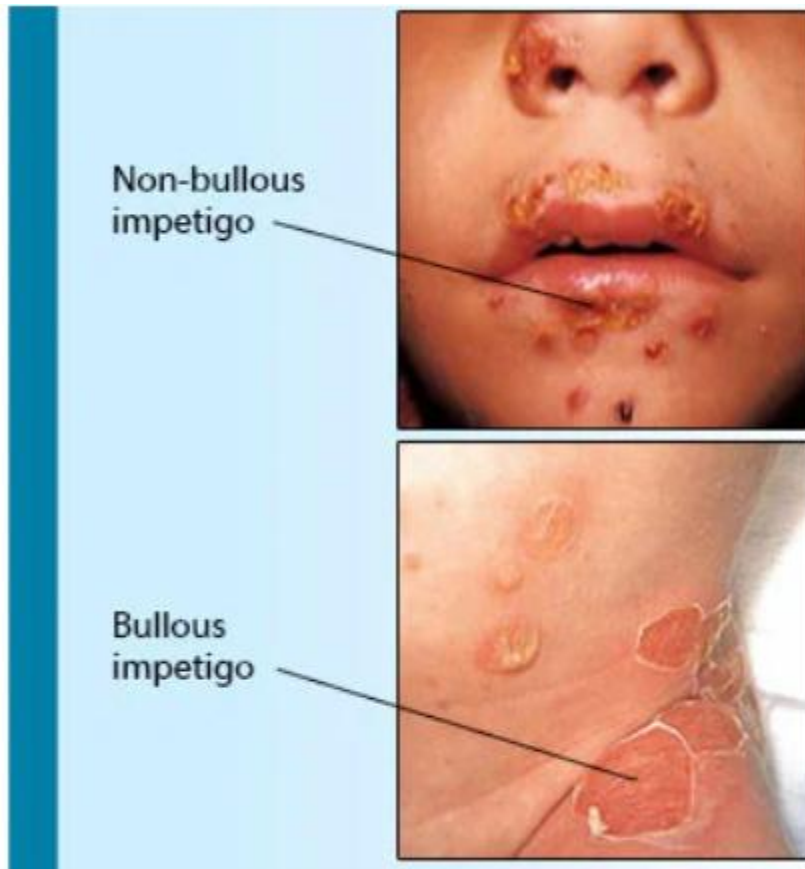
## **impetigo and its relationship to COVID-19:**

Prolonged mask use causes exacerbation of not only pre-existing facial dermatoses (acne, rosacea or perioral dermatitis) but also increases the incidence of acne mechanica, occupational dermatitis (both irritant contact dermatitis and allergic contact dermatitis) caused by the mask material and prolonged contact with straps. Increased warmth and dampness of the face skin due to expired air and sweating caused occlusive effect hampering the skin hydration and irritating pilosebaceous glands ducts with changes in skin microflora.(12), (13) A lengthy daily non-changed mask wearing leads to *S. aureus* activation and causes an infection, for instance, impetigo.(14)

Mask-related lesions involve chin, cheeks and nasal bridge. These areas could be potentially a focus for preventative measures.(15) To avoid mask-associated facial dermatoses, dermatologists counsel patients with the help of mass media and individually regarding the proper skin hygiene: to avoid over cleansing, to use mild cleansers close to skin's natural pH (pH 5) and to add non-comedogenic moisturizing creams.(12)

### **Diagnosis:**

The diagnosis of nonbullous and bullous impetigo is nearly always clinical. Differential diagnosis includes many other blistering and rash disorders. Skin swabs cannot differentiate between bacterial infection and colonization. (16) In patients in whom first-line therapy fails, culture of the pus or bullous fluid, not the intact skin, may be helpful for pathogen identification and antimicrobial susceptibilities. Although serologic testing for streptococcal antibodies is helpful in the diagnosis of acute poststreptococcal glomerulonephritis, it does not aid in the diagnosis of impetigo. (17)



There are two types of impetigo include nonbullous (left) and bullous impetigo

### Management:

In patients with impetigo, lesions should be kept clean, washed with soap and warm water and secretions and crusts should be removed. (18) Topical antibiotics are the treatment of choice for most cases of impetigo. There is strong evidence on the superiority, or at least the equivalence, of topical antibiotics compared to oral antibiotics in the treatment of localized impetigo. (19) In addition, oral antibiotics have more side effects than topical antibiotics. For localized, uncomplicated, non-bullous impetigo, topical therapy alone is the treatment of choice. The crust should be removed with soap and water before the application of topical antibiotic therapy. Mupirocin and fusidic acid are the first choice options. (20) Fusidic acid is highly effective against *S. aureus*, with good penetration into cutaneous surface and high concentration at the site of infection. It is also effective against *Streptococcus* and *Propionibacterium acnes*. Gram-negative bacilli are resistant to fusidic acid. (21) Resistance, in vitro and in vivo, to fusidic acid

has been verified but at low levels. As it belongs to the fusidanes group, it has a very different chemical structure from that of other classes of antibiotics, such as betalactams, aminoglycosides and macrolides, thereby reducing the possibility of cross-resistance. The incidence of allergic reactions is low and cross-allergy has not been seen. This antibiotic is not marketed in the United States. (22) Unlike in Europe, in Brazil it can only be found as 2% cream, being thus unavailable for oral use. (23)

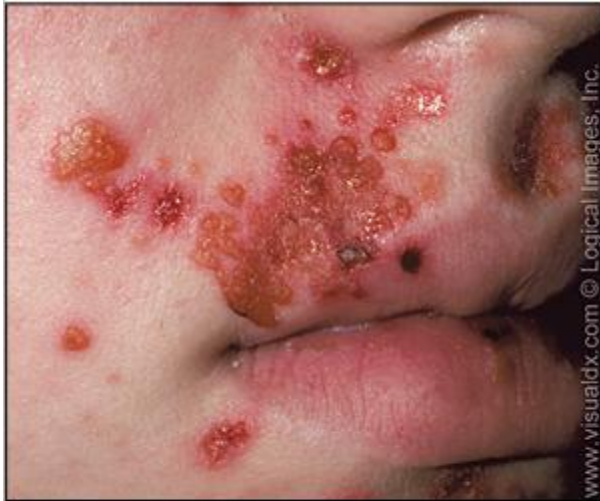

Figure 1.  
Honey-colored crust of nonbullous impetigo.

Mupirocin (pseudomonic acid A) is the major metabolite of *Pseudomonas fluorescens* fermentation. (24) Its chemical structure is not related to antibacterial agents and due to its unique mechanism of action there is no cross-resistance with other antibiotics. Mupirocin acts by inhibiting bacterial protein synthesis, by binding with isoleucyl-tRNA synthetase enzyme, thus preventing the incorporation of isoleucine into protein chains. It is highly effective against *Staphylococcus aureus*, *Streptococcus pyogenes* and all other species of streptococci except those of group D. (25)

It is less effective against Gram-negative bacteria, but exhibits in vitro activity against *Haemophilus influenzae*, *Neisseria gonorrhoeae*, *Pasteurella multocida*, *Bordetella pertussis*, and *Moraxella catarrhalis*. It is not active against bacteria of the normal cutaneous flora and therefore does not alter the skin's natural defense. Mupirocin's

bactericidal activity is increased by the acidic pH on the skin. It can eradicate *S. aureus* on the skin. (26) Bacterial resistance rate is low, around 0.3% for *S. aureus* strains. MRSA resistance to mupirocin has already been described. Adverse reactions are reported in 3% of patients, with itching and irritation at the application site being the most common ones. Photoreactions are unlikely, because the range of ultraviolet light that is absorbed by the product does not penetrate the ozone layer. (27) Systemic absorption is minimal and the little that is absorbed is rapidly converted to inactive metabolite, hence the reason why there are not oral or parenteral formulations available. The use in extensive area or in patients with burns aren't recommended, because of the risk of nephrotoxicity and absorption of the drug's vehicle, polyethylene glycol, especially in patients with renal insufficiency. In the United States there is already a formulation of mupirocin ointment without polyethylene glycol. It is considered safe and effective in patients over two-months old. It is listed in category B for use in pregnant and lactating women. The product is found in Brazil as 2% cream. (28)

Systemic antimicrobial agents are indicated when there is involvement of deeper structures (subcutaneous tissue, muscle fascia), fever, lymphadenopathy, pharyngitis, infections near the oral cavity, infections on the scalp and / or numerous lesions more than five. (29) The spectrum of the selected antibiotic must cover staphylococci and streptococci, both for bullous impetigo as well as for crusted impetigo. Thus, benzathine penicillin or those sensitive to penicillinases are not indicated in the treatment of impetigo. (30) Penicillins that are resistant to penicillinase (oxacillin, cloxacillin, dicloxacillin) can be used, but the difficulty lies in the absence of a specific formulation for oral use in Brazil. The first-generation cephalosporins, such as cephalexin and cefadroxil, may be used, since no differences between them was found in a meta-analysis. Erythromycin, being less expensive, can become the antibiotic of choice for the most impoverished populations. One should take into account the possibility of resistance to *S. aureus*, which occurs in varying rates, depending on the population studied. (31) Other macrolides such as clarithromycin, roxithromycin and azithromycin have the advantage of presenting fewer side effects in the gastrointestinal tract, as well as a more comfortable posology, although with a higher cost. Staphylococcal strains that are resistant to erythromycin will also be resistant to clarithromycin, roxithromycin and azithromycin.

(32) The amoxicillin associated with clavulanic acid is the combination of one penicillin with a beta-lactamase inhibiting agent (clavulanic acid), thus enabling adequate coverage for streptococci and staphylococci. (33)

Clindamycin, sulfamethoxazole / trimethoprim, minocycline, tetracycline and fluoroquinolones are the antibiotics of choice for MRSA. (34)

### **Prognosis:**

Without treatment, the infection heals in 14-21 days. About 20% of cases resolve spontaneously. Scarring is rare but some patients may develop pigmentation changes. Some patients may develop ecthyma. With treatment, cure occurs within 10 days. Neonates may develop meningitis. A rare complication is acute post streptococcal glomerulonephritis, which occurs 2-3 weeks after the skin infection. (35)

### **Complications:**

While most patients do improve with therapy, a few patients may develop renal failure. This is more likely if the infection is due to streptococcus. The renal dysfunction appears 7-14 days after the infection. The transient hematuria and proteinuria may last a few weeks or months. Other complications include septic arthritis, scarlet fever, sepsis, and staphylococcal scalded skin syndrome. (36)

### **Conclusion:**

Impetigo is the most common bacterial skin infection in children. It is treated by topical antibiotics such as mupirocin, retapamulin, and fusidic acid. Oral antibiotic therapy can be used for impetigo with large blisters or when topical therapy is not practical. Amoxicillin / clavulanate, dicloxacillin, cephalexin, clindamycin, doxycycline, minocycline, trimethoprim / sulfamethoxazole, and macrolides are optional, but penicillin is not.

## References:

1. Oumeish I, Oumeish OY, Bataineh O. Acute bacterial skin infections in children. *Clin Dermatol*. 2000;18:667–678. [[PubMed](#)] [[Google Scholar](#)]
2. Vlassova N, Han A, Zenilman JM, James G, Lazarus GS. New horizons for cutaneous microbiology: the role of biofilms in dermatological disease. *Br J Dermatol*. 2011;165:751–759. [[PubMed](#)] [[Google Scholar](#)]
3. Chiller K, Selkin BA, Murakawa GJ. Skin microflora and bacterial infections of the skin. *J Investig Dermatol Symp Proc*. 2001;6:170–174. [[PubMed](#)] [[Google Scholar](#)]
4. Nardi NM, Schaefer TJ. Impetigo. 2021 Aug 11. In: StatPearls [Internet]. Treasure Island (FL): StatPearls Publishing; 2021 Jan–. PMID: 28613693.
5. Carrol JA. Common bacterial pyodermas. *Postgrad Med*. 1996;100:311-3, 317-22. [[PubMed](#)] [[Google Scholar](#)]
6. Scaramuzzino DA, McNiff JM, Bessen DE. Humanized in vivo model for streptococcal impetigo. *Infect Immun*. 2000;68:2880–2887. [[PMC free article](#)] [[PubMed](#)] [[Google Scholar](#)]
7. Loadsman MEN, Verheij TJM, van der Velden AW. Impetigo incidence and treatment: a retrospective study of Dutch routine primary care data. *Fam Pract*. 2019 Jul 31;36(4):410-416. [[PubMed](#)]
8. Lin JN, Chang LL, Lai CH, Lin HH, Chen YH. Clinical and molecular characteristics of invasive and noninvasive skin and soft tissue infections caused by group A streptococcus. *J Clin Microbiol*. 2011;49:3632–3637. [[PMC free article](#)] [[PubMed](#)] [[Google Scholar](#)]
9. Brown J, Shriner DL, Schwartz RA, Janniger CK. Impetigo: an update. *Int J Dermatol*. 2003;42:251–255. [[PubMed](#)] [[Google Scholar](#)]
10. Durupt F, Mayor L, Bes M, Reverdy ME, Vandenesch F, Thomas L, et al. Prevalence of Staphylococcus aureus toxins and nasal carriage in furuncles and impetigo. *Br J Dermatol*. 2007;157:1161–1167. [[PubMed](#)] [[Google Scholar](#)]

11. Araújo T, Schacner L. Benign vesicopustular eruptions in the neonate. *An Bras Dermatol*. 2006;81:359–366. [[Google Scholar](#)]
12. Qian YU, Li W, Yang L. A case of goggle-mask-related impetigo at the time of the COVID-19 pandemic. Running title: Goggle-mask-related impetigo. *Dermatol Ther* 2020; **33**: e13636. [PubMed](#) [Web of Science](#) [Google Scholar](#)
13. Gomolin TA, Cline A, Russo M. Maskne: exacerbation or eruption of acne during the COVID-19 pandemic. *SKIN J Cutaneous Med* 2020; **4**: 438– 439. [Crossref](#) [Google Scholar](#)
14. Han C, Shi J, Chen Y, Zhang Z. Increased flare of acne caused by long-time mask wearing during COVID-19 pandemic among general population. *Dermatol Ther* 2020; **29**: e13704. [Google Scholar](#)
15. Yu J, Chen JK, Mowad CM *et al*. Occupational dermatitis to facial personal protective equipment in healthcare workers: a systematic review. *J Am Acad Dermatol* 2021; **84**: 486– 494. [Crossref](#) [CAS](#) [PubMed](#) [Web of Science](#) [Google Scholar](#)
16. Hirschmann JV. Impetigo: etiology and therapy. *Curr Clin Top Infect Dis*. 2002;22:42-51. PMID: 12520646.
17. Koning S, van der Sande R, Verhagen AP, van Suijlekom-Smit LW, Morris AD, Butler CC, et al. Interventions for impetigo. *Cochrane Database Syst Rev*. 2012;1: [[PMC free article](#)] [[PubMed](#)] [[Google Scholar](#)]
18. Bangert S, Levy M, Hebert AA. Bacterial resistance and impetigo treatment trends: a review. *Pediatr Dermatol*. 2012;29:243–248. [[PubMed](#)] [[Google Scholar](#)]
19. Hartman-Adams H, Banvard C, Juckett G. Impetigo: diagnosis and treatment. *Am Fam Physician*. 2014 Aug 15;90(4):229-35. PMID: 25250996.
20. Taylor JS. Interventions for impetigo. *Am Fam Physician*. 2004 Nov 1;70(9):1680-1. PMID: 15554483.
21. Pérez LC, López PB, Barrios M, Ulloa SR, Aguilera OS, Perfaur MC, et al. Etiología del impétigo infantil. Etiology of impetigo in children. *Rev Chil Pediatr*. 2001;72:199–203. [[Google Scholar](#)]
22. Mancini AJ. Bacterial skin infections in children: the common and the not so common. *Pediatr Ann*. 2000;29:26–35. [[PubMed](#)] [[Google Scholar](#)]

23. Nagaraju U, Bhat G, Kuruvila M, Pai GS, Jayalakshmi, Babu RP. Methicillin-resistant *Staphylococcus aureus* in community-acquired pyoderma. *Int J Dermatol*. 2004;43:412–414. [[PubMed](#)] [[Google Scholar](#)]
24. Castro MCR, Ramos-E-Silva M. Cutaneous infections in the mature patient. *Clin Dermatol*. 2018 Mar - Apr;36(2):188-196. [[PubMed](#)]
25. May PJ, Tong SYC, Steer AC, Currie BJ, Andrews RM, Carapetis JR, Bowen AC. Treatment, prevention and public health management of impetigo, scabies, crusted scabies and fungal skin infections in endemic populations: a systematic review. *Trop Med Int Health*. 2019 Mar;24(3):280-293. [[PMC free article](#)] [[PubMed](#)]
26. Sahu JK, Mishra AK. Ozenoxacin: A Novel Drug Discovery for the Treatment of Impetigo. *Curr Drug Discov Technol*. 2019;16(3):259-264. [[PubMed](#)]
27. Feaster T, Singer JI. Topical therapies for impetigo. *Pediatr Emerg Care*. 2010 Mar;26(3):222-7; quiz 228-31. doi: 10.1097/PEC.0b013e3181d1e71b. PMID: 20216288.
28. Vainer G, Torbensen E. Behandling af impetigo i almen praksis. En sammenligning mellem tre lokalantibiotika [Treatment of impetigo in general practice. Comparison of 3 locally administered antibiotics]. *Ugeskr Laeger*. 1986 May 12;148(20):1202-6. Danish. PMID: 3523909.
29. Eells LD, Mertz PM, Piovanetti Y, Pekoe GM, Eaglstein WH. Topical antibiotic treatment of impetigo with mupirocin. *Arch Dermatol*. 1986 Nov;122(11):1273-6. PMID: 3096221.
30. Mertz PM, Marshall DA, Eaglstein WH, Piovanetti Y, Montalvo J. Topical mupirocin treatment of impetigo is equal to oral erythromycin therapy. *Arch Dermatol*. 1989 Aug;125(8):1069-73. PMID: 2502950.
31. Oranje AP, Chosidow O, Sacchidanand S, Todd G, Singh K, Scangarella N, Shawar R, Twynholm M; TOC100224 Study Team. Topical retapamulin ointment, 1%, versus sodium fusidate ointment, 2%, for impetigo: a randomized, observer-blinded, noninferiority study. *Dermatology*. 2007;215(4):331-40. doi: 10.1159/000107776. PMID: 17911992.

32. Kluytmans-Vandenberg MF, Kluytmans JA. Community-acquired methicillin-resistant *Staphylococcus aureus*. *Clin Microbiol Infect*. 2006;12:9–15. [[PubMed](#)] [[Google Scholar](#)]
33. Del Giudice P, Hubiche P. Community-associated methicillin-resistant *Staphylococcus aureus* and impetigo. *Br J Dermatol*. 2010;162:905. [[PubMed](#)] [[Google Scholar](#)]
34. George A, Rubin G. A systematic review and meta-analysis of treatments for impetigo. *Br J Gen Pract*. 2003;53:480–487. [[PMC free article](#)] [[PubMed](#)] [[Google Scholar](#)]
35. Tveten Y, Jenkins A, Kristiansen BE. A fusidic acid-resistant clone of *Staphylococcus aureus* associated with impetigo bullosa is spreading in Norway. *J Antimicrob Chemother*. 2002;50:873–876. [[PubMed](#)] [[Google Scholar](#)]
36. Eichenfield LF, Carney PS, Chow MJ, Tal A, Weinberg JM, Yurko M. Unique approaches for the topical treatment and prevention of cutaneous infections: report from a clinical roundtable. *Cutis*. 2004;74:2–23. [[PubMed](#)] [[Google Scholar](#)]