

Geriatric Physiotherapeutic Approach For Intertrochanteric Fracture- A Case Report

Abstract:

Hip fractures are a growing concern around the world as the geriatric population increases rapidly. The purpose of this study was to assess the impact of proximal femoral nailing on elderly. Despite the fact that intertrochanteric fracture fixation is generally successful, treatment is difficult when fixation fails. The purpose of this study was to assess the efficacy of an evidence-based protocol designed for the treatment of failed intertrochanteric fractures. When treating an unstable intertrochanteric fracture, there is a lesser risk of implant failure and reoperation, as well as a better postoperative functional recovery is seen. But in some rare cases some implant failures are major and requires a long term treatment. Intertrochanteric femur fractures, particularly those with unstable patterns, are increasingly being treated with intramedullary implants. Despite the widespread use of nails in the treatment of these fractures, perspectives on the proper length of an intramedullary nail differ. Long nails were created to alleviate the risk of diaphyseal fracture that came with prior short nail designs. The main aim is to govern the unstable nail fixation of the intertrochanteric femoral fractures.

Keywords: Intertrochanteric fracture, Long proximal femoral nailing, Implant failure, Rehabilitating

Introduction

Hip joint is a synovial joint of ball and socket variety. It is the weight bearing joint of the body⁽¹⁾. The iliofemoral, ischiofemoral, and pubofemoral ligaments of the hip joint play a major role in functional mobility and joint stability. Despite the fact that intertrochanteric fracture fixation is generally successful, treatment is difficult when fixation fails⁽²⁾. When treating an unstable intertrochanteric fracture, there is a lesser risk of implant failure and reoperation, as well as a better postoperative functional recovery is seen⁽²⁾. Long nails were created to alleviate the risk of diaphyseal fracture that came with prior short nail designs⁽³⁾⁽⁴⁾. Hip fractures are connected with higher mortality and cause severe morbidity. Women account for 80% of hip fractures, and people with hip fractures are on average more than 70 years old. A fall is the most common cause of hip fractures, although other risk factors include low bone mineral density, low exercise, and chronic medication usage⁽⁵⁾. Hip fracture patients have groin pain and are unable to bear weight on the affected limb. Displaced with external rotation and abduction are observed during the physical examination⁽⁶⁾. Hip fractures are common as the hip joint is main weight bearing joint. Trochanteric fractures are becoming more common as the number of elderly people with osteoporosis rises⁽⁷⁾. Intracapsular and extracapsular hip fractures can be distinguished radiographically. Depending on the depth of the fracture and the presence or absence of displacement and comminution, these can be further categorized⁽⁸⁾. Intertrochanteric fractures are defined as extracapsular fractures of the proximal femur that occurs between the greater and lesser trochanter. The intertrochanteric aspect of the femur is located between the greater and lesser trochanters and is composed of dense trabecular bone⁽⁹⁾.

Patient Information:

79 years old female resident of Borgaon Wardha, presented to Acharya VinobhaBhave Rural Hospital with incidence of fall from bed and complaint of pain over hip joint of left side and inability in walking with generalized weakness of the respective limb along with inability to do daily activities normally. Patient is a known case of hypertension.

Patient was brought to casualty with injury to her left hip 6 months ago for which she was managed with proximal femoral nailing for fracture neck of femur of left side. Pain was sudden in onset and gradually progressive. Pain increases while moving the limb and decreases on taking rest. The pain does not radiate to any other part of the body. Pain is dull aching in nature. Pain does not have any diurnal or seasonal variation. She has been

diagnosed with intertrochanteric fracture of left femur. For further management she was recommended for physiotherapy.

Clinical Findings:

On physical examination the findings were found normal.

The general examination was normal.

Table 1: Pulse, respiratory rate, blood pressure and temperature was also normal.

Decubitus	NORMAL
Nutritional Status	NORMAL
Higher Function	NORMAL
Hairs	NORMAL
Eyes & Sclera	NORMAL
Ears	NORMAL
Tongue	NORMAL
Teeth	NORMAL
Lymph Nodes:	
Cervical	NOT PALPABLE
Axillary	NOT PALPABLE
External Iliac	NOT PALPABLE
Inguinal	NOT PALPABLE
Others	NOT PALPABLE

Table 2: Range of motion in pre and post condition with physiotherapy management;

	Pre- Physiotherapy	Post- Physiotherapy
Hip Joint (left side)		
Flexion	0-23*	0-60*
Extension	0-20*	0-55*
Abduction	0-15*	0-30*
Adduction	0-15*	0-30*
Internal Rotation	0-10*	0-25*

External Rotation	0-10*	0-25*
-------------------	-------	-------

Table 3: Manual Muscle Testing Strength

Muscles	Right	Left
Hip Flexors	NORMAL	3
Hip Extensors	NORMAL	3
Hip Abductors	NORMAL	3
Hip Adductors	NORMAL	3

Table 4: Isometric strength evaluation

Muscles	Right	Left
Hip:		
Flexors	NORMAL	Weak and Painless
Extensors	NORMAL	Weak and Painless
Abductors	NORMAL	Weak and Painless
Adductors	NORMAL	Weak and Painless

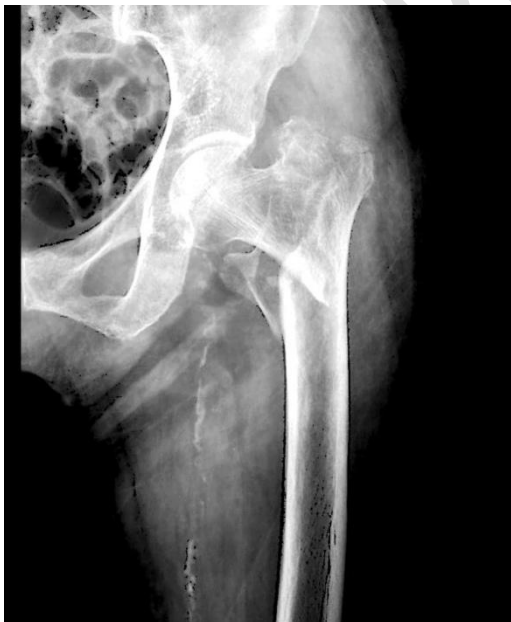

Figure 1- Shows preoperative X-ray of Neck of femur fracture

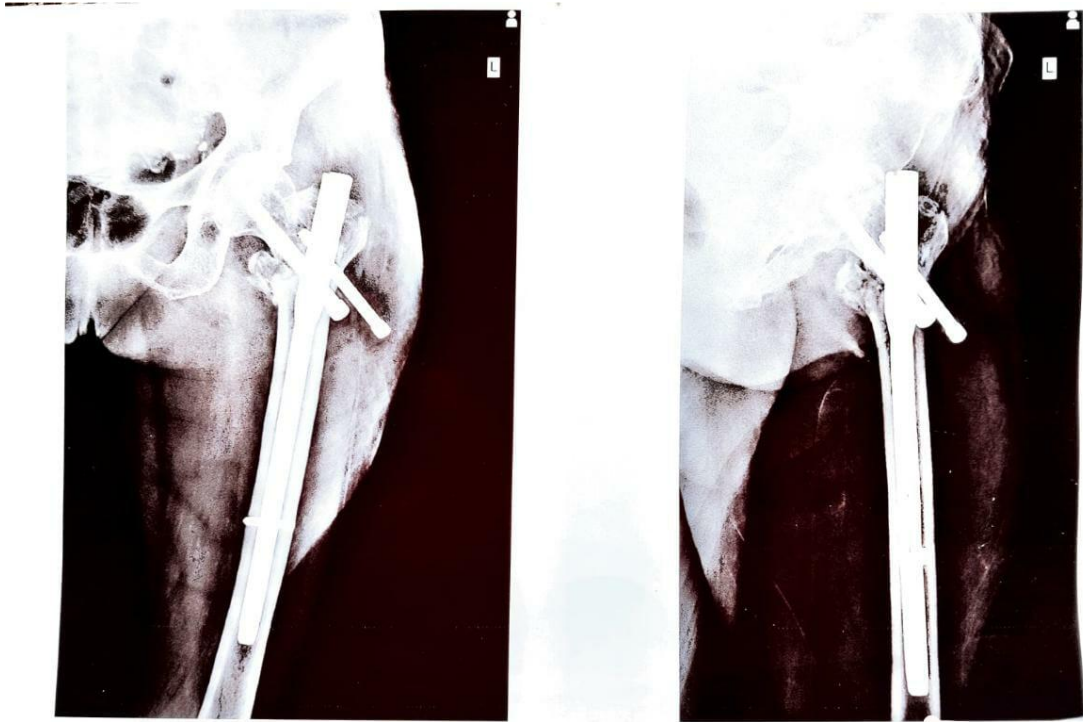


Fig.1-PostOperative X-ray

Treatment:

Table 5: Therapeutic Management:

Phase (week wise)	Therapeutic exercise
Phase I: Immediate postoperative phase (Week 1-2)	
Precaution	No active ROM of Hip joint. Avoid activities of daily living. No lifting of heavy objects. Avoid prone and side lying
To reduce inflammation	Cryotherapy application for 8 to 10 minutes
To reduce pain and tenderness	Application of ice pack for 8 – 10 minute Thermotherapy, Ultrasound, two times a day.

To improve range of motion	Hip and knee passive ROM exercises, 10 repetitions x 2 Isometric exercises – static quadriceps, hamstring, glutes (5sec hold ,10 sec relax, 10 repetitions ,2 sets) Isotonic exercises – ankle pumps
Phase II: Protection phase(week 2-6)	
To reduce inflammation and pain	Cryotherapy continued for 8 to 10 min
To improve ROM	Progressive active assisted exercises for back, knee and ankle. Progress to passive ROM until full pain free ROM is achieved. Isometric exercises for hip, knee, and ankle (5sec hold,10 sec relax, 10 repetitions, 2 sets) Ankle pumps to prevent deep vein thrombosis
To improve strength endurance and functional activities	Core stabilisation exercises. Strengthening of uninvolved lower extremity. Power conditioning in right lower extremity
Phase III: Intermediate phase (6-8 week)	
To improve ROM and muscle strength, endurance and functional activities	Active range of motion of lower limb and back Started strengthening program to lower limb muscle with theraband(10x2) Modality- continuous passive motion (CPM), Faradic current-electric muscle stimulation. Exercises such as heel slides, bed side sitting, assisted and resisted exercises of back and lower limb.
Phase IV : Advanced strengthening exercises (week 8-10)	

To improve strength, endurance and functional activities	Active full range of motion and stretching exercises. enhancing stability, balance, fitness and open-chain proprioceptive activities. Progressive strengthening exercises(10×2) Resisted and dynamic exercises to quadriceps, hamstring, glutei and back muscles
--	---

Discussion:In this case report we are discussing a case of 79 year old with intertrochanteric fracture managed with intramedullary nail. Surgical approaches to manage depends upon the age and the mobility and stability requirement of the patient.

In this case, the primary goal of physiotherapy management was to educate the patient, prevent the deformities and other secondary complications. For the prevention of secondary complication ankle toe movements were initiated on the second day of the surgical process⁽¹⁰⁾. Ankle toe movement's helps in maintaining the peripheral circulation and to maintain the mobility of distal joint. Gabriel's study showed that physical therapy has an effect on maintaining the mobility and enhancing the gait of the patient. In gait training we start with non-weight bearing walking progress to partial weight bearing and then to full weight bearing. For the gait training, training of unaffected limb plays an important. So, range of motion and strength training was provided to the unaffected leg, Home physiotherapy was given in order to maintain the strength and range of motion of the patient.

Conclusion:

Intertrochanteric fractures are most common fractures among old age people. Proper management of such fractures plays important role in quality of life of the patient. Early physiotherapy rehabilitation helps in maintaining the range of motion and strength of the joint.

Consent Disclaimer:

As per international standard or university standard, patient's consent has been collected and preserved by the authors.

References:

1. Chang S-M, Hou Z-Y, Hu S-J, Du S-C. Intertrochanteric Femur Fracture Treatment in Asia: What We Know and What the World Can Learn. *OrthopClin North Am.* 2020 Apr;51(2):189–205.
2. Yu X, Wang H, Duan X, Liu M, Xiang Z. Intramedullary versus extramedullary internal fixation for unstable intertrochanteric fracture, a meta-analysis. *ActaOrthopTraumatolTurc.* 2018 Jul;52(4):299–307.
3. Horwitz DS, Tawari A, Suk M. Nail Length in the Management of Intertrochanteric Fracture of the Femur. *J Am AcadOrthop Surg.* 2016 Jun;24(6):e50-58.
4. Ng KCG, Jeffers JRT, Beaulé PE. Hip Joint Capsular Anatomy, Mechanics, and Surgical Management. *J Bone Joint Surg Am.* 2019 Dec 4;101(23):2141–51.
5. Jung D-K, Chung Y-J. The Effect of a Hip Joint Strengthening Exercise using PNF on Balance, Sit-to-Stand Movement, and Gait in a Tibia Fracture Patient with Skin Defects - A Single Case Study -. *PNF Mov.* 2018;16(3):317–32.
6. LeBlanc KE, Herbert L, Muncie J, LeBlanc LL. Hip Fracture: Diagnosis, Treatment, and Secondary Prevention. *Am Fam Physician.* 2014 Jun 15;89(12):945–51.
7. Babhulkar S. Unstable trochanteric fractures: Issues and avoiding pitfalls. *Injury.* 2017 Apr;48(4):803–18.
8. Parker M, Johansen A. Hip fracture. *BMJ.* 2006 Jul 1;333(7557):27–30.
9. Bawiskar D, Dhote S, Phansopkar P. Early physical rehabilitation post-surgery in a complex type 5 SchatzkerTibial plateau fracture improves functional outcomes: A case report. 2020;8.
10. Phansopkar P, Naqvi WM. Early physiotherapy rehabilitation approach enhances recovery in rare acute tibial osteomyelitis post-operative in a 9 year old child. 2020;5.