

A Rare Case of Renal Squamous Cell Carcinoma with Underlying Staghorn Calculus as Confounding Factor

**Shubham Pratap Durge¹, Anurag Anupkumar Bhattacharjee^{2*}, Harshal Ramteke³,
Abhishek Gupta⁴, Varun Kulkarni⁵, Shyamal Shaha⁶, Roshani Mannek⁷**

¹Department of General Surgery, Datta Meghe Institute of Medical Sciences, Wardha, Maharashtra

²Department of General Surgery, Datta Meghe Institute of Medical Sciences, Wardha, Maharashtra

³Department of General Surgery, Datta Meghe Institute of Medical Sciences, Wardha, Maharashtra

⁴Department of General Surgery, Datta Meghe Institute of Medical Sciences, Wardha, Maharashtra

⁵Department of General Surgery, Datta Meghe Institute of Medical Sciences, Wardha, Maharashtra

⁶Department of General Surgery, Datta Meghe Institute of Medical Sciences, Wardha, Maharashtra

⁷Department of General Surgery, Datta Meghe Institute of Medical Sciences, Wardha, Maharashtra

ABSTRACT

Renal cell carcinoma is one of the most common kidney pathologies in adults, responsible for approximately 90-95% of cases. The most common variant is clear cell accounting for 60-70% of cases, while papillary accounts for 10-15% of the cases.

Diagnosis of carcinoma in the presence of staghorn calculus is seen in less than 1% of patients in recorded data. However, squamous cell carcinoma of the kidney is a rare condition usually associated with chronic irritation by a foreign body, most likely due to staghorn calculus. Here we present a case report of a 65 year old male who came with complaint of pain in the abdomen since two months associated with malaise, weight loss and fever.

CT KUB was suggestive of a non-excreting enlarged left kidney with multiple calculi with abnormal cortical and periureteric lesions with encasement of adjacent vessels. Histopathological report revealed a rare case of primary squamous cell carcinoma, most probably originating from the pelvis and secondarily infiltrating the renal parenchyma and associated with nephrolithiasis and hydronephrosis. Initially the patient was managed conservatively. Later the patient underwent nephrectomy.

Keywords

Squamous cell carcinoma; Nephrolithiasis; Hydronephrosis; Abdominal pain; Pyelonephritis

Introduction

Staghorn calculi are radio-opaque stones that tend to occupy the renal pelvis. Inadequate management of staghorn calculi can cause severe complications such as renal dysfunction or pyelonephritis leading to urosepsis. However, rare cases have shown squamous metaplasia of the renal pelvis to squamous cell carcinoma. [1] In the upper urinary tract system, urothelial carcinoma is the most common type of malignancy. Conversely, squamous cell carcinoma (SCC) is rare and has a prevalence of <1% among urinary tract neoplasms. [2]

Case Report

A 65 year old male came to a casualty with complaint of pain over the left side of the abdomen for two months. The pain was insidious in onset, gradually progressive with radiation to the back and was associated with fever, malaise and weight loss. The patient reported similar complaints in the past as well, dating back to 15 years. Systemic examination revealed tenderness in the left lumbar region associated with a nodular, non mobile lump of size 7x6 cm with diffuse margins palpable in the left lumbar region on deep palpation. Leukocyte count was 47400 on admission. The renal function tests were deranged with serum creatinine value: 4.8.

Sr. No.	Investigation done	Report
1.	USG Abdomen Pelvis	<p>Findings:</p> <p>Multiple calculi in the renal pelvis with the largest measured to be approximately 4x3.8 cm in size noted at pelviureteric junction causing mild dilatation of pelvicalyceal system suggestive of mild hydronephrosis</p> <p>Impression:</p> <p>Nephrolithiasis of the left kidney with moderate left-sided hydronephrosis</p>
2.	CT Urography	<p>Findings:</p> <ul style="list-style-type: none"> • Left kidney enlarged with

		<p>evidence of multiple calculi in all calyces. Multiple non-enhancing hypodense areas replacing renal cortex noted with poor appreciation of pelvicalyceal system, paper cortical thinning present. Perinephric fat stranding seen.</p> <ul style="list-style-type: none">• Right kidney shows evidence of multiple central non-enhancing areas with peripheral enhancement, largest of size 2.2x1.2 cm.• Mild enhanced thickening of renal pelvis seen.• Hypodense ill-enhancing areas at renal hilum extending to adjacent retroperitoneal region, encasing adjacent aorta• Lesion encases renal vein with poor identification and enhancement of renal vein. Lesion also encases renal artery however there is normal post contrast enhancement of renal artery.• Left ureter poorly identified with multiple enhancing lesions in periureteric region and periureteric fat stranding.
--	--	--

		<ul style="list-style-type: none"> • Multiple enlarged lymph nodes in para caval, para aortic and aorto caval and left iliac regions with few showing central necrosis. <p>Impression:</p> <ul style="list-style-type: none"> • Non-excreting enlarged left kidney with multiple calculi and abnormal cortical and periureteric lesions with encasement of adjacent vessels • Normal excreting right kidney with evidence of pyelonephritis and few cortical abscesses • Multiple adenopathy and poor appreciation/poor post contrast enhancement of right renal vein; possible differentials being: <ol style="list-style-type: none"> 1-Xanthogranulomatous pyelonephritis 2-Pyonephrosis with perinephric and periureteric inflammation 3-Possibility of renal malignancy • Persistent focal filling defect
--	--	---

		<p>in right renal vein – possibly focal thrombosis</p>
<p>3.</p>	<p>CECT KUB (senior review)</p>	<p>Findings:</p> <ul style="list-style-type: none"> • Enlarged left kidney showing Grade-III hydronephrosis with thinning of renal parenchyma • Multiple calculi noted in left kidney associated with multiple peripherally enhancing lymph nodes at left renal hilum and in the course of ureter with surrounding fat strandings • Patchy areas of hypodensity in lower pole of right kidney with hypodense medullary pyramid • Pyelonephritis in right kidney <p>Impression:</p> <ul style="list-style-type: none"> • Left sided kidney pyelonephrosis v/s tuberculous kidney (putty kidney) • Right sided kidney pyelonephritis

4.	Histopathology report	<p>Gross findings:</p> <ul style="list-style-type: none"> • Cut open sutured left nephrectomy specimen (16.5x10.8 cm) with attached ureter (4 cm length) shows presence of diffuse tumor ranging from size 15x8x7 cm occupying whole of kidney • On cut section, large greyish white, necrotic and hemorrhagic areas seen along with staghorn calculi measuring 8x6x4 cm • Multiple calculi identified (approximately 15 in number) <p>Histopathology findings:</p> <ul style="list-style-type: none"> • Section from tumor mass shows histopathological features suggestive of well differentiated squamous cell carcinoma • Section from pelvis and ureter shows infiltration by malignant epithelial cells • Section from renal vessels shows tumor emboli <p>Impression: Histopathological features suggestive</p>

		<p>of Primary Squamous Cell Carcinoma probably originating from renal pelvis and secondarily infiltrating renal parenchyma</p> <p>TNM Staging: pT3apNxMx (Stage III)</p>
--	--	--

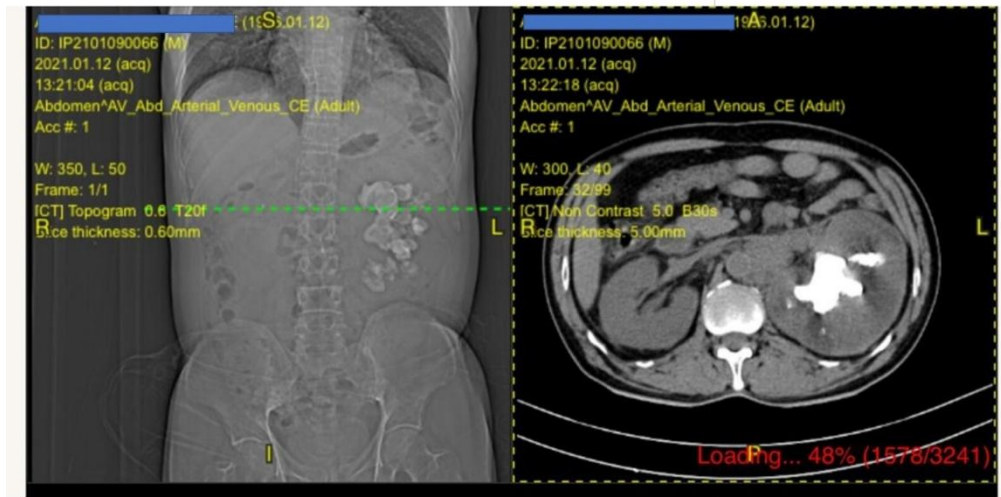


Figure 1: CT film; Sagittal view and topogram showing staghorn calculi in left kidney

Patient subsequently went into sepsis and was unfit for chemotherapy or radiotherapy options. In view of the deteriorating condition, a decision was taken to immediately operate. The patient underwent left sided nephrectomy and the retrieved specimen was sent for histopathological review.

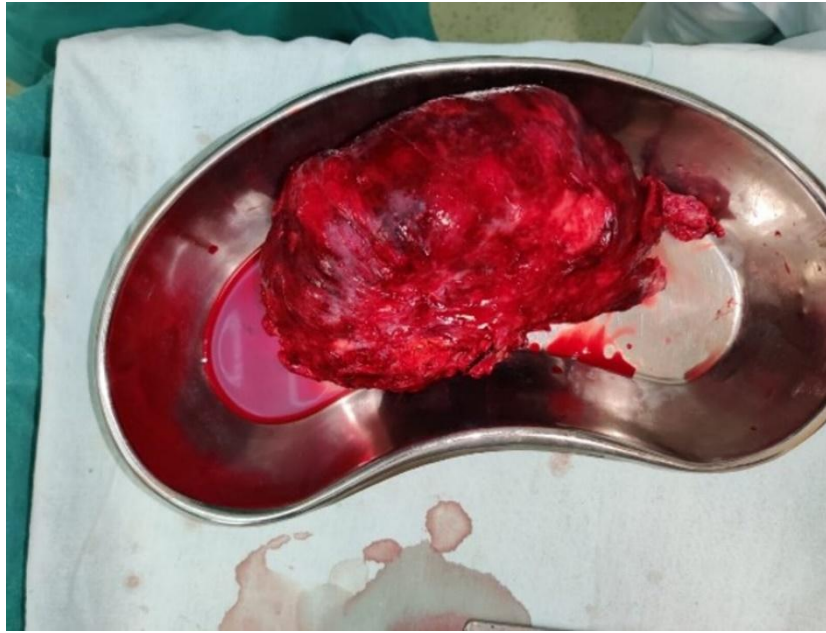


Figure 2: Showing gross specimen of retrieved kidney

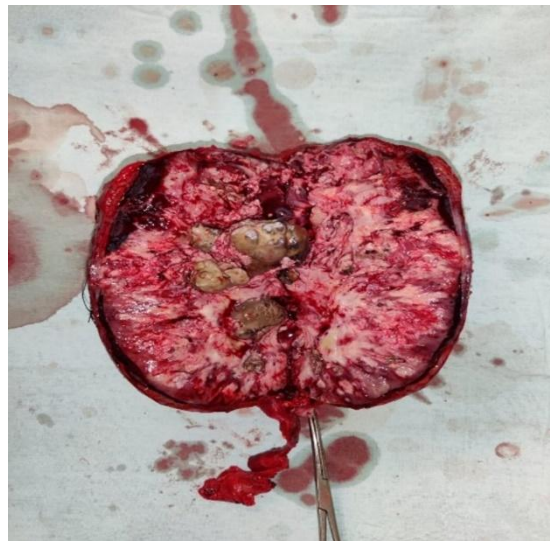

Figure 3: Showing cut section of a retrieved kidney with multiple calculi

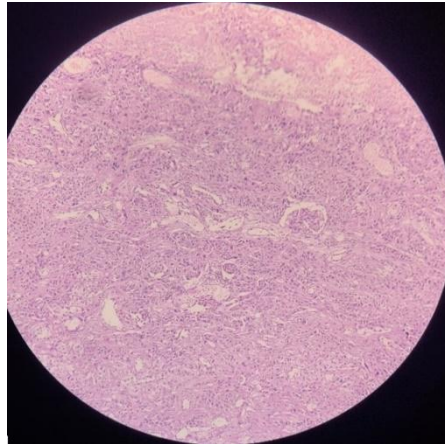


Figure 4: Histopathology slides showing keratin pearl formation

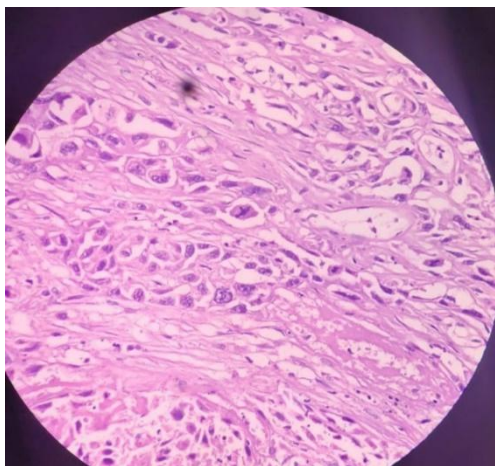


Figure 5: Histopathology slides showing irregular squamous nests under 40X magnification

Management: Patients urinary output was low and patient was having recurrent episodes of fever. Patient was in sepsis as leukocyte count was on increasing trend day by day. Hence patient underwent a left sided nephrectomy under general anaesthesia.

Discussion

The most frequently occurring neoplasms within the urinary tract are urothelial carcinomas. SCC in the renal pelvis is rare and only accounts for 0.5% of malignant renal tumours [3]. Renal SCCs are aggressive tumours with a worse prognosis in comparison to other urothelial carcinomas since they tend to be detected at mostly advanced stages (pT3 or more significant) [4,5]. The prognosis for renal SCC is abysmal and less than 10% of patients are reported to survive upto five years [5,6]. It is unclear whether renal calculi can cause SCC. Some studies have reported that urothelial epithelium may lead to squamous metaplasia with chronic irritation or inflammation, which progresses to dedifferentiation, dysplasia, and, ultimately, carcinogenesis [5]. The coexistence of calculi has been reported in approximately 90% cases of renal SCC [3,7,8]. Previous studies have mentioned that patients with renal SCC had chronic episodes of pyelonephritis or nephrolithiasis [9,10]. In most cases reported, the diagnosis of SCC is made during the histopathologic examination of the excised kidney.[11] This may be due to nonspecific symptoms patients present with, which overlaps with those of renal stones. Nonspecific radiological findings as well as the biologic growth pattern of this tumor; which in most cases does not produce an exophytic mass that could easily be detected on radiologic examination is also another reason. [12] A study by Narumi et al. found that renal pelvic and ureteral SCC demonstrated predominantly extraluminal extension with invasion into surrounding organs or the renal parenchyma. [13] A study by Busby et al. reported that half patients have had tumor bed recurrence or distant metastasis within 5 months after operation [14]. The aggressive nature of this tumor is indicated by the extensive regional spread, lymphadenopathy and metastasis to the lungs and liver but rarely to the bones. According to Hameed's study, there were only three cases of SCC of the renal pelvis with bone metastasis reported before 2014 [15]. The first line treatment option is radical surgical resection since alternative treatments have shown to be of limited efficacy. Despite aggressive surgical efforts, prognosis remains poor as most patients die within one year of surgery. [1]. Platinum based chemotherapy and radiotherapy is reserved for patients with metastatic disease, however nephrectomy is still indicated in the presence of

metastasis in order to establish a diagnosis and provide symptomatic relief. [1] Currently, a chemotherapy combination of cisplatin, methotrexate, and bleomycin is employed, but fails to show any survival benefit. The presence of health disparities in rural areas mandates the need to assess survival in these areas in order to understand which factors detract from the successes of standard medical interventions while taking into the consideration the poor prognosis of the disease entity.

Conclusion

Primary renal SCC is a rare entity strongly related to renal stones, which might confound its diagnosis. They may not be radiologically detectable and the first indication of malignancy might come incidentally on histological review of nephrectomy for a non-excreting enlarged calculous kidney. This highlights the need for prompt treatment of renal stones and assessment for renal tumors in patients with long-standing staghorn calculi. The high incidence of SCCs in hydronephrotic kidneys also highlights the need for the meticulous sampling of the renal pelvis by the pathologist in such specimens. Patient workup to rule out tubercular pathology may also be done. The patient's complete blood count profile should be assessed at regular intervals since it was found that the leukocyte trend was increasing in this patient. On the basis of these findings, we speculate that the renal calculus might have initially provoked the metaplasia which then further exacerbated the calculus leading to a vicious cycle and conclusive squamous carcinogenesis.

Limitations and Future Studies

There are multiple variants of renal cancers such as clear cell, papillary, chromophobe, clear cell papillary, collecting duct, and medullary type. However, SCCSs associated with staghorn calculus are a rare condition found in less than 1% of patients. Whenever there is any evidence of renal stones associated with multiple episodes of fever, weight loss, abdominal pain, hematuria, oliguria, malignancy should be suspected. As of recent, there are no diagnostic modalities for early detection of renal cancer other than incidental radiologic discovery. There are also no existing biomarkers for kidney cancer diagnosis. The currently available biomarkers appear to have the most utility as mere diagnostic adjuncts.

Consent Disclaimer:

We have added the Consent Disclaimer in the revised paper. The revised paper is attached herewith this mail for your kind perusal. Kindly check the revised paper

References

- [1] Holmäng et al., (2007). Squamous cell carcinoma of the renal pelvis and ureter: incidence, symptoms, treatment and outcome. *J Urol.* 178(1), 51–6.
- [2] Kasahara R, Kawahara T, Tajiri R, Uemura H, Kitami K: Renal Squamous Cell Carcinoma with Staghorn Calculus. *Case Rep Oncol* 2020;13:403-407. doi: 10.1159/000506675
- [3] Romero et al., (2010). Kidney stones: a global picture of prevalence, incidence, and associated risk factors. *Rev Urol.*12(2-3), 86–96.

[4] Berz et al., (2012). Survival of patients with squamous cell malignancies of the upper urinary tract. *Clin Med Insights Oncol.* 6, 11–8.

[5] Mardi et al., (2010). Rare coexistence of keratinizing squamous cell carcinoma with xanthogranulomatous pyelonephritis in the same kidney: report of two cases. *J Cancer Res Ther.* 6(3), 339–41.

[6] Bhaijee, (2012). Squamous cell carcinoma of the renal pelvis. *Ann Diagn Pathol.* 16(2), 124–7.

[7] Lee et al., (1998). Renal squamous cell carcinoma: CT findings and clinical significance. *Abdom Imaging.* 23(2), 203–8.

[8] Raghavendran et al., (2003). Stones associated renal pelvic malignancies. *Indian J Cancer.* 40(3), 108–12.

[9] Jain et al., (2011). Incidentally detected squamous cell carcinoma of renal pelvis in patients with staghorn calculi: case series with review of the literature. *ISRN Oncol.* 620574.

[10] Talwar et al., (2006). Primary squamous cell carcinoma of the renal pelvis masquerading as pyonephrosis: a case report. *Indian J Pathol Microbiol.* 49(3), 418–20.

[11] Jain A, Mittal D, Jindal A, Solanki R, Khati S, Parikh A, et al. Incidentally detected squamous cell carcinoma of renal pelvis in patients with staghorn calculi: Case series with review of the literature. *ISRN Oncol* 2011;2011:620574.

[12] Ahmad AM, Umar AB, Ali SA. Primary renal squamous cell carcinoma: A case report and literature review. *Arch Int Surg* 2020;10:69-71

[13] Narumi Y, Sato T, Hori S, et al. Squamous cell carcinoma of the uroepithelium: CT evaluation. *Radiology* 1989;173:853-6

[14] Busby JE, Brown GA, Tamboli P, et al. Upper urinary tract tumors with nontransitional histology: a single-center experience. *Urology* 2006;67:518-23.

[15] Hameed ZB, Pillai SB, Hegde P, et al. Squamous cell carcinoma of the renal pelvis presenting as sacral bone metastasis. *BMJ Case Rep* 2014.