

Case report

Bilateral task-oriented training and strengthening leads to improvement in gross motor functioning in patients post-ischemic stroke: An interesting Case study

UNDER PEER REVIEW

Abstract:

Background: A stroke is a medical emergency that requires immediate attention. Early intervention can prevent brain damage and other adverse outcomes. An ischemic stroke occurs when a blood clot stops or narrows in a blood vessel that leads to the brain.

Presentation of case: In the present case, a 63-year-old retired Zila Parishad worker came to our hospital with complaints of fever and weakness; after six days of medication and hospital stay, his fever subsided, but he developed weakness of the right upper extremity and slurring of speech. Regular investigations were done. MRI revealed Acute Infarct in the Left Frontal Region.

Discussion: Bilateral training is proved to be effective in improving hand functioning in patients post-stroke. This is the application of the movement to both the extremity to gain progress.

Conclusion: The patient was provided with medical, regular physiotherapy management, and speech therapy leading to improvement in his condition. He is still under regular physiotherapy for improvement in his fine motor function.

Keywords: Acute ischemic stroke, cerebrovascular disease, rehabilitation, case report

Introduction:

A stroke occurs when blood flow to the brain is disrupted, resulting in a temporary loss of neurological function. Stroke is the fourth leading cause of death in adults and the leading cause of neurological disability⁽¹⁾. A significant public health problem is the prevention of acute ischemic stroke. The purpose of intravenous thrombolysis and endovascular thrombectomy in insufficiently chosen individuals is to achieve recanalization and reperfusion of the ischemic penumbra⁽¹⁾. It is critical to treat ischemic stroke correctly to reduce mortality and morbidity⁽²⁾.

Ischemic stroke is the most common type of stroke, accounting for around 80% of all cases. It is caused by thrombus components that result in low systemic perfusion pressures. Acute ischemic stroke (AIS) is one of the most dangerous conditions that endanger human health worldwide; it causes severe disability and has a high risk of recurrence and mortality⁽³⁾.

Ischemic stroke has been on the rise in young adults since the 1980s, which has coincided with an increase in the prevalence of vascular risk factors and substance abuse among this age group⁽⁴⁾. Ischemic strokes account for 68% of all strokes globally, with hemorrhagic strokes accounting for 32%^(5,6).

The ischemic stroke can affect any of the three territories of the Cerebral artery. Here, the middle cerebral artery is affected, leading to more upper limb involvement. So, our rehabilitation focused more on improving the upper extremity function and task-oriented training to the upper limb⁽⁷⁾.

Patients Information:

A 63 years old male patient, the resident of Yavatmal, Maharashtra, who was retired from his job in 2015 as a worker of Zila Parishad, presented to Acharya VinobhaBhave Rural Hospital with complaints of fever since 10/10/21 along with

cough & cold, and weakness. He then consulted to doctor on the 11th and was on regular medication. On the 6th day, i.e., 16/10/21, he complained of development of numbness in his right arm and had difficulty in speech, and was afebrile. The patient complained of weakness on the right side of the body, but his gait was normal. He faced problems performing movements like daily hand movements, right arm, and no strength in the wrist, and he could not hold the objects. **The patient lived in a rural place and was illiterate.**

Clinical Findings:

The patient is conscious, cooperative, and well oriented. **All the vitals were normal.** During a physical examination, there was no postural abnormality. There was no superficial, profound, or cortical sensory loss. On motor examination, the tone on the right upper extremity was reduced compared to the left side; no voluntary control was there in the right wrist. There was no tonal abnormality in the lower limbs. The range of motion of the right upper limb was reduced, while the left upper limb and both lower limbs had a normal full range of activities. The Deep tendon reflexes, i.e., the biceps jerk and triceps jerk, were diminished on the right side while intact on the left upper extremity. Right-hand coordination was also impaired (Finger- nose test was positive).

Clinical Diagnosis:

The patient was investigated for a routine checkup, MRI, Echo. The Echo was found to be expected. After all the investigations and the clinical findings, the patient was

diagnosed with Acute Infarct in the Left Frontal Region. Age-related atrophic changes with pre ventricular ischemic changes were found.

Table 1: Timeline of events:

Date of visit to the hospital	10/10/2021
Date of start of physiotherapy	17/10/2021
Last date of rehabilitation	01/12/2021

Physiotherapy Interventions:

Physiotherapy was primarily focused on strengthening of muscles of the shoulder joint. Physiotherapy care was provided once a day, which includes passive, active-assisted, and strengthening exercises to the upper limb of the right side. For strengthening, the protocol was ten repetitions of 3 sets with two minutes of rest between the sets. It started with 1kg of weight, progressing to 2kg by the next 15 days. Bilateral training was focused⁽⁷⁾. The patient was given the exercises to the affected side within the pain-free limit to the full range of motion. The patient was asked to actively perform movements of the shoulder joint where possible and was assisted where there was no or less muscle power⁽¹⁰⁾. For the recovery of the wrist curls, rubber band strengtheners, wrist strengtheners improve strength and power in the wrist, forearm, and fingers⁽¹¹⁾.

Outcome Measures:

Outcome Measures	Pre- Rehabilitation	Post-Rehabilitation
MAS (Modified Ashworth Scale)	Grade 1	Grade 0

Brunnstrom stage	Stage 0	Stage 5
Fugl-Mayer Assessment (Upper extremity)	10	27
FIM (Functional Independence Measure)	84	105

Results:

This patient received a normal range of motion exercises and strength training for the upper extremity. He received a proper strengthening protocol and got a tremendous improvement in the gross motor function, but the affection in fine motor function is still under rehabilitation. We achieved the expected recovery in 2-3 weeks.

Discussion:

This case study mainly focused on improving patients' hand function with hemiplegia. Previous literature suggests improved hand function post physiotherapy; the focus was bilateral upper extremity training, leading to enhanced fine and gross motor functions⁽⁹⁾. Rigorous inpatient physiotherapy leads to an early return in role post-ischemic stroke.

Conclusion:

Bilateral upper extremity training leads to early improvement in gross motor function of a patient, but the fine motor functions show late recovery. Most interventions focus on strengthening in the early phase affect stroke survivors' gross motor functioning.

Informed consent: A proper informed consent was taken from the patient prior.



Fig 1: POSTURE: Standing

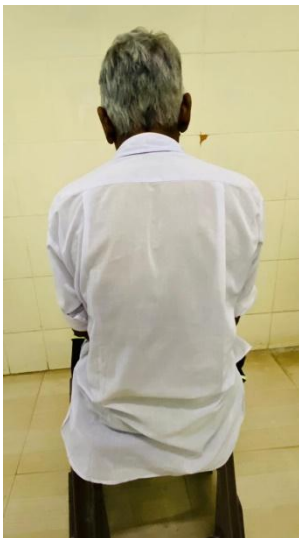

Fig 2: POSTURE: Sitting

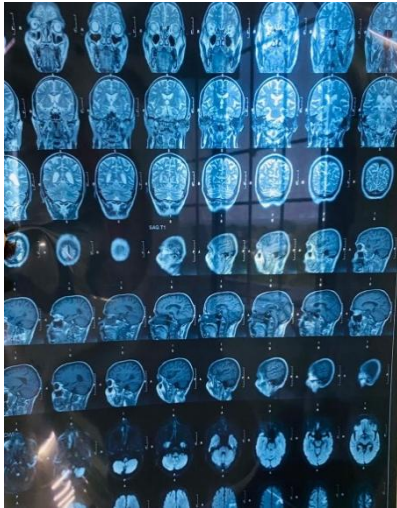


Fig 3: MRI findings of patient

UNDER PEER REVIEW

References:

1. Hurford R, Sekhar A, Hughes TAT, Muir KW. Diagnosis and management of acute ischaemic stroke. *Pract Neurol*. 2020 Aug;20(4):304–16.
2. Herpich F, Rincon F. Management of Acute Ischemic Stroke. *Crit Care Med*. 2020 Nov;48(11):1654–63.
3. Qiu S, Xu Y. Guidelines for Acute Ischemic Stroke Treatment. *Neurosci Bull*. 2020 Jun 19;36(10):1229–32.
4. Putaala J. Ischemic Stroke in Young Adults. *Contin Minneap Minn*. 2020 Apr;26(2):386–414.
5. Chugh C. Acute Ischemic Stroke: Management Approach. *Indian J Crit Care Med Peer-Rev Off Publ Indian Soc Crit Care Med*. 2019 Jun;23(Suppl 2):S140–6.
6. Agrawal A, Joharapurkar SR, Gharde P. Ischemic stroke in a child mistaken as functional disorder. *Clin Neurol Neurosurg*. 2007 Dec;109(10):876–9.
7. Recommendations for the Early Management of Acute Ischemic Stroke: A Consensus Statement for Healthcare Professionals from the Indian Stroke Association - Dheeraj Khurana, M. Vasantha Padma, Rohit Bhatia, Subhash Kaul, Jeyaraj Pandian, P. N. Sylaja, , Deepak Arjundas, Ashok Uppal, V. G. Pradeep, Vinit Suri, D. Nagaraja, Anand Alurkar, Sunil Narayan, , 2018 [Internet]. [cited 2021 Jan 25]. Available from: <https://journals.sagepub.com/doi/abs/10.1177/2516608518777935>
8. Harjpal P, Qureshi MI. Efficacy of bilateral lower limb training over unilateral to re-educate balance and walking in post stroke survivors: a protocol for randomized clinical trial [Internet]. *Protocol Exchange*; 2021 May [cited 2021 Aug 2]. Available from: <https://protocolexchange.researchsquare.com/article/pex-1497/v1>
9. Whittall J, McCombe Waller S, Sorkin JD, Forrester LW, Macko RF, Hanley DF, et al. Bilateral and Unilateral Arm Training Improve Motor Function Through Differing Neuroplastic Mechanisms: A Single-Blinded Randomized Controlled Trial. *Neurorehabil Neural Repair*. 2011 Feb;25(2):118–29.
10. Phansopkar P, Athawale V, Birelliwari A, Naqvi W, Kamble S. Post-operative rehabilitation in a traumatic rare radial nerve palsy managed with tendon transfers: a case report. *Pan Afr Med J [Internet]*. 2020 Jun 30 [cited 2021 Oct 22];36(141). Available from: <https://www.panafrican-med-journal.com/content/article/36/141/full>
11. Rubinstein-Taybi syndrome: a rare case report of a female child emphasizing physiotherapy on gross motor function [Internet]. [cited 2021 Oct 22]. Available from: <https://www.panafrican-med-journal.com/content/article/40/85/full/>

Physical Rehabilitation, Susan B. O`Sullivan, Thomas J. Schmitz, George D. Fulk

Page No. 592,593

UNDER PEER REVIEW