



Adult Idiopathic Hypertrophic Pyloric Stenosis- A Diagnostic Challenge for Surgeons

K. Pranay^{a#}, R. Anantharamkrishnan^{a†}, K. Senthil Kumar^{a†}, P. Varadaraju^{a†}

^a Department of General Surgery, Chettinad hospital and research institute, Kelambakkam, Chengalpattu district, Tamil nadu-603103, India.

Case Report

ABSTRACT

Background and Objectives: AIHPS (adult idiopathic hypertrophic pyloric stenosis) is an uncommon but clear cut condition in adults, with only 200-300 case reports are recorded in the articles so far, now a case report of AIHPS treated in our hospital is discussed, as well as a review of the literature.

Methods and Results: The patient had upper abdominal discomfort that started suddenly and was accompanied by nausea, vomiting, and anorexia. The pylorus showed a distinct "cervix sign" during an esophagogastroduodenoscopy (EGD). He next had a partial distal gastrectomy with a Billroth II gastrojejunostomy, which resulted in significant alleviation in his symptoms.

Conclusion: Adult idiopathic hypertrophic pyloric stenosis (AIHPS) is an uncommon condition as it were underreported owing to diagnostic difficulties. After food nausea, vomiting, early satiety, and epigastric discomfort are the most prevalent symptoms of AIHPS, as shown in our case. Endoscopy impression reveals a distinct sign characterised by a fixed, constricted pylorus with a smooth border also known as cervix sign which is in diagnostic favour for AIHPS. Endoscopic dilatation, pyloromyotomy with forethought pyloroplasty, and gastrectomy with a Billroth II gastrojejunostomy have all been recommended as therapies for AIHPS. There is currently no proof that one surgical method is better than another. Before one approach can be established as the standard of care, more study on AIHPS is required.

Keywords: Idiopathic hypertrophic pyloric stenosis in adult (AIHPS); gastric-outlet obstruction.

1. INTRODUCTION

AIHPS (adult idiopathic hypertrophic pyloric stenosis) is an uncommon but clear cut condition in adults, within 200–300 instances recorded in the literature to date [1-4]. The pathological anatomy of AIHPS was originally reported in 1842, and in 1885, Maier et al. validated it as a distinct illness [5]. We provide a case to illustrate this condition that is challenging to diagnose but likely treatable [6].

A 65-year-old male came to the surgery department with the main grievance of abdominal pain since two months, he had symptoms of sudden onset, continuous upper stomach ache, sharp, burning, and stabbing type pain that has steadily intensified, is scored a 10/10 in pain intensity, is non-radiating. His symptoms were not related to food habits. Physical per abdomen examination unremarkable except for mild distention. CECT abdomen showed dilated stomach with antropyloric stricture (Fig. 2 and Fig. 3).

2. CASE REPORT

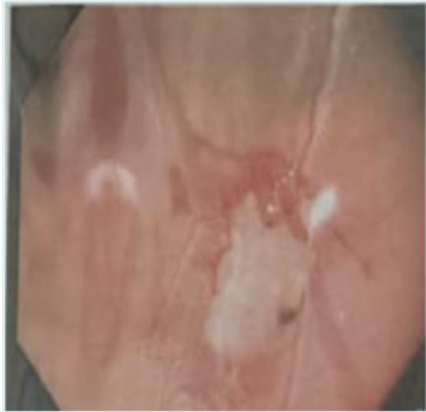


Fig. 1. Upper GI endoscopy: Narrowed pyloric antrum , Scope couldn't be passed beyond, Cervix sign visualized

On Esophagogastroduodenoscopy (EGD), antrum in the prepyloric region showed tight luminal narrowing and not able to pass the scope beyond (Fig. 1). Our major differential diagnoses at the time were AIHPS, acid peptic disease, cancer, and gastrointestinal stromal tumours (GISTs). Only the final pathology report may provide a conclusive diagnosis. Following consultation with gastroenterology more over patient's desire for a more permanent therapy for his underlying issue, a laparotomy was scheduled and performed. He subsequently had a truncal vagotomy and a partial distal gastrectomy with a Billroth 2 gastrojejunostomy (Fig. 4, Fig. 5). After surgery, HPE revealed (Fig. 6) hypertrophy of the circular muscles of the muscularis propria, as well as fibrosis, which was indicative with AIHPS, GISTs or cancer had been ruled out. The patient's recovery was sluggish and delayed after surgery, and he reported significant improvement in his symptoms at his 3-month follow-up appointment.

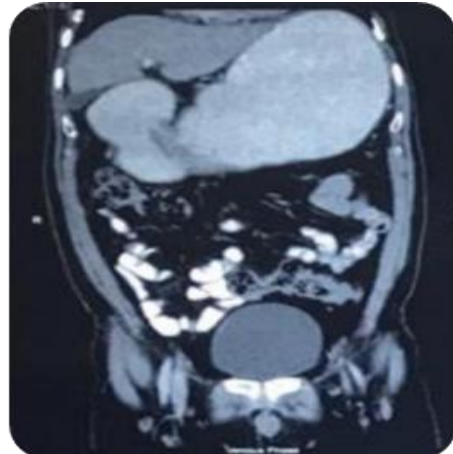


Fig. 2. CECT sagittal view thickening noted in Antro-pyloric region

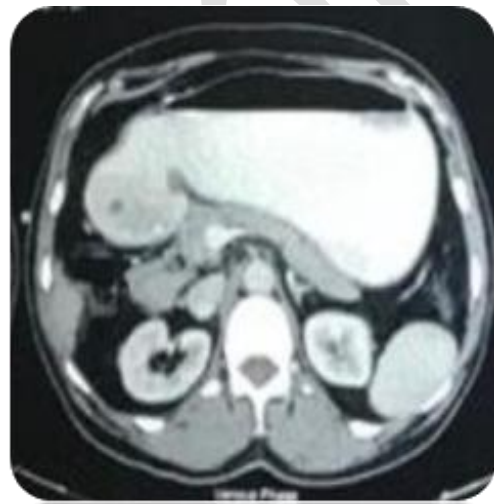

Fig. 3. CECT coronal view thickening noted in Antropyloric region with gastric stasis, Gastric Outlet Obstruction – Antropyloric Stricture

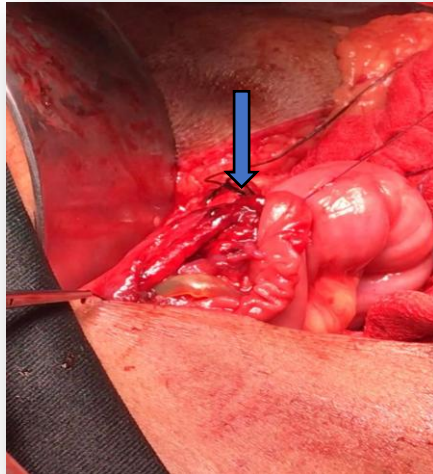


Fig. 4. BILLROTH – II Gastrojejunostomy

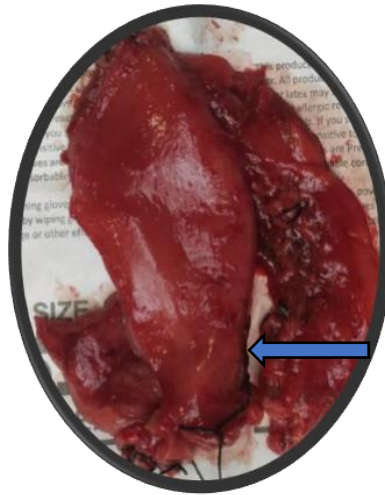


Fig. 5. Resected specimen pyloric thickening noted

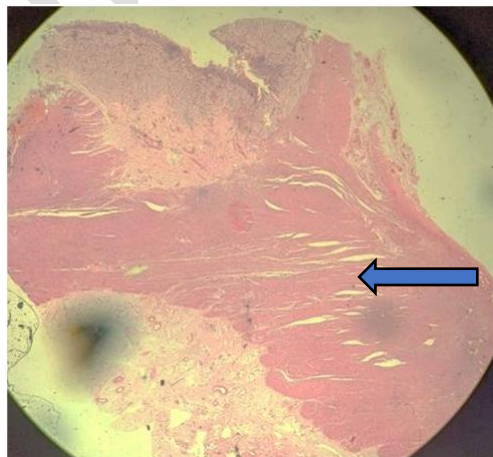

Fig. 6. H/P Examination: Muscularis propria shows hypertrophy and hyperplasia prominently in circular muscle layer

3. DISCUSSION AND CONCLUSION

Adult idiopathic hypertrophic pyloric stenosis (AIHPS) is an uncommon condition with a challenging diagnosis. Our patient, who had seen numerous doctors over the years before being diagnosed with AIHPS, exemplifies this difficulty in diagnosis. Middle-aged men are more likely to develop AIHPS, and our case was one of them [7,8].

Multiple researchers have characterised Hypertrophic Pyloric Stenosis (HPS) in different ways. Danikas et al. and Zarineh et al. have the most widely recognised categories. Danikas and colleagues classified HPS into various categories:

Type 1 is a infantile HPS; Type 2 is the most common kind, and it arises throughout adulthood and probably due to elemental GI diseases like acid peptic disease, cancer, and convulsed provocable illnesses; and Type 3 is prime adult-onset HPS [9].

Zarineh et al. classified HPS into two types: AIHPS is an example of a primary condition that has no underlying aetiology, Secondary pylorus hypertrophy is caused by an underlying condition such as excessive gastric or duodenal ulcer healing, cancer, GISTs, surgical intraabdominal adhesiveness, bezoars, and marked up vagal activity leading in pylorus hypertrophy. When compared to the primary kind of HPS, the secondary variety has little or minor pylorus muscle hypertrophy [10].

The specific cause of AIHPS is unknown, however genetic and environmental factors are likely to have a role. The majority of scientists believe it's because of the moderate juvenile form of HPS's persistence which latter present as adult form [11-13], which is supported by histological and anatomical variations abnormalities exhibited similarly in both adult and juvenile forms. However, the cause of the protracted asymptomatic phase till the age of 30–60 years remains unknown. In a susceptible person, oedema, spasm, or inflammation, according to some studies, causes pyloric blockage. Long-term pylorospasm, vagal hyperactivity, and Auerbach's plexus changes are all possible reasons [14].

After having food nausea, vomiting, early satiety, and epigastric discomfort are the most prevalent symptoms of AIHPS, as shown in our case. When related to the juvenile type of HPS, an abdominal lump is rarely felt [15].

Malignancy and diabetic gastroparesis are two conditions that might seem similar to AIHPS and are among the differential diagnoses. GISTs and AIHPS might be difficult to distinguish on pathology [10].

It's challenging to diagnose AIHPS on imaging since some instances have perfectly regular studies with no pathognomonic symptoms. The mushroom sign is the expansion of the pyloric muscle in the direction of duodenal cap on the upper GI series on barium examination, this sign is detected in 50% of juvenile HPS patients, however its incidence in AIHPS has not been determined.

Manual pressure on the stomach might also elicit the symptom. In certain circumstances, such as in our patient, an abdominal CT scan reveals comprehensive distal stomach wall thickening. It is, however, largely used to screen out secondary causes of HPS, such as cancer. The 'Cervix sign,' which is a stable, confined pylorus with a smooth border that endure even after anticholinergic treatment, is usually seen during endoscopy [16]. When pressure is administered through the endoscope, it can be distinguished from pylorospasm. Our patient had the cervical sign, which was the key factor that led us to diagnosis AIHPS. Based on a intensity of clinical uncertainty and with suggestive radiological findings and endoscopic evidence, the pathologist provides the actual diagnosis of AIHPS i.e. The pylorus is significantly enlarged and thickened on pathology. On microscopy, the stomach muscularis propria shows considerable hypertrophy and hyperplasia, but no inflammatory cells or cancer [17].

Endoscopic dilatation, pyloromyotomy, and partial distal gastrectomy with a Billroth II gastrojejunostomy have all been recommended as therapies for AIHPS. A less invasive procedure is laparoscopic pyloroplasty. Endoscopic dilation bear a high likelihood of reappearance and only provide a temporary symptom relief. It is a probable option for high-danger surgical patients. There is presently no information that only a single surgical procedure is superior to another. More research on AIHPS is needed ahead a procedure can be accepted as the basic of treatment [18-20].

CONSENT AND ETHICAL APPROVAL

As per university standard guideline, participant consent and ethical approval have been collected and preserved by the authors

COMPETING INTERESTS

Authors have declared that no competing interests exist.

REFERENCES

1. Taliaferro L, Barnett DA, Mann NS. Adult hypertrophic pyloric stenosis: case report. *Tex Med.* 1986;82:27–28. [PubMed] [Google Scholar]
2. Thielemann H, Anders S, Naveke R, Diermann J. Primary hypertrophic pyloric stenosis. An uncommon condition of pyloric stenosis in adults. *ZentralblChir.* 1999;124(10):947–949. [PubMed] [Google Scholar]
3. Simson JN, Thomas AJ, Stoker TA. Adult hypertrophic pyloric stenosis and gastric carcinoma. *Br J Surg.* 1986;73:379–380. [PubMed] [Google Scholar]
4. Christiansen KH, Grantham A. Idiopathic hypertrophic pyloric stenosis in the adult: a review of the literature and the report of two cases. *Arch Surg.* 1962;85:207–214. [PubMed] [Google Scholar]
5. Cruveilhier J. Anatomiepathologique du corps humain, ou descriptions, avec figures lithographiées et coloriées, des diverses altérations morbides dont le corps humain est susceptible. Chez J B Baillière. 1835. [Google Scholar]
6. Keynes - Gut WM. Simple and complicated hypertrophic pyloric stenosis in the adult. *ncbi.nlm.nih.gov* [Internet]. 1965. Available: <https://www.ncbi.nlm.nih.gov/pmc/articles/pmc1552288/>. [PMC free article] [PubMed]
7. Knight CD. Hypertrophic pyloric stenosis in the adult. *Ann Surg.* 1961;153: 899–910. [PMC free article] [PubMed] [Google Scholar]
8. Craver-Gastroenterology WL. Hypertrophic pyloric stenosis in adults. *europemc.org* [Internet];1957. Available: <http://europemc.org/abstract/med/13490683>. [PubMed]
9. [9] Danikas D, Geis WP, Ginalis EM, et al. Laparoscopic pyloroplasty in idiopathic hypertrophic pyloric stenosis in an adult. *JSLs.* 2000;4:173–175. [PMC free article] [PubMed] [Google Scholar]
10. Zarineh A, Leon ME, Saad RS, et al. Idiopathic hypertrophic pyloric stenosis in an adult, a potential mimic of gastric carcinoma. *Patholog Res Int.* 2010; 6:14280. [PMC free article] [PubMed] [Google Scholar]
11. Dye TE, Vidals VG, Lockhart CE, et al. Adult hypertrophic pyloric stenosis. *Am Surg.* 1979;45:478–484. [PubMed] [Google Scholar]
12. Takano S, Murakami A, Harada K, et al. Journal of primary hypertrophic pyloric stenosis in the adult. Wiley Online Library [Internet]. 1992. Available: <http://onlinelibrary.wiley.com/doi/DOI:10.1111/j.1440-1746.1992.tb01032.x/full>.
13. Lin HP, Lin YC, Kuo CY. Adult idiopathic hypertrophic pyloric stenosis. *J Formos Med Assoc.* 2015;114:659–662. [PubMed] [Google Scholar]
14. Belding HH 3rd, Kernohan JW. A morphologic study of the myenteric plexus and musculature of the pylorus with special reference to the changes in hypertrophic pyloric stenosis. *SurgGynecol Obstet.* 1953;97:322–334. [PubMed] [Google Scholar]
15. Hsien-Ping L, Yu-Chiang L, Chen-Yun K. Adult idiopathic hypertrophic pyloric stenosis. *J Formos Med Assoc.* 2015;114:659–662. [PubMed] [Google Scholar]
16. Bateson EM, Talerma A, Walrond ER. Radiological and pathological observations in a series of seventeen cases of hypertrophic pyloric stenosis of adults. *BJR Suppl.* 1969;42:1–8. [PubMed] [Google Scholar]
17. [17] *Pediatric Radiology* [Internet]. [cited 2017 October 31]. Available: https://www.med-ed.virginia.edu/courses/rad/peds/abd_webpages/abdominal15b.html.
18. Hernanz-Schulman M. Infantile hypertrophic pyloric stenosis. *Radiology.* 2003;227:319–331. [PubMed] [Google Scholar]
19. Currarino G. The value of double-contrast examination of the stomach with pressure “spots” in the diagnosis of infantile hypertrophic pyloric stenosis. *Radiology.* 1964;83:873–878. [PubMed] [Google Scholar]
20. MacDonald JA. Adult hypertrophic pyloric stenosis. *Br J Surg.* 1973;60:73–75. [PubMed] [Google Scholar]
21. Subramanian V, Rao GB, Thanka J. The Histopathological Study of Gastrointestinal Polyps. *Journal of Pharmaceutical*

© 2021 Pranay et al.; This is an Open Access article distributed under the terms of the Creative Commons Attribution License (<http://creativecommons.org/licenses/by/4.0>), which permits unrestricted use, distribution, and reproduction in any medium, provided the original work is properly cited.

Galley Proof