

SCROTAL ULCER IS A RARE PRESENTATION OF TB EPIDIDYMYIS IN YOUNG MALE

Abstract:

Introduction: Scrotal tuberculosis (TB) is rare and may present as painful scrotal swelling with ulceration and discharging sinus. **Case Report:** A 28 years male with 2 months history of swelling and pain over left scrotum. Developed ulcer over the scrotal region with multiple sinus associated with pus discharge. **Conclusion:** The clinical presentation of TB scrotal ulcer can be atypical and a high index of suspicion is required for early diagnosis. Diagnosis is by using ultrasonography, microbiology, and biopsy. Treatment requires prolonged ATT for 6 months.

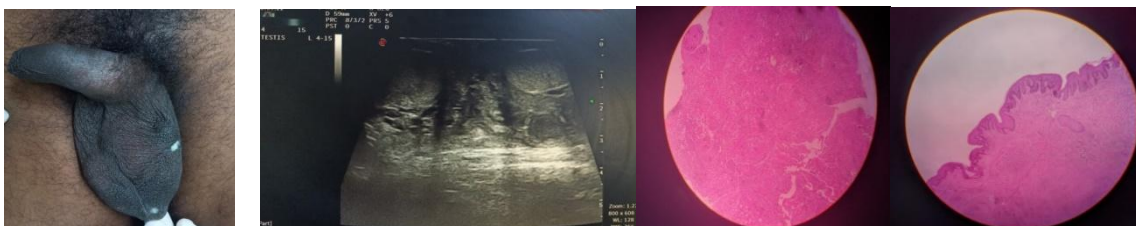
Keywords: Tuberculosis; scrotal swelling; biopsy.

INTRODUCTION:

Pulmonary tuberculosis (TB) is the most common form of TB disease. Extra-pulmonary TB (EP-TB) is seen only in 10–15% cases and lymph nodes are the most common site for EP-TB in India. Genital TB is uncommon, and testicular TB is further rare, comprising only 3% of genital TB.[1] Commonly, it occurs during disseminated TB, but isolated testicular TB is extremely rare. In most cases, it clinically mimics other testicular lesions, such as testicular tumor, infarction, or even testicular torsion. Middle-aged males, especially of 20–40 years of age are most commonly affected, and presented with painful or painless scrotal swelling with or without discharging sinus. Infertility may occur. In elderly age group, diagnostic dilemma develops between testicular malignancy and testicular TB, as the first one is more common than the latter. Testicular biopsy is needed, especially in the elderly age group as exclusion of testicular malignancy, in this age group is main concern. Anti-TB chemotherapy comprising rifampicin, isoniazid, pyrazinamide, and ethambutol is the mainstay of treatment. Here, we report a rare case we report a very rare case of left sided TB epididymis with scrotal ulcer in a 28-year-old male patient after getting the written informed consent from him.

CASE REPORT:

A 28 years male came to opd with two months history of swelling over left scrotum which was insidious in onset. It was associated with pain. Patient developed ulcer over the scrotal region with multiple openings and associated with pus discharge [fig 1]. Known case of TB in childhood [did not complete full treatment]. On local examination wound left scrotal region, multiple sinus found in left hemiscrotal region. Pus discharge present from one sinus, induration present. Laboratory tests revealed no abnormalities. USG scrotum impression LEFT CHRONIC EPIDIDYMO-ORCHITIS, TO R/O GRANULOMATOUS INFECTION [fig 2]. Patient planned for excision and biopsy. Intra op sinus tract identified and excised all around and removed and sent for HPE. Pus discharge noted from another induration and specimen sent for GENE EXPERT. Intra and post-operative period uneventful [fig 3]. GRAM STAIN showed occasional pus cells. GRAM POSITIVE COCCI in pairs seen. HPE showed GRANULOMATOUS LESION-TUBERCULOSIS [fig 4]. GENE EXPERT showed M-TB presence. X-ray showed B/L reticulo nodular shadow suggestive of military TB, RIGHT upper lobe non homogenous opacity present [fig 5]. Pulmo review obtained and advice rifampicin, isoniazid, pyrazinamide, and ethambutol for the first 2 months, followed by rifampicin, and isoniazid for next 4 months.



DISCUSSION:

TB is a leading cause of death worldwide, especially in the developing countries which are TB endemic zone, like India. Emergence of drug resistance TB and rapid increase in incidence of HIV infection makes the world's scenario further critical. Genitourinary TB is an unusual presentation of TB and comprises 8–15% of EP-TB.[2] Isolated genital involvement is seen in 28% patients of genitourinary TB.[3] It is more common in males. The most common site of genital TB is the epididymis in men, followed by the seminal vesicles, prostate, testis, and the vas deferens.[4]

Mechanism of dissemination of tubercle bacilli into the scrotal sac structures is controversial. It is believed that, in most cases, TB epididymo-orchitis is developed from retrograde spread of tubercle bacilli from the affected urinary tract into the prostate via reflux, followed by canalicular spread to the seminal vesicle, deferent duct, and epididymis.[5,6] However, TB bacilli may also gain entry via the hematogenous and lymphatic spread. In most cases, testicular involvement is due to local spread or retrograde seeding from the epididymis, and rarely by hematogenous spread.[5,6] Hence, TB epididymal involvement is extremely uncommon, which we present in this case report.

TB epididymis commonly occurs with TB involvement of lower urinary tract, even of kidneys. Hence, it presents with lower urinary tract symptoms, especially irritative voiding symptoms and hematuria. Epididymo-orchitis, prostatitis, scrotal swelling with or without discharging sinus are other manifestations. reported cases of TB epididymis presenting with scrotal ulceration.[7,8] In our case, initial presentation was only the left sided hard, painful testicular swelling with discharging sinus.

USG of testis is very useful investigation in the diagnosis of TB epididymis. TB involvement of the epididymis and testis may be classified into four types depending on the USG finding: (1) Diffusely enlarged, heterogeneously hypoechoic; (2) diffusely enlarged, homogeneously hypoechoic; (3) nodular enlargement, heterogeneously hypoechoic; and (4) miliary.[9] Seminoma and lymphoma are mostly homogenous while nonseminomatous tumors tend to be heterogeneous.[10] Color Doppler USG is useful to differentiate testicular TB from testicular torsion, as blood flow within the testis is reduced or absent, whereas it is increased in subjects with inflamed testis.[11] Finding of the epithelioid granulomas and AFB on Ziehl-Neelsen staining in the USG-guided FNAC materials obtained from the testicular swelling confirms the diagnosis of TB orchitis. However, the presence of AFB is again extremely uncommon, especially in an isolated TB epididymis in an immunocompetent male, which we report in our case. On the other hand, excision and biopsy TB epididymis with scrotal ulcer, as it is possible to confirm the diagnosis of TB epididymis.

Six-month regimen of anti-TB chemotherapy comprising of rifampicin, isoniazid, pyrazinamide, and ethambutol for the first 2 months, followed by rifampicin, and isoniazid for next 4 months is very much effective to ensure the complete resolution of the TB lesion of the testis. Sometimes, surgery may be required.[2]

CONCLUSION

The clinical presentation of TB scrotal ulcer can be atypical and a high index of suspicion is required for early diagnosis. Diagnosis is by using ultrasonography, microbiology, and biopsy. treatment requires prolonged rifampicin, isoniazid, pyrazinamide, and ethambutol for the first 2 months, followed by rifampicin, and isoniazid for next 4 months. Follow up for 1 year is advised.

Disclaimer regarding Consent and Ethical Approval:

As per university standard guideline, participant consent and ethical approval have been collected and preserved by the authors

REFERENCES

1. Viveiros F, Tente D, Espiridião P, Carvalho A, Duarte R. Testicular tuberculosis: Case report. *Rev Port Pneumol*. 2009;15:1193–7. [[PubMed](#)] [[Google Scholar](#)]
2. Hadadi A, Pourmand G, Mehdipour-Aghabagher B. Unilateral testicular tuberculosis: Case report. *Andrologia*. 2012;44:70–2. [[PubMed](#)] [[Google Scholar](#)]
3. Shah H, Shah K, Dixit R, Shah KV. Isolated tuberculous epididymo-orchitis. *Indian J Tuberc*. 2004;51:159–62. [[Google Scholar](#)]
4. Gurubacharya RL, Gurubacharya SM. A 14-year-old boy with isolated tuberculous orchitis. *J Nepal Paediatr Soc*. 2009;29:30–2. [[Google Scholar](#)]
5. Wise GJ, Shteynshlyuger A. An update on lower urinary tract tuberculosis. *CurrUrol Rep*. 2008;9:305–13. [[PubMed](#)] [[Google Scholar](#)]
6. Viswaroop BS, Kekre N, Gopalakrishnan G. Isolated tuberculous epididymitis: A review of forty cases. *J Postgrad Med*. 2005;51:109–11. [[PubMed](#)] [[Google Scholar](#)]
7. Garbyal RS, Sunil K. Diagnosis of isolated tuberculous orchitis by fine-needle aspiration cytology. *Diagn Cytopathol*. 2006;34:698–700. [[PubMed](#)] [[Google Scholar](#)]
8. Shugaba AI, Rabiou AM, Uzokwe C, Matthew RM. Tuberculosis of the testis: A case report. *Clin Med Insights Case Rep*. 2012;5:169–72. [[PMC free article](#)] [[PubMed](#)] [[Google Scholar](#)]
9. Muttarak M, Peh WC, Lojanapiwat B, Chaiwun B. Tuberculous epididymitis and epididymo-orchitis: Sonographic appearances. *AJR Am J Roentgenol*. 2001;176:1459–66. [[PubMed](#)] [[Google Scholar](#)]
10. Muttarak M, Peh WC. Case 91: Tuberculous Epididymo-orchitis. *Radiology*. 2006;238:748–51. [[PubMed](#)] [[Google Scholar](#)]
11. Pavlica P, Barozzi L. Imaging of the acute scrotum. *Eur Radiol*. 2001;11:220–8. [[PubMed](#)] [[Google Scholar](#)]