

ROLE OF SURGICAL INTERVENTION IN HEREDITARY SPHEROCYTOSIS WITH HAEMOLYTIC ANAEMIA, SPLENOMEGALY AND JAUNDICE

Abstract

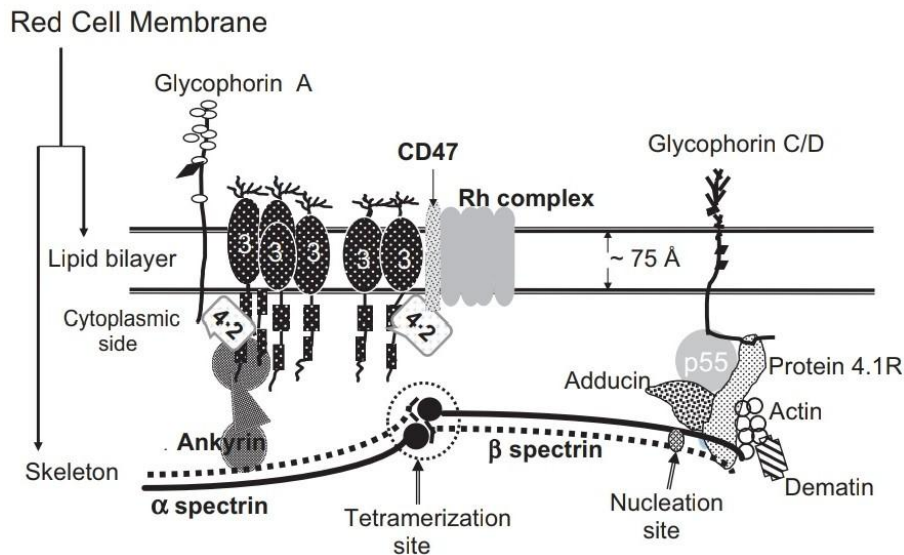
This case series includes surgical management in 3 cases of Hereditary spherocytosis presenting with haemolytic anaemia, splenomegaly and jaundice, admitted in Chettinad hospital and research institute during one year period from January 2019 to January 2020. Surgical intervention is indicated for selected patients with hereditary spherocytosis with haemolytic anaemia and jaundice to **abate the hemolytic process** after correction of anaemia with blood transfusion. Pigmented gallstones are seen in more than 50% cases for which incidence increases with severity of hemolysis and with age. Complications include aplastic anemia (most common after parvovirus B19 infection), haemolytic crisis during inter-current infection, megaloblastic crisis – during folic acid deficiency, cardiomyopathy, hematological malignancies.

Keywords: surgical management, hematological malignancies, hemolysis, spherocytosis

INTRODUCTION:

Hereditary spherocytosis (HS) is a rare type of congenital haemolytic anaemia that occurs world wide. The estimated prevalence in Caucasian population ranges from 1:2000 to 1:5000 [1]. Hereditary spherocytosis was described initially in 1871 [2] HS affects males and females equally. Age at diagnosis of HS is often between 3 – 7 years but can occur in infancy with severe disease or into adulthood with mild disease. In 80% instances, the inheritance of HS is autosomal dominant and in others autosomal recessive. [3] The molecular defect involves the genes encoding for spectrin, ankyrin, band 3, and protein 4.2 that link the bilayer of red cells to the membrane skeleton. Loss of this protein causes red blood cells to lack their characteristic biconcave shape.

FIG. NO. 01 SCHEMATIC REPRESENTATION OF THE STRUCTURAL ORGANIZATION OF THE RED CELL CYTOSKELETON: (ADAPTED FROM GUYTON AND HALL – TEXTBOOK OF MEDICAL PHYSIOLOGY, 13TH EDITION)



These proteins are more susceptible to trapping and destruction by the spleen resulting in haemolysis, splenomegaly and cholelithiasis. The passage of these RBCs into sinusoids is difficult and gets phagocytosed resulting in extravascular haemolysis. Splenomegaly is mild to moderate; but the size of spleen is not an indication for splenectomy. Direct / indirect bilirubin accumulates in gall bladder to form gallstones, altering liver function and causing hepatomegaly. Pigmented gallstones are seen in more than 50% cases for which incidence increases with

severity of hemolysis and with age. Complications include aplastic anemia (most common after parvovirus B19 infection), haemolytic crisis during inter-current infection, megaloblastic crisis – during folic acid deficiency, cardiomyopathy, hematological malignancies.

MATERIALS AND METHODS:

This case series includes surgical management in 3 cases of hereditary spherocytosis presenting with haemolytic anaemia, splenomegaly and jaundice, admitted in Chettinad hospital and research institute during one year period from January 2019 to January 2020, treated by

- Elective splenectomy with concomitant cholecystectomy in two patients (56-year male with obstructive jaundice post-ERCP status, and 30-year old female with cholelithiasis) and
- Only splenectomy in one patient (10-year-old boy with no features of gallstone disease).
- All three patients had Grade III splenomegaly (Hackett’s grading score) and diagnosed with hereditary spherocytosis according to hematological criteria.

FIG.NO.2: CLASSIFICATION OF HS AND INDICATIONS OF SPLENECTOMY

Classification	Trait	Mild	Moderate	Severe
Haemoglobin (g/dl)	Normal	11-15	8-12	6-8
Reticulocyte count %	Normal (<3%)	3-6	>6	>10
Bilirubin (µmol/l)	<17	17-34	>34	>51
Spectrin* per erythrocyte (% of normal)	100	80-100	50-80	40-60
Splenectomy	Not required	Usually not necessary during childhood	Necessary during school age before puberty	Necessary - delay until 6 years if possible

CASE SERIES :

This case series includes surgical management in 3 cases of Hereditary spherocytosis presenting with haemolytic anaemia, splenomegaly and jaundice, admitted in Chettinad hospital and research institute during one year period from January 2019 to January 2020, treated by Elective splenectomy with concomitant cholecystectomy in two patients (56-year male with obstructive jaundice post-ERCP status, and 30-year old female with cholelithiasis) and Only splenectomy in one patient (10-year-old boy with no features of gallstone disease). All three patients had Grade III splenomegaly (Hackett's grading score) and diagnosed with hereditary spherocytosis according to hematological criteria. Clinical features range from asymptomatic condition to fulminant haemolytic crisis. Anaemia – fatigue, pallor, Splenomegaly, Jaundice, icterus, Fever. Other findings : Hepatomegaly, growth failure, allergic diseases, Transfusion dependency and Extra-medullary haematopoiesis. Diagnosis was by Laboratory diagnosis mainly involving peripheral blood smear – abnormally small and lack central pallor, Howell-Jolly bodies may be seen, MCHC & reticulocyte count. The presence of spherocytes is confirmed by an Osmotic Fragility Test (Sensitivity - 48 to 95%) ; Acidified Glycerol Lysis Test (Sensitivity – 99%) and a Negative Coombs test. USG Abdomen to quantify size of spleen, to rule out cholelithiasis. Preoperative preparation of the patients included correction of anaemia with blood transfusion, cardiac status evaluation, and prophylactic administration of vaccines to prevent OPSI – Polyvalent Pneumococcal vaccine (PPV23), H. influenzae type b conjugate, and meningococcal polysaccharide vaccine.

TABLE.NO.1: VACCINE RECOMMENDATIONS FOR ASPLENIC PATIENTS (ADAPTED FROM: PARK'S TEXTBOOK OF SOCIAL AND PREVENTIVE MEDICINE, 23RD EDITION)

VACCINE	RECOMMENDATION
Tetanus (Td/Tdap)	One dose every 10 years
Human papilloma virus (HPV)	Three doses for women through age 26 (0, 2, 6 mo)
Measles, mumps, rubella (MMR)	One or two doses
Varicella	Two doses (0, 4-8 wk)
Zoster	One dose
Influenza	One dose annually
Pneumococcal polysaccharide	One or two doses
Hepatitis A	Two doses (0, 6-12 mo or 0, 6-18 mo)
Hepatitis B	Three doses (0, 1-2 mo, 4-6 mo)
Meningococcal	One dose

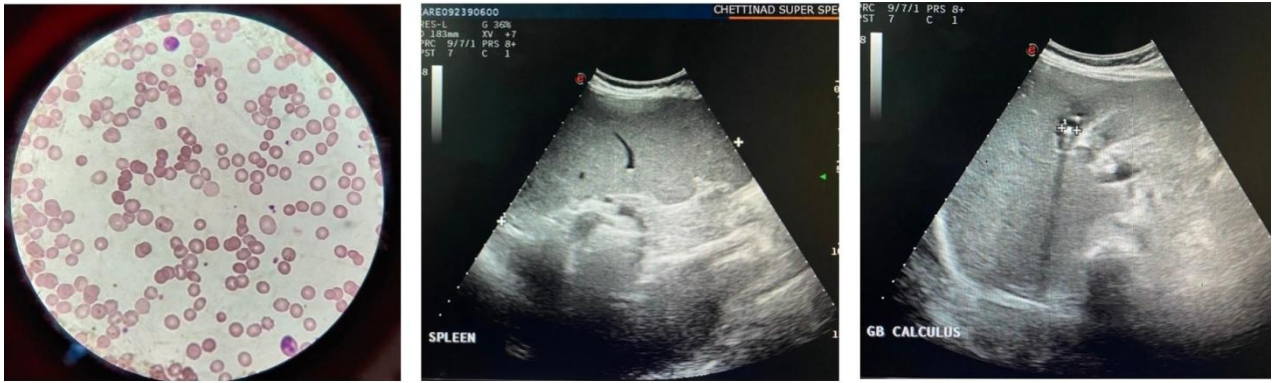

FIG.NO.3:PREOPERATIVEWORKUP.

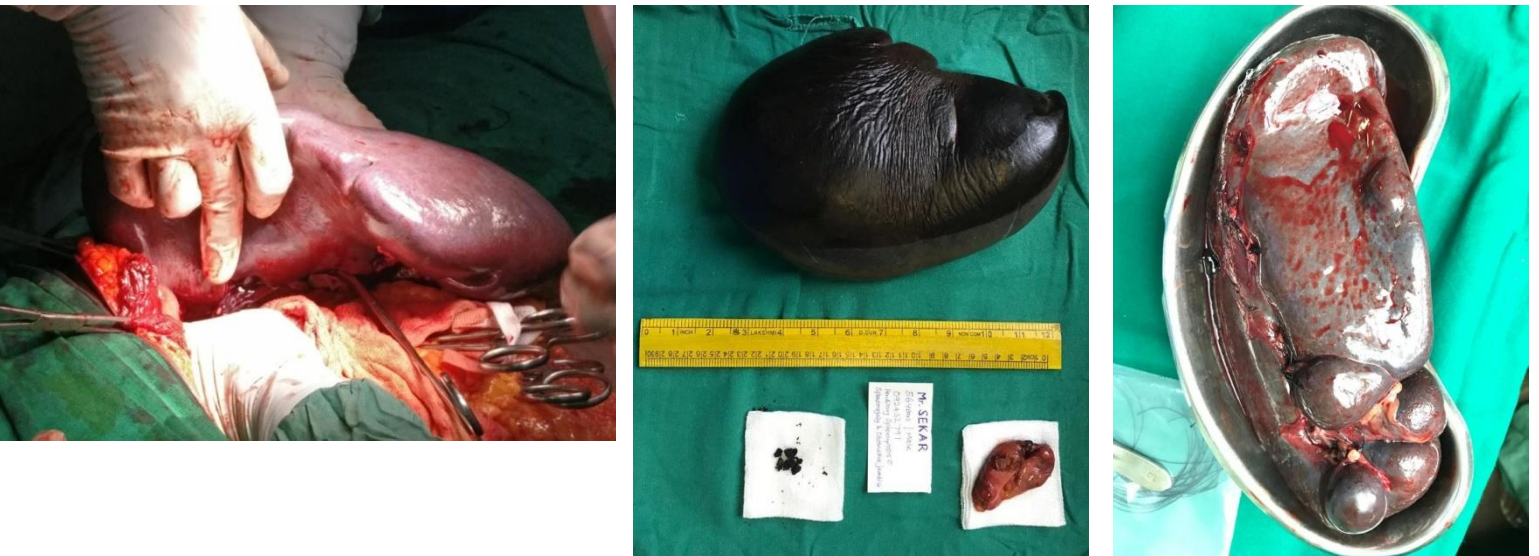

FIG.NO.4:INTRA-OPERATIVEIMAGES.

Proceeded with Elective splenectomy with cholecystectomy. Left subcostal (1)/upper midline incision (2). Entry into abdominal cavity à blunt and sharp dissection along convex surface of organ. Avascular peritoneal attachments and ligaments incised (Splenophrenic, splenocolic and splenorenal). Identify hilum à Splenic Artery and Vein double ligated and transfixed close to spleen. Short gastric vessels ligated and divided. Blunt dissection of posterior attachments. Hemostasis checked : Left subphrenic area, Greater curvature of stomach, Splenic hilum, Tail of pancreas. Look for accessory spleen : Hilum, Gastrocolic, gastrosplenic ligament, Greater omentum, Mesenteric region, presacral space. Drain may/may not be kept. +/- Cholecystectomy.

Intraoperative periods were uneventful. Postoperative febrile episodes required escalation of antibiotics. Normal hematocrit values were achieved 4 weeks postoperatively in all patients. There was no evidence of postoperative abdominal or wound infections, and no post-splenectomy sepsis.

DISCUSSION:

Hereditary spherocytosis (HS) is a disease affecting the red blood cell membrane and belongs to the congenital hemolytic anemias. The clinical spectrum ranges from asymptomatic patients to severe forms requiring transfusions in early childhood. The diagnosis can be based on the physical examination, complete red blood cell count, reticulocyte count, medical history and specific tests, preferentially the EMA test (eosin-5-maleimide binding) test and AGLT (Acidified Glycerol Lysis Time). Splenectomy is considered the standard surgical treatment in moderate and severe forms of hereditary spherocytosis.

Total splenectomy exposes the patient to a life-long risk of potentially lethal infections and thus, its usage was reconsidered. Because of this reason, a feasible alternative is the partial splenectomy. The use of partial splenectomy aims to retain splenic immunologic function, while at the same time to decrease the rate of hemolysis. The long-term outcomes of patients with total or subtotal splenectomy for congenital hemolytic anemia, still remain unclear, but the majority of the studies showed a qualitative resolution of anemia and reduction of transfusion rate. Thus, surgical intervention is indicated for selected patients with hereditary spherocytosis with haemolytic anaemia and jaundice to abate the haemolytic process after correction of anaemia with blood transfusion.

Cholecystectomy is indicated in patients with pigment gallstones. Splenectomy is very effective in reducing haemolysis, leading to a significant prolongation of the red cell lifespan and should be performed in patients with severe HS, considered in those who have moderate disease, and should probably not be performed in those with mild disease. If splenectomy is done in a patient with symptomatic gallstones, cholecystectomy should be done concomitantly. [5]

CONCLUSION:

To conclude, in patients with Hereditary Spherocytosis (Moderate-Severe) presenting with splenomegaly and jaundice, splenectomy with or without cholecystectomy can be performed with minimal morbidity, to relieve symptoms due to hemolysis and to prevent further episodes of jaundice.

Disclaimer regarding Consent and Ethical Approval:

As per university standard guideline, participant consent and ethical approval have been collected and preserved by the authors

REFERENCES:

- [1] Mariani M, Barcellini W, Vercellati C, Marcello AP, Fermo E, Pedotti P, et al. Clinical and hematologic features of 300 patients affected by hereditary spherocytosis grouped according to the type of the membrane protein defect. *Haematologica* 2008;93:1310-7.
- [2] Shafiqat S, Roger V. Hereditary Spherocytosis. *Paediatr Rev* 2004;25:168-72.
- [3] Das MR, Ananthakrishnan S. Hereditary spherocytosis in a family from Tamil Nadu. *Indian Pediatr* 2005;42:610-1.
- [4] Sabiston textbook of surgery, Volume II, First South Asia Edition, Page 1568.

[5] Bolton Maggs PH, Langer JC, Iolascon A, Titterton P, King MJ. Guidelines for the diagnosis and management of hereditary spherocytosis-2011 update. *Br J Haematol* 2012;156:37-49.