

## A RARE CASE OF SALMONELLA TYPHI PRESENTING WITH TONSILLITIS

### Abstract:

Typhoid fever is an endemic infection in developing countries like India. Oral manifestations of enteric fever and typhoid tonsillitis have rarely been reported in the literature. We report a 20 year old male, showing tonsillitis to be an integral part of clinical presentation of typhoid fever. The patient presented with fever, throat pain and oral ulcers. Blood culture and swab from tonsils showed significant growth of Salmonella typhi. This case report adds light to tonsillitis as a rare clinical manifestation of typhoid fever.

**Keywords:** Typhoid, Tonsillitis, Oral ulcers

### INTRODUCTION

Typhoid fever is caused by Salmonella typhi and paratyphi. The incubation period for S. Typhi ranges from 5 to 21 days. The most prominent symptom of enteric fever is prolonged high fever, which can continue for up to 4 weeks if left untreated. Other clinical manifestations include headache, chills, cough, sweating, myalgias, malaise, and arthralgia. Gastrointestinal manifestations include anorexia, abdominal pain, nausea, vomiting, and diarrhea more commonly than constipation. Physical findings include coated tongue, splenomegaly, and abdominal tenderness. Other findings on examination include rose spots, hepatomegaly, epistaxis, and relative bradycardia at the peak of high fever. Gastrointestinal bleeding and intestinal perforation are very rare nowadays and commonly occur in the third and fourth weeks of illness. Blood culture is the specific laboratory test for diagnosing enteric fever. Empirical treatment include ceftriaxone 2gms IV for 10-14 days or oral azithromycin 1gm/day for 5 days<sup>1</sup>. Unusual manifestations of typhoid fever, including respiratory symptoms, epistaxis, and intestinal bleeding are sometimes encountered. The purpose of this particular case is to shed light on tonsillitis being a rare presentation of typhoid fever<sup>2</sup>.

### CASE REPORT

A 20 year old unmarried male came to medicine department with complains of fever for past 3 days, high grade with throat pain, headache, chills, cough myalgia, sweating, and multiple painful oral ulcers for 2 days. He also noticed painful swallowing associated with hoarseness of voice. There were no history of vomiting, loose stools, constipation or abdominal pain. He had an occupation related recent travel to Varanasi. There was no history of any co morbidities and unprotected sexual practice. He neither used illicit drugs nor consumed alcohol.

On examination, patient was conscious, oriented, febrile and toxic. He had signs of dehydration in the form of dry tongue and reduced skin turgor. His pulse rate was 100/min, blood pressure was 100/80 mmHg, temperature was 102.4° F and saturation was 99% in room air.

Examination of oral cavity showed coated tongue (fig.1). The oral and pharyngeal mucosa were congested. Multiple vesicles with ulcers were present with an erythematous base over the tongue and palate (fig.2 and 3). Both the tonsils were enlarged with white patches and ulcers noted over the surface (fig.1). The patch could not be removed. He had enlarged and tender submandibular lymph nodes bilaterally. Systemic examinations were found to be normal.

Blood investigations revealed normal leucocyte count with differentials and raised inflammatory markers. Other baseline investigations like RFT, LFT, RBS, serum electrolytes and urine routine were found to be within normal limits. Chest x-ray and ECHO were normal. Viral serology for HIV 1 AND 2, HBsAg, and HCV were negative. HSV 1 IgM antibody titer was negative on 7<sup>th</sup> day. CD4 count was 1185 cells/μl. Empirical antibiotic treatment was started for acute tonsillitis along with IV fluids and other supportive measures. There was no clinical improvement even after 5 days of appropriate treatment for tonsillitis.

Meanwhile, blood culture and swab from tonsils showed significant growth of salmonella typhi. So, the diagnosis of typhoid fever with tonsillitis was made. He was started on injection ceftriaxone. After 3 doses of ceftriaxone, there was gradual improvement in fever and the oral lesions began to subside. By the 8th day, the patient's tonsils had decreased in size and were less hyperemic. He had finished 2 weeks course of antibiotics. Follow-up at two weeks and three months after discharge showed no evidence of recurrence of fever, tonsillitis or oral ulcers.

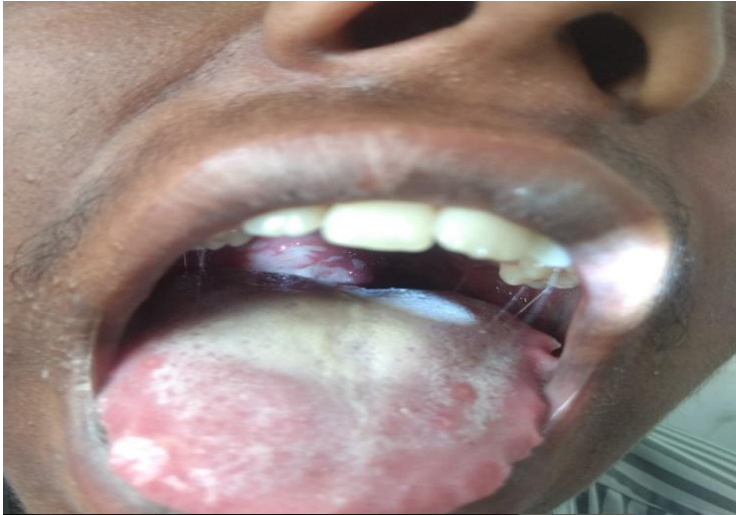

Fig-1 shows coated tongue and tonsillar enlargement with white patch over the tonsil

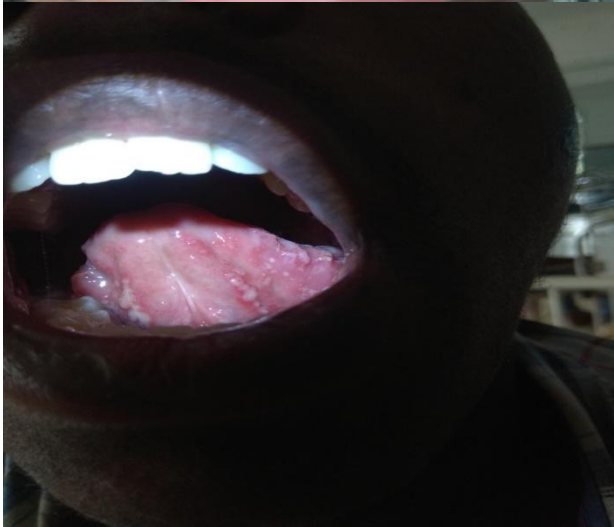

Fig-2 shows multiple ulcers over the tongue

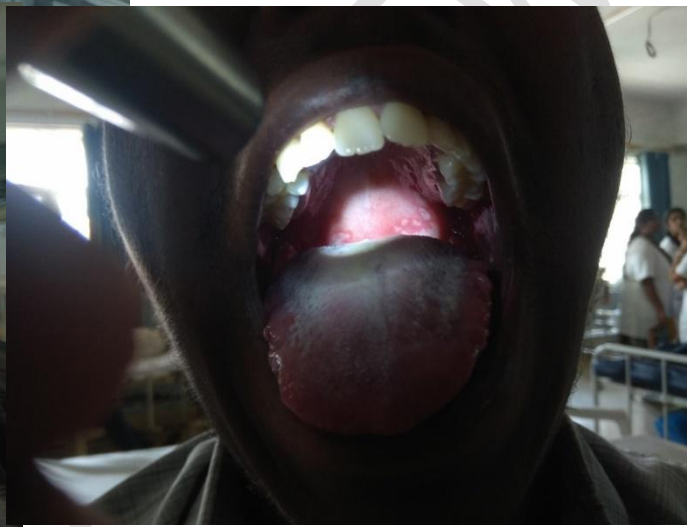


Fig-3 shows multiple ulcers over the hard palate

## DISCUSSION

In this case report, we present a young male with history of recent travel to an endemic area for enteric fever with consumption of street food and unpackaged water. After returning from his trip, patient started to have high grade fever with painful oral ulcers and enlarged tonsils.

An initial clinical diagnosis of acute pharyngotonsillitis was made and was treated on empirical antibiotic without much improvement. Common causes for this condition were ruled out like herpes simplex, Infectious mononucleosis, herpangina and diphtheria. He was tested negative for HIV and CD4 count was normal. As blood culture and throat swab showed growth of salmonella typhi, injection ceftriaxone was started following which the patient showed drastic improvement.

Oral ulcers with tonsillitis are uncommon clinical manifestations of typhoid fever. The mechanism of oral ulcers and tonsillitis are not known completely. As the portal of entry for typhoid organism is through the GI tract, involvement of oral mucosa and tonsils can partly be explained. As like the organisms lodge and multiply in the lymphatic follicles within the Peyer's patches, they may also invade and multiply within the tonsils resulting in their enlargement<sup>2</sup>.

The same strain of bacteria cultured from the patient's tonsils and oropharynx with marked clinical response to cephalosporin aided in the diagnosis of typhoid causing tonsillitis. Perhaps due to earlier and more effective treatment, tonsillitis in typhoid is often rarely seen in today's scenario.

## CONCLUSION

Tonsillitis is an uncommon clinical manifestation of typhoid fever. As these manifestations are rarely encountered, this produces a great diagnostic dilemma to the treating physician. Clinicians should also rule

out typhoid fever, whenever they encounter a case of acute tonsillitis that poorly responds to conventional treatment. Apart from throat swab, blood culture should also be planned in them.

**Disclaimer regarding Consent and Ethical Approval:**

As per university standard guideline, participant consent and ethical approval have been collected and preserved by the authors

**COMPETING INTERESTS DISCLAIMER:**

Authors have declared that no competing interests exist. The products used for this research are commonly and predominantly use products in our area of research and country. There is absolutely no conflict of interest between the authors and producers of the products because we do not intend to use these products as an avenue for any litigation but for the advancement of knowledge. Also, the research was not funded by the producing company rather it was funded by personal efforts of the authors.

**REFERENCES**

1. Longo D, Fauci A, Kasper D, Hauser S, Jameson L, Loscalzo J. *Harrison's Principles of Internal Medicine, 20e*. New York, NY: McGraw-Hill; 2018; 1173-1177
2. Johnson PC, Sabbaj J. Typhoid Tonsillitis. *JAMA*. 1980;244(4):362.