

## Case report on: Appendicitis

### Abstract

**Introduction:** Acute appendicitis (AA) is the most common surgical infection, with a 7–8% lifetime risk. The mortality rate following appendectomy is quite low, ranging from 0.07 to 0.7 percent in patients without perforation to 0.5 to 2.4 percent in patients with perforation, which is an acute inflammation of the appendix. It affects people of all ages, with the majority of cases occurring between the ages of 10 and 30, and both boys and females are afflicted equally. Appendicitis is substantially less common in developing nations, particularly regions of Africa, and among lower socioeconomic levels. After being diagnosed with appendicitis, a 24-year-old male was taken to AVBRH with complaints of pain in the right iliac fossa, nausea, and vomiting. The findings of the examination were consistent with acute appendicitis. His systemic health remained unaffected, and testing such as blood tests, urine samples, and abdominal ultrasounds were inconclusive. Acute appendicitis (AA) is the most common surgical condition, and in the vast majority of cases, appendectomy is the treatment of choice. An accurate diagnosis is essential for lowering the rate of negative appendectomy. In the case of a complex appendicitis, management can be tough. The diagnostic process must be improved in order to reduce the negative appendectomy rate and the danger of misdiagnosis. The diagnosis of acute appendicitis was primarily relied on symptoms, signs, and laboratory evidence prior to the widespread use of CT scans.

**Keywords:** Appendicitis, Subhepatic appendix, Malrotated Caecal pole, adhesions

## **Introduction**

Acute appendicitis (AA) is a common condition that necessitates immediate medical attention. If not addressed early, AA can proceed quickly. In the extremes of age, appendicitis complications such as perforation peritonitis are common.<sup>1</sup> the enlargement (inflammation) of the appendix is known as appendicitis. The appendix is a tiny tube-like structure that connects the large intestine to the stomach. The problem is caused by a blockage in the appendix.<sup>2</sup> the obstruction causes increased pressure and irritation. Pain in the right iliac fossa (RIF), anorexia, nausea, constipation, and vomiting are common symptoms, but only 50% of people experience them. The discomfort began in the umbilical region, progressed down the lower abdomen, and finally landed on the RLQ.<sup>3, 4</sup> the pain began abruptly, was acute and colicky, and worsened with time. Pathogenesis is characterized by luminal obstruction. <sup>5</sup> The most common cause of obstruction is a faecolith, which is caused by the accumulation and inspissation of faecal waste around vegetable fibre. Virus-induced lymphocyte follicular growth, inspissated barium, worms, and tumours are all known to block the lumen. Mucus suppuration causes appendicitis, which dilates the lumen and raises intraluminal pressure.<sup>6</sup> If the process is sluggish, an inflammatory mass containing the terminal ileum, caecum, and omentum forms, leading to the formation of an appendicular abscess. As a result of the abscess rupture, fistulas between the appendix and the bladder, the small intestine, the sigmoid colon, or the caecum may occur.<sup>7</sup>

**Present medical history:** On March 11th, 2021, a 24-year-old male was taken to AVBRH by his wife with the major symptom of pain in the right iliac fossa, nausea, and vomiting. He was admitted to the ward for surgery. He is in agony and has a dull countenance at the moment of admission, which causes him discomfort.

**Past medical history:** A 24-year-old man was found to be free of any sickness, including diabetes mellitus, hypertension, asthma, and allergies.

## **Examination**

Deep palpation of the RIF revealed moderate soreness, and physiological measures such as heart rate, respiration rate, temperature, and blood pressure were all within normal norms.

## **Physical examination**

- General appearance: looks ill, lying uncomfortably, grasping on clothes, afebrile
- Vital signs: Temp: 37.0 °C ,PR: 70 beats per minute , BP: 146/72 mmHg ,RR: 18 breaths per minute , O2: 98%.

### **Hands**

Hands were warm and dry

No clubbing, koilonychia or leukonychia

No peripheral cyanosis

No palmar erythema

Normal sensation

### **Head and Neck**

No swelling observed

No conjunctival pallor

No jaundice

No central cyanosis

No mouth ulcers

### **Legs**

No pitting edema

No swelling

No redness

Normal sensation

### **Abdominal Examination**

Abdomen was soft and lax, no organomegaly, right iliac fossa tenderness

- Rebound tenderness positive
- Mcburney's sign positive
- psoas sign positive
- Flank tenderness negative

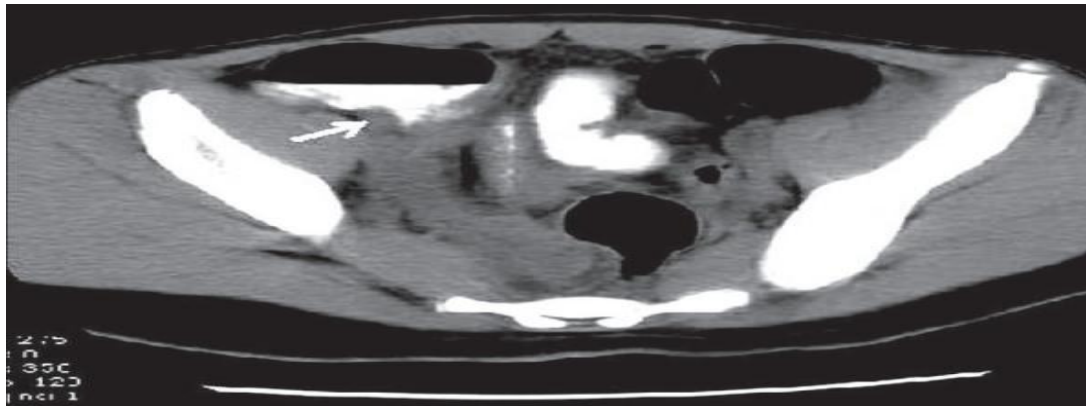
- Obturator sign negative
- Dunphy's sign negative
- Rovsing's sign negative
- Rectal examination may reveal localized tenderness as the only sign of an inflamed retrocaecal or pelvic appendix

### Investigations

**Diagnostic Assessment:** Blood test: Hb -14.5 gm%, Total RBC count -4.5millions/cu mm, Total WBC count -8000/cu mm, Total Platelet count -2.5 lacs/cu mm, Albumin -4.1 gm%,Bilirubin(conjugated)-0.4gm%,Bilirubin(unconjugated)-1.1gm%.

**CT scan of abdomen and pelvis:** Abnormal appendix (diameter >6 mm) identified or calcified appendicolith seen in association with periappendiceal inflammation, fat stranding

**Fig 1: CT scan shows an abnormal appendix**



Appendicitis. Contrast-enhanced CT scan shows an Abnormal appendix (diameter >6 mm) identified or calcified appendicolith seen in association with periappendiceal inflammation, fat stranding

### Therapeutic Intervention:

Inj.Amoxicillin 500mg x OD, Tab.Emset 4mg x TDS, Inj.Tramadol 100mg x TDS, Tab.Limcee 500mg x OD, Tab.pantaprozol 40mg x OD.

## **Discussion**

It is rare for the caecum and appendix to be located subhepatically since subhepatic appendicitis makes up an annual incidence of 0.09 per 100,000 populations.<sup>8</sup> In this patient, malrotation of the caecal pole resulted in the caecum being located at the hepatic flexure and appendix base poster inferior to the inferior border of the liver. The cause, in this case, was attributed to congenital adhesions which tend to arise during physiological organogenesis or as a result of an abnormality in the embryonal development of the abdominal cavity.<sup>9</sup>

The lumen can be restricted by virus-induced lymphocyte follicular growth, inspissated barium, worms, and tumours. Mucus suppuration causes appendicitis, causing the lumen to widen and the intraluminal pressure to rise.<sup>6</sup> If the process is not progressed quickly enough, an inflammatory mass containing the terminal ileum, caecum, and omentum arises, resulting in an appendicular abscess. As a result of the abscess rupture, fistulas can occur between the appendix and the bladder, the small intestine, the sigmoid colon, or the caecum.<sup>10</sup> In the case observed by Hafiz, a positive Murphy's sign was also elicited despite previous cholecystectomy<sup>11</sup>.

A total of 100 patients with acute appendicitis were included in this prospective cross-sectional investigation, with no age limit. Before the appendectomy, CRP was measured in the resected specimen for histological investigation. C-reactive protein levels were elevated in 62 of 100 individuals. The sensitivity and specificity were 81.28 and 92.86 percent, respectively, with negative and positive predictive values of 26.26 and 99.37 percent. CRP levels more than 15/dl were associated with more complex appendicitis, such as perforation and gangrene.<sup>12</sup>

## **Conclusion**

To conclude, this was a 24-year-old male who presented with RLQ pain and was diagnosed with acute appendicitis. The patient had an appendix located poster inferior to the inferior border of the liver. Chronic appendicitis does not manifest with classical clinical symptoms and signs of acute appendicitis. In the evolution of the chronic and recurrent abdominal pain, the chronic appendicitis must always be considered as one of the probable pathological conditions.

## Consent & Ethical Approval:

As per international standard or university standard guideline Patient's consent and ethical approval has been collected and preserved by the authors.

## References

1. Mundada A, Vaidya V, Lamture Y. Anorexia in acute appendicitis: A non-specific factor with significant accuracy in diagnosis. *Medical Science*. 2020;24(105):2812-6.
2. Jones MW, Lopez RA, Deppen JG. Appendicitis. *StatPearls* [Internet]. 2021 Feb
3. . Lerner AJ. The aetiology of appendicitis. *Br J Hosp Med* 1988;39: 540-2.
4. Addiss DG, Shaffer N, Fowler BS, Tauxe RV. The epidemiology of appendicitis and appendectomy in the United States. *Am J Epidemiol* 1990;132: 910-25
5. Murphy J. Two thousand operations for appendicitis, with deductions from his personal experience. *Am J Med Sci*. 1904 Aug 1;128:187-211.
6. Brennan GD. Pediatric appendicitis: pathophysiology and appropriate use of diagnostic imaging. *Canadian journal of emergency medicine*. 2006 Nov;8(6):425-32.
7. Hurme T, Nylamo E. Conservative versus operative treatment of appendicular abscess. Experience of 147 consecutive patients. In *Annales chirurgiae et gynaecologiae* 1995 Jan 1 (Vol. 84, No. 1, pp. 33-36).
8. Longani SK, Ahmed A. Classical Presentation of Acute Appendicitis in the Case of a Subhepatic Appendix. *Cureus*. 2019 Oct;11(10).
9. Brüggmann D, Tchartchian G, Wallwiener M, Münstedt K, Tinneberg H, Hackethal A: Intra-abdominal adhesions: definition, origin, significance in surgical practice, and treatment options. *Dtsch Arztebl Int*. 2010, 107:769-75. 10.3238/arztebl.2010.0769
10. Hafiz N, Greene KG, Crockett SD: An unusual cause of right upper quadrant pain. *Gastroenterology*. 2017, 153:10-11. 10.1053/j.gastro.2016.12.042
11. Ball WR, Privitera A: Subhepatic appendicitis: a diagnostic dilemma. *BMJ Case Rep*. 2013, 2013:Accessed: April 18, 2018: 10.1136/bcr-2013-009454
12. RAMRAO, Lamture Yeshwant, et al. Role of c Reactive Protein in Acute Appendicitis: A Cross-Sectional Study. *International Journal of Current Research and Review*, 2020, 12: 66-69.

