

Radiographic Assessment of Impacted Mandibular Third Molar- An ex-vivo study

Abstract:

Background: Mandibular third molars are the most commonly impacted teeth and frequently associated with various pathologies including infection, traumatic, inflammatory and cystic lesions necessitating their surgical removal. To avoid complications, clinical and radiographic evaluation of impacted teeth is essential to provide information about tooth anatomy, position and condition of the surrounding bone.

Aim: To evaluate impacted mandibular third molars (IMTM) with the help of panoramic radiographs for the type of impaction, available third molar space, level of eruption, and relation to the inferior alveolar nerve (IAN).

Materials and Methods: Total 600 patients were selected and were divided into three groups; group I (18-27 years), group II (28-37 years), and group III (≥ 38 years). Digital OPG were traced and evaluated for angulations, third molar space, level of eruption, and relation of third molar roots to IAN canal. The observations were subjected to statistical analysis using Chi-square test.

Results: Out of 600 samples, 306 (51%) were males and 294 (49%) were females. Out of 1079 third molar sites, mesioangular impaction (40.22%) was the most common. Class II relation (84.24%) for third molar space and level A of eruption (45.69%) were most frequent. In true relation, interruption of the white line of the IAN canal (20.85%) was the most frequent relation of the IMTM roots to the IAN canal and others (false/no relation) was the most common in all relations.

Conclusion: Panoramic radiography is a relatively safe, reliable, inexpensive, and readily accessible technique for preoperative evaluation of IMTM and their relation to IANcanal.

Keywords

Angulation, impacted mandibular third molar, inferior alveolar nerve canal, level of eruption, panoramic radiography, third molar space

UNDER PEER REVIEW

Introduction:

With evolutionary advancements, jaw sizes in the human race have reduced significantly diminishing the need for third molars. Third molars, or wisdom teeth, however, are still present in the bulk population with considerable variations in different individuals and often require removal to prevent or treat the third molar-associated disease states.¹ It supports the second molar in function. Though the tooth is never as well developed and presenting with many structural deformities, it resembles closely the mandibular second molar in the number of cusps and to the first molar in occlusal design.²

Mandibular third molars (MTM) are the most frequently congenitally impacted teeth and normally erupts at ages ranging from 16 to 24 years.³ An impacted tooth is defined as a tooth that is prevented from erupting into normal position because of malposition, lack of space, or other impediments (Mead 1954). According to Peterson, impacted teeth are those teeth that fail to erupt into the dental arch within the expected time.⁴ Farman in 2004, pent that impacted teeth are prevented from normal eruption due to a physical barrier within the path of eruption⁴. It has been observed that approximately 73 percent of young adults may have a minimum of one impacted mandibular third molar (IMTM).⁵ The incidence varies from 9.5% to 68% in different populations. Several factors have been reported to be responsible for the high rate of impaction of Mandibular Third Molar (MTM). These include less space in the dental arch, inappropriate angulations and wrong path of eruption, high thickness of overlying soft and hard tissues, and the untimely eruption sequence. Mesiodistal width of the third molar may also have a part in the tendency for impactions.⁶ Teeth that fail to attain their proper place in the arch may be pathological and should be indicated for extraction. Other common indications for extraction include pain, pericoronitis, periodontal disease, caries, cyst formation, and pathological root resorption. The Impaction of the MTM weakens the

angle area of the mandible making it vulnerable to fracture either during removal or due to trauma.⁷

Mandibular impaction is classified based on three criteria: angulation, position relative to the anterior border of ramus, and position relative to the occlusal plane. Several methods have been used to classify impaction, however Winter's (1926) and Pell and Gregory's (1933) classifications are the most commonly used methods to classify impacted mandibular third molar. According to Archer (1975) and Kruger (1984), depending on the direction of the crown of the impacted tooth, they are classified into mesioangular, distoangular, vertical, horizontal, buccoangular, linguoangular, and inverted.^{8,9}

Surgical removal of the third molars is the most frequently performed procedure and may have several complications.¹⁰ Injury to sensory nerve bundles is a frequent and serious complication associated with the extraction of the MTM^{11,12}. A close anatomic relationship between the roots of the third molar and the mandibular canal places the IAN at risk of damage¹². The chances of nerve injury occurring after lower third molar disimpaction is usually around 5% ranging from 0.5%- 8%.^{11,12} The various reasons that may cause nerve damage are the position of the third molar, the relationship between the mandibular canal and third molar roots, surgical technique, method of anesthesia and patient's age. To avoid complications, clinical and radiographic evaluation of impacted teeth is essential. A good-quality panoramic radiograph provides information about the general condition, tooth anatomy, and condition of the surrounding bone. This study was carried out to evaluate IMTM for the type of impaction, available third molar space, depth of impaction, and relation to inferior alveolar nerve canal allowing the dentist to consider these factors to assess the risk of complications associated with the surgical removal of IMTM.

Materials and Methods:

The present study was designed as an observational study and conducted in the Department of Oral Medicine and Radiology after obtaining approval from the Institutional Ethical Committee in which the Panoramic radiographs were obtained after detailed clinical examination.

Inclusion Criteria: Patient with age 18 years or above having atleast one IMTM and willing to give consent for the study.

Exclusion Criteria:

- History of extraction of a permanent tooth, mandibular fractures or orthodontic treatment.
- Patients with a developmental anomaly, congenital or systemic diseases, or major pathology in the mandible that has caused severe bone resorption /destruction and tooth migration.
- Third molars with underdeveloped roots (less than 2/3 root formation radiographically).

Methodology:

Patients who were referred to the Oral Radiology department for orthopantomograms and met the definite inclusion criteria were selected for the study. Digital Panoramic Radiographs were taken using I Max Touch (C E 0459, Owandy) OPG x-ray machine and were processed using Dental eye 3.1 software. A total of 600 patient's orthopantomograms were studied who had a minimum of one IMTM. The patients were divided into three groups according to their age. The age range of group I was 18-27 years, group II was 28-37 years, and the age range of group III was 38 years and above. All the IMTM included in the study were evaluated for the type of angulations, available third molar space, level of eruption (depth of impaction), and relation of their root with the inferior alveolar canal based on panoramic radiographic presentation. Interpretation of the radiographs was done using a radiographic viewer and

magnifying lens. White acetate tracing paper and pencil were used to trace the following necessary radiographic findings.

- Outline of the lower border of mandible, condyle, coronoid, anterior and posterior border of ramus of the mandible and superior and inferior border of the IAN canal on both right and left side.
- Outline of mandibular first and second premolar, first, second and third molars of right and left sides were traced.
- Occlusal plane was drawn through the tip of the most superior cusps of the first premolar and the tip of the most superior mesial cusps of the second molar, extending up to the anterior border of the ramus of the mandible.
- A perpendicular line was drawn from the occlusal plane touching the most distal point of the second molar. (Figure 1)

Traced radiographs were assessed for:

Angulations of impacted mandibular third molars¹⁰:

- The inclinations / angulations of third molars was determined by measuring the angle formed between the line intersecting the long axis of the second and third molars, drawn through the midpoint of the occlusal surface and midpoint of the bifurcation and classified into following four types: the inclination of third molar was considered as vertical if angle was $\pm 10^\circ$, mesioangular if angle was $+11^\circ$ to 70° , horizontal if angle was -11° to -70° and distoangular if more than 70° .

(+ Sign denotes that intersection of line is above the molars and - sign denotes that intersection of line is below the molars)

Third molar space:

- The available third molar space was determined as the distance between the intersection of the occlusal plane with the anterior border of the ramus and intersection of the vertical line from the distal surface of the second molar with the occlusal plane. The mesiodistal width of the third molar crown was also measured and recorded. Space available for the third molar was classified into three types as class I, Class II and Class III.
- Class I: If the available space is more or equal to mesiodistal width of third molar
- Class II: If the available space was less than mesiodistal diameter of third molar
- Class III: If the tooth was located completely within the mandibular ramus.

Level of eruption: It was recorded as

- Level A: when there was crown to crown position between the impacted third molar and second molar.
- Level B: when the occlusal surface of the third molar is between the occlusal and cervical position of the second molar.
- Level C: when the occlusal surface is below the cervical position of the second molar.

Relation of inferior alveolar nerve canal

Relation of the IAN canal with the roots of MTM was assessed on the basis of Rood's criteria as follows¹³.

1. Darkening of root: when there is increased radiolucency due to impingement of canal on molar roots
2. Deflected roots: when there is abrupt deviation of the root when it reaches the IAN canal.
3. Narrowing of roots: the relation is considered as narrowing when the width of the roots is reduced.

4. Dark and bifid root apex : when the IAN canal crosses the root apex and is identified by the double periodontal ligament shadow of the bifid apex.
5. Interruption of white line: the white line is considered as interrupted if either or both of the two radiopaque lines disappears before it reaches the tooth structure
6. Diversion of inferior alveolar canal: the IAN canal considered to be diverted when it changes its direction.
7. Narrowing of the IAN canal: the IAN canal is considered to be narrowed when there is reduction in diameter of the mandibular canal where it crosses the roots of MTM.
8. Others: the relation of MTM roots to IAN canal other than above all relations was considered as others.

The radiographic signs, darkening of roots, deflection of roots, narrowing of roots, dark and bifid apex of root, diversion of IAN canal, interruption of canal and narrowing of IAN canal were considered as true relation and 'others' was considered as false relation.

The data was collected and systematically tabulated. It was analyzed using statistical analysis software SYSTAT version 12 (By Cranes software's, Bangalore). Statistical analysis was done by descriptive statistics as mean, SD, and proportions/percentages, etc. Chi-Square test of association between two variables was used to compare various variables. Chi-square test was used for qualitative data whenever two or more than two groups were used to compare. The level of significance was set at $P = 0.05$ ($p = < 0.05$ – significant).

Observations and Results:

The present study was conducted to evaluate the IMTM by using panoramic radiography. A total of 600 subjects were selected for the study. All the subjects were divided into three groups. Group I (18-27 years) consisted of 368 subjects, group II (28-37 years) consisted of 154 subjects. Group III (38 years and above) consisted of 78 subjects. (Table 1)

Out of 1200 MTM sites, 1079 (89.91%) MTM sites were evaluated in the study. At remaining sites, third molars were either missing or erupted. The following parameters were compared:

Position of IMTM:

Out of 1079 IMTM, 527(48.84%) were present on the right side and 552 (51.16%) were present on the left side. A total of 434 (40.22%) third molars showed mesioangular impaction, 144 (13.34%) IMTM were distoangular, 321(29.75%) third molars were vertical and 180 (16.68%) IMTM were horizontal. There was statistically significant difference between the angulations of different types (right side (χ^2) = 25.52, p = 0.0023 and left side (χ^2) = 34.21, p = 0.0041, both were significant, as $p < 0.05$) (Figure 2)

Space-wise distribution:

Of the total, 82 (7.60%) were in class I relation. The maximum number of IMTM i.e. 909 (84.24%) were in class II relation and 88 (8.15%) showed class III relation. There was a statistically significant difference between different third molar spaces. (right side (χ^2) = 20.54, p = 0.0057 and left side (χ^2) = 24.26 and p = 0.0034, both were significant considering $p < 0.05$). (Figure 3)

Level of Eruption:

Out of 1079 IMTM sites, 493 (45.69%) showed level A of eruption followed by 350 (32.43%) at level B, and 236 (21.87%) showed level C eruption. There was a statistically significant difference between different levels of the eruption of third molars in all groups.

(right side (χ^2) $p < 0.05$) (Figure 4)

Inferior Alveolar nerve canal relation wise distribution of IMTM:

Out of evaluated sites, 138 (12.80 %) showed darkening of roots, 73 (6.77%) relations were deflection of the root, 67 (6.21%) were narrowing of the root, 24 (2.22%) relations were dark and bifid apex of the root, 225 (20.85%) were interruption of the white line of the canal, 52 (4.82%) showed diversion of the inferior alveolar canal, 72 (6.67%) showed narrowing of inferior alveolar nerve canal, and 428 (39.67%) relations were others. There was a statistically significant difference between different inferior alveolar nerve canal relations of third molar roots. [Right side (χ^2) = 29.64, $p=0.0009$ and left side (χ^2) = 41.28, $p=0.0005$, both were significant considering $p < 0.05$].(Figure 5)

Discussion:

An impacted wisdom tooth is perceived to be a prevalent problem in dentistry. The occurrence of impaction has been rising over the years due to the less functional activity of the jaws. The incidence of impaction may differ from one race to the another depending on the genetically inherited factors, the type of food, and habits that may have a role in the growth of the jaws. Impacted and partially erupted third molars can result in several symptoms and pathologies such as bone loss, root resorption of adjacent teeth, odontogenic cysts and tumors, pericoronitis, and systemic infections. Presently, there is an argument in dental literature regarding the clinical management of impacted third molars. Although the decision to remove symptomatic third molars is a straightforward one, the prophylactic removal of asymptomatic third molars remains a controversial issue¹⁴.

A total of 600 (306 males and 294 females) samples were included in the study and out of 1200 mandibular third molar sites, 1079 sites were evaluated. The maximum number of samples, 368 (61.33 %) were in the age group I (18-27 years). The second age group (28-37 years) included 154 (25.67%) samples and the third age group (38 years and above) included 78 (13%) samples. The results of the present study are coinciding with the study of Obiechina AE et al¹⁵ in which the majority of impactions were in the age group of 16-25 years (341 out of 473) and the highest number (200) was in the age group of 21-25 years. The results are also as per the studies conducted by Sandhu SS¹⁶ and Gupta et al¹⁷, where the highest incidence of impacted mandibular third molar was in the age group between 17 to 25 years and 18 to 27 years respectively. According to Schersten et al the most suitable age for studying the frequency of third molar impaction is 20 to 25 years.

In the conducted analysis, 306 (51%) were males and 294 (49%) were females which showed andriocentric results. As regards the gender distribution of this study, it is per studies of Hazza AM et al¹⁸ [789 (58%) males and 570 (42%) females], Hassan AH¹⁹ [males

222 (52.6%) and females 200 (47.4%)] and Padhye M et al²⁰[620 males (51.77%) and 580 (48.3%) females] as they found slight andriocentrism in their studies. However the assessments by Sandhu SS¹⁶, Odusanya and Abayomi²¹, Eshghpour M²², Bansal S et al²³ and Shivramkrishnan SM²⁴ showed female predominance which is not consistent with our study.

It was typically seen that the type of impaction in the present analysis was mesioangular. Obiechina AE¹⁵ studied 338 patients in the age range of 16 to 54 years. They found mesioangular impaction (48.20%) as the most routine type, followed by vertical 30.23%, horizontal 15.64%, distoangular 5.50%, and inverted 0.2 % which is also consistent with our study. The assessment by Sivaramakrishnan SM²⁴ found more mesioangular third molar impactions (41.2%) which is consistent with the present analysis.

The conducted assessment showed a maximum of third molars (84.24%, 909 out of 1079 subjects) in class II relation with the anterior border of ramus, followed by class III (8.15%, 88 in 1079 in subjects) and Class I relation (7.60%, 82 in 1079 subjects). Results of the conducted analysis are following the study of Obiechina et al¹⁵ and Monaco et al²⁵, where they found Class II relation as a pattern in Nigerian and Italian populations respectively. Gupta et al¹⁷ and Eshghpour M²² also reported class II as the most common relation, followed by class I and class III relation.

In the present study, level A (45.69%) was the prevalent level of eruption followed by level B (32.43%) and level C (21.87%). This is per the studies by Gupta et al¹⁷, Monaco et al²⁵, Obiechina AE et al¹⁵. These findings are also in agreement with the study of Ajay Kumar Pillai et al²⁶ who found level A (54.9%) as the most common level of an eruption of IMTM followed by level B (38.9) and level C (6.3%).

In the present analysis, most prevalent third molar relation to IAN canal was interruption of the white line of the canal (20.85%), darkening of root (12.80%), deflection of root (6.77%),

narrowing of inferior alveolar canal (6.67%), narrowing of root (6.21%), diversion of the inferior alveolar canal (4.82%), and dark and bifid apex of root (2.22%). Relationship other than the above mentioned were found in 39.67% (others) of cases. The results of this analysis are in accordance to the study by Michael Sedaghatfaret al²⁶. They found the frequency of the panoramic radiographic signs of third molar roots to the IAN canal as darkening of root (17%), interruption of the white line of the canal (35.9%), diversion of the inferior alveolar canal (12.5%), deflection of roots (13.9%) and narrowing of roots (11.8%). Darkening of the root, interruption of the white line of the canal, diversion of the inferior alveolar canal, and narrowing of roots are significantly associated with IAN exposure. According to Sedaghatfar²⁷, from the radiologist's perspective, four radiological parameters, including darkening and narrowing of dental roots, interception of the canal, and deviation of the canal had a significant relationship with mandibular nerve injury and concluded that radiological assessment before surgery plays a key role in decreasing the risk of injury to the mandibular canal.

Conclusion:

A good-quality panoramic radiograph provides knowledge about the general condition, tooth anatomy, and condition of the surrounding bone. Panoramic radiography is a relatively safe, reliable, inexpensive, and readily accessible technique used for preoperative evaluation of impacted mandibular third molars for their angulation, available third molar space, level of eruption, and their relation to inferior alveolar nerve canal.

COMPETING INTERESTS DISCLAIMER:

Authors have declared that no competing interests exist. The products used for this research are commonly and predominantly use products in our area of research and country. There is absolutely no conflict of interest between the authors and producers of the products because we do not intend to use these products as an avenue for any litigation but for the advancement of knowledge. Also, the research was not funded by the producing company rather it was funded by personal efforts of the authors.

References:

1. Meara DJ. Evaluation of Third Molars: Clinical Examination and Imaging Techniques [Internet]. Vol. 20, Atlas of the Oral and Maxillofacial Surgery Clinics. 2012. p. 163–8. Available from: <http://dx.doi.org/10.1016/j.cxom.2012.07.001>
2. Nelson SJ. Wheeler's Dental Anatomy, Physiology and Occlusion - E-Book. Elsevier Health Sciences; 2009. p.368
3. Kaya GS, Muzaffer M, Omezli MM, Dayi E. Some morphological features related to mandibular third molar impaction [Internet]. Journal of Clinical and Experimental Dentistry. 2010. p. e12–7. Available from: <http://dx.doi.org/10.4317/jced.2.e12>
4. Spiotto MT, Juodzbaly G, Daugela P. Mandibular Third Molar Impaction: Review of Literature and a Proposal of a Classification [Internet]. Vol. 4, Journal of Oral and Maxillofacial Research. 2013. Available from: <http://dx.doi.org/10.5037/jomr.2013.4201>
5. Alhajja ESJA, Abu Alhajja ES, AlBhairan HM, AlKhateeb SN. Mandibular third molar space in different antero-posterior skeletal patterns [Internet]. Vol. 33, The European Journal of Orthodontics. 2011. p. 570–6. Available from: <http://dx.doi.org/10.1093/ejo/cjq125>

6. Šečić S, Prohić S, Komšić S, Vuković A. Incidence of impacted mandibular third molars in population of Bosnia and Herzegovina: a retrospective radiographic study [Internet]. Vol. 3, Journal of Health Sciences. 2013. p. 151–8. Available from: <http://dx.doi.org/10.17532/jhsci.2013.80>
7. Shunmugavelu K. Rare occurrence of the left maxillary horizontal third molar impaction, the right maxillary third molar vertical impaction and the left mandibular third molar vertical impaction with inferior alveolar nerve proximity in a 30 year old female: a case report [Internet]. Vol. 27, Ethiopian Journal of Health Sciences. 2017. p. 101. Available from: <http://dx.doi.org/10.4314/ejhs.v27i1.14>
8. Mehra P, D’Innocenzo R. Manual of Minor Oral Surgery for the General Dentist. John Wiley & Sons; 2015.312 p.
9. Fragiskos FD. Surgical Extraction of Impacted Teeth [Internet]. Oral Surgery. p. 121–79. Available from: http://dx.doi.org/10.1007/978-3-540-49975-6_7
10. Koong B, Pharoah MJ, Bulsara M, Tennant M. Methods of determining the relationship of the mandibular canal and third molars: a survey of Australian oral and maxillofacial surgeons. Aust Dent J. 2006 Mar;51(1):64–8.
11. Nakagawa Y, Ishii H, Nomura Y, Watanabe NY, Hoshiba D, Kobayashi K, et al. Third Molar Position: Reliability of Panoramic Radiography [Internet]. Vol. 65, Journal of Oral and Maxillofacial Surgery. 2007. p. 1303–8. Available from: <http://dx.doi.org/10.1016/j.joms.2006.10.028>
12. Valmaseda-Castellón E, Berini-Aytés L, Gay-Escoda C. Inferior alveolar nerve damage after lower third molar surgical extraction: a prospective study of 1117 surgical extractions. Oral Surg Oral Med Oral Pathol Oral RadiolEndod. 2001 Oct;92(4):377–83.
13. Rood JP, Shehab BA. The radiological prediction of inferior alveolar nerve injury during third molar surgery. Br J Oral Maxillofac Surg. 1990 Feb;28(1):20–5.

14. Shoaee S, Khazaei P, Mashhadiabbas F, Varshosaz M, Sharifi F, HesarI H. Association between tooth impaction and odontogenic lesions: A matched case-control study. *Med J Islam Repub Iran*. 2018 Jul 6;32:57.
15. Obiechina AE, Arotiba JT, Fasola AO. Third molar impaction: evaluation of the symptoms and pattern of impaction of mandibular third molar teeth in Nigerians. *Odontostomatol Trop*. 2001 Mar;24(93):22–5.
16. Sandhu SS, Kapila BK. Incidence of impacted third molars. *J Indian Dent Assoc*. 1982 Dec;54(12):441–4.
17. Gupta S, Bhowate RR, Nigam N, Saxena S. Evaluation of impacted mandibular third molars by panoramic radiography. *ISRN Dent*. 2011;2011:406714.
18. Hazza's AM, Albashaireh ZSM, Bataineh AB. The Relationship of the Inferior Dental Canal to the Roots of Impacted Mandibular Third Molars in Jordanian Population [Internet]. Vol. 7, *The Journal of Contemporary Dental Practice*. 2006. p. 71–8. Available from: <http://dx.doi.org/10.5005/jcdp-7-2-71>
19. Hassan A. Pattern of third molar impaction in a Saudi population [Internet]. Vol. 2, *Clinical, Cosmetic and Investigational Dentistry*. 2010. p. 109–13. Available from: <http://dx.doi.org/10.2147/ccide.s12394>
20. Padhye MN, Dabir AV, Girotra CS, Pandhi VH. Pattern of mandibular third molar impaction in the Indian population: a retrospective clinico-radiographic survey [Internet]. Vol. 116, *Oral Surgery, Oral Medicine, Oral Pathology and Oral Radiology*. 2013. p. e161–6. Available from: <http://dx.doi.org/10.1016/j.oooo.2011.12.019>
21. Odusanya SA, Abayomi IO. Third molar eruption among rural Nigerians [Internet]. Vol. 71, *Oral Surgery, Oral Medicine, Oral Pathology*. 1991. p. 151–4. Available from: [http://dx.doi.org/10.1016/0030-4220\(91\)90457-n](http://dx.doi.org/10.1016/0030-4220(91)90457-n)
22. Eshghpour M, Nezadi A, Moradi A, Shamsabadi RM, Rezaei NM, Nejat A. Pattern of

mandibular third molar impaction: A cross-sectional study in northeast of Iran. *Niger J ClinPract.* 2014 Nov;17(6):673–7.

23. Bansal S, Garg S, Gupta K, Srivastava S. Frequency of impacted and missing third molars among orthodontic patients in the population of Punjab [Internet]. Vol. 3, *Indian Journal of Oral Sciences.* 2012. p. 24. Available from: <http://dx.doi.org/10.4103/0976-6944.101672>
24. Sivaramakrishnan SM, Ramani P. Study on the Prevalence of Eruption Status of Third Molars in South Indian Population [Internet]. Vol. 07, *Biology and Medicine.* 2015. Available from: <http://dx.doi.org/10.4172/0974-8369.1000245>
25. Monaco G, Montevecchi M, Bonetti GA, Gatto MRA, Checchi L. Reliability of panoramic radiography in evaluating the topographic relationship between the mandibular canal and impacted third molars. *J Am Dent Assoc.* 2004 Mar;135(3):312–8.
26. Kumar Pillai A, Thomas S, Paul G, Singh SK, Moghe S. Incidence of impacted third molars: A radiographic study in People's Hospital, Bhopal, India. *J Oral BiolCraniofac Res.* 2014 May;4(2):76–81.
27. Sedaghatfar M, August MA, Dodson TB. Panoramic radiographic findings as predictors of inferior alveolar nerve exposure following third molar extraction. *J Oral Maxillofac Surg.* 2005 Jan;63(1):3–7.

Table: 1. Age and gender wise distribution of patients

Age group		Gender		Total
		Male	Female	
18-27 years	N	177	191	368
	%	29.5%	31.8%	61.3%
Mean		22.27	22.09	
SD		2.47	2.54	
Minimum		18	18	
Maximum		27	27	
28-37 years	N	80	74	154
	%	13.3%	12.3%	25.7%
Mean		32.18	31.87	
SD		2.89	2.75	
Minimum		28	28	
Maximum		37	38	
>38 years	N	49	29	78
	%	8.2%	4.8%	13.0%
Mean		46.59	47.96	
SD		6.97	8.61	
Minimum		38	38	
Maximum		64	70	
Total	N	306	294	600
	%	51.0%	49.0%	100.0%

Figure Legends:

Figure 1: Cropped panoramic radiograph with tracing showing class II, Level C Vertical impaction with deflection of roots

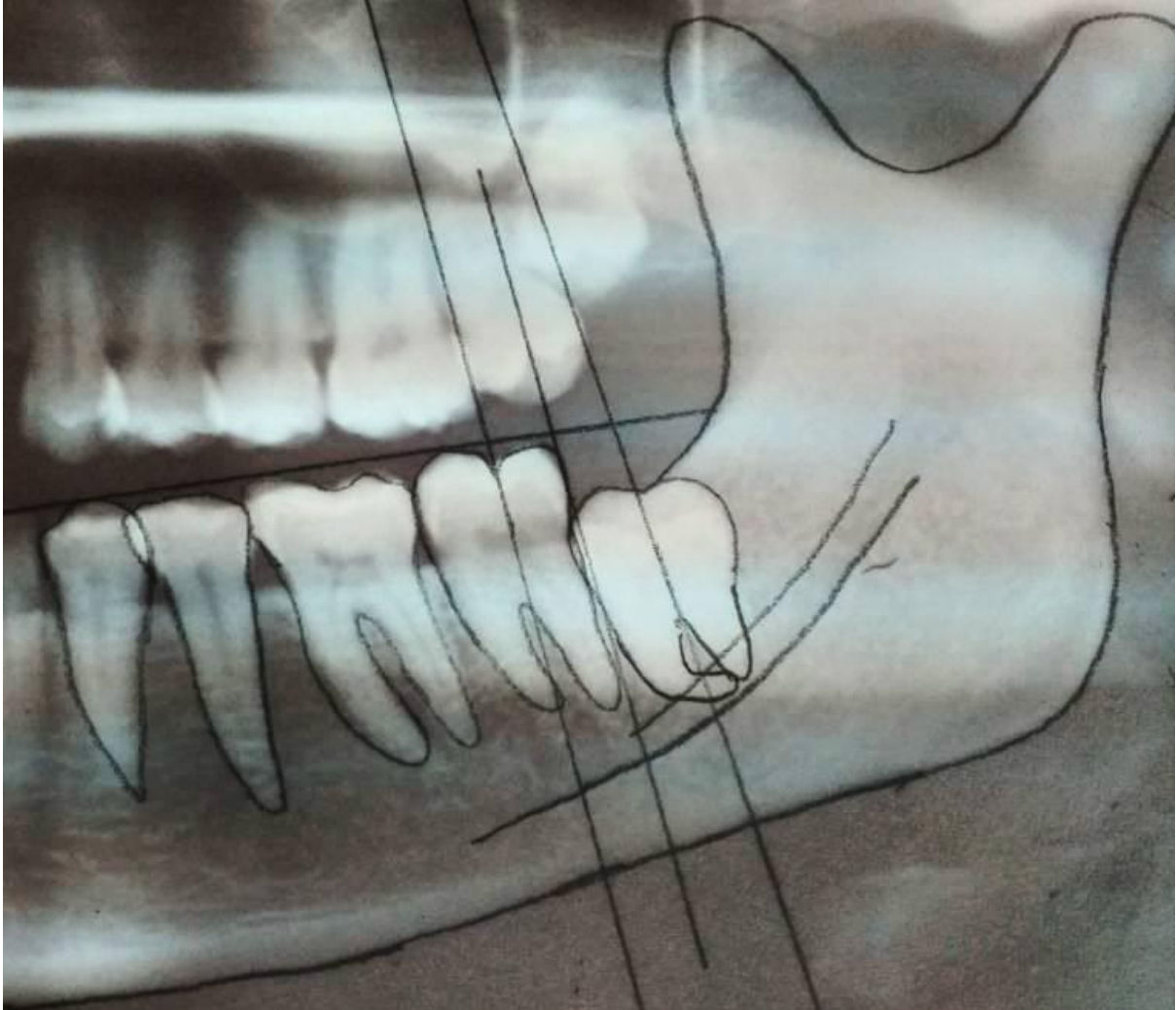


Figure 2: Distribution of Angulations

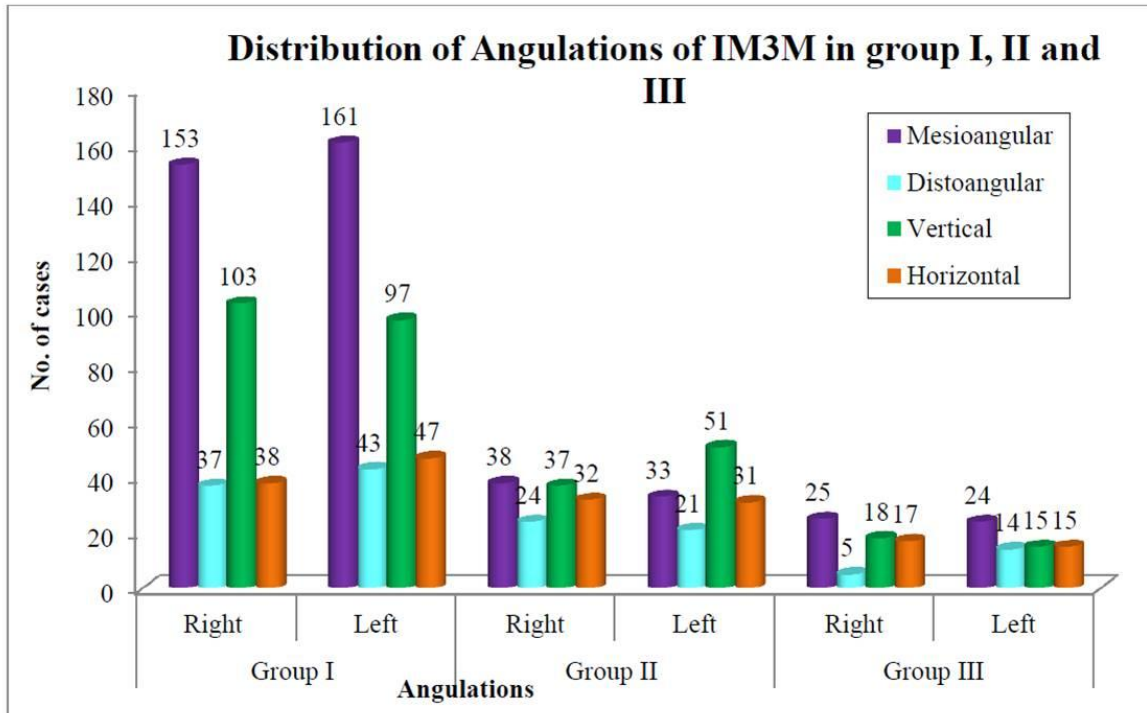


Figure 3: Third molar space wise distribution

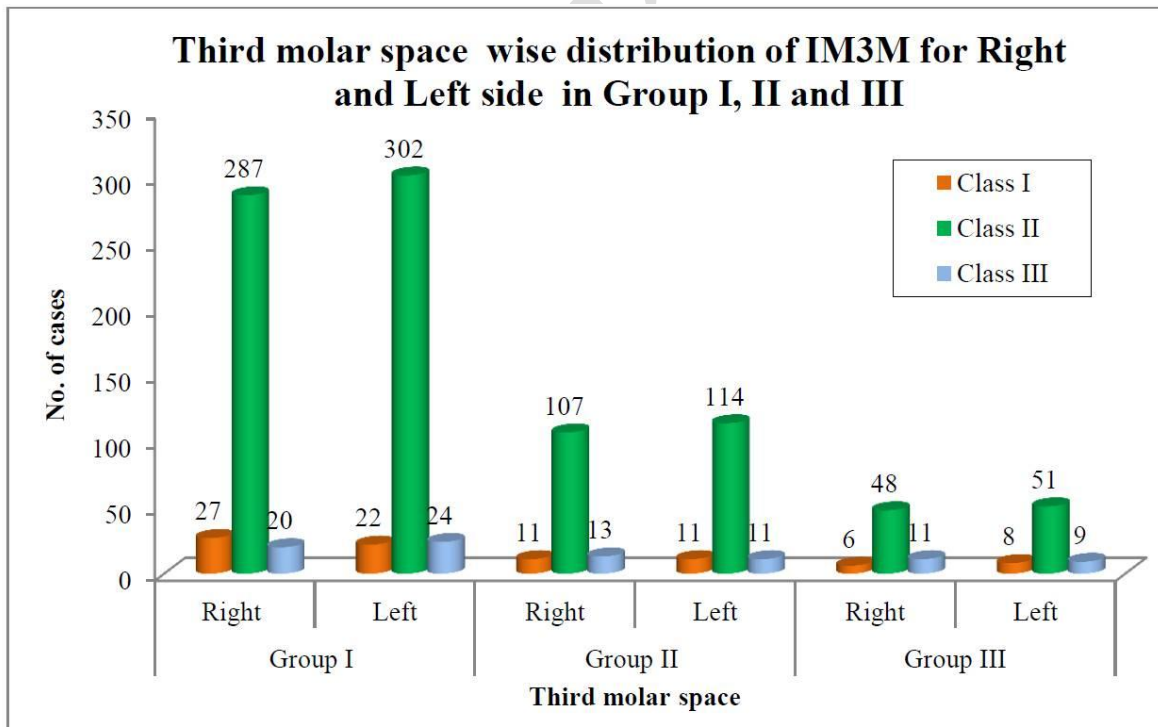


Figure 4: Level of eruption

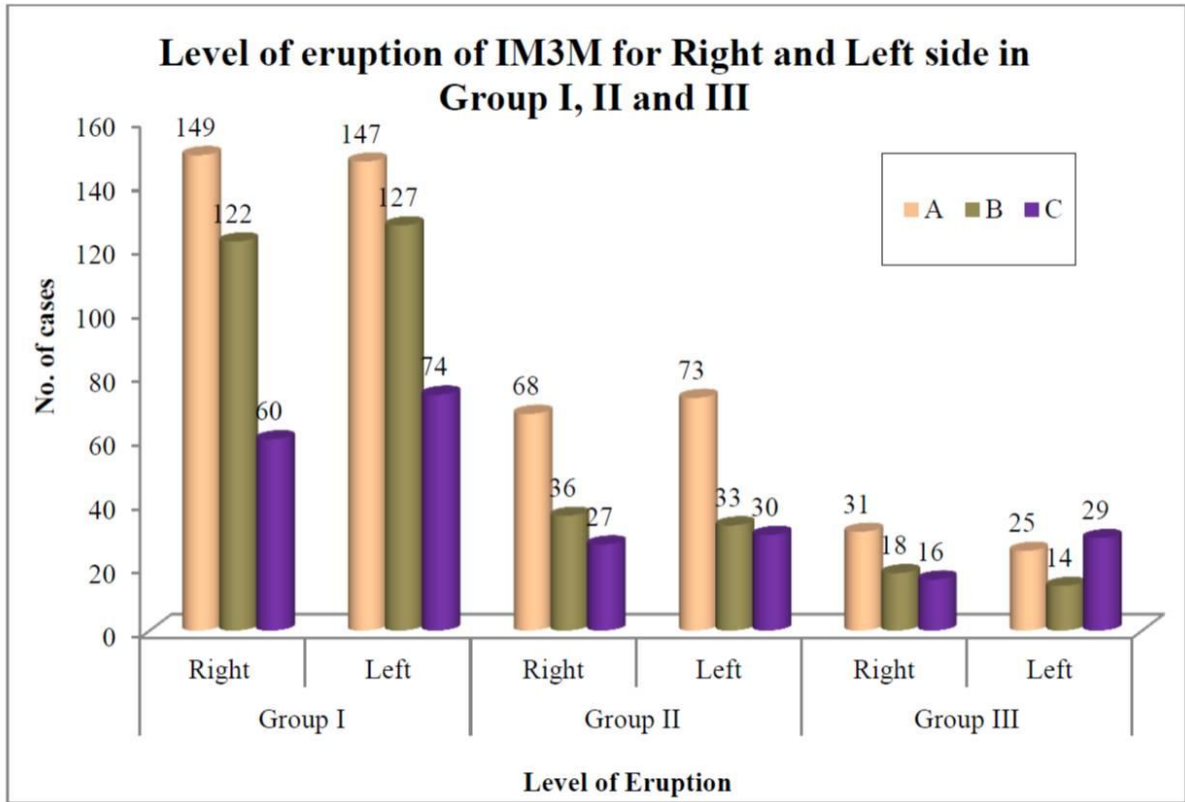


Figure 5: Relation of IMTM to IAN canal

UNDER PEER REVIEW

Relation of IM3M to IAN canal for right and left side in Group I, II and III

