

Study of lesions in bronchial brush and wash cytology

ABSTRACT

Aims: The aim of the study is to compare and evaluate the efficacy of bronchial brush and wash cytology in diagnosing neoplastic and non- neoplastic bronchopulmonary lesions and to relate the cytological findings with the clinical diagnoses.

Study design: Retrospective descriptive study.

Place and Duration of Study: Saveetha Medical College and Hospital, between January 2019 and December 2019

Methodology: Cases with both Bronchoalveolar lavage (BAL) and Bronchial brush (BB) samples (35) were included in the study. The slides were stained with Hematoxylin & Eosin stain, Papanicolaou stain, and were studied under the light microscope. The clinical points of interest were obtained from the case records at the medical records division, and histopathological findings from the histopathology registers at the Department of Pathology.

Results: A total of 35 cases were studied. Follow up with histopathology after a cytological diagnosis revealed that the sensitivity of diagnosing malignancy from BAL specimen and bronchial brush sample was 58% and 92% respectively.

Conclusion: The study confirms that the efficacy in assessing the risk of malignancy by respiratory cytology using a bronchial brush specimen is higher than the bronchoalveolar lavage specimen.

Keywords: Bronchial brush, Bronchoalveolar lavage, bronchopulmonary lesions.

1. INTRODUCTION

Lung cancer is one of the most prevalent malignancies. It is currently the primary cause of cancer related deaths globally [1]. The foremost solution for the treatment of lung cancer is diagnosis at an early stage. Primary lung carcinomas are classified as non-small cell carcinoma (NSCC) and small cell lung carcinomas (SCLC) [2]. Small cell lung cancers are highly malignant, most aggressive form of lung cancer that are usually located centrally in the major airways with a high metastatic potential. These cancers account for nearly 15 percent of lung cancers. Small cell lung carcinomas mostly metastasize by the time of diagnosis and is associated with poor prognosis. Concurrent chemotherapy and radiation therapy are attempted in limited stage small cell lung carcinomas. Non-small cell carcinoma (NSCC) includes malignancies apart from small cell lung

cancer like large cell neuroendocrine carcinoma, adenocarcinoma, squamous cell carcinoma, large cell carcinoma, spindle cell carcinoma. Non-small cell carcinoma usually grows and spreads more slowly than the small cell lung cancer and hence they are mostly resectable. Non-small cell carcinoma like squamous cell carcinomas usually arise in the center of large bronchi. Adenocarcinoma are formed from glandular structures in the epithelial tissues and are mostly peripherally located. Large cell carcinomas that can occur in any part of the lung and tend to spread faster than the other two types. [1]

Diagnosing the carcinomas at an early stage is key for early and effective treatment. The various diagnostics tests include chest X-rays, computerized tomography scans, magnetic resonance imaging, fiber optic bronchoscopy. Cytology specimens are best suited aids in diagnosis for most cases of lung cancer. There are various cytological methods which are accessible that includes sputum cytology, fiber optic techniques like bronchial brushing, bronchoalveolar lavage. Bronchoscopy gives a direct view of the airways and allows specific sampling of cells and tissues. It helps us in diagnosing endobronchial and centrally located lesion like squamous cell carcinoma and carcinoid tumor.

Broncho-alveolar lavage (BAL), initially evolved as a beneficial instrument for lung conditions like pulmonary alveolar proteinosis, cystic fibrosis and intractable asthma, and has gained acceptance and steady popularity as a tool for diagnosing carcinoma [3]. Broncho alveolar lavage specimens are often used as acceptable diagnostic tools for alveolar hemorrhage, malignancies and infections caused by bacteria, fungus, and virus as it improves the diagnostic yield.

Bronchial brushing (BB) is a cytological technique where surface of suspected lesions, visualized through a bronchoscope, is scraped and a cytological sample is obtained [3]. There is an added advantage with bronchial brushings as it is associated with direct sampling from the visualized mucosal abnormality.

2. MATERIAL AND METHODS

This study was conducted at Saveetha Medical College and Hospital. It is a retrospective study of bronchial brush and bronchial wash cytology specimen for neoplastic and non-neoplastic bronchopulmonary lesions received in the department of Pathology, Saveetha Medical College and Hospital during the period of one year from January 2019 to December 2019. A total of 35 cases were selected which had both bronchoalveolar lavage and bronchial brush samples available. The samples were obtained through fiber optic bronchoscopy performed by pulmonologists and were received in 95% isopropyl alcohol and processed as per standard procedures of cytology.

Bronchoalveolar lavage was performed with 20ml of saline infused in the syringe and observing the flow of saline with the distal tip of the bronchoscope. By maintaining the wedge position, a suction of 50 to 80 mm Hg was applied to collect the lavage specimen in the collecting trap. This step was repeated nearly 5 times as needed to obtain an adequate specimen. The bronchoalveolar lavage specimens were processed as soon as possible and stained with Hematoxylin and Eosin stains for microscopic examination.

Bronchial brushing were obtained with a small threaded brush through a separate channel in the fiber optic bronchoscope, guided to a selected site under visual control. The wash specimens were obtained by the guidance of bronchoscopy and aspirating the accumulated contents of the bronchus in the initial sample, and then additional samples were obtained by repeatedly installing and aspirating normal saline from the selected bronchus. The slides were stained Hematoxylin and Eosin stain and Pap stain and studied under light microscope.

The clinical points of interest were obtained from the case records at the medical records division and histopathological findings from the histopathology registers at the department of pathology.

3. RESULTS AND DISCUSSION

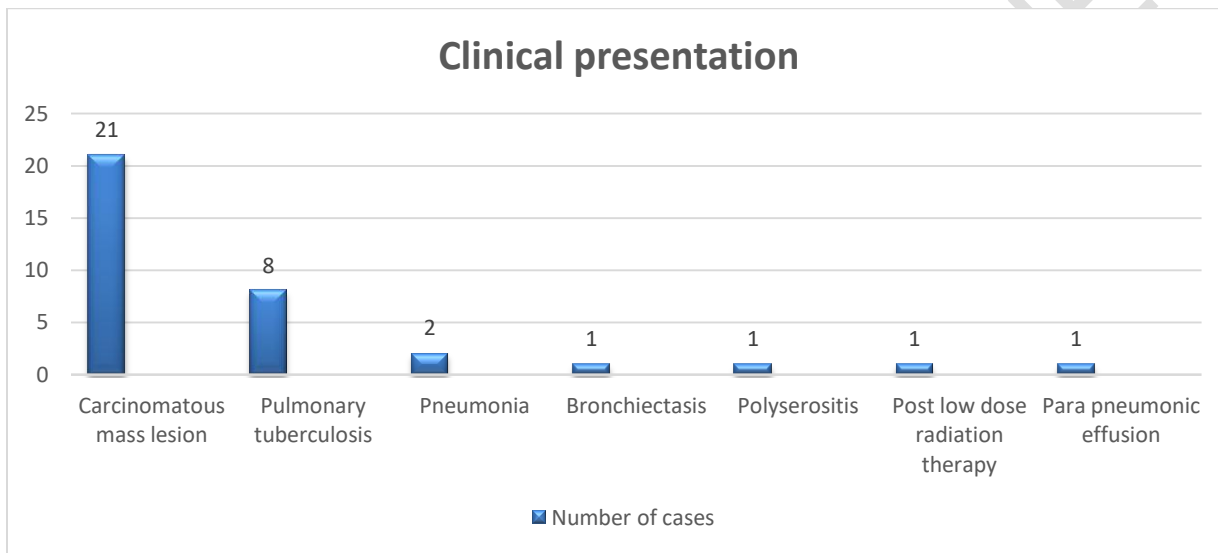
The present study comprised of 35 patients which included 24 male and 11 females (Table 1) The male: female ratio was 0.7: 0.3.

Table 1: Number of male and female cases

Total number of cases	Female	Male
35	11	24

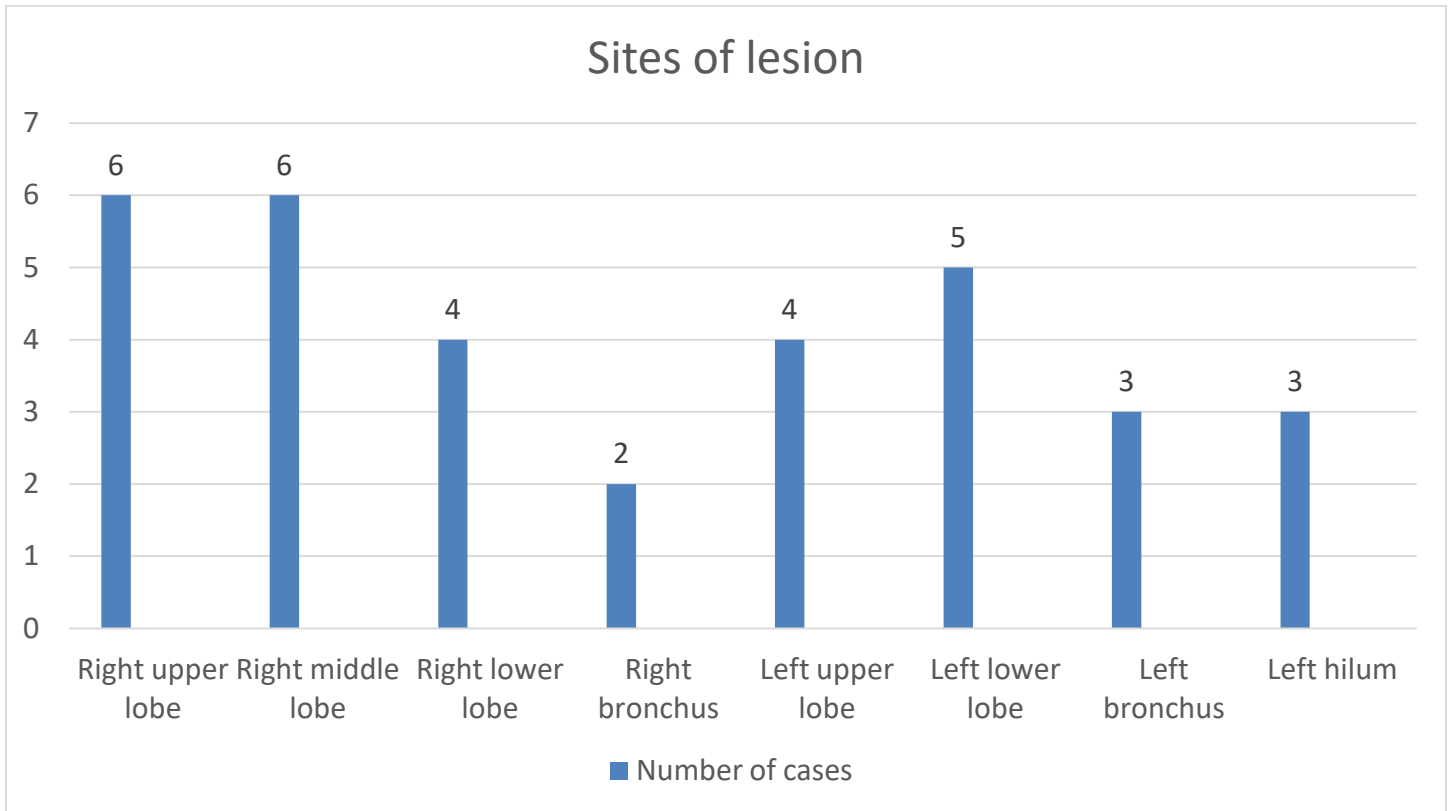
Out of 35 cases, 21 were clinically diagnosed as carcinomatous mass lesions, 8 as Pulmonary tuberculosis, 2 as pneumonia, Bronchiectasis, polyserositis, Post LDRT and Para pneumonic effusion each. (Figure 1)

Figure 1: Clinical diagnoses of the patients studied



On analyzing the sites most involved, it was inferred that right upper lobe and right middle lobe of the lung were the most affected sites. A total of 20 cases of lesions seen in right lung and in 15 cases the lesions were confined to the left lung (Figure 3 shows the pictorial representation of the location of lesions)

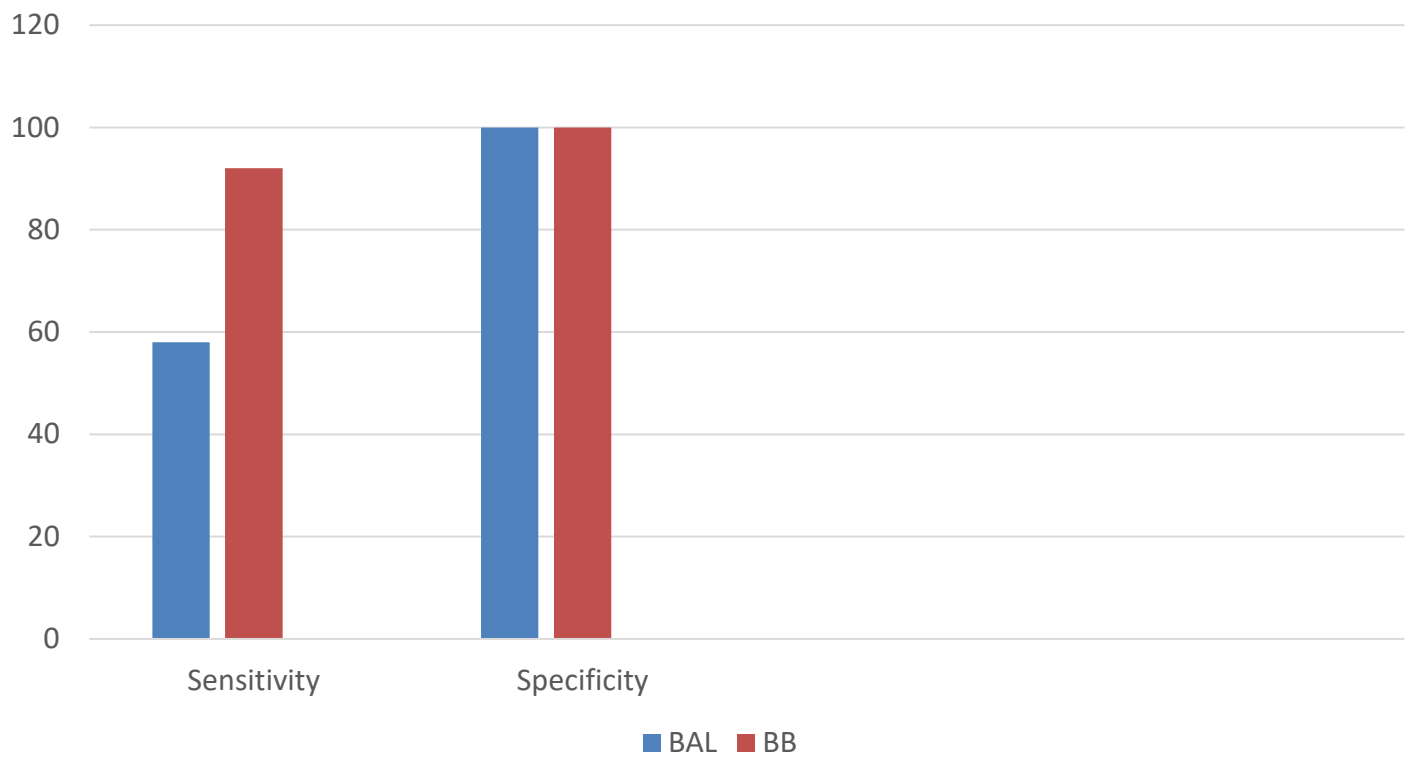
Figure 2: Pictorial representation of the sites of lesion



Keeping histopathology as gold standard, the accuracy of cytological diagnoses was assessed. Among the 35 cases studied, 12 cases were found to be positive for malignancy on histopathological examination. Bronchoalveolar lavage specimen identified lung cancer in 7 cases, thus showing a sensitivity of 58% and all cases which were negative for malignancy on histopathological examination were found to be negative in cytological examination as well, and hence had 100% specificity. The positive predictive value was 100% as the bronchoalveolar lavage examination accurately detected positivity in all the true positive cases.

Bronchial brushings showed a higher sensitivity of 92% as compared to BAL specimens. This also had a 100% positive predictive value and specificity, accurate in all the 11 cases showing positivity in the total of 12 cases of histopathologically confirmed lung cancer cases. (Figure 3)

Measures of validity – Sensitivity and specificity



UNDER PEER

3.1 DISCUSSION

With the materialization of fiber optic bronchoscope, respiratory cytology took a new turn, as samples like bronchial brushings, broncho alveolar lavage could be collected from respiratory tract, providing a good yield of respiratory specimen. With this, the emphasis shifted from diagnosis of malignancy in potentially operable patients and confirmed metastasis, and cytology was made use as a first line diagnostic procedure with which crucial management decisions could be based [4,5]. Bronchoscopy provides direct visualization of the airways and permits more focused sampling of cells /tissue [6]

In our study, out of 35 cases of suspected malignancies, 24 (69%) were males and 11 were females with their ages ranging between 18 and 80 years, indicating the gap in tests done for male when compared to female. The prevalence of lung malignancies has been on rise and is the major cause of death due to cancer in males [4]

In our study, out of the 35 people on whom both the tests were performed, bronchoalveolar lavage and bronchial brushings had a sensitivity of 58% and 92% respectively, while the specificity was 100% in both.

In general, less differentiated lesions have more loosely cohesive cells in comparison to well differentiated lesions [3] and these exfoliated cells in bronchial cavity degenerate, losing its cytomorphological features to be classified as malignant and nonmalignant cells [3] In bronchoalveolar lavage, saline is instilled through the bronchoscope and wash samples are collected. If the procedure of the physician was not good enough, the specimen collected may be fewer and there may be lesser cytological evidence than assumed. Consequently, there is furthermore possibilities of increased false negative results. All these elements might influence the overall yield and the diagnostics value of bronchoalveolar lavage specimens. The cell yield is usually much better in bronchoalveolar lavage in peripheral lung lesions, as lavage reaches the distal bronchial units and samples out more than one bronchus at the same time [7,8]

Bronchial brushing sampling is done by directly visualizing the lesion using a bronchoscope and scrapping the surface to make smears [9]. This technique enables scrapping of surface containing cells that are not normally exfoliated and are difficult to dislodge from their surface and are subjected to degenerative changes. This increases the sample yield better compared to bronchoalveolar lavage specimens [3]. However, studies show that repeat bronchoalveolar lavage sampling improves its sensitivity, specificity and accuracy.

Our study is comparable with studies conducted by Shalinee rao et al [4], Dinesh et el [11], where it was concluded that bronchial wash cytology has comparably low sensitivity in detecting pulmonary lesions. However, bronchoalveolar lavage technique can be made use in patients with contraindications for biopsy.

4. CONCLUSION

This study compares the cytological efficacy of bronchoalveolar lavage and bronchial brushings in diagnosing malignancy of lung and correlates with the clinical diagnosis revealing that bronchial brush cytology has a superior diagnostic efficacy for bronchopulmonary lesions compared to Broncho alveolar Lavage.

REFERENCES:

1. Thoracic tumours / edited by WHO Classification of Tumours Editorial Board. Fifth edition. Lyon: International Agency for Research on Cancer, 2021
2. Shagufta Tahir Mufti, Ghadeer A. Mokhtar ; Diagnostic value of bronchial wash, bronchial brushing, fine needle aspiration cytology versus combined bronchial wash and bronchial brushing in the diagnosis of primary lung carcinomas at a tertiary care hospital. Biomedical Research 2015; 26 (4): 777-784

3. Gaur DS, Thapiyal NC, Kishore S, Pathak VP: Efficacy of bronchial alveolar lavage and bronchial brush cytology in diagnosing lung cancers. *J Cytol* 2007, 24:73-77
4. Shaline R et al. Bronchial brushing for the diagnosis of lung cancer. *Eur Respir Mon.* 2008; 12: 1-6
5. Apar Agarwal¹, Prakhar Sharma², Mahi Saluja³, Komal Lohchab⁴, Nitin Jain⁵ To Study the Efficacy of Bronchoalveolar Lavage, Bronchial Brush Cytology and Bronchial Biopsy in Diagnosing Lung Cancer. *International Journal of Contemporary Medical Research.* 2018;5(1):1-4.
6. Atkins KA. The diagnosis of bronchioloalveolar carcinoma by cytologic means. *Am J Clin Pathol* 2004;122:14-6
7. Pirozynski M. Bronchoalveolar lavage in the diagnosis of peripheral, primary lung cancer. *Chest* 1992;102:372-4.
8. Henderson AJ. Bronchoalveolar lavage. *Arch Dis Child* 1994;70:167-9.
9. Johnston WW, Elson CE. Respiratory tract. In: Bibbo M, editor. *Comprehensive cytopathology.* 2nd ed. Philadelphia: W.B. Saunders Company; 1997. p. 325-401.
10. William et al. The Bronchoscopic Diagnosis of Lung Cancer: A Prospective Correlation between the Bronchoscopic Appearances and Cytology and Biopsy Results. *J Broncho Inter Pulm.* 2000; 16-26.
11. Dinesh Reddy, Vaibhav Krishna, Nitish Gupta. Bronchoscopy in Lung Malignancies At Indian Rural centre. *J Dent Med Sci.* 2016; 92-96.