

# A Case Series Of Atrial Myxomas – A Tertiary Care Centre Experience

## Abstract

**Aim** - The current study aims at highlighting the clinical presentation, echocardiographic profile and histopathological details of the four cases of cardiac myxoma which we had encountered in our institution within a period of one year and to identify a relationship between the clinical behaviour and the histopathological picture.

**Results** - Among the four cases 2 were males and 2 were females and their ages ranged from 36 to 49 years. Two of the four patients presented with chest pain and palpitations , one with dyspnoea and the other case presented with recurrent stroke. Three of the cases were located in the left atrium while one case was in the right atrium. The histopathological examination of all the cases showed stellate , round and polygonal cells surrounded by abundant myxoid stroma. There was no histopathological correlation between the different clinical presentations or locations of the myxomas.

**Conclusion** - Although histopathological examination is necessary along with echocardiography to make a diagnosis of cardiac myxoma , there is no correlation between the different clinical presentation , site and the histopathological examination.

**Key words:** *Atrial myxoma, cardiac tumours, primary tumours, cardiac myxoma*

## Introduction

Primary tumours of the heart are extremely rare when compared to metastatic cardiac tumours and have an incidence rate of 1.38 per 100,000 people every year. <sup>(1)</sup> Among the primary neoplasms, cardiac myxomas are the most common and attribute to 50% of the cases. The term myxoma is the Latin translation of the Greek word 'muxa' which means mucus. <sup>(2)</sup> Cardiac myxomas are benign , slow proliferating neoplasms and they may be sporadic or familial. Majority of the cardiac myxomas are sporadic and only 7 % are familial. <sup>(3)</sup> The incidence is higher in females as compared to males. <sup>(4)</sup> The most common site involved is the left atrium where 75%-80% of the cardiac myxomas arise , 10-20% arise in the right atrium and the remaining 5- 10% arise in either of the ventricles of both the atria of the cardiac chambers. Macroscopically the cardiac myxomas can be of two types , polypoid and papillary . <sup>(5)</sup> The histopathological diagnosis of a cardiac myxoma requires the presence of myxoma cells, sometimes referred to as the lepidic cell. The arrangement of the cells may be in clusters, single cells or may even form capillary like channels. <sup>(6)</sup>

There have been many studies in which large case series of myxomas have been reported, however there have been very few studies in India in which the correlation between the clinical presentation, site and the histopathological examination has been done. We present a retrospective study of the cases of cardiac myxoma in our institution over one year and the relationship between the clinical presentation , echocardiographic profile, location and the histopathological characteristics and its significance have been studied. In our study, all the echocardiographs were

taken using the Philips Affiniti 30 Ultrasound Machine and the cardiac biopsies have been taken using a biopptome.

## Case presentation

### Case 1

A 47 year old female presented with history of recurrent stroke. Echocardiography showed a well circumscribed pedunculated tumour in the left atrium attached to the left atrial aspect of the interatrial septum and protruding through the mitral valve into the left ventricle. The size of the tumour was 3.4 x 4 cm. (Figure 1) A biopsy from the lesion showed stellate cells, round and polygonal cells surrounded by abundant myxoid stroma, admixed with the presence of thrombi. The arrangement of the cells were in cords and singly scattered and few cells were also seen around the small blood vessels and was histopathologically confirmed as cardiac myxoma. (Figure 2)

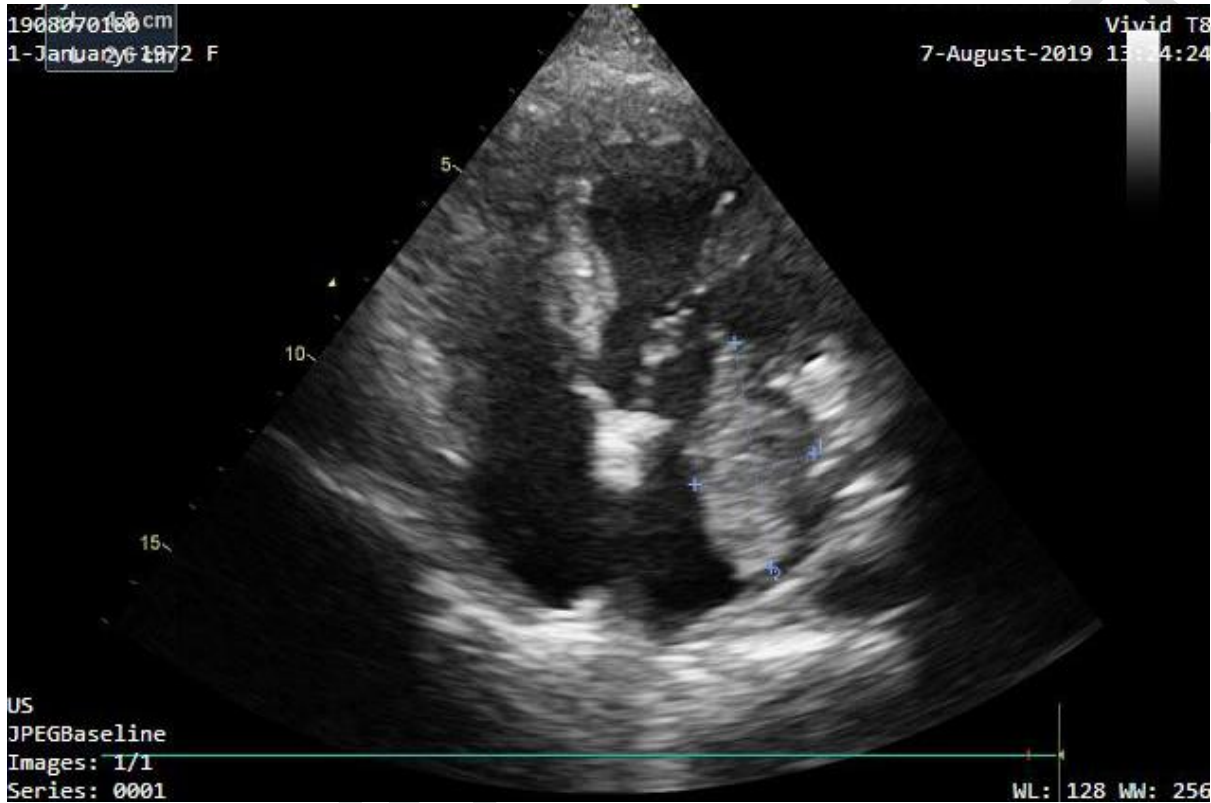


Figure 1 – Echocardiographic profile of case 1

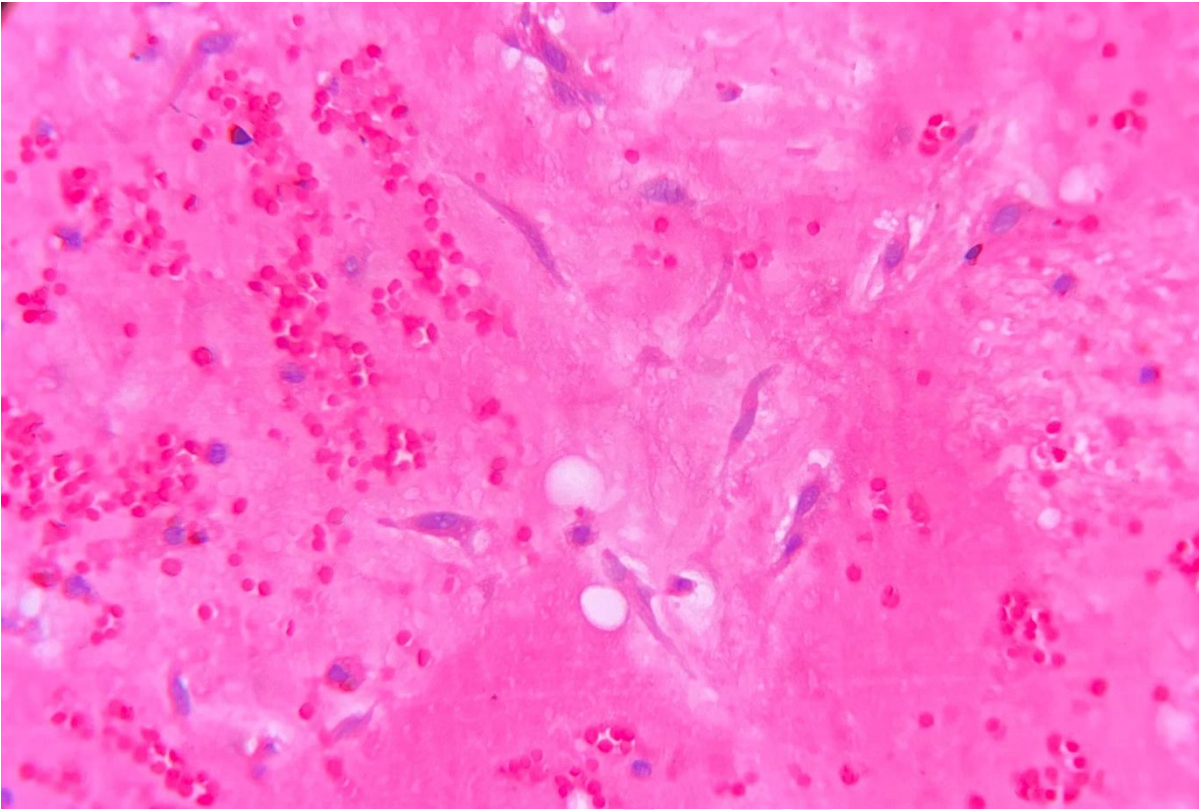


FIGURE 2 – Microscopic picture showing stellate cells and polygonal cells with abundant myxoid material surrounding it.

### Case 2

A 47 year old female presented with dyspnoea and recurrent fever and malaise . She had a distinct tumour plop on auscultation and she experienced severe dyspnoea each time on attaining the upright posture. The echocardiography showed a myxoma arising from left atrial aspect of the interatrial septum and it occupied almost the entire left atrial cavity.. The tumour was of varying echogenicity and measured about 3.9cm x 4.2cm. (Figure 3)The histopathological features were same as that of the first case with stellate, (Figure 4) round and polygonal cells arranged in cords and scattered singly surrounded by abundant myxoid stroma, admixed with thrombi and was histopathologically confirmed as cardiac myxoma.

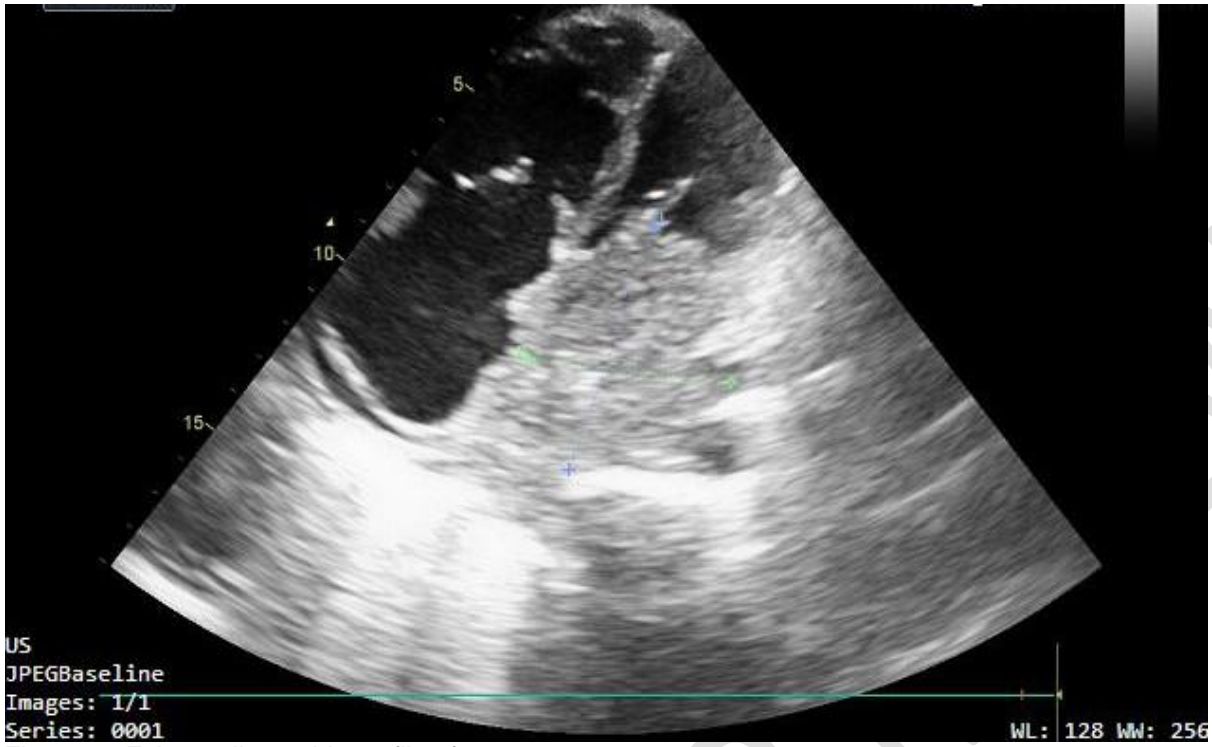


Figure 3 - Echocardiographic profile of case 2

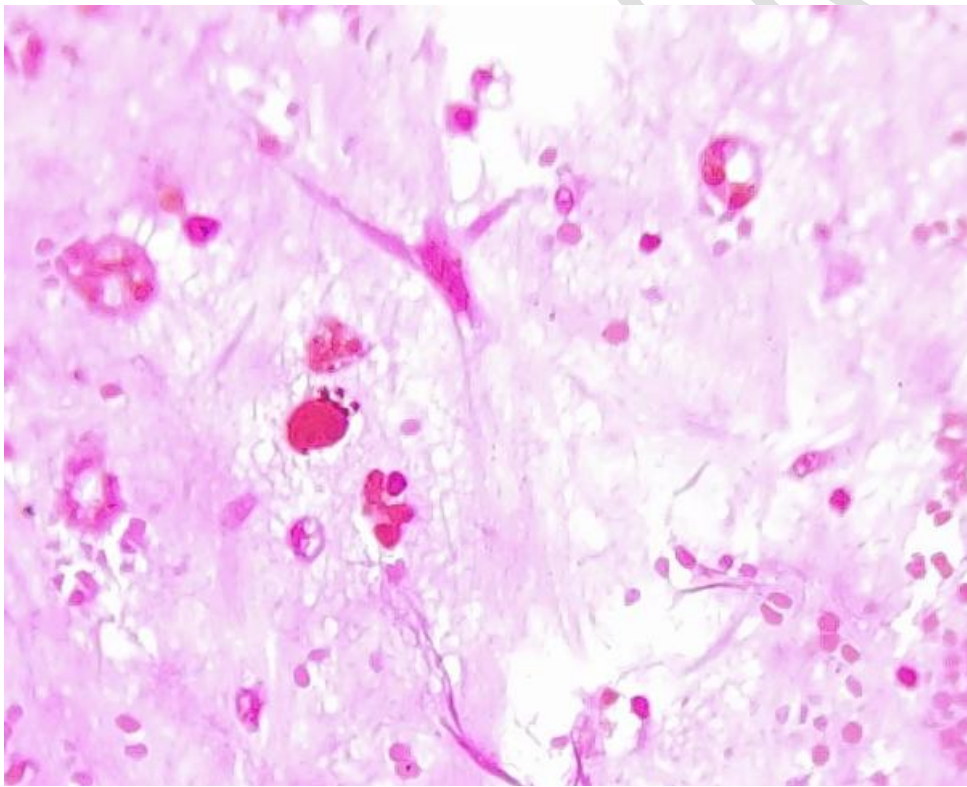


Figure 4 – Histopathologic examination showing a stellate cell in cardiac myxoma

### Case 3

A 36 year old male came with symptoms of chest pain and palpitations. On echocardiography , it was a frond like growth attached to the interatrial septum on its left atrial aspect and also to the posterior wall of the left atrium. The tumour measured about 2.4cm x 2.9cm. It did not protrude through the mitral valve. (Figure 5) The biopsy showed predominantly myxomatous material with interspersed , elongated fusiform , polyhedral and stellate cells, showing vacuolated eosinophilic cytoplasm with elongated to rounded uniform nuclei with hemosiderin laden macrophages thus histopathologically confirmed as cardiac myxoma.

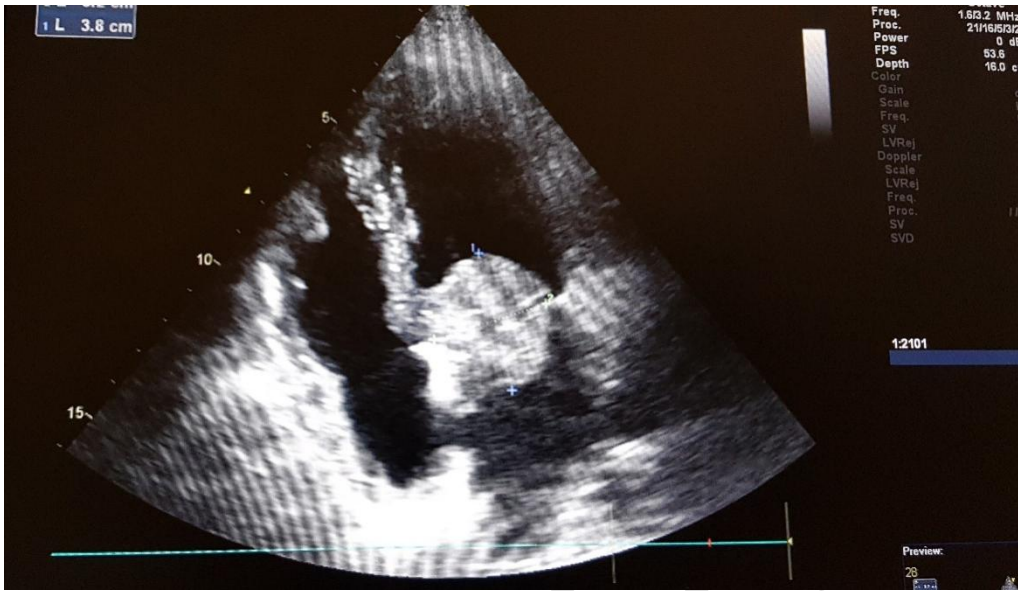

Figure 5– Echocardiographic profile of case 3

#### Case 4

A 39 year male came with left sided chest pain and palpitations. The echocardiographic findings showed a right sided atrial myxoma. A biopsy was taken which showed stellate cells, round and polygonal cells with abundant myxoid stroma admixed with thrombi. The cells were arranged in cords, syncytial pattern and single scattered. The histopathological diagnosis was given as cardiac myxoma. (Figure 6)

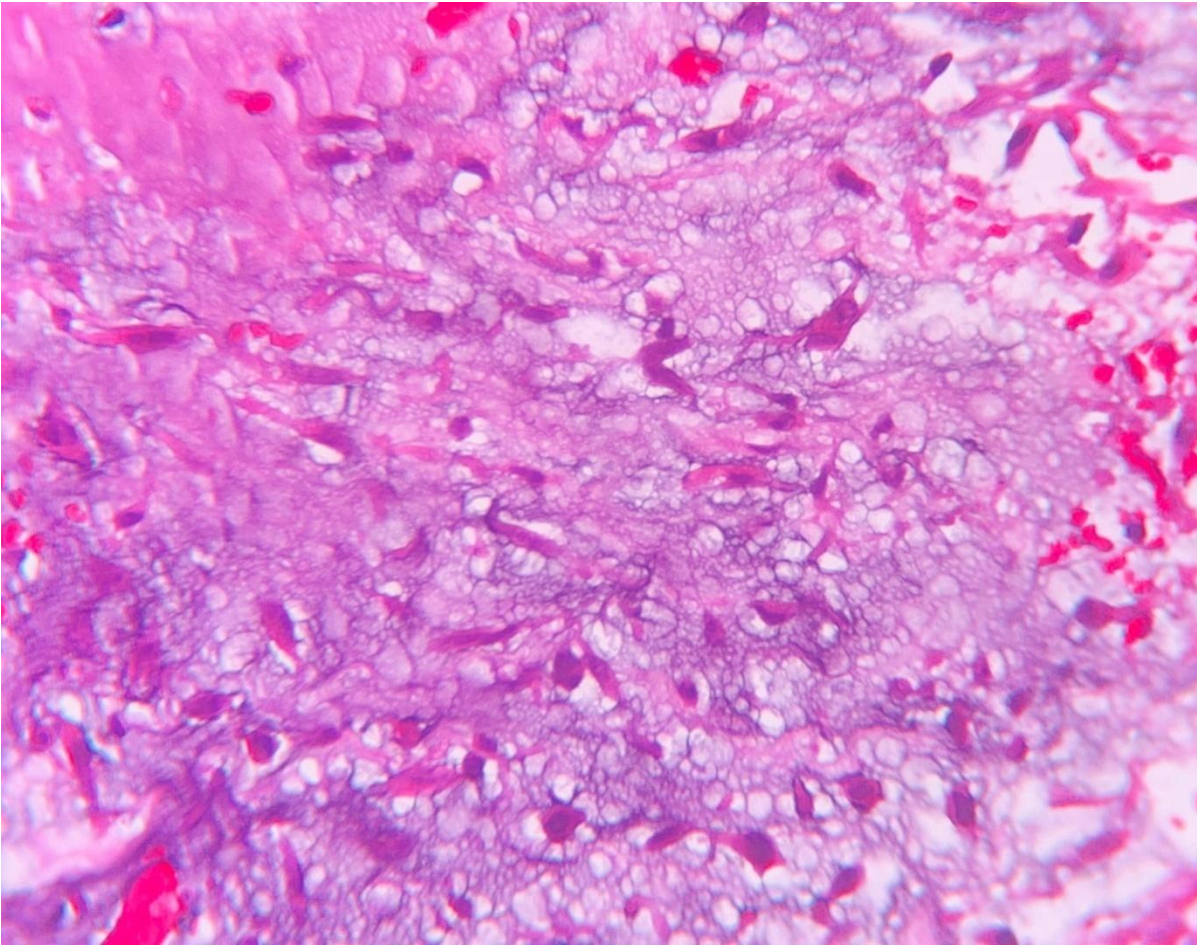


FIGURE 6 – Microscopic picture showing stellate cells and few polygonal cells with abundant myxoid material surrounding it

All these myxomas were clearly picked up in the parasternal long axis, short axis and apical four chambers. All the patients underwent surgery under cardiopulmonary bypass with a medial sternotomy incision. A simple resection including the endocardium and the pedicle was done. The excised area was directly closed without the need for a patch. None of the patients required a mitral valve replacement. Post operative atrial fibrillation was seen in one of the patients which subsided with intravenous Amiodarone.

## Discussion

Cardiac myxomas represent about 0.25% of all the cardiac diseases, 50% of all cardiac neoplasms and about 50-85% of all benign ones.<sup>(7)</sup>

The origin of these tumours are considered to be from multipotent mesenchymal cells of the fossa ovalis that persist as embryonal residues during the septation of heart.<sup>(8)</sup> Few theories also suggest that these tumours arise from cardiomyocyte progenitor cells, subendothelial vasoformative reserve cells or primitive cells that reside in the fossa ovalis and surrounding endocardium or endocardial sensory nerve.<sup>(9)</sup>

There were an equal number of males and females affected with cardiac myxoma in our study. Most of the studies showed a female predominance as in the study by Keeling et al.<sup>(10)</sup> However there were also some studies where there was a male predominance as in the study done by Khan et al.<sup>(11)</sup>

**Table 1. Concise literature review of cardiac myxoma cases with regard to clinical presentation and histopathology features**

S.No.	Study done by	Clinical features	Histopathological features
1.	Anvari et al <sup>(19)</sup>	Dyspnoea (63%), chest pain (37%), neurological symptoms (5%)	myxoid stroma with satellite cells, and multinucleated cells Scattered lymphocytes, except in 1 papillary tumor, but plasma cells were found in 1 papillary and 14 solid tumors. Neutrophils were detected in 1 papillary and 9 solid tumors. Three solid tumors revealed mineralized circumscribed nodules (Gamma-Gandy bodies)
2.	Wang et al <sup>(6)</sup>	Dyspnoea	tumor cells of solid type have a tendency to form vasoforming structure, cords or rings. However, the morphological features had no correlation with the clinical presentations.
3.	Geetha k et al <sup>(13)</sup>	Dyspnoea, palpitation	Stellate single cells, vasoformative area, cord like pattern, foci of hemorrhage

Cardiac myxomas occur most commonly between 30 to 70 years of age.<sup>(12)</sup> In our study, the age of the patients ranged from 36 to 49 years. Some studies have shown a wider range of age of patients with cardiac myxoma as in the study by Rahman et al where the age ranged from 17 to 76 years.<sup>(13)</sup>

The cardiac myxomas can arise in any one of the chambers but are most common in the left atrium. Three of the cases were in the left atrium and one case was located in the right atrium which was similar to the study done by Geetha K et al.<sup>(14)</sup> In the study done by Kim et al there were more cases of cardiac myxoma in the right atrium as compared to the left atrium.<sup>(15)</sup>

Most of the patients present with one or more symptoms of the classic cardiac triad which comprise of symptoms and signs due to obstruction, signs of systemic embolization or systemic constitutional symptoms, or a combination of these.<sup>(16)</sup> Solid tumours cause obstruction of the pulmonary or systemic venous drainage, mitral stenosis, dyspnoea and arrhythmias. Papillary cardiac myxomas cause central or peripheral embolization symptoms, such as strokes, embolisms and low haemoglobin due to fragmentation of the tumour and clot formation.<sup>(12)</sup> In our study two of our cases had chest pain with palpitations, one had dyspnoea and one had a history of recurrent stroke.

Myxomas can be sporadic or familial and in our study, all the cases were sporadic cases. The familial cardiac myxomas are often multiple, recurrent and right sided as compared to sporadic myxomas. Familial cardiac myxomas are seen in association with Carney Complex which is an autosomal dominant syndrome. In sporadic cardiac myxomas no single gene defect has been identified, although structural rearrangement in PRKAR1A has been identified in few cases.<sup>(17)(18)</sup>

Diagnosis of cardiac myxoma is most commonly done with the help of two dimensional echocardiography.

Transoesophageal echocardiography is more sensitive than transthoracic echocardiography. However histopathology is the gold standard to diagnose cardiac myxomas as they can be differentiated from an intramural thrombus, vegetation or a metastatic tumour only with the help of the microscopic examination.

The histomorphology of myxomas can be variable but the most commonly identifiable in our study has been a neoplasm composed of stellate cells, round cells and polygonal cells in abundant myxoid stroma with hemosiderin laden macrophages. In our study the arrangement of the cells were in three different patterns – clusters, singly scattered and around the blood vessels. These patterns did not have any clinical or prognostic significance which was similar to the study by Wang JG et al.<sup>(6)</sup> No mitosis was noted in any of the cases. About 20% of the cases may be calcified but none of the cases in our study showed calcification.<sup>(17)</sup> Glandular differentiation in myxoma was not present in any of our cases. It is very rare and has been reported in cases with Carney's complex.<sup>(19)</sup>

## Conclusion

Our study constituted a series of four cases of cardiac myxoma over a span of one year, which had different clinical presentations and all the myxomas had a similar histopathological picture. This study proves that histopathology can only be used for diagnostic purpose and has no correlation with the clinical presentation or with the prognosis except in the case of malignant transformation.

## References

1. Cresti A, Chiavarelli M, Glauber M, Tanganelli P, Scalese M, Cesareo F, Guerrini F, Capati E, Focardi M, Severi S. Incidence rate of primary cardiac tumors: a 14-year population study. *Journal of cardiovascular medicine*. 2016 Jan 1;17(1):37-43.
2. Onubogu U, West B, Orupabo-Oyan B. Atrial myxoma: a rare cause of hemiplegia in children. *Cardiovascular journal of Africa*. 2017 Sep;28(5):e1.
3. Gošev I, Paić F, Đurić Ž, Gošev M, Ivčević S, Jakuš FB, Biočina B. Cardiac myxoma the great imitators: comprehensive histopathological and molecular approach. *International journal of cardiology*. 2013 Mar 20;164(1):7-20.
4. Oliveira R, Branco L, Galrinho A, Abreu A, Abreu J, Fiarresga A, Mamede A, Ramos R, Leal A, Pinto E, Fragata J. Cardiac myxoma: a 13-year experience in echocardiographic diagnosis. *Revista portuguesa de cardiologia: orgão oficial da Sociedade Portuguesa de Cardiologia= Portuguese journal of cardiology: an official journal of the Portuguese Society of Cardiology*. 2010;29(7-8):1087-100.
5. Bjessmo S, Torbjörn Ivert MD. Cardiac myxoma: 40 years' experience in 63 patients. *The Annals of thoracic surgery*. 1997 Mar 1;63(3):697-700.
6. Wang JG, Li YJ, Liu H, Li NN, Zhao J, Xing XM. Clinicopathologic analysis of cardiac myxomas: seven years' experience with 61 patients. *Journal of Thoracic Disease*. 2012 Jun 1;4(3):272.
7. Hasan M, Abdelmaseih R, Faluk M, Chacko J, Nasser H. Atrial Myxoma, a Rare Cause of Sudden Cardiac Death: A Case Report and Review of Literature. *Cureus*. 2020 Jan;12(1). Rahman MT. PW311 Clinical And Echocardiographic Profile of Cardiac Myxomas. *Global Heart*. 2014;1(9):e321
8. Amano J, Kono T, Wada Y, Zhang T, Koide N, Fujimori M, Ito KI. Cardiac myxoma: its origin and tumor characteristics. *Annals of Thoracic and Cardiovascular Surgery*. 2003 Aug 1;9(4):215-21
9. Keeling IM, Oberwalder P, Anelli-Monti M, Schuchlenz H, Demel U, Tilz GP, Rehak P, Rigler B. Cardiac myxomas: 24 years of experience in 49 patients. *European journal of cardio-thoracic surgery*. 2002 Dec 1;22(6):971-7.
10. Khan MS, Sanki PK, Hossain MZ, Charles A, Bhattacharya S, Sarkar UN. Cardiac myxoma: A surgical experience of 38 patients over 9 years, at SSKM Hospital Kolkata, India. *South Asian journal of cancer*. 2013 Apr;2(2):83.

11. Demir M, Akpınar O, Acartürk E. Atrial myxoma: an unusual cause of myocardial infarction. *Texas Heart Institute Journal*. 2005;32(3):445.
12. Rahman MT, Ali MZ, Kabir MH, Azam SA, Majumder AA, Rahman A, Haque SA. Clinical profile of cardiac myxoma: 11 years experience of 90 cases. *Bangladesh Heart Journal*. 2016 Dec 12;31(1):18-22.
13. Vani M. Cardiac myxoma-2 years experience at a tertiary care center. *International Journal of Research in Medical Sciences*. 2017 Mar;5(3):1107.
14. Kim CH, Dancer JY, Coffey D, Zhai QJ, Reardon M, Ayala AG, Ro JY. Clinicopathologic study of 24 patients with primary cardiac sarcomas: a 10-year single institution experience. *Human pathology*. 2008 Jun 1;39(6):933-8.
15. Pinede L, Duhaut P, Loire R. Clinical Presentation of Left Atrial Cardiac Myxoma. A Series of 112 Consecutive Cases. *Medicine (Baltimore)* 2001; 80(3):159-72
16. Burke AP, Virmani R. Cardiac myxoma: a clinicopathologic study. *American journal of clinical pathology*. 1993 Dec 1;100(6):671-80.
17. Fogt F, Zimmerman RL, Hartmann CJ, Brown CA, Narula N. Genetic alterations of Carney complex are not present in sporadic cardiac myxomas. *International journal of molecular medicine*. 2002 Jan 1;9(1):59-60.
18. Goldman BI, Frydman C, Harpaz N, Ryan SF, Loiterman D. Glandular cardiac myxomas histologic, immunohistochemical, and ultrastructural evidence of epithelial differentiation. *Cancer*. 1987 May 15;59(10):1767-75.
19. Anvari MS, Boroumand MA, Karimi A, Abbasi K, Ahmadi H, Marzban M, Movahedi N, Moshtaghi N, Salehiomran A, Davoodi S, Shirzad M. Histopathologic and clinical characterization of atrial myxoma: a review of 19 cases. *Laboratory Medicine*. 2009 Oct 1;40(10):596-9.