

Title:

**LOWER INCISOR POSITIONS IN DIFFERENT
MALOCCLUSIONS AND FACIAL PATTERN**

Abdul Jabbar¹ , Saba² , Ramesh Lal^{3*} , Amber Farooq⁴ , Uzma Bashir⁵, Nadeem Hussain⁶

Abstract:

Aims:

The position of lower incisor has been of significant concern when seeking orthodontic treatment plan, it has been recognized as one of diagnostic key and play an important in the development of normal occlusion and facial pattern. This study was aimed at the determination of lower incisor position and its possible association with different sagittal malocclusions and facial patterns.

Study Design: Descriptive Cross-sectional Study

Place and Duration of Study: Department of Orthodontics Institute of Dentistry Liaquat University Medical and Health Sciences (LUMHS) Jamshoro between June 2019 to July 2020.

Methodology: Ninety-seven pre-treatment lateral cephalometric radiographies were taken, and they were classified sagittally into skeletal class I, II and III, and vertically into normodivergent, hyperdivergent and hypodivergent facial pattern using ANB and SNMP, respectively. Lower incisor position was assessed by means of FMIA and IMPA. One way analysis of variance (ANOVA) was applied to check any association between lower incisor position and sagittal malocclusion and facial pattern. *P* value of 0.05 was considered statistically significant.

Results: The study sample consisted of 97 patients. The mean age of the patients was 25.55 SD \pm 3.93. The mean SNMP value was 28.84 SD \pm 7.354 and mean ANB value 4.809 SD \pm 3.85. Mean Incisor position based on IMPA was 98.598 SD \pm 9.413 and FMIA 54 SD \pm 9.995. Intra and interobserver reliability was assessed with intraclass correlation coefficient values ranging between 0.825 and 0.990 respectively. The ANOVA test results showed significant relationship between the sagittal malocclusion and incisor position with *P* value .036. The Bonferroni analysis indicated that statistically significant association existed in term of lower incisor position between Class II and Class III malocclusion with *P* value .047. Test results further indicated that there is no significant difference in the position of lower incisor in relation to facial pattern with *P* value .355.

Conclusions: Statistically significant association was found between lower incisor position with respect to the sagittal malocclusion. **However, no significant association was found between facial pattern and lower incisor position.**

Key words: Lower incisor, cephalometric analysis, facial patterns, facial biotype, skeletal malocclusions.

¹BDS, FCPS, FFDRCSI, Associate Professor, Institute of Dentistry; LUMHS, Jamshoro.

² BDS, MSc, Orthodontics, Institute of Dentistry; LUMHS, Jamshoro.

^{3*} BDS, M.sc, MBE, FCPS Resident, Lecturer, Institute of Dentistry LUMHS, Jamshoro.

⁴BDS, FCPS, Associate Professor, Abbottabad international Dental College Islamabad

⁵ BDS, M.sc, Senior Lecturer, Institute of Dentistry LUMHS, Jamshoro.

⁶BDS, FCPS, Institute of Dentistry; LUMHS, Jamshoro.

INTRODUCTION:

At the time of Orthodontic diagnosis and treatment planning, lower incisor position holds primary importance. The position of lower incisor is key to achieve good facial aesthetics and have marked functional effects i.e., resisting incisor over eruption, providing harmony and functionality to TMJ, allowing appropriate anterior guidance and protrusive movements, to protect organic occlusion.^{1,2} It has been proven that within dentofacial complex a compensatory mechanism exists that attempt to maintain a proportional and harmonious facial pattern, when either maxilla or mandible deviates from normal growth, then remaining orofacial structures responds to mask this discrepancy.³⁻⁵ In this regard dental compensation acts as natural camouflage to sagittal and vertical discrepancies to achieve normal incisor relationship. Studies have shown that lower incisor inclination varies in different malocclusion in anteroposterior and vertical facial pattern.⁵⁻⁷ In class III malocclusion the lower incisors are typically retroclined and proclined in Class II malocclusion. In vertical dimension the compensation is attained by thorough incisor eruption.⁸⁻¹⁰

This is important to assess the position and inclination of incisors as there are certain limits to move teeth according to facial profile¹¹. Labial movement of lower incisors could be a risk for the progressive bone loss and development of gingival recession.¹²

Upper and lower anterior teeth should be in perpendicular/upright position on basal bone to cortical boundaries for better aesthetics and stability for orthodontic tooth movement.¹³ Previous studies have claimed that skeletal growth pattern correlates with lower incisor inclination and crowding which is a factor that has been considered during treatment planning and retention in orthodontic patients. According to literature hyper divergent cases showed the highest percentage of lower incisor crowding (92.6%) followed by hypo divergent profiles.¹⁴

To evaluate the precise position of the lower incisor root apex within the alveolar bone is essential before orthodontic treatment¹², hence this study is aimed at evaluation of lower incisor position in different malocclusion in sagittal dimension and vertical facial pattern.

MATERIAL & METHODS:

This cross-sectional study was conducted at Outpatient department of Orthodontics, Institute of dentistry, Liaquat University of Medical and Health Sciences Jamshoro/Hyderabad following approval from ethical review committee LUMHS. Nonprobability consecutive sampling technique was employed. The included sample consisted of pretreatment lateral cephalometric radiograph from

both male and female patients (age range 14-28 years), seeking orthodontics treatment with full dentition except for third molar. Patients with previous history of orthodontic or orthognathic treatment, or a trauma to maxillofacial region and developmental anomaly involving teeth and orofacial structures were excluded.

To ensure the high degree of accuracy in obtaining cephalogram following measures were taken: All pretreatment lateral cephalograms were obtained on the same machine with patient's head fixed with X-ray source at distance of 150 cm and patients' midsagittal plane to film distance of 15 cm, with patient's Frankfurt horizontal plane parallel to the floor. Teeth were occluded in centric occlusion and lips were kept in relaxed position.

Each radiograph was traced manually with lead pencil of 0.3 mm tip diameter on a standard translucent acetate sheet of 8 x10 inch which was placed on standard illuminated view box. Following cephalometric parameters were measured and shown in figure No:1

Anteroposterior Skeletal relationship:

ANB: Angle formed between point A, N and B, determining the anteroposterior jaw relationship.

Facial Pattern (Vertical Skeletal Relationship):

SNMP: Angle between Sella to Nasion and Mandibular plane.

Mandibular Incisor position.

IMPA: Angle between mandibular plane (Me-Go) and lower incisor.

FMIA: Angle between Frankfurt plane (Po-Or) and lower incisor.

All the enrolled patients were classified anterioposteriorly into skeletal Class I, II and III, and vertically into normodivergent, hyperdivergent and hypodivergent facial pattern.

To ensure reliability of readings, ten lateral cephalometric radiographs were selected randomly and evaluated independently by two investigators on two different occasions at the interval of 2-weeks. Data were entered and analyzed using Statistical Package for the Social Sciences (SPSS) software, Version 21 (Armonk, NY: IBM Corp.) for Windows. The intra-class correlation coefficient (ICC) was applied for the reliability of measurements. Descriptive statistics, including the frequency, mean and standard deviation for each variable were calculated and presented. One way analysis of variance (ANOVA) was applied to check any association between lower incisor position and sagittal malocclusion and facial pattern. **P** value of < 0.05 was considered significant.

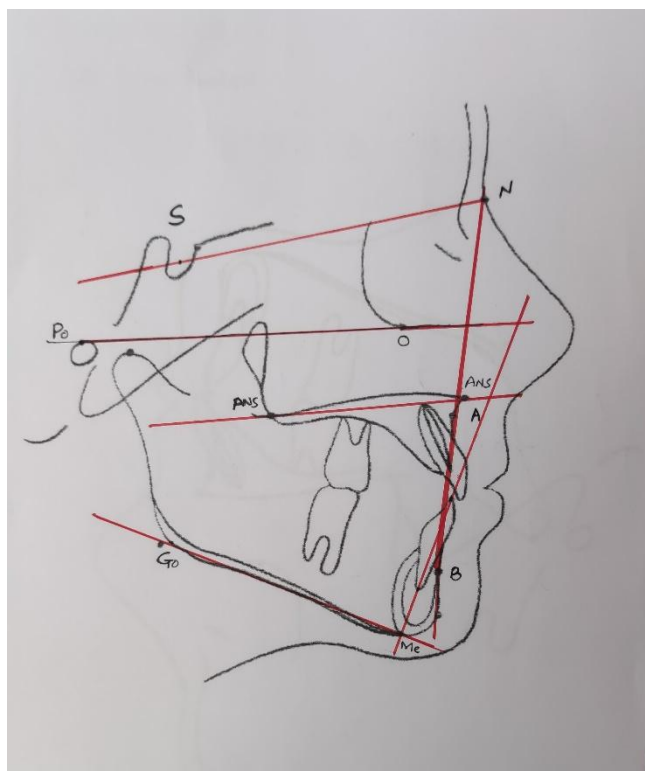


Figure No: 1 Cephalometric landmarks and measurement used.

Results:

The study sample consisted of 97 patients; 29 were males (29.9%) and 68 were females (70.1%). The mean age of the patients was 25.55 SD \pm 3.93. Of the 97 patients, 60 patients were class II malocclusion which accounted 61.9% of total sample size while 28 had Class II sagittal malocclusion. Based on SNMP 52 patients out of 97 presented with normodivergent facial pattern that accounted 53.6% of all the study participants while 34 and 11 were hypodivergent and hyperdivergent respectively. The Mean SNMP value was 28.84 SD \pm 7.354 and mean ANB value 4.809 SD \pm 3.85. Mean Incisor position based on IMPA was 98.598 SD \pm 9.413 and FMIA 54 SD \pm 9.995. Descriptive statistics of all study variable and each subgroup in Sagittal malocclusion, vertical facial pattern and lower incisor position of whole sample is presented in Table No: 1 and 2 respectively.

Intra and interobserver reliability was assessed using intraclass correlation coefficient. The values attained were ranging between 0.825 for intra observer and 0.990 for interobserver, which shows good repeatability for all cephalometric parameters measured in this study.

Various comparisons were made using ANOVA test to determine any association between incisor position and sagittal malocclusion and facial pattern. The test results showed significant relationship between the sagittal malocclusion and incisor position with *P* value .036. The Bonferroni analysis was applied and indicated that statistically significant association existed in term of lower incisor position between Class II and Class III malocclusion *p* value .047. Test results further indicated that there is no

significant difference in the position of lower incisor in relation to facial pattern with p value .355. The detail of all comparison using ANOVA is shown in Table No: 3.

Table NO: 1. Descriptive statistics of study variables used in this study

N= 97

Study Variable	Frequency	Mean – SD
Sagittal Malocclusion		ANB= 4.809 ± 3.85
Class I	28 (28.9%)	
Class II	60 (61.9%)	
Class III	09 (9.2%)	
Facial Pattern		SNMP=28.84 ± 7.354
Normodivergent	52(53.6%)	
Hyperdivergent	11 (11.3%)	
Hypodivergent	34 (35.1%)	
Incisor Inclination		IMPA= 98.598 SD ± 9.413 FMIA= 54.00 SD ± 9.995
Normal	28 (28.9%)	
Proclined	63 (64.9%)	
Retroclined	06 (6.2%)	

Table No: 2 Mean value of incisor inclination in Sagittal malocclusion and Facial Pattern

Parameter	Mean incisor Inclination based on IMPA Overall Mean: 98.598 SD ± 9.413	Mean incisor Inclination based on FMIA Overall Mean: 54.00 SD ± 9.995
Class I	97.089 SD ±9.337	55.536 SD ±8.395
Class II	100.242 SD ±8.900	52.242 SD ±10.457
Class III	92.333 SD ± 10.606	60.944 SD ±8.353
Hyperdivergent	97.091 SD ± 11.30	51.864 SD ±12.343
Hypodivergent	97.118 SD ±9.885	57.29 SD ±9.474
Normodivergent	98.885 SD ±8.653	52.298 SD ±9.414

Table:3 Relation of Incisor Position with Sagittal Malocclusion and Facial Pattern (ANOVA)

Variable	Sagittal and Vertical Class	Comparison	Mean Difference	P value
Incisor Inclination	Class – I	Class II	-3.1524	.41
		Class III	4.7560	.54
	Class II	Class I	3.1524	.41
		Class III	7.9083	.046
	Class III	Class I	-4.7560	.539
		Class II	-79083	.046
	Hyperdivergent	Hypodivergent	-.0267	1.00
		Normodivergent	-2.7937	1.00
Hypodivergent	Hyperdivergent	.0267	1.00	
	Normodivergent	-2.7670	.557	
Normodivergent	Hyperdivergent	2.9737	1.00	
	Hypodivergent	2.7670	.557	

Discussion

The position of the lower incisors has always been considered a major deciding factor in treatment planning and one of the key treatment objectives, to achieve the lower incisor stability. Several factors play a role in attaining lower incisor stability.⁴ Numerous studies have proven that proclined lower incisors at the end of treatment, have always been considered an undesirable side effect of orthodontic treatment and is disadvantageous for two main reasons (1) it can lead to negative periodontal ramifications and (2) can result in reduced stability. A reduction in stability increases the potential for rebound. In this cross-sectional study, the pretreatment lateral cephalometric radiograph was used to assess the position of mandibular incisor in different malocclusion in sagittal dimension ie Class I, II and III and vertical facial pattern ie hyperdivergent, hypodivergent and normodivergent. The relationship between the study variables was assessed by means of one-way analysis of variance (ANOVA). The presents study reveals significant association between lower incisor position and sagittal malocclusion. The teeth were proclined and retroclined in class II and III malocclusion respectively. In this regard the results were consistent with the study conducted Azmina Salaman et al.¹⁵ In another study conducted by Schulhof et al.¹⁶ on 60 patients found significant association between incisor inclination and ANB. Asli Baysal et al assessed lower incisor position in class II and I Malocclusion with Cone beam computed tomography, they observed that lower incisors were more protrusive in class II than class I malocclusion.³

Regarding the relationship of lower incisor position and facial pattern, literature seems to be divided. Our study results show statistically no significant relationship with vertical facial pattern and incisor position which contradicts to the results of other authors, this possibly could be attributed to heterogeneity in subgroups based on SNMP. Since in our study normodivergent were 52 and hyperdivergent facial pattern only 11 patients, hence this non stratification of the subgroups based on facial pattern could be the reason behind the lack of agreement in literature with the other authors. Cecile Gutermann et al.⁶ revisited incisor inclination and they revealed that hyperdivergent facial pattern is related to retroclined lower incisor and having negative correlation with divergence of jaw. A study by Handelman et al.¹⁷ found that long face hyperdivergent facial pattern with thin alveolus is frequently associated with bimaxillary proclination which is not in agreement with our results. In another study conducted by Manea et al.¹⁸ reveals positive relationship between incisor position and facial growth pattern. Similar results were also observed by Azamina Salaman et al.¹⁵ and Nuria Molina-Berlanga et al.¹²

Conclusion:

There is statistically significant association between lower incisor position and sagittal class of malocclusion. Though the results of study could not find statistically significant link between vertical facial pattern and lower incisors yet the frequency of proclination was greater in hyperdivergent facial pattern.

References:

1. Hernández-Sayago E, Espinar-Escalona E, Barrera-Mora JM, Ruiz- Navarro MB, Llamas-Carreras JM, Solano-Reina E. Lower incisor position in different malocclusions and facial patterns. *Medicina oral, patología oral y cirugía buccal*. 2013;18(2):343-52.
2. Shigenobu N, Hisano M, Shima S, Matsubara N, Soma K. Patterns of dental crowding in the lower arch and contributing factors: a statistical study. *The Angle Orthodontist*. 2007;77(2):303-10.
3. Baysal A, Ucar FI, Buyuk SK, Ozer T, Uysal T. Alveolar bone thickness and lower incisor position in skeletal Class I and Class II malocclusions assessed with cone-beam computed tomography. *The Korean Journal of Orthodontics*. 2013;43(3):134-40.
4. Maniyar M, Kalia A, Hegde A, Gautam RG, Mirdehghan N. Lower incisor dentoalveolar compensation and symphysis dimensions in class II and class III patients. *International Journal of Dental and Medical Specialty*. 2014;1(2):20-29.
5. Allais D, Melsen B. Does labial movement of lower incisors influence the level of

- the gingival margin? A case-control study of adult orthodontic patients. *The Eur J Orthod.* 2003;25(4):343-52.
6. Gutermann C, Peltomaki T, Markic G, Hanggi M, Schatzle M, Signorelli L, Patcas R. The inclination of mandibular incisors revisited. *The Angle Orthod.* 2013 Jul 18;84(1):109-19.
 7. Birla S, Mathur A, Thakur A, Toshniwal NG. Preplanning contemporary incisor positioning using inclinometer: A clinical and cephalometric study. *Journal of Indian Orthodontic Society.* 2014;48(4):217-223.
 8. Ponraj RR, Korath VA, Nagachandran DV, Param Eswaran RA, Raman P, Sunitha C, Khan N. Relationship of Anterior Alveolar Dimensions with Mandibular Divergence in Class I Malocclusion—A Cephalometric Study. *Journal of clinical and diagnostic research: JCDR.* 2016;10(5):29-38.
 9. Rasul G, Khan AA, Qiam F. The role of vertical parameters in the development of lower incisor crowding amongst patients. *PODJ.* 2012 Aug;32(2):108-115.
 10. Wijaz, HA Raza, G Rasool. Correlation between mandibular base length and dental crowding in patients with class II malocclusion. *PODJ.* 2015;7(1):35-40.
 11. Al-Khateeb, S. N., Al Maaitah, E. F., Abu Alhajja, & Badran, S. Mandibular symphysis morphology and dimensions in different anteroposterior jaw relationships. *The Angle Orthod.* 2014;84(2):304–309.
 12. Molina-Bezlang N, et al. Lower incisor dentoalveolar compensation and symphysis dimensions among Class I and III malocclusion patients with different facial vertical skeletal patterns. *Angle Orthod.* 2013;83:948-955.
 13. A Jabbal, M Cobourne, N Donaldson et al. Assessing lower incisor inclination change: a comparison of four cephalometric methods. *Eur j Orthod.* 2016;4:184-189.
 14. Yu Q, Pan X, G Ji, G Shan. The Association between Lower Incisal Inclination and Morphology of the Supporting Alveolar Bone — A Cone-Beam CT Study. *Int j Oral Sci.* 2009;1(4):217-223.
 15. Azmina S, Aisha K, Sarah Q, Owais K D. Association of symphyseal morphology with lower incisor inclination in sagittal and vertical growth patterns. *PODJ.* 2020;12(1):18-23
 16. Schudy ff. The rotation of the mandible resulting from growth: Its Implications in orthodontic treatment. *Angle Orthod.* 1965;35:36-50.
 17. Handelman. The anterior alveolus: its importance in limiting orthodontic treatment and its influence on the occurrence of iatrogenic sequelae. *The Angle*

Orthod. 1996;66(2):95-110

18. Manea I, Pineda I A, Mendoza B S, Reina A S, Reina J E S. Facial growth pattern: Association between lower incisor position and symphyseal morphology. J. World Fed Orthod 2017;6(4):147-51.