

# **Clinico-Radiological Profile of Abdominal Pain in Children admitted in a Tertiary Care Centre - A Retrospective Cohort Study**

## **ABSTRACT:**

**Background and Aim:** Mesenteric lymphadenitis in pediatric population usually presents with abdominal pain mimicking appendicitis mounting a challenging task for physicians to diagnose. It is a self-limiting inflammatory process and resolves spontaneously. In addition to clinical features, ultrasonography is the primary diagnostic modality. We aimed to evaluate the clinico-radiological characteristics of mesenteric adenitis in patients presenting with abdominal pain.

**Materials and Methods:** A total of 108 patients attending paediatric out-patient and paediatric surgery clinic in Saveetha Medical College and Hospital, Chennai, between January 2018 and December 2020 with abdominal pain for several aetiologies were included in this study. The clinical presentation, laboratory parameters and the ultrasonographic findings were noted. Data summarized as numbers, percentages and Mean  $\pm$  Standard Deviation (SD).

**Results:** Peak prevalence was found to be at around 8 [range 6-10] years. Clinically, 58.3% had fever, 40.7% had dysuria and 36.1% had diarrhoea. Laboratory parameters were non-specific for this condition. Majority of the enlarged lymph nodes were found in the right lower quadrant (81.5%) followed by (10.2%) in the para-umbilical region and (8.3%) in left lower quadrant.

**Conclusions:** Mesenteric lymphadenitis as an individual clinical entity is a very challenging task for the paediatricians to evaluate and diagnose due to several possible variations in the clinical presentation. Although mesenteric lymphadenitis is usually a self limiting entity, a cohort of children warrant medical interventions.

**Keywords:** Abdominal pain, Mesenteric lymphadenitis, Paediatric, Ultrasonography

## **INTRODUCTION:**

Mesenteric lymph nodes are approximately 100–150 in number. They are small, bean-shaped structures running along the course of lymphatic vessels. The mesenteric lymph node is the “first pass” organ for nutrients and microbial substances entering the lymph fluid in the intestinal lamina propria<sup>[1]</sup>. Their major functions are to act as a filter for particulate matter and micro-organisms, and are the site of antigen presentation.

Mesenteric lymphadenitis refers to nonspecific self-limiting inflammation of the mesenteric lymph nodes. This conditions Mesenteric lymphadenitis typically occurs in children, adolescents, and young adults of both sexes, although males might be slightly more frequently affected than females<sup>[2]</sup> This condition is known to have varied clinical presentations that can include abdominal pain, fever, vomiting and diarrhea. Physical examination alone is often sufficient in the pediatric population but still requires imaging studies to make the diagnosis.

Laboratory parameters like white blood cell (WBC) and C-reactive protein (CRP) will generally be elevated, but the diagnosis cannot be ruled out even if they are within normal limits<sup>[3]</sup>. The diagnosis of lymph node enlargement by imaging modality is reported based on the size criterion. Majority of pediatric patients with abdominal pain are subjected to imaging studies, in particular, ultrasound examination of the abdomen<sup>[4]</sup>, and a high prevalence of mesenteric lymph node (MLN) in the right lower abdominal quadrant has been previously reported<sup>[5]</sup>. The current radiological definition defines mesenteric adenitis as at least one abnormally enlarged lymph node measuring 8 mm or more in its short-axis diameter<sup>[6]</sup>.

This retrospective study was aimed to evaluate the clinico-radiological characteristics of enlarged mesenteric nodes in pediatric patients presenting with abdominal pain.

## **METHODOLOGY:**

### **Patients**

This retrospective cohort study received approval from the Institutional Review Board and Ethics Committee of the hospital (SMC/IEC/2021/03/048 dated 25.03.2021) and was conducted in the outpatient Department of Paediatrics and Paediatric Surgery, Saveetha Medical College and Hospital, Thandalam, Chennai, Tamilnadu, India, over a period of 6 months (March 2021 to August 2021). All Children aged 1 to 15 years presenting with abdominal pain were included. The exclusion criteria included congenital anomalies, tuberculosis, lymphoma, gastrointestinal perforation, as well as children with tumors or systemic diseases. The clinical data (age, sex, socio-economic status, symptomatology, and examination findings), laboratory parameters (WBC and CRP) and the ultrasound characteristics of mesenteric lymph nodes (location, size) of the patients presenting with abdominal pain over the past 3 years (January 2018 to December 2020) were collected sequentially from the medical records. Children were divided into three groups – 1-5 (pre-schoolers) years, 6-10 (school age) years and 11-15 (adolescence) years.

### **Ultrasonography**

All the ultrasound examinations were performed by an experienced sonographer using a standard Siemens SONOLINE G50 ultrasound machine. After scanning of the whole abdomen and pelvis with a curved 4 MHz transducer, mesenteric lymph node evaluations were performed with a linear 9 MHz transducer. The transverse diameter of the largest mesenteric lymph node were recorded for each

child. The current radiological definition defines mesenteric adenitis as at least one abnormally enlarged lymph node measuring 8 mm or more in its short-axis diameter<sup>[7]</sup>.

### **Laboratory parameters**

An EDTA-anticoagulated whole-blood specimen was collected on the same day of the ultrasound examination. All blood samples were collected and analyzed by the Central Clinical laboratory of the hospital. WBC and CRP of each child was provided post blood sample analysis using a Sysmex KX-21 fully automated Hematology Analyzer (East Asia Co., Japan), and Bhat BIO-SCAN C-REACTIVE PROTEIN LATEX SLIDE TEST KIT respectively. Elevated WBC and CRP<sup>[8]</sup> is defined in children as  $\geq 11.0 \times 10^9/L$  and  $> 6 \text{ mg/dL}$  respectively.

### **Statistical analysis**

Data was entered in MS Excel and was analysed using Statistical Package for the Social Sciences (SPSS) program for Windows (SPSS Inc, Chicago, version 19.0). **Categorical variables were presented in the form of frequencies and percentages. Continuous variables were summarized and depicted as Mean  $\pm$  Standard Deviation (SD).**

## **RESULTS:**

### **Cohort Characteristics**

A total of 108 paediatric patients with abdominal pain of various etiologies visited the outpatient department of paediatrics and paediatric surgery between January 2018 and December 2020. Of these children, 75 (69.4%) were boys, giving a male to female (M:F) ratio of 2.3:1, with median age of 8 years old **[range 6 - 10 years]**. There was parity in the distribution between sexes, with more male preponderance in the distribution. 77 (71.3%) patients were in age group between 6 and 10 years.

### **Clinical Characteristics**

Clinically [108 (100%)] children had abdominal pain, [63 (58.3%)] had fever, [44 (40.7%)] had dysuria and [39 (36.1%)] had diarrhoea, as shown in Figure 1.

Elevated WBC was seen in [77 (71.3%)] patients. Predominantly lymphocytosis was detected in [63 (81.8%)] patients. CRP was found to be elevated in [23 (21.3%)] patients only.

### **Ultrasonographic Characteristics**

Distribution of enlarged mesenteric lymph nodes was analyzed, with regard to the location of the node (Left lower quadrant, Right lower quadrant and para-umbilical region). The largest proportion of the nodes was seen in the right lower quadrant [88 (81.5%)], followed by the para-umbilical region [11

(10.2%)] and the left lower quadrant [9 (8.3%)]. The demographic and clinic-radiological characteristics of study population are presented in Table 1.

Analysis of dimensions of largest measuring mesenteric lymph nodes by ultrasound revealed that the median transverse diameter was 6.80 mm [range 5.30 mm - 8.40 mm]. Majority [54 (50%)] of patients had transverse diameter measured between 4 mm and 6.9 mm. The mean dimensions of the largest mesenteric lymph node among patients with cystitis, primary mesenteric lymphadenitis and appendicitis were found to be statistically significant (Table 2).

Ultrasonographic diagnosis for abdominal pain in the study population was observed to be cystitis [67 (62%)], primary mesenteric lymphadenitis [18 (16.7%)], colitis [15 (13.9%)], appendicitis [5 (4.6%)], intussusception [3 (2.8%)], as depicted in Figure 2.

## **DISCUSSION:**

In our study, there is sex (gender) difference in children having mesenteric lymphadenopathy (males 69.4% and females 30.6%). This is similar to the study done by Maheswari et al<sup>[9]</sup> that concluded most affected patients were males (75.4%) than females (24.5%). In another study conducted by Murthy Nagaraj et al<sup>[10]</sup> it was seen that majority of the affected cases were males (64%).

In the present study, the peak incidence of mesenteric lymphadenitis was seen in 8 year of age (range 6 -10 years). Sikorsha et al<sup>[11]</sup> has shown that the peak incidence of mesenteric lymphadenitis is in 9 year of age. Yet another study conducted by Maheswari et al<sup>[9]</sup> revealed the peak incidence was between 5 and 10 years of age.

In our study, we have taken those cases presenting with abdominal pain and hence, all cases had abdominal pain (100%) as a symptom. On clinical grounds, we also found few associated symptoms. Accordingly, fever (58.3%) was the most common associated symptom, followed by, dysuria (40.7%), and diarrhoea (36.1%). These results are similar to the study conducted by Nagaraj et al<sup>[10]</sup>.

On the analysis of the laboratory parameters, we found no correlation in regard to WBC count and C-Reactive Protein. CRP was found to be elevated in [23 (21.3%)] patients only. This analysis is in accordance to the study done by Allagadda et al<sup>[12]</sup> in which CRP was positive in 16 (25%) only.

In the present study, the range of transverse diameter was observed between 5.48 mm and 8.63 mm. Majority of enlarged lymph nodes was found to be in right lower quadrant [88 (81.5%)] followed by para-umbilical region [11 (10.2%)] and left lower quadrant [9 (8.3%)]. Our findings correlated with the study published by Roshan Chanchlani<sup>[2]</sup> regarding the size and location of the mesenteric nodes.

In clinical practice, children presenting with abdominal pain of various etiologies are subjected to either of the three treatment modalities based on their symptomatology and clinic-radiologic

features: observation; medical management (and/or) surgical intervention. In our study, majority of the patients fell in the observation and follow up category. With respect to the primary mesenteric adenitis group of children, major proportion of patients fell under the category of observation. Very few patients required medical management in the form of antibiotics and analgesics.

## **CONCLUSION:**

Mesenteric lymphadenitis is a self limiting inflammatory condition usually caused by pathogens of viral origin. It is one of the most common medical causes of abdominal pain in paediatric patients. Although majority of the patients have self limiting course, few patients warrant medical intervention at times.

## **LIMITATION:**

Since this research was a retrospective study, other characteristics that could only be assessed by observation or history-taking were not possible.

## **REFERENCES:**

1. Jorge Henao-Mejia, Eran Elinav, Christoph A. Thaiss, Richard A. Flavell. In: The Intestinal Microbiota in Chronic Liver Disease. Frederick W. Alt editors. Advances in Immunology. Academic Press, 2013, p. 73-97.
2. R. Chanchlani. Clinical profile and management of mesenteric lymphadenitis in children-our experience. Int. J Orthop. Traumatol. Surg. Sci. 2015;1(1):1-4.
3. Otto M, Nagalli S. Mesenteric Adenitis. [Updated 2020 Aug 14]. In: StatPearls [Internet]. Treasure Island (FL): StatPearls Publishing; 2021 Jan-. Available from: <https://www.ncbi.nlm.nih.gov/books/NBK560822/>
4. Pilhatsch A, Riccabona M. Role and potential of modern ultrasound in pediatric abdominal imaging. Imaging Med. 2011;3(4):393-410.
5. Vayner N, Coret A, Polliack G, Weiss B, Hertz M. Mesenteric lymphadenopathy in children examined by US for chronic and/or recurrent abdominal pain. Pediatr Radiol. 2003; 33(12):864-867.
6. Wang WG, Tian H, Yan JY, Li T, Zhang TD, Zhao YP, et al. Enlarged mesenteric lymph nodes in children: a clinical analysis with ultrasonography and the implications. Nan Fang Yi Ke Da Xue Xue Bao. 2011;31(3):522-524.

7. Simanovsky N, Hiller N. Importance of sonographic detection of enlarged abdominal lymph nodes in children. *J Ultrasound Med.* 2007;26(5):581-4.
8. Nehring SM, Goyal A, Bansal P, et al. C Reactive Protein. [Updated 2021 May 10]. In: StatPearls [Internet]. Treasure Island (FL): StatPearls Publishing; 2021 Jan-. Available from: <https://www.ncbi.nlm.nih.gov/books/NBK441843/>
9. Maheswari K, Wadhwa L. Clinical profile and causes of mesenteric lymphadenitis in children. *Int J Contemp Pediatr* 2016;3(2):550-552.
10. Murthy N, Raman R. Non-specific mesenteric lymphadenitis and cervical lymphadenopathy in pediatric age group – a correlative study. *Asian Journal of Medical Radiological Research* 2018;6(1):20-25.
11. Sikorska-Wiśniewska G, Liberek A, Góra-Gebka M, et al. Mesenteric lymphadenopathy-a valid health problem in children. *Medycyna Wieku Rozwojowego* 2006;10(2):453-462.
12. Allagadda DK, Appana H, Pedada R, et al. Aetiological outcome of mesenteric lymphadenopathy and pain abdomen in paediatric population at a tertiary care hospital (MRIMS-Hyderabad) - a hospital based prospective observational study. *J Evid Based Med Healthc* 2021;8(29):2601-2608.

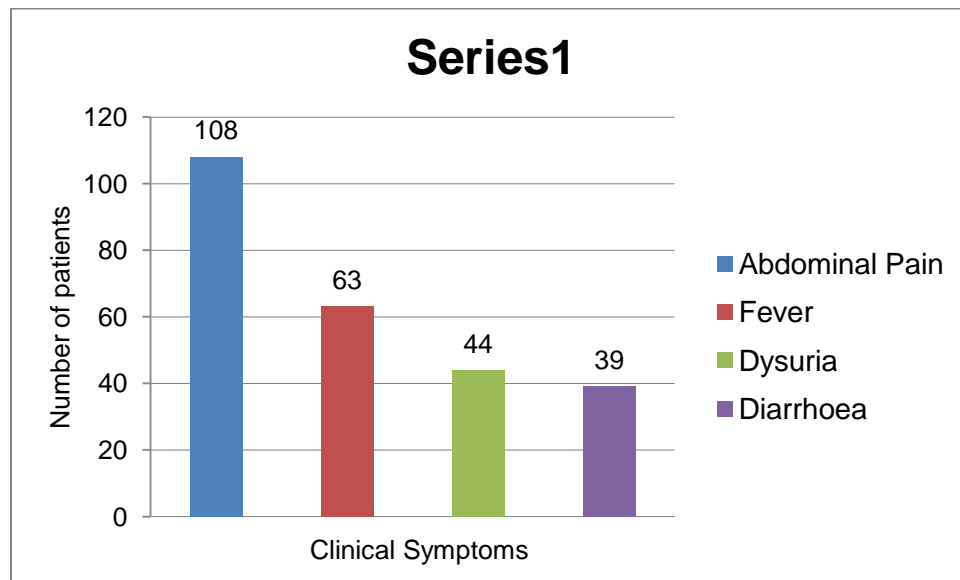
**TABLE 1: DEMOGRAPHIC AND CLINICO-RADIOLOGICAL CHARACTERISTICS OF THE STUDY POPULATION**

Variables	n (%)
<b>Gender</b>	
Male	75 (69.4)
Female	33 (30.6)
<b>Age (Years)</b>	
1 - 5	11 (10.2)
6 - 10	77 (71.3)
11 - 15	20 (18.5)
Range	6 – 10
<b><i>Transverse diameter (mm)</i></b>	
4 – 6.9	54 (50.0)

7 – 9.9	41 (38.0)
≥ 10	13 (12.0)
Range	5.30 – 8.40
Mean ± SD	7.01 ± 1.98
<b><i>Diagnosis (USG)</i></b>	
Cystitis	67 (62.0)
Primary mesenteric adenitis	18 (16.7)
Colitis	15 (13.9)
Appendicitis	5 (4.6)
Intussusception	3 (2.8)
Range	12870 – 17120
Mean ± SD	15052.55 ± 2591.49
Lymphocytosis (%)	63 (81.8)
Range	59.0 – 68.5
Mean ± SD	63.38 ± 5.03
Positive CRP (mg/L)	23 (21.3)

Range	14.85 – 36.60
Mean ± SD	26.98 ± 13.95
<b>Ultrasonographic Characteristics</b>	
<b>Location</b>	
Right lower quadrant	88 (81.5)
Paraumbilical	11 (10.2)
Left lower quadrant	9 (8.3)

**FIGURE 1: DISTRIBUTION OF CLINICAL CHARACTERISTICS OF THE STUDY POPULATION**



**TABLE 2: TRANSVERSE DIAMETER OF LARGEST MESENTERIC LYMPH NODE BASED ON SONOGRAPHIC DIAGNOSIS**

Ultrasonographic Diagnosis	Transverse Diameter	p value
	Mean ± SD	
Cystitis	5.20 ± 0.54	< 0.0001
Primary Mesenteric Lymphadenitis	6.92 ± 1.98	
Appendicitis	10.72 ± 0.19	

**FIGURE 2: DISTRIBUTION OF SONOGRAPHIC DIAGNOSIS OF THE STUDY POPULATION**

