

## **Pleomorphic Adenoma of Neck: Case Report**

### **ABSTRACT:**

Pleomorphic adenomas are benign tumour of the salivary glands that mostly affect the parotid gland. The tumor's "pleomorphic" form can be explained by its epithelial and connective tissue origins. Females between the ages of 30 and 50 are more likely to get the tumour. The tumour usually presents as asymptomatic swelling that progresses slowly. The majority of treatment is surgical removal of the tumour mass, with special attention paid to preserving the facial nerve. This is a case report of a 42-year-old female patient who had a pleomorphic adenoma of the parotid gland. On the right side of the face, the patient had a slowly growing asymptomatic swelling. Pleomorphic adenoma is the commonest salivary gland tumor characterized by diverse histomorphological features. Early diagnosis and treatment plan entails thorough history taking, clinical examination, coupled with radiographic and histopathological findings.

## **KEY-WORDS:**

PA: Pleomorphic Adenoma; Fine needle aspiration cytology- 'FNAC'.

## **INTRODUCTION**

Tumors of salivary gland constitutes 3% among all head and neck tumors, mostly derived from major salivary glands [1] Invasion of parotid gland found to be commonest with pleomorphic adenoma (PA) makes it highly prevalent. Pleomorphic adenomas usually presents as solitary, unilateral, slow growing asymptomatic nodules. Chronologically it is of synchronous and metachronous. The parotid gland and minor salivary gland of hard palate are the most commonly affected[2]. Here we highlighted a rare case of 42 year systemically healthy women with a tumour of submandibular gland origin extending in the neck region.

## **CASE REPORT**

A systemically healthy, 42 year old female presented to the Department of Oral and Maxillofacial Surgery with a complaint of swelling on angle of mandible and neck region of right side. Patient gave history of asymptomatic enlarging swelling on right side since 3-year for which she underwent FNAC r/s/o "pleomorphic adenoma" of right submandibular gland. Patient complains of difficulty in breathing since 15 days. On examination, a well-circumscribed lobulated swelling of about 8 x 4 cm, firm, mobile and non-tender in nature. There was no evidence of other lymphadenopathy. (Fig.1) FNAC was performed using a 23-gauge needle over swelling

that showed similar cytomorphology. Smear showed sheets cuboidal polygonal epithelial cell, at places entrapped and surrounded by fibro myxoid material [10].

All these findings were suggestive of pleomorphic adenoma, a case arising from the submandibular gland extending into the neck causing airway obstruction.

. Radiographic examination was done on contrast enhanced computed tomogram examination that showed e/o ill-defined large lobulated mass lesion in the right gland predominantly in right superficial lobe showing the extension into the deep lobe. The mass is measuring approx. 9.9 x 5.78 x 5.6 cms. Neurovascular bundles to be displaced posterolateral. (Fig.2) after the final diagnosis, patient was prepared for surgical removal of the tumour. After obtaining the fitness of the patient, GA was induced and tumour was opened by apron's incision. Complete removal of tumour of right side was performed. (Fig.3) Closure was then done in 2 layers. (Fig.4) Patient is on follow up for 2 years and no complications or recurrence is seen

### **Treatment:**

The treatment of pleomorphic adenoma includes the excision of tumor with the minor salivary glands. As parotid gland is the most commonly affected followed by the submandibular gland. It is better to consider the surgical anatomy of the structure intra-operatively. Facial artery, Facial vein and Marginal mandibular nerve these are the structures which can be preserved during submandibular gland excision unless the tumor is abutting it.

Treatment of choice for pleomorphic adenoma is total excision of the tumor with a recurrence rate of 2 - 5%. Malignant transformation is rare and only 5% of cases have been reported [7]. In the present case, complete removal of tumor of right side was performed. No reoccurrence have been reported on follow up of 2 years.

## **Discussion**

Pleomorphic adenomas are one of the commonest parotid tumors, accounting for 70 - 80% of all salivary gland neoplasms [11]. PAs are usually unilateral, slow growing, painless tumors. Seifert and Donath [4] in 1996 classified these tumors under unilateral and bilaterally, and chronologically - Synchronous or metachronous. Metachronous salivary gland tumors can be of unilateral, bilateral or of combination any of above.

The high variance of microscopic character of disease makes it pleomorphic. The mixed polygonal, myo-epithelial cell with mixed myxoid, chondroid and hyaline tissue makes it pleomorphic adenoma [3]. Myoepithelial cell is the primary proliferating cell in pleomorphic adenoma [9]. The epithelial cells are of star shaped, spindle or of polygonal shaped which can clump together to form ducts or sheets. They are formed by inner cuboidal cells and outer myo-epithelial cells. The differential diagnosis for the condition are "Warthin tumor, parotid nodal metastasis, facial nerve schwannomas, myoepitheliomas, mucoepidermoid and adenoid cystic carcinoma" Post-op imaging and IHC test of the sample was not being done which could be a limitation to the study. Although it is difficult to differentiate between all these pathologies clinically. Histopathological examination is a gold standard for understanding the differential features among all [6] whereas radiologic studies are usually unable to differentiate benign from malignant tumours in most cases [8].

## **Conclusion**

Pleomorphic adenomas though are benign tumors, should be diagnosed at early stage and must undergo surgical removal. Metachronous tumor may be missed at first presentation and therefore careful evaluation of imaging is mandatory to detect early and unsuspected lesions.

UNDER PEER REVIEW

## Bibliography

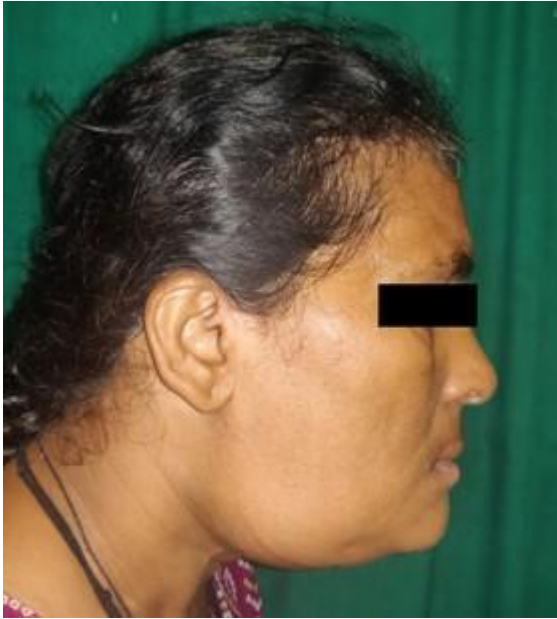1. Davudov MM. "Pleomorphic Adenoma of Parotid Gland-Clinical Case in 14-Years-Old Child". *Journal of Head and Neck Surgery* 2.1 (2019).
2. Da Silva Sindeval José., *et al.* "Metachronous bilateral pleomorphic adenoma of the parotid gland". *Oral surgery, Oral Medicine, Oral Pathology, Oral Radiology, and Endodontology* 101.3 (2006): 333-338.
3. Gupta Vivek and Arvind Bhake. "Molecular diagnosis of tubercular lymphadenopathy from fine-needle aspirates in pediatric patients". *Acta Cytologica* 61.3 (2017): 173-178.
4. Seifert G and K Donath. "Multiple tumours of the salivary glands-terminology and nomenclature". *European Journal of Cancer Part B: Oral Oncology* 32.1 (1996): 3-7.
5. Ahn Min S., *et al.* "Familial mixed tumors of the parotid gland". *Head and Neck: Journal for the Sciences and Specialties of the Head and Neck* 21.8 (1999): 772-775.
6. Bokhari MR, Greene J. Pleomorphic Adenoma. [Updated 2021 Jul 10]. In: StatPearls [Internet]. Treasure Island (FL): StatPearls Publishing; 2021 Jan-. Available from: <https://www.ncbi.nlm.nih.gov/books/NBK430829/>
7. Espinosa Carlos A., *et al.* "Clinicopathologic and surgical study of pleomorphic adenoma of the parotid gland: analysis of risk factors for recurrence and facial nerve

dysfunction". *Journal of Oral and Maxillofacial Surgery* 76.2 (2018): 347-354.

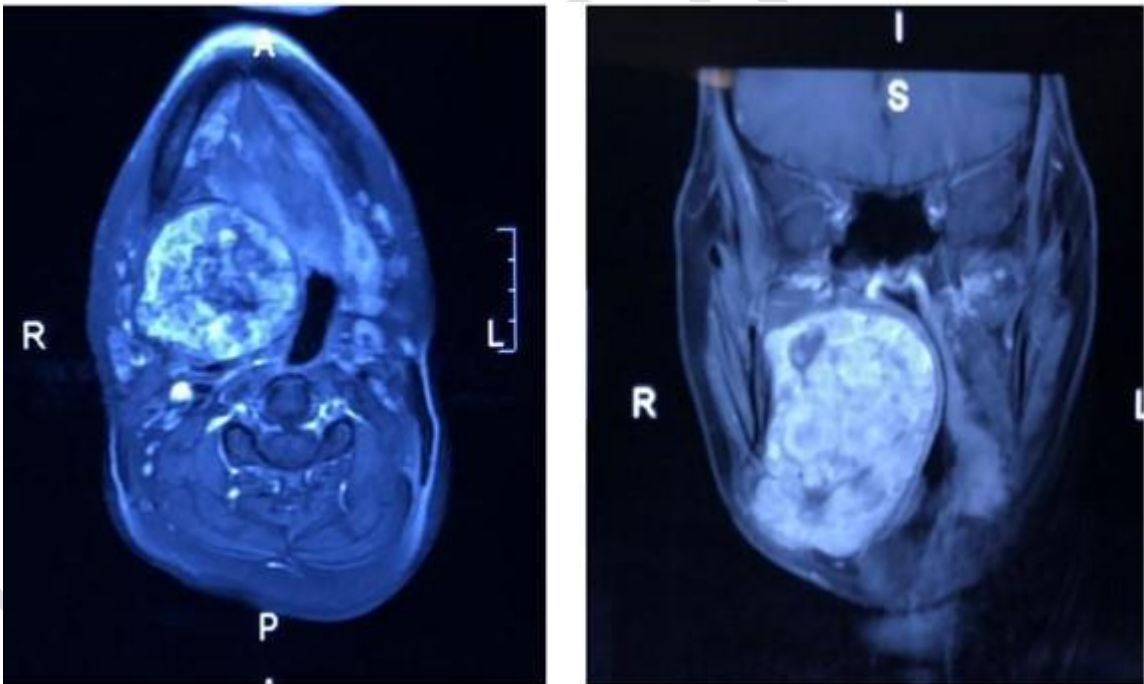
8. Khanal P. Pleomorphic Adenoma of the Submandibular Gland: A Case Report. *JNMA J Nepal Med Assoc.* 2019 Jan-Feb;57(215):53-55.
9. Choi JS, Cho BH, Kim HJ, Kim YM, Jang JH. Identification of new genes of pleomorphic adenoma. *Medicine (Baltimore).* 2019 Dec;98(51):e18468.
10. Kajiyama A, Edo H, Inoue N, Yokouchi Y, Gomi T. Magnetic Resonance Imaging and Histopathology in a Case of Pleomorphic Adenoma of a Minor Salivary Gland in the Nasal Cavity. *Am J Case Rep.* 2019 May 12;20:679-684.
11. Erdem MA, Cankaya AB, Güven G, Olgaç V, Kasapoğlu C. Pleomorphic adenoma of the palate. *J Craniofac Surg.* 2011 May;22(3):1131-4.

## LEGEND OF FIGURES

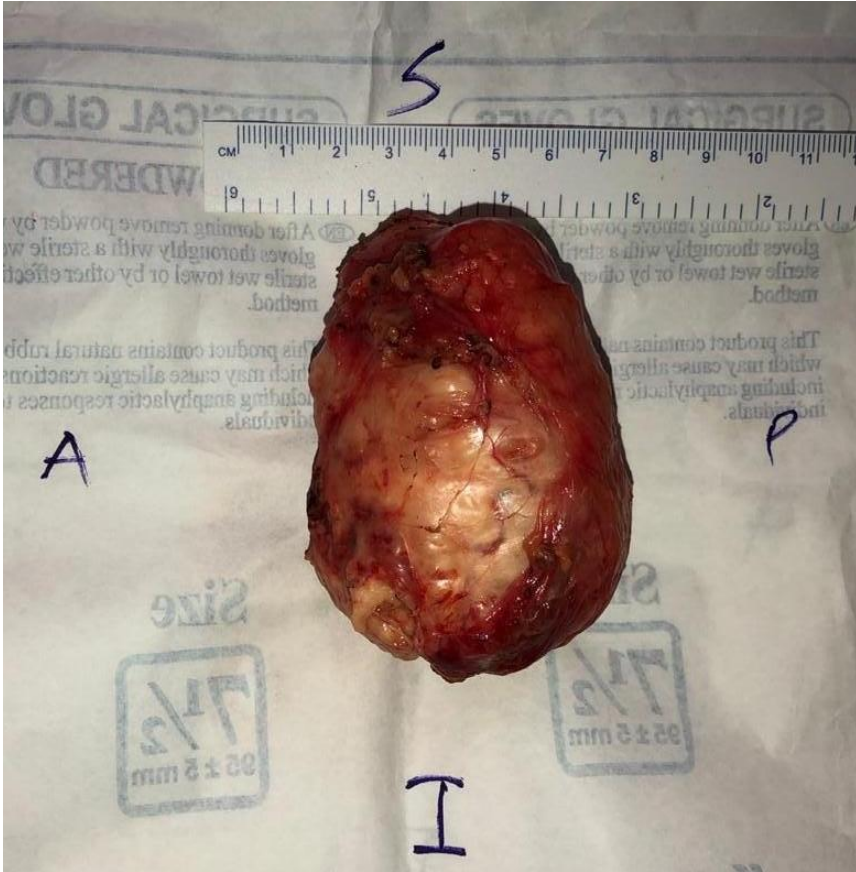
UNDER PEER REVIEW



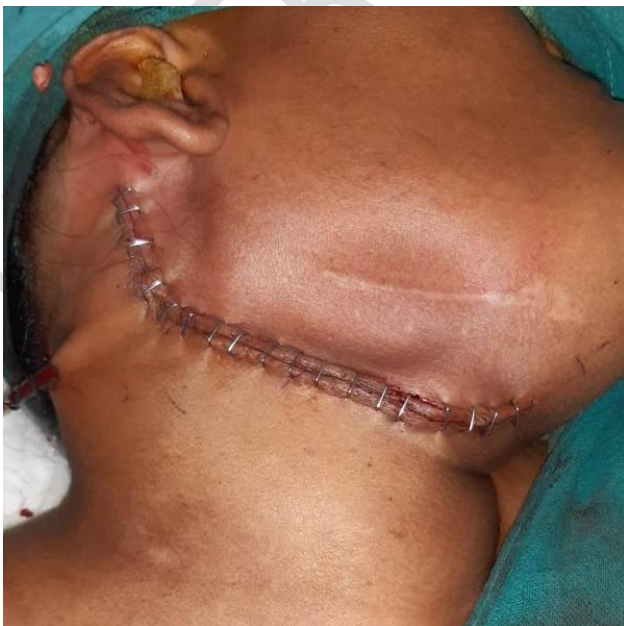**Fig.1 – Extra-oral swelling extending in the angle and the neck region**



**Fig.2- CT Head showing the enhancing lesion arising from the submandibular gland**



**Fig.3- Excised salivary gland tumor**



**Fig.4- Closure**

UNDER PEER REVIEW