

ACL injuries and Meniscal lesion: Hand in hand?

ABSTRACT

Objective: To assess the incidence, nature and pattern of meniscal tear in ACL injury.

Methodology: A retrospective study was conducted among the patients who were admitted and treated for ACL tear in Saveetha Medical And College And Hospital over a 2-year period from August 2019-August 2021. There were 52 patients admitted and treated for the same. The case records of each of the patients were reviewed to find the incidence of meniscal lesion in ACL tear and were then analyzed using appropriate statistical tests.

Results: 52 patients with ACL tear were reviewed in this study. ACL tear was most commonly reported in younger age group of 20-29 (46.15%). Out of which, 19(36.54%) patients had meniscal tears. About 9(47.37%) patients had lateral meniscus tear, 6(31.58%) had medial meniscus tear and 4(21.05%) had bilateral meniscal tear. It was seen that bucket handle injury (n=12) was the most common meniscus tear overall. Radial tear was most specifically common in bilateral meniscus injury(N=4).

Conclusion: Meniscal tears are the most common intra articular lesions associated with

ACL tear. It was most commonly reported in the age group of 20-29. We found that the incidence of lateral meniscal tear was significantly higher in the patients rather than medial meniscal tear. Bucket handle injury was the most commonly reported tear in meniscal injury. Therefore, the surgeon needs to equip himself with the necessary meniscal repair instruments in his armamentarium.

Key words: Anterior crucial ligament tear, lateral meniscus injury, bucket handle tear

INTRODUCTION: The main role of meniscus is to evenly distribute impact forces through the knee and to maintain joint stability. A meniscus tear is usually caused by twisting or turning quickly. These tears can occur commonly while playing sports or lifting heavy weights and is common in young, active adults. Degenerative tears commonly occur in patients with osteoarthritis. Initially meniscus tear was described as functionless remain of a leg ¹, extensive scientific studies have described meniscus as one of the most important structure of the knee ²

Meniscus tear can occur along-side with other ligamentous injury and it is commonly associated with ACL tear because of its anatomic and functional relationships to these structures. Isolated ACL tears are not common ³.

For maintaining long term joint function, especially in active patients, meniscal tissue function should be preserved. However concomitant meniscal surgery has no significant effect on patient outcome on strength and jump metrics post-operatively ³. Early repair of posterior horn of lateral meniscus has significant improvement in loading profile in lateral compartment and may help in prevention of damage of cartilage and osteoarthritis associated with partial menisectomy ³⁴

The purpose of this study is to document the frequency, morphology and commonest meniscal injuries accompanying anterior cruciate ligament tear

Methodology:

A retrospective study was conducted among the patients over a period of August 2019 – August 2021. The data was collected from the database of the Orthopaedics department of Saveetha Medical College And Hospital.

Inclusion criteria:

- Age between 18 years to 70 years
- Isolated ACL injuries

Exclusion criteria:

- Previous surgery involving partial meniscectomy
- Patients with multi-ligamentous injury
- Patients with previous ACL surgery

The data and documents of the patients who met the inclusion and the exclusion criteria were studied. Not all patients operated were clinically positive for meniscus tear (valgus/varus stress test, Apley's grind test) but showed radiological evidence of meniscus tear. Surgical procedures were done under spinal anesthesia and diagnostic arthroscopy was done in each case to confirm the diagnosis intra-operatively. ACL tear was recorded. The site and type of meniscus repair was recorded.

During the study period, 52 patients met the inclusion/ exclusion criteria which included 45 male patients and 7 female patients.

Meniscal Tear Classification

In all patients, diagnostic arthroscopy was done to confirm the meniscal lesions. Tears

were documented as lateral and medial meniscal tear which was further subdivided into anterior horn, posterior horn and body involvement. Types of meniscal tears were further classified as longitudinal tear, radial tear, horizontal tear, bucket handle tear and flap tear, complex tear

Results: Out of 52 patients reviewed in this study, it was found that about 19(36.54%)patients had meniscal injury along with ACL tear whereas 33(63.46%) patients had isolated ACL tear alone. Table 1 shows the demographic details of the patients. It was found that about 2(3.85%) patients in the age group of 10-19 , 23(44.23%) patients in the age group of 20-29, 17(32.69%) of age group 30-39 , about 7 (13.46%) in the age group of 40-49 and 3 (5.77%) in the age group of 50-59. The highest incidence of ACL tear about 24 (46.15%)was reported in the age group of 20-29. This shows us that ACL tear more common in younger age group around 20-29 years.

The ACL tear was most commonly reported in the right knee in 38(73.07%) patients. 13(25%) patients had ACL tear in left knee and about 1(1.93%) had bilateral knee involvement.

Table 2 shows the site of the meniscal tear. The most commonly reported injury was located in the lateral meniscus which was seen in 9(47.37%) patients. In 6 (31.58%) patients it was located in the medial meniscus and in 4(21.05%) patients both lateral and medial meniscus were involved.

Table 3 shows the morphology of meniscal tears associated with ACL injury. The most commonly reported tear was the bucket handle tear. It was seen in about 12 patients

which included 7 lateral meniscal tear and 5 medial meniscal tear. Radial tear was commonly reported in bilateral meniscal tear(4) and about 1 patient in lateral meniscal tear and 1 patient in medial meniscal tear. Flap tear was reported only in one patient with lateral meniscal tear.

The patients with medial meniscal tear(6) underwent partial medial meniscectomy and bilateral meniscal tear patients (4) had underwent bilateral partial meniscectomy along with ACL reconstruction.

Discussion:

ACL is a band of connective tissue that courses from femur to tibia. It helps to keep the knee stable. ⁷ About 50% of ACL tears are most commonly associated with meniscal tears. ⁶ ACL tear is a common tear with an annual incidence ranging between 68.6 10000 person years in the population. ACL is an important stabilizer of the knee joint, most commonly occurs with twisting of knee whilst weight bearing. An ACL tear typically will present with rapid joint swelling and significant pain. For clinical examination , Lachman test and Anterior drawer test would be performed. ⁷.

In our study we found that lateral meniscal injury(47.37%) were most commonly associated with ACL tear. Where as in the study published by Jewell Brent Duncan et al., it was found that 141 (83%) patients had lateral meniscal injury whereas 29 (17%) patients had medial meniscal injury. The findings from this study goes hand in hand with our study.

The study also concluded that the triad of injury of ACL-MCL-Lateral meniscus was nine times more common than the triad of ACL-MCL-Medial meniscus tear. ^{8 11}

The study conducted by Tetsuo Hagino et al., revealed that in acute ACL injury group,

lateral meniscal injury was seen in about 129 knees(69.4%) ,medial meniscal injury in 20

knees(10.8%) and bilateral meniscal tears were found in 37 knees(24.7%). This study also suggests that lateral meniscal tear was most common in acute ACL injury Whereas In chronic ACL group, bilateral meniscal tear in 104 knees(41.4%) was most commonly reported. Whereas the lateral and medial meniscal tears were reported in about 85(33.9%) and 62(24.7%) knees respectively. ^{9 10}

It was observed that bucket handle tear was most commonly seen in Meniscus tear patients. It's reported higher in medial meniscal tear injury rather than lateral meniscus. ^{12 13} Testuo Hagino et al., reported that bucket handle tear was observed in 25 knees whereas in our study it was observed in 12 knees. ^{9 15} With regards to radial tears, there have been reports of association with medial meniscal tear^{15 16} as well as bilateral meniscal tears ^{17 18}. In our study, radial tears were seen in both medial and lateral meniscal tears.

Diagnostic arthroscopy was done to confirm the ACL tear and concomitant meniscal injuries. As Arthroscopy is the gold standard diagnostic method for diagnosis of meniscal tears than MRI ^{19 20}

Conclusion:

Meniscal tears are often missed injuries in the pre operative phase. The association between ACL injuries and Meniscal tears needs to be establishes to enhance the surgeons preparedness to address the meniscal problem. In concomitant ACL and meniscal injuries, the symptoms of instability can supersede the symptom of pain thereby masking the meniscal lesion. Hence it is imperative for the treating physician to

be well aware of the expected meniscal injuries so that treatment is effective.

PARAMETERS	VARIABLES	FREQUENCY N=52	PERCENTAGE
Age	10-19	2	3.85
	20-29	24	46.15
	30-39	17	32.69
	40-49	7	13.46
	50-59	2	3.85
Side of ACL tear	Right	38	73.07
	Left	13	25
	Bilateral	1	1.93
Meniscal Tear	Yes	19	36.54
	No	33	63.46

Table 1: Socio-demographic details of patient

Percentage of meniscal tears

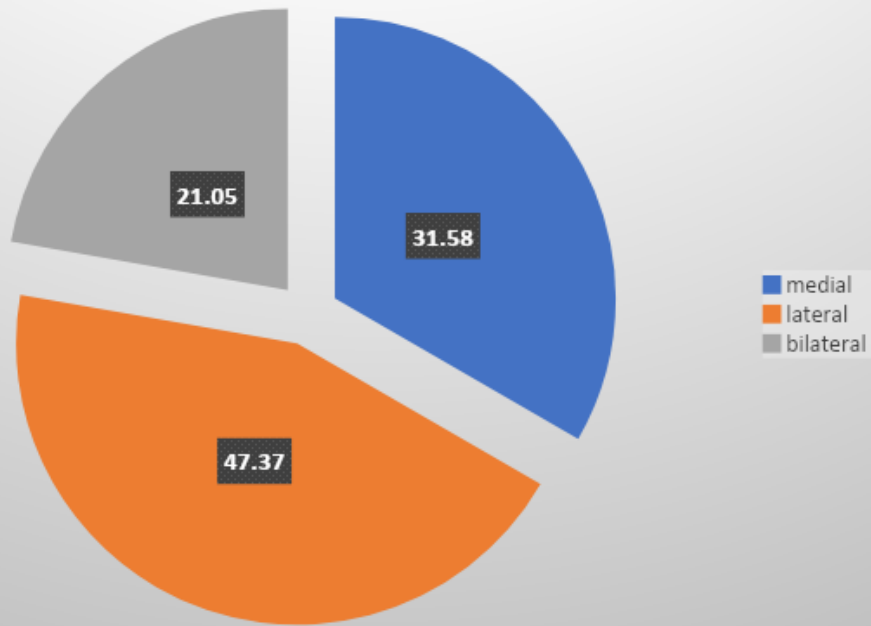


Table 2: Site of meniscal tear

Site	Frequency N=19	Percentage
Lateral meniscus	9	47.37
Medial meniscus	6	31.58
Bilateral meniscus	4	21.05

Table 3: Morphology of meniscal tears

Morphology	Lateral	Medial	Bilateral	Total	Chi square value	P value
Bucket handle tear	7	5	-	12	11.87	0.018
Radial tear	1	1	4	6		
Flap tear	1	-	-	1		
Complex tear	-	-	-	-		
Root tear	-	-	-	-		
Total	9	6	4	19		

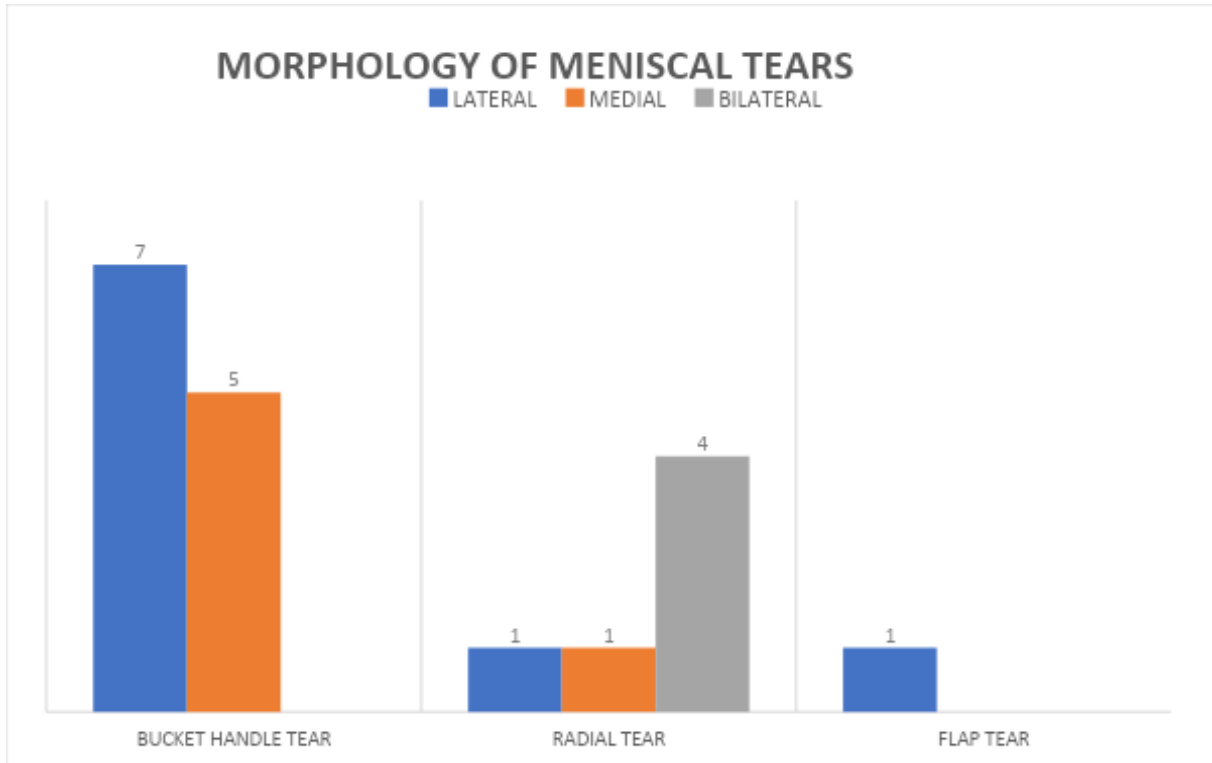


Table 4:

Age	Twisting injury	RTA	Sports injury	Chi square value	P value
10-19	0	0	7	29.25	<0.0001
20-29	0	2	9		
30-39	4	6	8		
40-49	3	7	0		
50-59	1	5	0		

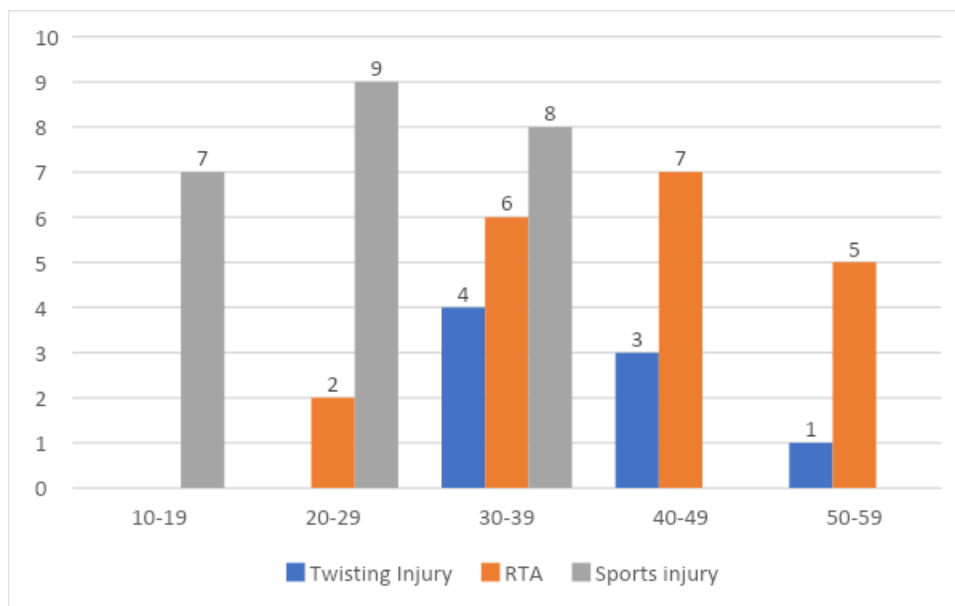


Table 5:

Age group	Bucket handle tear	Radial tear	Flap tear	Chi square value	P value

10-19	0	0	0	2.9	0.821
20-29	6	3	0		
30-39	3	2	1		
40-49	2	1	0		
50-59	1	0	0		

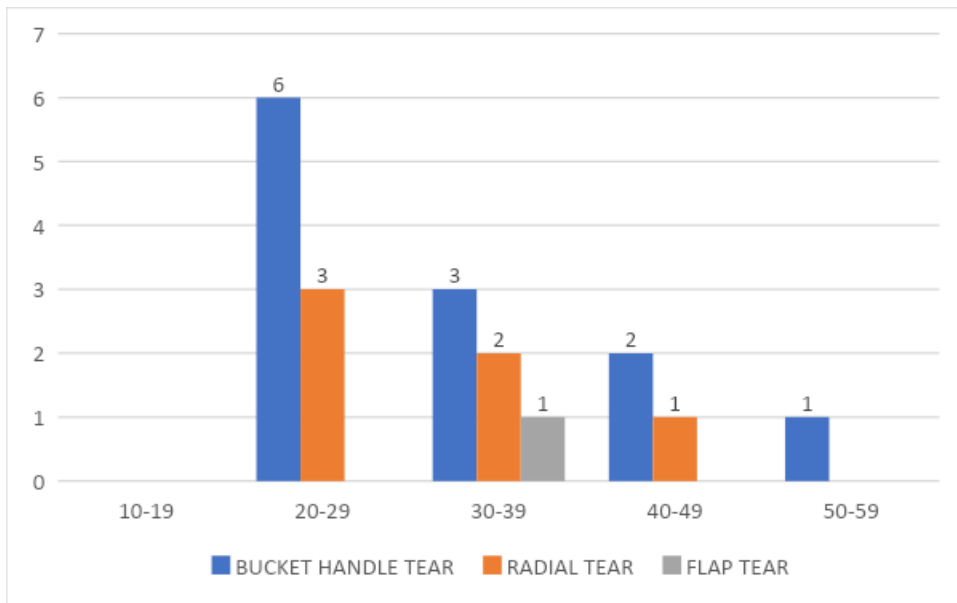
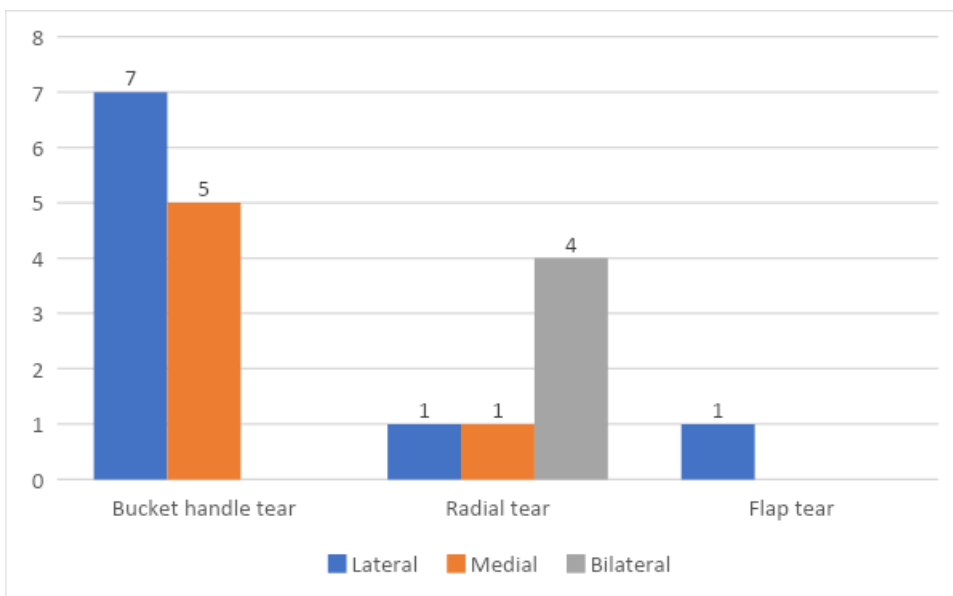


Table 6:

Morphology	Lateral	Medial	Bilateral	Chi-square value	P value
Bucket handle tear	7	5	0	11.87	0.018
Radial tear	1	1	4		
Flap tear	1	0	0		



References:

- 1.Sutton B: Ligaments: their nature and morphology. Bristol Med Chir J (1883). 1897, 15:344.
- 2.Menisal tears: Current understanding, diagnosis and management
Kavyansh Bhan
- 3.Feucht MJ, Bigdon S, Bode G, Salzmann GM, Dovi-Akue D, Südkamp NP, Niemeyer P. Associated tears of the lateral meniscus in anterior cruciate ligament injuries: risk factors for different tear patterns. Journal of orthopaedic surgery and research. 2015 Dec;10(1):1-8.
- 4.Mansori AE, Lording T, Schneider A, Dumas R, Servien E, Lustig S. Incidence and patterns of meniscal tears accompanying the anterior cruciate ligament injury: possible local and generalized risk factors. International orthopaedics. 2018 Sep;42(9):2113-21
- 5.Bisson LJ, Kluczynski MA, Hagstrom LS, Marzo JM. A prospective study of the association between bone contusion and intra-articular injuries associated with acute anterior cruciate ligament tear. The American journal of sports medicine. 2013 Aug;41(8):1801-7.
- 6.Matsumoto, H., Suda, Y., Otani, T., Niki, Y., Seedhom, B. B., Fujikawa, K. (2001). [Roles of the anterior cruciate ligament and the medial collateral ligament in preventing valgus instability](#). J Orthop Sci, 6(1), 28-32.
- 7.Sanders TL, Maradit Kremers H, Bryan AJ, Larson DR, Dahm DL, Levy BA, Stuart MJ, Krych AJ. Incidence of anterior cruciate ligament tears and reconstruction: a

21-year population-based study. *The American journal of sports medicine*. 2016 Jun;44(6):1502-7.

8.Duncan JB, Hunter R, Purnell M, Freeman J. Meniscal injuries associated with acute anterior cruciate ligament tears in alpine skiers. *The American journal of sports medicine*. 1995 Mar;23(2):170-2.

9.Hagino T, Ochiai S, Senga S, Yamashita T, Wako M, Ando T, Haro H. Meniscal tears associated with anterior cruciate ligament injury. *Archives of orthopaedic and trauma surgery*. 2015 Dec;135(12):1701

10.Bellabarba C, Bush-Joseph CA, Bach Jr BR. Patterns of meniscal injury in the anterior cruciate-deficient knee: a review of the literature. *American journal of orthopedics (Belle Mead, NJ)*. 1997 Jan 1;26(1):18-23.

11.Arnold JA, Coker TP, Heaton LM, Park JP, Harris WD. Natural history of anterior cruciate tears. *The American journal of sports medicine*. 1979 Nov;7(6):305-13.

12.Binfield PM, Maffulli N, King JB. Patterns of meniscal tears associated with anterior cruciate ligament lesions in athletes. *Injury*. 1993 Sep 1;24(8):557-61.

13.Byrne L, King E, Mc Fadden C, Jackson M, Moran R, Daniels K. The effect of meniscal pathology and management with ACL reconstruction on patient-reported

outcomes, strength, and jump performance ten months post-surgery. *The Knee*. 2021 Oct 1;32:72-9.

14. Anderson AF, Anderson CN. Correlation of meniscal and articular cartilage injuries in children and adolescents with timing of anterior cruciate ligament reconstruction. *The American journal of sports medicine*. 2015 Feb;43(2):275-81.

15. Lerer DB, Umans HR, Hu MX, Jones MH. The role of meniscal root pathology and radial meniscal tear in medial meniscal extrusion. *Skeletal radiology*. 2004 Oct;33(10):569-74.

16. Kenny C. Radial displacement of the medial meniscus and Fairbank's signs. *Clinical Orthopaedics and Related Research*®. 1997 Jun 1;339:163-73.

17. Petersen W, Forkel P, Feucht MJ, Zantop T, Imhoff AB, Brucker PU. Posterior root tear of the medial and lateral meniscus. *Archives of orthopaedic and trauma surgery*. 2014 Feb 1;134(2):237-55.

18. Anderson L, Watts M, Shapter O, Logan M, Risebury M, Duffy D, Myers P. Repair of radial tears and posterior horn detachments of the lateral meniscus: minimum 2-year follow-up. *Arthroscopy: The Journal of Arthroscopic & Related Surgery*. 2010 Dec 1;26(12):1625-32.

19. Jeffery D Voigt, Michael Mouser and Bryan Huber : In-office diagnostic Arthroscopy for knee and shoulder intra-articular injuries its potential impact in cost savings in the United States

20. Karan A Patel, David E. Hartigan, Justin L. Makovicka et al : Diagnostic evaluation of the Knee in the Office Setting Using Small-bore needle Arthroscopy