

CASE REPORT ON GASTRIC CARCINOMA

ABSTRACT

Introduction : Gastric cancer or stomach cancer is an any malignant tumor arising from the region extending between the gastroesophageal (GE) junction and the pylorus. The incidence and mortality of gastric cancer have been declining in most developed countries. The age-adjusted risk fell 5% from 1985-1990. **Clinical Findings :** Abdominal pain in an region, weakness and loss of appetite from 50 days, pain in lower limb from one month, nausea and vomiting, history of passage of black color stool (for two days, 50 days back), loss of weight five kg in last one month **Diagnostic Evaluation :** Hb - 11.2 gm/dl Decreased , RBC 4.17cumm, CBC MCH- 22.6 Pico gm (decrease), Platelet -1.2 lakhs / cumm (decrease), Eosinophil- 9 % (increase) Monocytes-2% (decrease) ,KFT- sodium – 132 meq/L (decrease) LFT -bilirubin (conjugated) – 0.30 gm %(decrease) Bilirubin (unconjugated) 0.33 gm % { decrease}, CT scan, MRI, Upper GI endoscopy - showed abnormal mass ,Endoscopic ultrasound lesion as small as 2-3 mm in diameter, USG CECT Abdomen Report- showed enhancing wall thickening Involving body of gastric without obvious perigastric extension Or significant, consistent with gastric carcinoma. Histopathology report of gastrectomy specimen showed poorly Differentiated adenocarcinoma gastric- mixed type – pT4a N1 M0 **Therapeutic Interventions :** Inf. Metrogyl 500 mg TDS, Inj. Amikacin 500 mg OD, Inj. Pantop 40 mg BD , Inj. Piptaz in 100ml NS 4.5 mg TDS ,Inj. Levoflox 500 mg OD, Tab. Telma 40 mg OD, Inj. PCM in 100ml NS 500 mg TDS, Chemotherapy and Radiation therapy was also Done **Outcome :** After treatment, the patient show improvement. His abdominal pain , nausea and vomiting , pain in lower limb were relieved and After all pharmacological, surgical and medical intervention , patient is now in stables condition his mental and it physical condition is improving and laboratory value are in normal range, and he is able to do his daily activities. **Conclusion:** My patient was admit in surgery Ward No- 28 , AVBRH with a known case of Gastric carcinoma and he had complaint of abdominal pain, nausea and vomiting ,pain in lower limb , weakness, black color stool and loss of appetite. After getting appropriate treatment his condition was improve.

Keywords : Gastric Carcinoma, Endoscopy, Chemotherapy, Radiation, therapy, symptoms of Gastric carcinoma, Management

Introduction

Gastric carcinoma, is the accumulation of an Abnormal group of cells that form a mass in a part of the stomach. It consistsof Gastric cancer is classified as follows:

GASTRIC CA IN THE EARLY STAGES – mucosa & submucosa ADVANCED GASTRIC CA – into or through diseased forms of the muscularis propriatwo, both intestinal and diffuse. The small

intestine Around 90-95 percent of all gastric carcinomas are Adenocarcinoma. According to the WHO, 723,000 Carcinoma-related deaths are caused by gastric Carcinoma each year, globally. It is the fifth most common carcinoma worldwide.

Defination:

In its early stages, gastric cancer is generally asymptomatic or causes only nonspecific symptoms. One of the main reasons for its poor prognosis is that by the time symptoms appear, the cancer has often spread to other parts of the body. The following signs and symptoms may occur as a result of gastric carcinoma:

Early signs include indigestion or a burning sensation in the chest (heartburn), Appetite loss, especially for meat

Investigation:

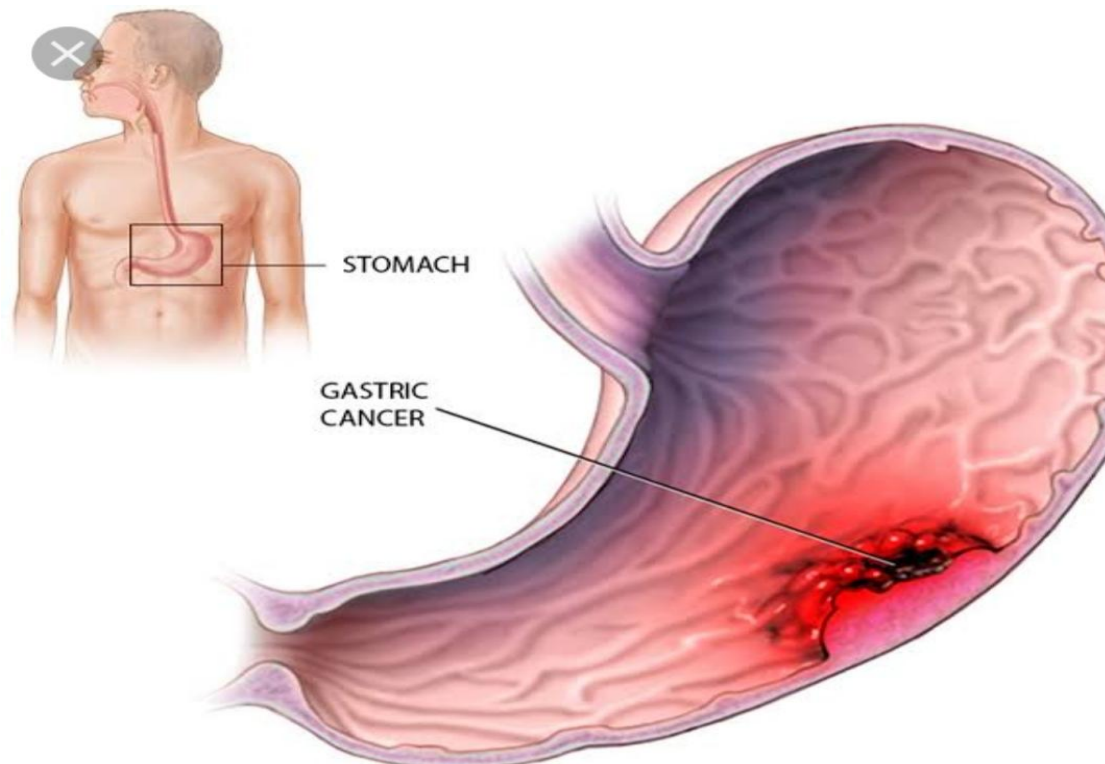
Blood tests, CT scans, MRIs, USGs, CECTs, biopsies, stool examinations for occult blood, stomach function tests – which will detect gross hypo/achlorhydria, and endoscopy are all typical cancer investigations.

Gastric cancer is classified as follows:

GASTRIC CA IN THE EARLY STAGES – mucosa & submucosa GASTRIC CA – injected into or through the muscularis propria. Gastric cancer is classified as follows by the World Health

Organization

(WHO):



management : is include the surgical therapy , Endoscopy therapy, Endoscopy Mucosal Resection, Chemotherapy and Radiation therapy , palliative care is also given to the patient.

Nursing management:

Nursing care of patient with gastric carcinoma is similar to that for other patients with carcinoma and addresses the physiologic and psychological needs of the patient. Physiologic problems are primarily . Due to gastrointestinal manifestation of the disease. Nursing care strategies will reduce the pain, Discomfort and to prevent complication.

Patient Identification : A 50 years male from Dasonapur district Adilabad admitted to surgery ward no 28, AVBRH on 26 February 2021. He diagnosed as case of Gastric Carcinoma.

Present Medical History : A 50 years male was brought to AVBRH on 26 February 2021 admitted in surgery word no. 28 with a Chief complains of abdominal pain in Epigastric region, weakness and loss of appetite from 50 days, pain in lower limb from one month, history of passage of black color stool (for two days, 50 days back), loss of weight five kg in last one month. He is diagnosed as case of Gastric Carcinoma .

Past Medical History : My patient come in A.V. B. R. H on date 26 February 2021 he having the history of Hypertension from since last 7 years under the medication Amlodipine 40 and telmisartan.

Family History : My patient is belongs to middle class family and his Family is nuclear family. There are 4 members in his family. All members in his family are healthy. All other members of the family were not having complaints in their health except from my patient who was being admit in the hospital.

Past Interventions and Outcome : My patient diagnose as Gastric Carcinoma. After treatment, the patient show improvement. His abdominal pain, nausea and vomiting, pain in lower limb were relieve and After all pharmacological, surgical and medical intervention, patient is now in stables condition his mental and it physical condition is improving and laboratory value are in normal range, and he is able to do his daily activities.

Personal History :My Patient is smoker from last 15 years one bundle of bidi per day and occasionally taking alcohol

Clinical Findings : Abdominal pain in epigastric region , weakness and loss of appetite from 50 days, pain in lower limb from one month, history of passage of black color stool (for two days, 50 days back), loss of weight five kg in last one month.

Etiology : Gastric carcinoma causes include Infection of the gastric with the bacterial organism H.Pylori , Gastric Polyps , Bile reflux , Epstein-Barr virus: EBV account for 7% to 18% of all cases, working in coal , metal, timmber or rubber industries, a family history of gastric ulcer , long term stomach inflammation, pernicious anemia, stomach surgery for an ulcer and a diet in high smoked, pickled or salty food .

Physical Examination : On physical examination patient is conscious and oriented to self, time, place and person. He was dull and cooperative, well dressed and groome. Patient was afebrile, pulse and respiration was normal with Increase BP. On abdominal examination, pain is present in epigastric region, abdomen was distend, no visible veins; abdomen was soft and tenderness present over epigastric and umbilical region. Bowel sound was present. In cardiovascular system assessment, no chest deformity, S1 and S2 Heard normal. On respiratory assessment, bilateral wheeze sound heard in upper lobe and pulmonary Function test report shown suspected severe Restrictive abnormality.

Diagnostic Assessment : Diagnostic Evaluation: Hb – 11.2 gm/dl Decreased, RBC 4.17cumm, CBC MCH-22.6 Pico gm (decrease), Platelet -1.2 lakhs/ cumm (decrease), Eosinophil-9% (increase)Monocytes-2% (decrease),KFT- sodium-132 meq/L(decrease) LFT-bilirubin(conjugated)-0.30 gm 6(decrease) Bilirubin (unconjugated) 0.33 gm %{ decrease}, CT scan,MRI, Upper GI endoscopy showed abnormal mass, Endoscopic ultrasound lesion as small as 2-3 mm in diameter, USG, CECT Abdomen Report - showed enhancing wall thickening Involving body of gastric without obvious perigastric extension Or significant, consistent with gastric carcinoma. Histopathology report of gastrectomy specimen showed poorly Differentiated adenocarcinoma gastric- mixed type – pT4a N1 MO

Therapeutic Interventions : Inf. Metrogl 500 mg TDS, Inj. Amikacin 500mg OD, Inj. Pantop 40 mg BD , Inj. Piptaz in 100ml NS 4.5 mg TDS, Inj. Levoflox 500 mg OD , Tab. Telma 40 mg OD , Inj. PCM in 100ml NS 500 mg TDS, Chemotherapy and Radiation therapy is also given.

Discussion

A 50 years old male from Dasonapur district Adilabad was Admitted to surgery ward no 28. AVBRH on 26 February 2021 with a symptom of epigastric abdominal pain region, weakness and loss of appetite from 50 days, pain in lower limb from one month, history of passage of black color stool (for two days, 50 days back), loss of weight five kg in last one month. As soon as he was admitted to hospital investigations such as Blood Investigation, CT scan, MRI, Endoscopy were done and appropriate treatment were started. After getting treatment. He shows great improvement and the treatment was still going on till my last date of care. In this case report study about the

Conclusion:

Gastric carcinoma is a disease that affects the stomach and then spreads to the rest of the body's organs.

Metastases begin in the body.

It is critical to diagnose the patient at an early stage so that the disease does not cause consequences.

It is also critical to adopt preventive measures, such as limiting the amount of alcohol consumed and refraining from using tobacco products.

Smoked and pickled meals, as well as salted meats and fish, should be avoided.

Consume plenty of fresh fruits and vegetables, as well as whole grain breads, cereals, pasta, and rice.

Maintain a healthy body mass index (BMI).

After receiving medication, chemotherapy, and radiation therapy, my patient has made a significant improvement.

Clearance : Taken from institutional ethics Committee.

Patient Inform Consent : While preparing case report and for publication patient's informed consent has been taken

Source of Funding : Self.

Conflict of Interest : Nil

Reference

- 1) Lewis's Medical Surgical Nursing: Assessment and Management of Clinical Problems. 7th Ed. New Delhi: Elsevier; 2011.p.1036-1039.
- 2) Brunner and Suddarth,s Textbook of Medical and Surgical Nursing , 10th Edition, page 1108-1112
- 3) Essentials of Anatomy and Physiology, 8th Edition , page 106-115
- 4) Lippincott. Manual of Nursing Practice, 9th Edition page 1688-1690
- 5) Jemal A, Bray F, global cancer statistics CA cancer 2011;61
- 6) Simpson J, roman Law. Preliminary analysis of cancer 1971-1990
- 7) Aragones N, Pollan stomach cancer and occupation in Sweden 1971-1989