

Radiological Findings in COVID-19 Patients

Review Article

ABSTRACT

After its starting point in Wuhan, China, Corona Virus related respiratory disease has been spread worldwide and pronounced by WHO in 2020. Since it's obtained through respiratory beads, local area spread is obligated for the new worldwide emergency. RT-PCR and a few serology tests, including but not limited to the recently affirmed five-minute serology assays, are examples of demonstrative techniques. The infection influences lower respiratory tract illness. Recounted encounters have shown that imaging qualities are essential to the conclusion as radiological proof of infection shows up preceding clinical indications, which can be valuable in anticipating the phase of the illness. According to the exam, a CT scan is much more sensitive than a chest X-Ray in identifying these lung progressions.

Keywords: Virus; RT-PCR; CT Scan; X-ray.

1. INTRODUCTION AND BACKGROUND

It has influenced 1,099,389 individuals and professed to have 58,901 living souls [1]. The COVID pandemic is one of the deadliest known scourges lately. COVID-19 cases in this quantity are expanding dramatically day by day and, with no complete treatment or accessible antibody in see, making devastation for the wellbeing and monetary frameworks of the whole world. Wuhan, Hubei, China's regional capital, was the major case. These are thought to be pneumonia cases from a strange place in China. China threatened the World Health Organization (WHO) with a presence in Wuhan on several uncommon forms of pneumonia that may be seen within an infected person's lungs as the infection spread. Experts discovered and stated that the virus that caused the respiratory tract infection belonged to the Coronaviradae family and that it was almost comparable to the last two plagues, Middle Eastern Respiratory Syndrome (MERS) and Severe Acute Respiratory Syndrome (SARS) (SARS). On February 11, 2020, the International Committee on Virus Taxonomy (ICTV) identified the new disease SARS-CoV-2. SARS-CoV-2-related sickness was formally classified as COVID-19 by the World Health Organization (WHO) (ICD) [2].

2. REVIEW

COVID disease, after having begun with the bat-to-human transmission, is now primarily transmitted from person to person (i.e., within a local area) through communication, respiratory beads, and airborne transmission. [three] People's respiratory systems are the primary concern of the illness. The S protein, which is present in the architecture of COVID, This pathophysiology of the infection clarifies the power of respiratory adverse effects by connecting to the ACE2 receptor conveyed inside the alveolar epithelium [3].

3. DIAGNOSIS

The ability to diagnose the disease quickly and accurately is essential in initiating treatment and reducing the spread of the disease. RT-PCR monitoring in the laboratory and chest X-beam and CT scans are all part of the open conclusion as of today. On March 3, 2020, the Centers for Disease Control (CDC) approved an inspection of the research facility based mainly on RT-PCR using samples from the upper and lower parcels [4]. RT-PCR has a low risk of 60-70 percent, despite being highly specific for the condition (95-97 percent) [5,6] Several serology tests are available, and on March 27, 2020, the Food and Drug Administration (FDA) authorized a five-

minute serology testing device [7]. Radiological observation is beneficial for infection testing and follow-up. It gives us a quick understanding of the pathophysiology of infection-infection relationships. Common findings include abnormalities and used pneumonia as a COVID-related respiratory disease seen clinically as pneumonia [6,8]. Despite the fact that chest X-rays are less sensitive than CT scans, they can be used as a first-line method because of their availability and convenience. Chest X-ray abnormalities are typical before the clinical phase of infection begins, peaking 10-12 days after the beginning of clinical side symptoms [9]. Fig. 1 depicts the initial and arriving stages of COVID-19 infected patients after the X-beam was discovered.

4. ARDS - ACUTE RESPIRATORY DISTRESS SYNDROME

Chest CT scan has a stronger affectability in diagnosing COVID-19 than RT-PCR [10]. There has been much discussion over whether or not a CT scan should be used as the

cutting-edge measurement instrument for the COVID-19 finding. [9] CT results began to surface long before an infected person had a positive COVID-19 lab aftereffect. [11] As shown in Fig. 2, CT scan findings go through five stages, according to Jin et al. [12].

5. LUNG ULTRASOUND

According to Soldati et al., lung ultrasound (LUS) can indisputably differentiate alterations in shallow lung parenchyma with more precision than chest X-rays, which can play a significant role in the emergency, conclusion, and prognostic isolation of patients in ER and ICU settings [13-19] fourteenth) fourteenth) fourteenth) fourteenth) fourteenth) fourteenth) Poggiali and her colleagues recently reported a study in which ultrasound results in COVID-19 pneumonia patients matched CT findings, indicating that LUS might be effective for early diagnosis of COVID-19 pneumonia in ER patients fifteenth).

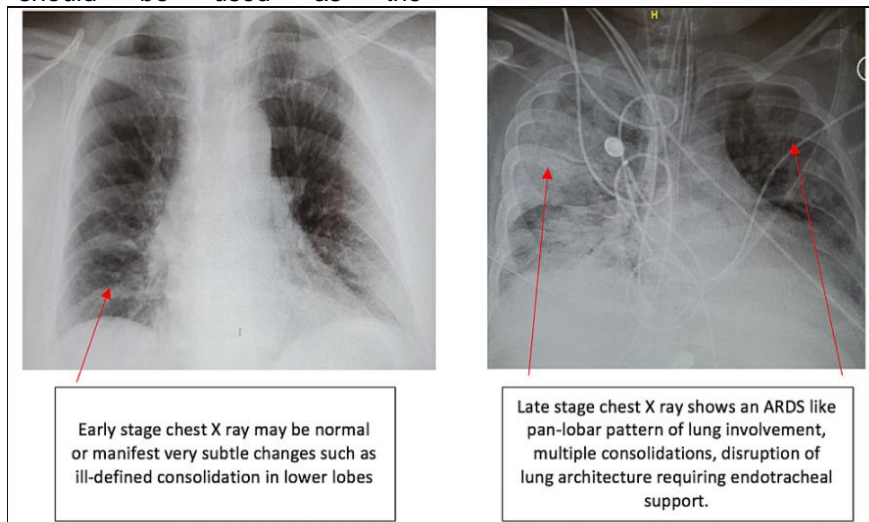


Fig. 1. Early and late-stage X-ray findings in patients with COVID-19 infection

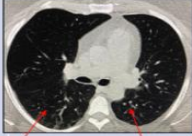

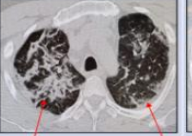
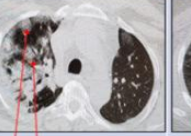
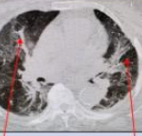
	Ultra-Early Stage	Early Stage	Rapid progression Stage	Consolidation Stage	Dissipation Stage
Findings	<ul style="list-style-type: none"> • Prior to symptom onset. • Throat swab positive, laboratory negative • Usually within 1-2 weeks of exposure. 	<ul style="list-style-type: none"> • Patients present with symptoms (within 1-3 days of symptoms like fever, dry cough). • On histopathology - There is congestion of alveolar capillaries resulting in alveolar and interlobular interstitial edema. 	<ul style="list-style-type: none"> • This stage follows within 3-7 days of symptomatic presentation. • There is an escalation in the hyperinflammatory response. Fibrous extensions that connect the alveoli begin to develop. 	<ul style="list-style-type: none"> • This phase coincides with 2nd week of clinical symptoms. • The vascular congestion diminishes and fibrosis predominates. 	<ul style="list-style-type: none"> • It occurs about 2-3 weeks after initial symptomatic presentation. • There is more of a healing and repair response within the lungs .
Images	 <p>CT scan demonstrates Bilateral, subpleural, multiple scattered ground glass opacities.</p>	 <p>CT scan shows multiple, bilateral ground glass opacities. Irregular, interlobular septa begin to develop.</p>	 <p>CT findings include subpleural, posterior consolidations, dispersed air bronchograms along with superimposed irregular septa.</p>	 <p>There is a decrease in size and density of consolidations.</p>	 <p>CT scan shows patchy consolidation, reticular opacities (strip-like opacities), bronchial and interlobular septal thickening.</p>

Fig. 2. CT scan stages in patients with COVID-19 infection

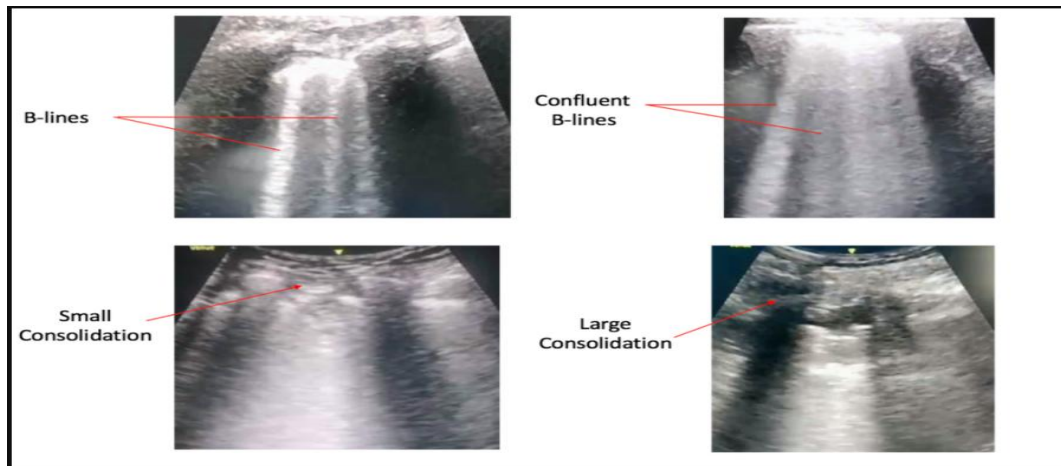


Fig. 3. Lung ultrasound findings in patients with COVID-19 infection

6. CONCLUSIONS

Although most patients recover entirely from illness, they will probably develop chronic lung damage. Only time will tell of the magnitude of the irreversible lung injury. Radiological radiation detection is essential and provides a preview of the treatment course of infection and should be used to evaluate long-term travel outcomes. Presently numerous investigates are being done on COVID - 19. With the wealth of most recent data accessible, we notice the changing patterns in symptomatic and therapeutic ways to deal with the irresistible transmittable illness.

CONSENT

It is not applicable.

ETHICAL APPROVAL

It is not applicable.

COMPETING INTERESTS

Authors have declared that no competing interests exist.

REFERENCES

1. COVID-19 Dashboard by the center for Systems Science and Engineering (CSSE) at Johns Hopkins University (JHU); 2020. Accessed: 4/1/2020. Available:<https://coronavirus.jhu.edu/map.html>.
2. Naming the coronavirus disease (COVID-19) and the virus that causes it; World Health Organization (WHO); 2020. Accessed: 4/2/2020:

- Available:[https://www.who.int/emergencies/diseases/novel-coronavirus-2019/technical-guidance/naming-the-coronavirus-disease-\(co...](https://www.who.int/emergencies/diseases/novel-coronavirus-2019/technical-guidance/naming-the-coronavirus-disease-(co...)
3. Jr BFP, Federico R. Tewes. What attorneys should understand about Medicare set-aside allocations: How Medicare Set-Aside Allocation Is Going to Be Used to Accelerate Settlement Claims in Catastrophic Personal Injury Cases. *Clinical Medicine and Medical Research*. 2021;2(1):61-64. Available:<https://doi.org/10.52845/CMMR/2021v1i1a1>
 4. Zhou P, Yang X, Wang X, et al. A pneumonia outbreak associated with a new coronavirus of probable bat origin. *Nature*. 2020;579:270-273. DOI:10.1038/s41586-020-2012-7
 5. CDC Tests for COVID-19; Center for Disease Control and Prevention; 2020. Accessed: 4/1/2020: Available:<https://www.cdc.gov/coronavirus/2019-ncov/about/testing.html>.
 6. Mossa-Basha M, Meltzer CC, Kim DC, Tuite MJ, Kolli KP, Tan BS: Preparedness for COVID-19: Radiology Scientific Expert Panel. *Radiology*; 2020. Accessed: 4/1/2020: DOI:10.1148/radiol.2020200988
 7. Daniel V, Daniel K. Diabetic neuropathy: new perspectives on early diagnosis and treatments. *Journal of Current Diabetes Reports*. 2020;1(1):12–14. Available:<https://doi.org/10.52845/JCDR/2020v1i1a3>
 8. Kanne JP, Little BP, Chung JH, Elicker BM, Ketai LH: Essentials for radiologists on COVID- 19: an update - Radiology Scientific Expert Panel. *Radiology*; 2020. Accessed: 4/1/2020: DOI:10.1148/radiol.2020200527
 9. Detect COVID-19 in as little as 5 minutes; Abbott; 2020. Accessed: 4/1/2020: Available:<https://www.abbott.com/corpnewroom/product-and-innovation/detect-covid-19-in-as-little-as-5-minutes.html>.
 10. Daniel V, Daniel K. Perception of Nurses' Work in Psychiatric Clinic. *Clinical Medicine Insights*. 2020;1(1):27-33. Available:<https://doi.org/10.52845/CM/2020v1i1a5>
 11. Kooraki S, Hosseiny M, Myers L, Gholamrezanezhad A: Coronavirus (COVID-19) outbreak: what the department of radiology should know. *J Am CollRadiol*. 2020;17:447-451. DOI:10.1016/j.jacr.2020.02.008
 12. Wong HYF, Lam HYS, Fong AH, et al. Frequency and distribution of chest radiographic findings in COVID-19 positive patients. *Radiology*; 2020. Accessed: 4/1/2020: DOI:10.1148/radiol.2020201160
 13. Daniel V, Daniel K. Exercises training program: It's Effect on Muscle strength and Activity of daily living among elderly people. *Nursing and Midwifery*. 2020;1(01): 19-23. Available:<https://doi.org/10.52845/NM/2020v1i1a5>
 14. Ai T, Yang Z, Hou H, et al. Correlation of chest CT and RT-PCR testing in coronavirus disease 2019 (COVID-19) in China: A report of 1014 cases. *Radiology*; 2020. Accessed: 4/1/2020: DOI:10.1148/radiol.2020200642
 15. Kenny JES, Canepa CM: An illustrated guide to the chest CT in COVID. *Pulm CCM*; 2020 Accessed: 4/1/2020: Available:<https://pulmccm.org/uncategorize/d/an-illustrated-guide-to-the-chest-ct-in-covid-19/>.
 16. Jin Y, Cai L, Cheng Z, et al. A rapid advice guideline for the diagnosis and treatment of 2019 novel coronavirus (2019-nCoV) infected pneumonia (standard version). *Mil Med Res*. 2020,7:16. DOI:10.1186/s40779-020-0233-6
 17. Soldati G, Smargiassi A, R Inchingolo, et. al.: Is there a role for lung ultrasound during the COVID-19 pandemic?. *J Ultrasound Med*; 2020, in press. DOI:10.1002/jum.15284
 18. Poggiali E, Dacrema A, Bastoni D, et. al.: Can lung US help critical care clinicians in the early diagnosis of novel coronavirus (COVID-19) pneumonia?. *Radiology*; 2020. Accessed: 4/1/2020: DOI:101148/radiol.2020200847
 19. Coronavirus disease. Situation Summary; Centers for Disease Control and Prevention (CDC); 2019.(3/18/2020). Accessed: 4/2/2020 Available:<https://www.cdc.gov/coronavirus/2019-ncov/cases-updates/summary.html>.