

Acute Fatty Liver of Pregnancy-a rare but potentially catastrophic cause of Jaundice in pregnancy

ABSTRACT:

A 27-year-old female primigravida at 36.2 weeks gestational age presented nausea, vomiting, and yellowish discoloration of the eyes. On investigation, she had deranged liver and kidney functions, and USG was suggestive of Coarse Echotexture of the Maternal liver. We diagnosed it as a case of Acute fatty liver of pregnancy followed by Early Caesarean section and intensive supportive management. Active monitoring of Haemodynamic status, Metabolic status, Coagulation profile, Renal, and CNS function resulted in a safe and healthy mother and child.

Keywords- Jaundice, Acute Fatty Liver of Pregnancy, Disseminated Intravascular Coagulation, HELLP Syndrome

INTRODUCTION:

The liver is one of the many organs affected during Pregnancy due to metabolic and hormonal changes associated with pregnancy. Liver disease in pregnancy presents mainly with jaundice with common causes being Viral hepatitis (most common), Drug-induced, Gall stones, Cholestatic jaundice, HELLP syndrome, and underlying chronic liver diseases such as liver cirrhosis and chronic hepatitis, and may rarely present as Acute fatty liver of pregnancy. (1)

Acute fatty liver of pregnancy is an uncommon cause of jaundice in pregnancy and is an obstetric emergency. It has been found that 1:7,000 to 1:20,000 pregnancies is the approximate incidence of Acute Fatty Liver of Pregnancy. It is mainly a disease affecting patients in their third trimester or postpartum peri, resulting in liver failure and maternal and fetal mortality. AFLP is usually diagnosed by ruling out all other differential diagnoses and requires prompt intervention. Maternal and fetal prognosis has been transformed thanks to rapid diagnosis and timely delivery of the baby. (2) The diagnosis should be suspected in the face of the appearance of epigastric pain, vomiting, jaundice associated with an increase in transaminases. AFLP shows a high degree of association with preterm labor, fetal growth restriction, and fetal distress. Causes of maternal death are mainly coagulation failure, DIC, renal failure, hepatic coma, Acute Hepatic failure, Hepatorenal syndrome, and septicemia. (3)

We are presenting this rare case as rapid diagnosis, timely delivery, and immense supportive care are of great importance to avoid poor outcomes and prevent a delay in the diagnosis that may cause severe catastrophic complications associated with high mortality. (4)

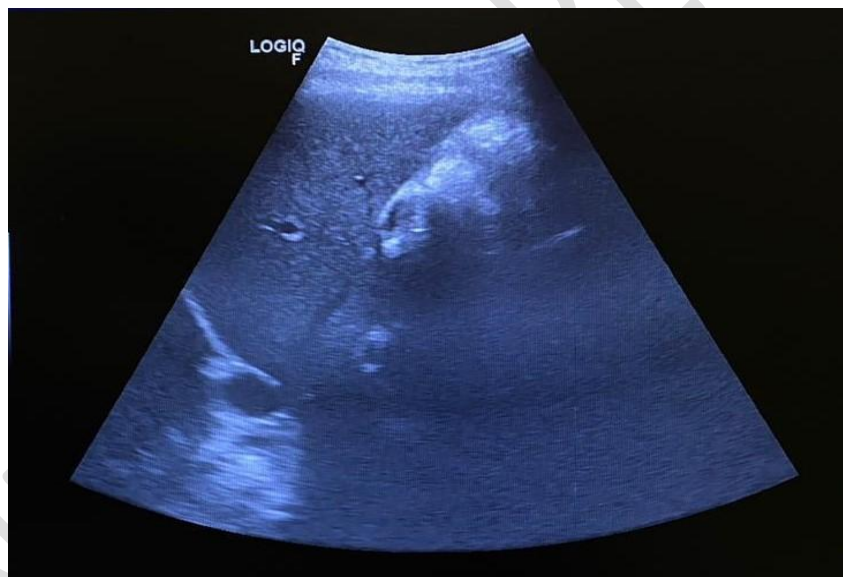
CASE DESCRIPTION:

A 27-year-old Primigravida with 36 weeks and 2 days Gestational Age presented to the tertiary care center given complaints of nausea, vomiting, and yellowish discoloration of the eyes. She was alright 4 days back when she developed nausea, vomiting 3-to four episodes per day, and yellowing of the eyes. She had no complaints of itching all over her body. There was no history of fever episodes, cough, cold, or loose stools. She was a booked patient, and in previous Antenatal Clinic (ANC) visits, she had no similar signs and symptoms. There was no history of traveling to regions endemic to malaria. There were no long-term morbid diseases and no history of intake of drugs like paracetamol, aspirin, sodium valproate, or herbal medicine in the past. No history of Sickle cell disease. On Clinical examination, she was conscious, cooperative, and well oriented in time, place, and person. Vitals on admission were Pulse 84 beats per minute, Blood pressure 118/80 mmHg, and temp 37.1 degrees Celsius. She had no pallor but bilateral edema feet up to the ankles and icterus of the bilateral sclera at the presentation. Cardiovascular and Respiratory examinations were unremarkable per abdomen examination-soft, non-tender, no guarding/ rigidity, and no organomegaly. The fundal height was 36 weeks, cephalic, relaxed, and the fetal heart sounds present regular, and 140 beats per minute. Per vaginal examination, the cervix was 1cm dilated, minimally effaced, the station was high up, membranes were present, and presenting part was vertex.

On investigation, her Haemoglobin was normal (14 g/dl), **white blood cell count (WBC) was raised (15,800/mm³)**, and Platelets (PLT) remained normal (1.86 lakhs/ mm³). Her early and late Sickling tests came negative. On Liver function tests, there was **raised Alkaline phosphatase (ALP) (540 U/L) with severely elevated Serum Glutamate Oxaloacetate Transaminase (SGOT) (231 U/L) and Serum Glutamate Pyruvate Transaminase (SGPT) (200 U/L)**. Total protein and albumin were normal (6.7g/dL and 3.5g/dL, respectively). **Total bilirubin was raised (5.9mg/dL) with raised conjugated bilirubin (4.7mg/dl). Serum LDH (607U/L) and Serum Uric Acid levels (7.7mg/dl) were raised.** Kidney Function was also deranged with **raised creatinine (1.3mg/dl)** and normal Urea, Sodium, and Potassium. The urinalysis was negative but showed the presence of trace urine albumin. Human Immunodeficiency Virus (HIV), Hepatitis B surface Antigen (HBsAg), and Hepatitis C virus (HCV) status came negative. Anti HCV, Anti HEV, and Anti-Nuclear antibodies (ANA) were also negative. Coagulation studies were deranged with **raised Prothrombin time 17.3secs (Control 12.5secs), raised INR (1.38), and Activated Partial Thromboplastin Time (APTT) being 42.7secs (Control- 30secs)** for which she was given inj. Vitamin K Intramuscularly once a day for 3 days to prevent coagulation failure. She had episodes of **hypoglycemia (RBS-60mg%)** which was corrected with an infusion of 10% dextrose followed by 5% dextrose and glucose powder 6hrly. To prevent and treat micronutrient deficiency, she was given a VMI drip in 5% Dextrose, followed by multivitamin capsules. Active monitoring of vital organs' clinical, hematological and biochemical profiles was done every 48-72hrs.

USG was done for her on the day of admission, which was suggestive of a Single live Intrauterine fetus (SLIUF) of average Gestational age of 33 weeks and 5 days, Estimated fetal Weight of 2255gms, with Placenta Fundo posterior Grade 2, with Severe Oligohydramnios (Amniotic Fluid Index- 4), with **Coarse Echotexture of Maternal Liver (Liver size 13.5cms)** as seen in Figure 1. B/L Kidneys, Spleen, Pancreas, and Urinary bladder were normal. No other imaging studies were ordered.

Fig 1- USG Abdomen showing Coarse Echotexture of maternal Liver (Liver size 13.5cms)



A detailed analysis of clinical and laboratory findings helped rule out preeclampsia and HELLP Syndrome, and after an evaluation of the **Swansea Criteria** (more than six criteria fulfilled- vomiting, elevated bilirubin, hypoglycemia, leucocytosis, elevated transaminases, raised uric acid, coagulopathy- raised PT-INR and aPTT), the patient was diagnosed to be a case Acute fatty Liver of Pregnancy.

The Swansea criteria for Diagnosis of Acute Fatty Liver of Pregnancy (more than equal to 6 criteria is diagnostic) are:

- Nausea and Vomiting
- Pain in abdomen
- Encephalopathy
- Polyuria/Polydipsia
- Increased bilirubin levels (>0.8 mg/dL or >14 micromol/L)
- Low blood sugars (<72 mg/dL or >4 mmol/L)

- Increased Leukocyte count (>11,000/cumm)
- Increased SGOT or SGPT (>42 IU/L)
- Increased Ammonia (>47 micromol/L)
- Increased urate (5.7 mg/dL or >340 micromol/L)
- Elevated Serum creatinine 1.7 mg/dL or >150 micromol/L
- Prothrombin time >14 seconds
- USG s/o Ascites
- Liver Biopsy showing Microvesicular Fatty Liver

The patient went into spontaneous labor and presented with Premature rupture of Membranes (PROM) and was draining thick Meconium Stained Liquor (MSL), which indicated an Emergency Lower Segment Caesarean Section. A baby boy weighing 2.1kg was delivered, cried immediately at birth with an APGAR score of 8/10, was shifted to NICU given mild Fetal distress. The baby was shifted to the mother's side on the same day with no active intervention. The further course of the baby was uneventful.

Postpartum maternal liver function improved with normalization of serum aminotransferases levels and improved coagulation profile and blood sugar levels after 48 to 72hrs of delivery. Blood sugar levels, prothrombin time (PT-INR), and partial thromboplastin time (PTT) were closely monitored postdelivery. After a due course of stay in the hospital with regular monitoring and management, the patient showed remarkable improvement in symptoms and was discharged from the hospital.

DISCUSSION:

AFLP, HELLP syndrome, and preeclampsia have overlapping findings that result in difficulty in differentiating these obstetrical syndromes from each other. As per various studies, signs of hepatic failure such as encephalopathy and coagulopathy as evident by elevated ammonia, prothrombin time, fibrinogen levels, and partial thromboplastin time are more commonly seen in cases of AFLP. The most common finding in HELLP syndrome, which presents with a severe degree of jaundice, is pain and tenderness in the epigastric region. Our patient did not present with any abdominal pain, tenderness, or low platelet count commonly found in HELLP syndrome; hence, we ruled out HELLP syndrome. (6) The patient had blood pressure within normal range during the prenatal course, and urine albumin was negative but had extensive coagulopathy. Preeclampsia was ruled out, and subsequently, AFLP was confirmed to be the definitive diagnosis. Considering these findings, we can differentiate these disorders with overlapping clinical signs and symptoms and focus on the distinct findings of these diseases to finally come to a correct diagnosis, thus helping us start a good and effective line of management. (7)

According to recent studies, the Swansea criteria have become an important screening tool for diagnosing AFLP and assessing the severity of the disease. A definitive diagnosis of AFLP can be made by liver biopsy, but it is hardly done as it is an invasive procedure that carries a high risk of intraperitoneal bleeding. On histopathological examination of liver biopsies, microvesicular steatosis in the centrilobular zone of liver lobules is seen on H & E and oil red O staining, as depicted in Figures 2 and 3. (8)

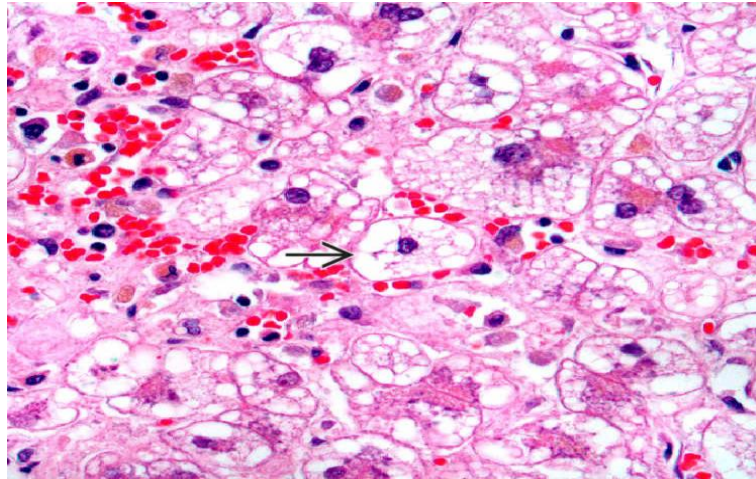
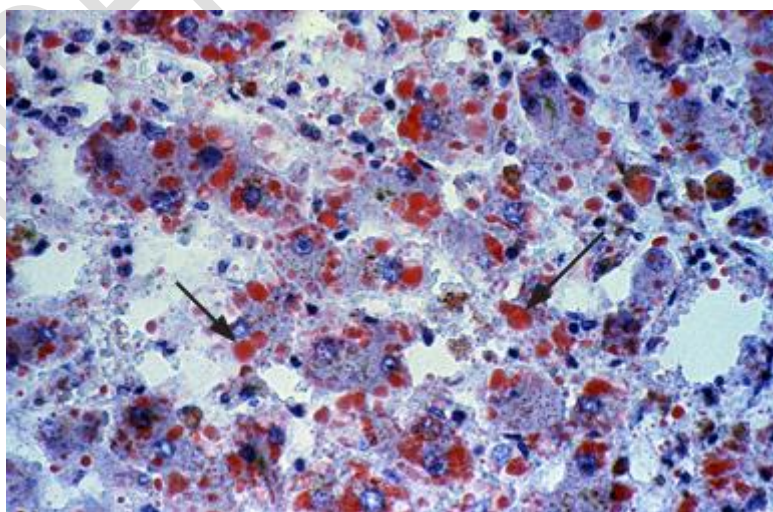


Fig 2-Extensive microvesicular steatosis typical of AFLP- multiple small steatotic vacuoles (arrow) surround and focally indent the hepatocyte nucleus

Fig 3- liver biopsy on Oil red O staining- vacuolated hepatocytes containing microvesicular fat which stains red (arrows).



The management of AFLP mainly involves maternal and fetal resuscitation and timely delivery of the baby irrespective of gestation. Glucose infusion (10% dextrose solution, additional 50% dextrose if and when required) and strict Blood glucose monitoring

are important until the liver function normalizes. (9) Blood products like packed red blood cells (PRCs), platelets, fresh frozen plasma (FFP), and cryoprecipitate are to be given as and when required. Whether to go for Vaginal or Caesarean delivery will depend on important factors like the baby and the mother's status and the possibility of successful labor induction. If a standard vaginal delivery can't be accomplished in 24hrs of labor induction, it is indicated to go for a Lower Segment Caesarean section. (10)

The catastrophic complication of AFLP is the development of Coagulopathies/DIC due to decreased production of coagulation factors by the liver. Therefore, patients with AFLP are at high risk of developing of complications such as postpartum and antepartum hemorrhage. (11) Monitoring patient's Coagulation profile that includes fibrinogen levels, Prothrombin Time, INR, and activated Partial Thromboplastin Time, and platelet count is of utmost importance for early diagnosis and management of overt coagulopathy. Seven to ten days after postdelivery, liver function starts to normalize. With early diagnosis and prompt delivery, aggressive resuscitation measures, and preterm delivery are uncommon. AFLP has a tendency to recur in subsequent pregnancies, however, the exact recurrence rate is not known thus patients should be counselled about subsequent pregnancies (12,13). Studies on fatty liver in different phenotypes were reviewed (14-16). Evidences of related issues were reviewed from articles by Patel et. al (17), Khatib et. al. (18) and Lozano et. al. (19).

CONCLUSION:

Early diagnosis and prompt delivery is of considerable importance in reducing unfavourable maternal outcomes in AFLP. Preeclampsia and HELLP syndrome have overlapping clinical findings with AFLP, therefore, it is of utmost importance to differentiate these from one another. Priority should be rapid diagnosis and timely management of AFLP in order to prevent Feto-maternal and neonatal mortality.

Disclaimer regarding Consent and Ethical Approval:

As per university standard guideline, participant consent and ethical approval have been collected and preserved by the authors

REFERENCES:

1. Acharya DN, Acharya DS, Shukla DS, Athvale DR, Shaveta D. Study of Jaundice in Pregnancy. Global Journal of Medical Research [Internet]. 2014 Feb 22 [cited 2021 Feb 21]; Available from: <https://medicalresearchjournal.org/index.php/GJMR/article/view/452>
2. Acharya N, Samal S, Sunilkumar, Acharya S, Shukla S. Pregnancy with Wilson's disease complicated with thrombocytopenia: a case report. International Journal of Advances in Medicine. 2017 Feb 11;1(2):155–7.
3. Rebahi H, Still ME, El Adib AR. A successful use of therapeutic plasma exchange in a fulminant form of acute fatty liver of pregnancy. J Gynecol Obstet Hum Reprod. 2019 Feb;48(2):133–7.
4. Nelson DB, Byrne JJ, Cunningham FG. Acute Fatty Liver of Pregnancy. Clin Obstet Gynecol. 2020;63(1):152–64.

5. Anon B, Barbet C, Gendrot C, Labarthe F, Bacq Y. [Acute fatty liver of pregnancy and mitochondrial fatty acid oxidation. Consequences for the offspring]. *Arch Pediatr*. 2017 Aug;24(8):777–82.
6. Ziki E, Bopoto S, Madziyire MG, Madziwa D. Acute fatty liver of pregnancy: a case report. *BMC Pregnancy Childbirth*. 2019 Jul 22;19(1):259.
7. Ronen J, Shaheen S, Steinberg D, Justus KR. Acute Fatty Liver of Pregnancy: A Thorough Examination of a Harmful Obstetrical Syndrome and Its Counterparts. *Cureus*. 2018 Feb 6;10(2):e2164.
8. Mikolasevic I, Filipec-Kanizaj T, Jakopcic I, Majurec I, Brncic-Fischer A, Sobocan N, et al. Liver Disease During Pregnancy: A Challenging Clinical Issue. *Med Sci Monit*. 2018 Jun 15;24:4080–90.
9. Gao Q, Qu X, Chen X, Zhang J, Liu F, Tian S, et al. Outcomes and risk factors of patients with acute fatty liver of pregnancy: a multicentre retrospective study. *Singapore Med J*. 2018;59(8):425–30.
10. Zhou M, Luo XD, Yang Y. [Analysis of changes in clinical characteristics and laboratory indexes of 54 cases of acute fatty liver of pregnancy]. *Zhonghua Gan Zang Bing Za Zhi*. 2019 Aug 20;27(8):638–42.
11. Minakami H, Morikawa M, Yamada T, Yamada T, Akaishi R, Nishida R. Differentiation of acute fatty liver of pregnancy from syndrome of hemolysis, elevated liver enzymes and low platelet counts. *J Obstet Gynaecol Res*. 2014 Mar;40(3):641–9.
12. Liu J, Ghaziani TT, Wolf JL. Acute Fatty Liver Disease of Pregnancy: Updates in Pathogenesis, Diagnosis, and Management. *Am J Gastroenterol*. 2017 Jun;112(6):838–46.
13. Gorginzadeh M, Safari S, Alavian SM. Acute Fatty Liver of Pregnancy: A Life-Threatening Condition Requiring a Life-Saving Approach. *Hepatitis Monthly*. 2016 Jun;16(6):e35256.
14. Jr, B. F. P. ., & Federico R. Tewes. (2021). What attorneys should understand about Medicare set-aside allocations: How Medicare Set-Aside Allocation Is Going to Be Used to Accelerate Settlement Claims in Catastrophic Personal Injury Cases. *Clinical Medicine and Medical Research*, 2(1), 61-64. <https://doi.org/10.52845/CMMR/2021v1i1a1>
15. Sratasa, S., S. Acharya, S. Kumar, S. Lahole, and S. Vasantrao Barekar. “Prevalence of Non-Alcoholic Fatty Liver Disease in Different Phenotypes of Obesity.” *International Journal of Pharmaceutical Research* 11, no. 3 (2019): 1418–23. <https://doi.org/10.31838/ijpr/2019.11.03.154>.
16. Bagga, C., R. Sarode, and S. Kumar. “The Spectrum of Non -Alcoholic Fatty Liver Disease (NAFLD) in Nursing Staff.” *European Journal of Molecular and Clinical Medicine* 7, no. 2 (2020): 2542–50.
17. Daniel, V., & Daniel, K. (2020). Perception of Nurses’ Work in Psychiatric Clinic. *Clinical Medicine Insights*, 1(1), 27-33. <https://doi.org/10.52845/CMI/20v1i1a5>

18. Raja, K.K., A.H. Inamdar, S. Lahole, and P. Palsodkar. "Prevalence of Non-Alcoholic Fatty Liver Disease in Prediabetes and Diabetes." *International Journal of Pharmaceutical Research* 11, no. 3 (2019): 1424–27. <https://doi.org/10.31838/ijpr/2019.11.03.166>.
14. Patel, S., S. Bawankule, S. Acharya, S. Kumar, A. Gaidhane, S.Z. Quazi, M.N. Khatib, and P. Karadbhajane. "'Interleukin-Six' as Predictor of 'Non Alcoholic Fatty Liver Disease' among 'Insulin Resistance Syndrome': A Study Protocol." *Annals of the Romanian Society for Cell Biology* 25, no. 1 (2021): 4161–68.
15. Daniel, V., & Daniel, K. (2020). Exercises training program: It's Effect on Muscle strength and Activity of daily living among elderly people. *Nursing and Midwifery*, 1(01), 19-23. <https://doi.org/10.52845/NM/2020v1i1a5>
16. Khatib, N., Q.S. Zahiruddin, A.M. Gaidhane, L. Waghmare, T. Srivastava, R.C. Goyal, S.P. Zodpey, and S.R. Johrapurkar. "Predictors for Antenatal Services and Pregnancy Outcome in a Rural Area: A Prospective Study in Wardha District, India." *Indian Journal of Medical Sciences* 63, no. 10 (2009): 436–44. <https://doi.org/10.4103/0019-5359.57643>.
17. Lozano, R., N. Fullman, J.E. Mumford, M. Knight, C.M. Barthelemy, C. Abbafati, H. Abbastabar, et al. "Measuring Universal Health Coverage Based on an Index of Effective Coverage of Health Services in 204 Countries and Territories, 1990–2019: A Systematic Analysis for the Global Burden of Disease Study 2019." *The Lancet* 396, no. 10258 (2020): 1250–84. [https://doi.org/10.1016/S0140-6736\(20\)30750-9](https://doi.org/10.1016/S0140-6736(20)30750-9).