

Posterior Gastric Perforation – Rare Surgical Emergency: A Case Report

Abstract:

Background: Incidence of perforation on posterior wall of stomach is rare throughout world; its occurrence has not been found till now in literature of central India. Diffuse symptoms with delayed presentation to health center and poorly skilled faculty with facilities make a way to raise in total number of deaths associated with posterior gastric perforation.

Objective: To report a rare case of posterior gastric perforation at a tertiary health care center in Central India, which would be first to be documented.

Materials and Method: Case report.

Case Presentation/Report: A 74-year-old male patient was referred to Department of General Surgery, AVBRH, with chief complaint of acute abdominal pain for two days. He had a history of alcohol consumption which was stopped 2 years back. A moderately distended, distinctly tender abdomen accompanied by guarding, rigidity and excluded bowel sounds was unveiled by abdominal examination. Patient has been resuscitated with intravenous fluids, antibiotics and analgesics. Consequently, an emergency exploratory laparotomy revealed a significant collection of purulent peritoneal fluid, 1x1 cm sized perforation on posterior wall of stomach. Perforation was repaired and thus patient recovered in a satisfactory way. **Conclusion:** And since posterior gastric perforation is extremely uncommon and expected to worsen, associated with increased morbidity and mortality leading to missed presence, this case report indicates that

evaluation of patients with gastric perforation, identify risk factors and ability to repair perforations right away along with resuscitation will greatly enhance clinical outcome.

Keywords

Ulcer, Peptic Ulcer Perforation, Stomach Ulcer, Stomach Diseases, Abdominal Injuries, Laparotomy

Introduction:

Four million people worldwide are affected by peptic ulcers every year[1]. Side effects are reported in 10-20 percent of these patients and ulcers perforate in 2-14 percent of total cases [2],[3]. Perforated peptic ulcer is comparatively uncommon and usually happens in ventral (anterior) aspect.[4]. most familiar type of perforation affiliated with stomach is anterior perforation observed in pylo-duodenal area. Posterior/ dorsal perforation of gastric ulcer is a rare clinical entity. Posterior gastric ulcer perforation is a unique category of peptic ulcer perforation with a distinctive clinical presentation[5]. Its phenomenon may be covered up by diffuse nature of illnesses of this disease, resulting in delays and difficulties in patient presentation to surgeon and corresponding raise in incidence of morbidity and death. Gastric tissue is integrated and adjusted to sustain digestive activity of gastric juice usually synthesized by stomach; furthermore, sensitivity of gastric tissue is negatively impacted by infection. with H. Pylori, smoking cigarettes and intake of non-steroidal anti-inflammatory drugs. A high level of great standard suspicion is necessary for a well before diagnosis of posterior gastric perforation; diagnosis was made intraoperatively in most of cases. Early identification and initiation of intervention in these cases is critical to enhance likelihood of living and survival of patient. Delays in visiting to hospital and choice to explore patient due to lack of skilled professional pose a major obstacle in resource-poor configurations. Accordingly, this case report proposes to index first ever recorded incidence of posterior gastric perforation in central India.

Case presentation:

A 74-year-old woman was admitted with a complaint of abrupt onset of dull aching pain in epigastric region for two days, followed by deepening and widening/generalisation of pain. Constipation is present for two days. on examination , abdomen was distended, tender all over with guarding and rigidity positive. Erect abdomen roentgenogram disclosed air under diaphragm and a decision has been made to explore abdomen. All through surgery, we identified a mild abdominal cavity collection without perforation on anterior surface of stomach, duodenum, or entire gastrointestinal tract. Mild collection was noted in lesser sac so gastrocolic omentum was opened and a small perforation of size less than 1X1 cm was found on posterior wall of stomach.(figure1). Post direct repair using an omental patch, patient got recovered and later discharged on post operative day 7. Posterior perforation of stomach wall due to a gastric ulcer is a very rare condition.

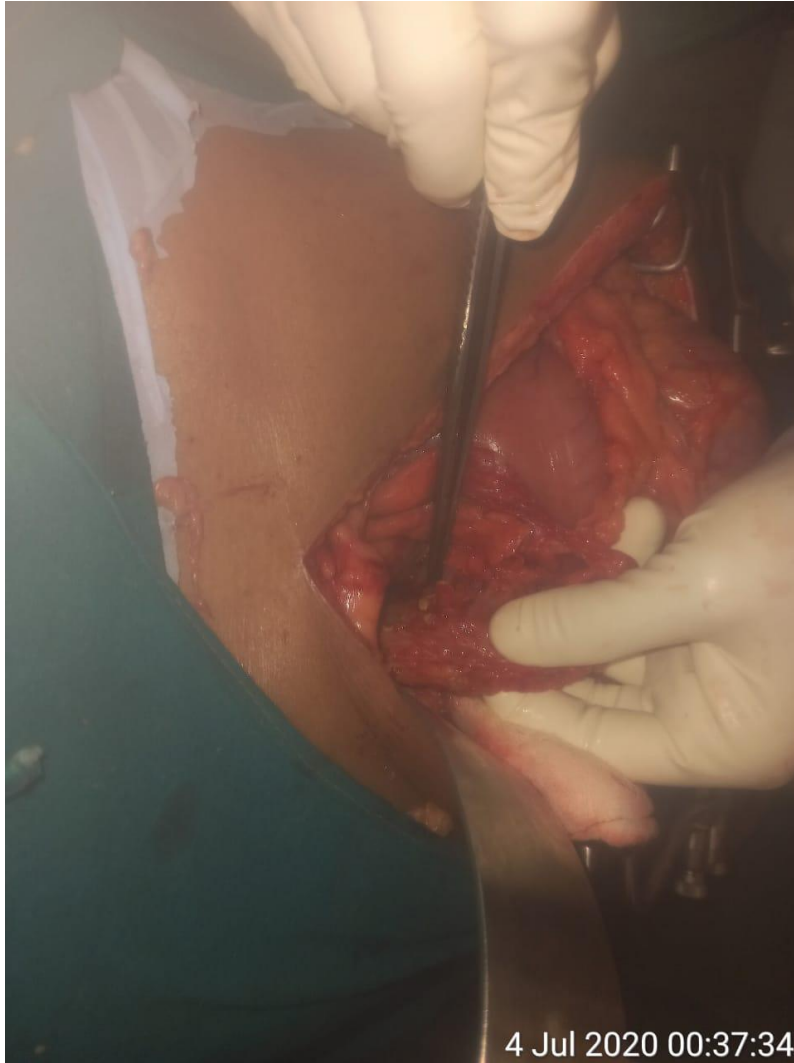


Figure 1: posterior gastric perforation

Discussion:

Posterior perforation of a gastric ulcer is an uncommon condition. There are a not many cases announced in writing. Wong and associates (2003) explored nine patients with posterior perforation, who were treated from January 1990 to June 2002. Their clinical cases were sealed/covered perforations, confined retroperitoneal abscess, and summed up peritoneal infection of lesser sac and peritoneal cavity(5). Of complete 125 years back to back punctured peptic ulcer patients worked upon by Hamilton Bailey, there was just a solitary instance of posterior gastric perforation[6]. most of benign gastric ulcers lie along lesser curve of stomach.

Be that as it may, almost 5-8% of ulcers lie in posterior wall of stomach [7]. At the point when posterior gastric ulcer perforates, it as a rule enters into lesser sac posterior to stomach (for gastric ulcers in fundus or group of stomach). lesser sac is a possible space and is less compelling in fixing off perforation; consequently, gastric substance and pus discharge will aggregate in lesser sac, forming abscess, and through foramen of Winslow these collections enters into peritoneal cavity, prompting up peritonitis. [5]. This is answer behind why clinical appearance of posterior gastric perforation is less prominent than that of common anterior wall perforations and is seen as late presentation. Furthermore, in light of late introduction and missed final diagnosis at laparotomy, post.wall perforation is normally connected to high morbidity and mortality. [5],[8]. If there should arise an occurrence of posterior wall perforation of pyloric or duodenal ulcers, these ulcers infiltrate into retroperitoneal space, that leads to either retroperitoneal abscess development, or perforation will be closed by adjacent inflammatory response and fibrosis of encompassing adhered retroperitoneal tissue.[5] In the event that posterior gastric ulcers puncture, they release gastric substance into lesser sac, which will in general restrict peritonitis. patients of this category may give less prominent complaints(10). CT scan has its particular ability in diagnosing perforated posterior wall gastric ulcers alongside its location, especially multidetector CT, in finding of perforated peptic ulcer. There are specific entities in CT studies that recommend gastric posterior wall perforation, for example, retro-gastric air as well as liquid assortment [9]. CT is more delicate for recognizing pneumoperitoneum and can portray retroperitoneal and intraperitoneal structures (11). How the patient of posterior perforations of gastric ulcers presents to health center relies upon site of these ulcers inside stomach. Ulcers present in fundus or stomach's body puncture into lesser sac, with ensuing lesser sac canker and summed up peritonitis infecting peritoneum through foramen of Winslow. Ulcers in stomach's

pylorus opens through into retroperitoneal space. These ulcers act like posteriorly perforated duodenal ulcers, with retroperitoneal collection and abscess development. It is significant for specialist to know that extravasated gastric or duodenal juices can follow in retroperitoneal space and end up as abscesses around any retroperitoneal structures, for example, pancreas, caecum, or kidneys (12). resultant abscesses regularly redirect consideration of specialist from genuine site of perforation. Consequently these ulcers are generally overlooked, with calamitous results (13, 14). most normal misinterpretation was infection of appendix. Retro-colic abscess, peri-nephric abscess, colonic abscess, pancreatic abscess, and even a incarcerated inguinal hernia are the other misdiagnosis included (13, 14,15,16). In an audit by Weston-Davis et al. (8), of sixteen patients with retroperitoneal extravasation from a punctured duodenal ulcer, an exact conclusion was made intraoperatively in just nine. conclusion of diagnosis was done on recurrent explorations in two patients and during postmortem in five patients. Hashmonai et al. (14) announced four patients with retroperitoneal perforation of duodenal ulcers; of these, diagnosis was concluded while at post-mortem examination for three. Thusly, when a retroperitoneal abscess is noted at laparotomy, a careful assessment, that includes entering a lesser sac and medialising duodenum (Kocher's maneuver), is required all together not to leave a probability of a posteriorly perforated ulcers.

Conclusion:

Very few documentations of Posterior perforation of gastric ulcer are available because of its rare occurrence. As per our research, this is first case reported in central India. An excess amount of doubt and knowledge with experience to access the lesser sac through gastro-colic ligament is expected to discover posterior gastric ulcers. Increased awareness of public and early presentation to specialist centre plays a key role in proper management of gastric perforations.

Disclaimer regarding Consent and Ethical Approval:

As per university standard guideline, participant consent and ethical approval have been collected and preserved by the authors

References:

1. Zelickson MS, Bronder CM, Johnson BL, Camunas JA, Smith DE, Rawlinson D, Von S, Stone HH, Taylor SM. Helicobacter pylori is not the predominant etiology for peptic ulcers requiring operation. *The American Surgeon*. 2011 Aug;77(8):1054-60.
2. Bertleff MJ, Lange JF. Perforated peptic ulcer disease: a review of history and treatment. *Digestive surgery*. 2010;27(3):161-9.
3. Lau JY, Sung J, Hill C, Henderson C, Howden CW, Metz DC. Systematic review of the epidemiology of complicated peptic ulcer disease: incidence, recurrence, risk factors and mortality. *Digestion*. 2011;84(2):102-13.
4. Williams N, O'Connell PR, editors. *Bailey & Love's short practice of surgery*. CRC press; 2008 Jun 27.
5. Williams NS, O'Connell PR, McCaskie A, editors. *Bailey & Love's short practice of surgery*. CRC press; 2018 Apr 27.
6. Ellis BW. Perforated and obstructed peptic ulcer. *Hamilton Bailey's Emergency Surgery Butterworth-Heinemann Oxford* 1995. 1995:356-8.
7. Norris JR, Haubrich WS. The incidence and clinical features of penetration in peptic ulceration. *JAMA*. 1961 Oct 28;178(4):386-9.
8. Weston-Davies WH, Pertkiewicz M, Szczygiel B. Retroperitoneal extravasation from perforated duodenal ulcer. *British journal of surgery*. 1988;75(9):878-9.
9. Wang SY, Cheng CT, Liao CH, Fu CY, Wong YC, Chen HW, Ouyang CH, Kuo IM, Hsu YP, Yeh CN. The relationship between computed tomography findings and the locations of perforated peptic ulcers: it may provide better information for gastrointestinal surgeons. *The American Journal of Surgery*. 2016 Oct 1;212(4):755-61.
10. Hasadia R, Kopelman Y, Olsha O, Alfici R, Ashkenazi I. Short-and long-term outcomes of surgical management of peptic ulcer complications in the era of proton pump inhibitors. *European Journal of Trauma and Emergency Surgery*. 2018 Oct;44(5):795-801.

11. Chen CH, Huang HS, Yang CC, Yeh YH. The features of perforated peptic ulcers in conventional computed tomography. *Hepato-gastroenterology*. 2001 Sep 1;48(41):1393-6.
12. Wong CH, Chow PK, Ong HS, Chan WH, Khin LW, Soo KC. Posterior perforation of peptic ulcers: presentation and outcome of an uncommon surgical emergency. *Surgery*. 2004 Mar 1;135(3):321-5.
13. Weston-Davies WH, Pertkiewicz M, Szczygiel B. Retroperitoneal extravasation from perforated duodenal ulcer. *British journal of surgery*. 1988;75(9):878-9.
14. Hashmonal M, Abrahamson J, Erlik D, Schramek A. Retroperitoneal perforation of duodenal ulcers with abscess formation. Report of four cases and survey of the literature. *Annals of surgery*. 1971 Mar;173(3):409.
15. Gajbhiye VP, Kale RS, Vilhekar KY, Bahekar SE. Drug utilization study on antimicrobials use in lower respiratory tract infection in Pediatric Intensive Care Unit of Rural Tertiary Care Hospital. *J Med Soc* 2016; 30:146-8 Available from: <http://www.jmedsoc.org/text.asp?2016/30/3/146/191178>
16. Shadma Quazi, Varsha Gajbhiye, Sharjeel Khan, Shailesh Nagpure. Efficacy of Tramadol in Comparison with Diclofenac in Ureteric Colic Patients Brought to a Medical College in Central India- A Prospective Observational Study. *Int J Cur Res Rev* July 2020, 12 (14) Special Issue ,103-109