

Endoscopic assisted Supraorbital Approach for Tumors of Anterior and Middle Skull Base

Abstract

Background data: The supraorbital eyebrow approach is a minimally invasive keyhole technique that offers wide access to the anterior skull base and parasellar region using the subfrontal corridor, with assistances of neuroendoscopy. The approach through the eyebrow permits access to a number of lesions in the subfrontal corridor with minimal brain retraction and a much smaller area of potential injury of main structures. **Study Design :** This study is a follow up study.

Objective: to evaluate the role of supraorbital endoscopic approach for tumors of anterior and middle skull base. **Patients and Methods:** All the operations were performed at Suez Canal University hospitals, in about 24 months, the first 30 patients having tumors of anterior and middle skull base fulfilling the inclusion criteria were included in this prospective study. **Results:** Endoscopy can play an important role in improving visualization through the keyhole corridor. With the use of neuroendoscopy, the reach of this approach may be extended even further to include the pituitary fossa, the top third of the clivus, the interpeduncular cistern, the anterior third ventricle, and the medial and anterior temporal lobe and middle fossa. The major advantage of the supraorbital over the endonasal route is a simplified skull base closure and reduced risk of postoperative CSF leak. It is a valuable approach for selected patients. Neuromonitoring may further increase surgical safety. **Conclusion:** The approach through the eyebrow permits access to a number of lesions in the subfrontal corridor. With the use of the assistance of neuroendoscopy, with minimal brain retraction and a much smaller area of potential injury of anatomical structures.

Keywords: Minimally invasive neurosurgery, Neuroendoscopy, Skull base surgery, Supraorbital approach, eyebrow approach

The article does not contain information about medical device(s)/drug(s).

No funds were received in support of this work.

The authors report no conflict of interest.

The chief editor is not included in decision or handling of this manuscript.

Address correspondence and reprint requests: Mohamed Elsayed Fathi, MD.

Neurosurgery Department, Faculty of Medicine, Suez Canal University, Ismailia, Egypt.

Introduction: route to of the anterior and middle cranial base tumors has traditionally required excessive trans-cranial approaches such as the Pterional, frontotemporal, Orbito fronto-zygomatic or bifrontal. Wide exposures, however, result in a more degree of frontal & temporal brain retraction and include unnecessary surgical dissection, resulting in unneeded perioperative morbidity⁽¹⁾. The supraorbital approach

trans eyebrow is a keyhole minimally invasive approach that may be useful to reach lesions located at the anterior & middle skull base and the perisellar area ⁽²⁾. depending on an incision in eyebrow and a small craniotomy, the supraorbital access in minimally invasive neurosurgery is a workhorse-type approach that lead to fantastic appearance of a series of anatomic sites and structures, including the anterior fossa base, the lamina terminalis, the optic structure, the internal carotid arteries on both sites, the Sylvian fissure proximally, temporal lobe medially, the circle of Willis, the basal surface of frontal lobe, and the interpeduncular cistern ⁽³⁾. The small view and wide surgical route of this technique made it minimally invasive and more effective. The visualization and reach of the supraorbital route can be improved by using endoscope, allowing better views and routes to the middle fossa, the area under the same side optic nerve (ON), contralateral parts of the circle of Willis, the anterior interhemispheric fissure, the anterior third ventricle, the upper part of the clivus, and the medial aspect of the ipsilateral middle cranial fossa and temporal lobe ⁽³⁾. To minimize the injurious effects of frontal and temporal lobe retraction and to avoid the use of potentially disfiguring skin incisions, approaches to tumors of the middle cranial base have become progressively less invasive. The strategic placement of "keyholes" eliminates the need for excessive surgical manipulation without sacrificing exposure or outcome. Furthermore, with the introduction of fully endoscopic approaches to the skull base, these tumors have now become amenable to endoscopic resection with a minimum of deleterious consequences ⁽³⁾. The widely involved lesions suitable to this supraorbital approach are the planum, tuberculum sellae, and anterior clinoidal meningiomas, olfactory groove meningioma, craniopharyngioma, and orbitofrontal region intra-axial tumors of the, frontal pole, and medial temporal lobe lesions, such as gliomas and metastases ⁽⁴⁾. Less common neoplastic lesions involved that are better managed by the supraorbital approach including gliomas involving the optic apparatus, the pituitary adenoma with a far lateral or anterior extension, or suprasellar part, and other tumors of the anterior third ventricle, such as hypothalamic hamartomas inferiorly extended. Tumors of the orbit that are superior and lateral to the optic nerve are better reached by this subfrontal approach with opening of the orbital roof ⁽³⁾.

Additionally, introduction of rigid endoscope to the supraorbital approach widen the available surgical corridor, providing without additional dissection or retraction extended access to the middle and the anterior cranial fossa.

Depending on the endoscopic supraorbital approach to reach base of the anterior and middle cranial fossa, enhancing the ability to preserve the anatomy of this region by its visibility, therefore maintain a more complete removal of middle cranial base lesions ⁽³⁾. This series aims for evaluating of the surgical management of anterior and middle skull base tumors by a minimal invasive endoscopic supraorbital procedure.

Patients and Methods This study is a follow up study to evaluate the role of supraorbital endoscopic approach for tumors of anterior and middle skull base.

All the operations were performed at Suez Canal University hospitals , In about 24 months, the first 30 patients having tumors of anterior and middle skull base fulfilling the inclusion criteria were included in this prospective study. **Inclusion criteria :** I Anterior and middle skull base small and medium sized lesions, II Both sexes were included, III Age 16-70 yrs. **Exclusion criteria:** I Recurrent cases, II Cranial Congenital anomalies, III Previous trauma affecting anterior or middle base, IV Large extended tumors (closely related to carotid artery or its branches and/or fibrous expected neoplasms), V Cranial infections.

Preoperative evaluation: History: Personal history was taken from the patients or the relatives including sex, age, occupation, special habits, and co-morbid medical conditions. Present history data concerning the presence of neurological symptoms (onset, course, duration) like visual symptoms, olfaction, and hormonal dysfunction. Past history of any previous cranial surgery or cranial trauma, **Examination:** General examination with detailed neurological examination, which also used as measurements for assessment the clinical progress **Investigations** including Preoperative CT-brain and MRI brain with contrast, Hormonal profile may be needed and Visual perimetry may be needed. if lesions are closely related to carotid artery or its branches: CT-angiography should done.

Operative Data: The mean operative time, the mean blood loss, the intra operative complications, was estimated.

Operative technique:

- The patient was placed in supine position on the operating room table, and the head of the bed was slightly raised to improve venous drainage.
- After the induction of general anesthesia, extension of neck approximately 15°-30° so that the frontal and the temporal lobes were relaxed and retracted downward away from the orbital roof and the floor of the skull base with gravity when CSF is drained.
- This position facilitates reaching to middle cranial fossa lesions from an anterior corridor.
- The head was fixed using a 3-pin clamp and the frontal and Para nasal areas were cleansed with an aqueous antiseptic solution and then draped after completing positioning.
- Opposite the surgeon the base of powered endoscope holding arm was fixed to the operating room table; the arm extended to firmly hold the endoscope.
- A 4.0-mm 0 degree rigid endoscope (Karl Storz) was linked to the holding arm.
- A skin incision was placed within the hair of the eyebrow a few millimeters above the orbital rim according to each patient's individual anatomical variation.

- The incision was bounded laterally by the lateral end of the eyebrow just anterior to the frontozygomatic suture and medially by the supraorbital notch.
- it had to vary slightly according to each patient's individual anatomy and skull shape so there was no standard position for the skin incision.
- Next to skin incision and soft tissue dissection, about 1.5-cm craniotomy supraorbitally was done with its lower border reach the skull base.
- The dura was opened, and CSF was drained slowly without traction under microscopic visualization.
- A combination of positioning, mild hyperventilation, and CSF drainage made a space as the frontal lobe retracted away from the anterior cranial base downward by gravity help.
- The monitor becomes the surgeon's eye at this point.
- The endoscopic lens was proceeded through the keyhole and manipulated between the frontal lobe and the anterior cranial base the floor, slowly sliding over the upper wall and the lesser wing of sphenoid bone to the middle cranial fossa.
- A panoramic view of the lesion was presented on the screen.
- Endoscopic assistance revealed the extension of intracranial tumor and spread.
- Using a combination of bipolar electrocoagulation and micro-CUSA (if available), the tumor was gradually removed.
- Once the tumor was suspected to be completely resected, the zero degree endoscope was removed, and the 30 degree endoscope was introduced and rotated in a clockwise and anticlockwise direction to achieve a survey of the middle cranial fossa and looking for any residual tumor parts not seen by the zero degree endoscope.
- Any tumor remnants were removed, to confirm that the tumor had been totally excised.
- The superior orbital roof and the sphenoid ridge could be drilled away giving a more basal view and better access to the tumor extension.
- After tumor excision, dura was tightly closed and the bone flap was refixed using micro plates and screws.
- The skin was closed with careful attention to the best repair.
- During the bony work if the frontal sinus was opened accidentally, the mucosa was stripped, the nasal- frontal duct was packed and dealt with.

- The patients undergoing these procedures were monitored overnight in the intensive care unit and thereafter transferred to the ward for 24 hours until discharge from the hospital.

Postoperative evaluation

Post-Operative Data:

- Time of stay in hospital, post-operative complications were estimated.
- Post-operative CT-brain.

Follow up evaluation

Clinical examination, hormonal investigations and brain image if needed were carried out at the out-patient clinic at 1, 6 and 12 month after the surgery.

Assessment of clinical outcome

We considered the following variables as primary outcomes:

- Total removal of tumors without neurological deficit.

Second outcomes

We also considered the following variables as second outcomes:

- Complications of surgery, including mortality and common thrombosis, surgical site and other infections.
- Duration of hospital stay.
- Surgical cost, and
- Operation time.

Statistical Data Analysis

Data was analyzed with the statistical package of social science (SPSS), statistical software program version 18.

Statistical data analysis was accomplished using the chi-square test and the Student t test. P value of 0.05 was used to define statistical significance.

Results

30 patients (12 males and 18 females) were recruited for this study after exclusion of who have lost during the follow up. Demographic data and age distribution are shown in table 1

93.33% were complaining of headache. **Distribution of symptoms & signs among study population is shown in table2 &3**

The smallest lesion operated upon in this study was 2cm while the largest was 8cm.

Radiologic analysis of lesions(nature, size, site &enhancement) were illustrated in table4 and figure 1,2&3

❖ **Surgical findings**

The selected approach among the 30 patients was as follows:

- 10 patients (33.33%) were operated via the right supraorbital endoscopic assisted trans eyebrow approach.
- 20 patients (66.67%) via the left supraorbital endoscopic assisted trans eyebrow approach.
- The lesion was found to be firm and tough in 19 patients (63.33%), soft and suckable in 7 patients (23.4%), cystic in 1 patients (3.3%), mixed cystic and solid in 3 patients (10%). Attachment of the lesions to the surroundings was illustrated in table5

Extent of surgical excision

The lesions were totally removed in 24 cases:

- 17 meningiomas (12 convexity meningiomas and 5 frontobasal meningioma - planum sphenoidal, and olfactory grooves-).
- 4 metastasis.
- 2 gliomas.
- 1 pituitary adenoma.

The lesions were subtotally removed in 5 cases:

- 2 meningiomas (diaphragm sellae& planum).
- 2 gliomas.
- 1 metastasis.

The lesions were partially resected in one case only:

- Pituitary adenoma.

The mean blood loss was 850 ml± 215 ml & the mean operative time was 300± 150 minutes

- All patients were given antibiotics for at least first postoperative week and antiepileptic drugs were given to all patients intraoperative and continued for at least first 3months post-operative.
- ***Adjuvant therapy*** (chemotherapy, radiotherapy and radiosurgery) proceeded according to histopathological analysis. Different pathological lesions were

treated: There were 19 meningiomas, 5 metastasis, 4 GBM and 2 pituitary adenomas.

Patient's admission ranged from 2-6 days, only one patient stayed at hospital for two weeks. ICU admission lasted for 12hrs in 14 patients and lasted for 24 hours in 15 patients (50 %).

All patients were assessed clinically and by radiological imaging immediately postoperative and at 3 months, 6 months and 1 year after surgery to evaluate:-
Extent of lesions resection, Related complications& Post- operative scar.

➤ Postoperative **visual evaluation** showed that:

- In 80% of patients with preoperative visual problems, the vision improved.
- The vision stayed the same in 20% of patients.
- The vision did not deteriorate in any patient.

Postoperative **endocrinal evaluation** showed:

- Improvement in 1 patient of pituitary adenoma in which menstruation became regular and prolactin level normalized.
- 2 patients developed diabetes insipidus; one was temporary and improved and one was permanent and received replacement therapy.
- Three patients presented by **fits**; all of them were controlled by antiepileptic drugs preoperative and remained free of fits during the period of follow up.
- **Cranial nerve assessment** showed that preoperative anosmia did not improve in 2 patients whom were presented with olfactory groove meningioma during the period of follow up.

-During the follow up period 2 patients showed recurrence after resection; one of them was the patient with convexity meningioma after 6months of follow up and one glioma patient who underwent subtotal resection showed regrowth with follow up. It should be considered that the maximum follow up period which was 12 months may not be sufficient to detect recurrence in some lesions e.g. meningiomas.

Postoperative complications are showed in table 6

The patients who had excellent outcome were 14 meningioma patients, 2 metastasis patients and 1 glioma patient. They had both clinical and radiological improvement.

The patients who had good outcome were 5 meningioma patients, 3 metastasis patients, 3 glioma patients and 1 pituitary adenoma. They had improvement but with some complications.

The patient who had Poor outcome was a patient with pituitary adenoma. The patient had permanent hormonal replacement dependence.

There was a significant relation between the size of the lesion and the extent of excision (P value = 0.032), between the extent of excision and the pathological type (P value = 0.024) & between extent of excision and outcome (P value = 0.001).

There is no significant relation between extent of excision and nature of the lesion at surgery (P value = 0.37), between pathology and outcome in this study & between the duration of symptoms and outcome (P value = 0.218).

Discussion

To decrease the size of the craniotomy many techniques have been established, to minimize brain retraction, and promote sufficient view of the cranial floor. In 1913, Frazier reported the first case, operating on a pituitary tumor across the anterior cranial base by removal of the supraorbital ridge⁽⁵⁾. A supraorbital approach was described by Jane, which deemed to be the technique of choice for pituitary tumors, craniopharyngiomas, orbital tumors and for anterior communicating artery aneurysms, and parasellar or olfactory nerve meningiomas⁽⁶⁾. Anterior cranial base, sellar and parasellar tumors conventionally reached by a traditionally pterional, fronto-temporal or basal bifrontal craniotomy are now reached by smaller corridors by improvements in microsurgical approaches, refined tools, surgical neuronavigation and endoscopy⁽⁷⁾.

One of the minimally invasive neurosurgery approaches is supraorbital approach which provide a less approach-related injury; through an eyebrow incision⁽⁸⁾.

Others saw that an eyebrow approach may limit exposure and allow in adequate exposure to do successful and safe surgery⁽⁹⁾. For safe intracranial microsurgical dissections, with the smaller craniotomy size, the exploration then CSF slow drainage suspected to be good enough with preservation of the integrity of as much normal tissue as possible, without Unnecessary manipulation or brain retraction. Early results faced difficulties with cosmetics due to the bony repair and the skin incision site, also loss of the supraorbital nerve function or frontal branch of the facial nerve injury were

commonly seen in early studies postoperatively. Also the frontal sinus opening, CSF leak or meningitis has been recorded. The limitations of these approaches were demonstrated in early case series, many of them have been overcome⁽⁹⁾.

in the largest series, complete excision was done in like extent as larger craniotomies, were resulting in 89.2% of skull base meningiomas gross totally resected⁽¹⁰⁾⁽¹¹⁾⁽¹²⁾.

Resection with preservation of arachnoid planes carefully piece by piece is the most important surgical step for preservation of the optic nerve and avoidance of perforators and other vessels injuries. Differentiation of blood supply to tumors from perforators supplying the optic or hypothalamus is important⁽¹³⁾.

Including a less CSF leak rate, morbidity and mortality does not expressed to be more than in other approaches for same tumors. Good experience and familiarity with a specific approach are considered an important points. Figueiredo et al. study found that little invasive approaches may give similar surgical working corridors to those done by conventional craniotomies and considered good choice in state of the pterional approach in certain cases⁽¹³⁾.

The angle and depth of visualization seen by the neurosurgeon are well maintained without excessive retraction of anatomical structures, the surgical corridor through the supraorbital track extend, with the help of navigation and intraoperative endoscopic view, so: the supraorbital procedure is used resulting in little surgery related morbidity and mortality. Because corridor through this technique is relatively narrow, these surgeries should be done by more qualified surgeons with well-equipped situations.

Avoiding unneeded frontal sinus opening and to choose the surgical track before the skin incision, some performed the surgical technique by navigation in their cases; image guiding frameless navigation is helpful in identifying the frontal sinus anatomy and the craniotomy planning lateral to the lateral border of the frontal sinus. Some avoid the supraorbital approach as a choice to cases with large frontal sinuses size, in few cases. Therefore; the size of the frontal sinus should be keep in mind while planning the supraorbital approaches. A larger frontal sinus moves the craniotomy border more laterally, changing the operative pathway.

Our study included 12 males and 18 females with mean age of 52.7 years. Different pathological lesions were treated: There were 19 meningiomas, 5 metastasis, 4 glioblastoma multiforme, and 2 pituitary adenomas.

In the study of (Eroglu et al., 2019), The supraorbital keyhole approach was used in 106 patients (55% males and 45% females). The mean age was 51.7 (range, 2-79) years⁽¹⁴⁾. A total of 97 patients (32 men and 65 women) were operated in the study of (Gazzeri et al., 2014), their ages ranged from 10 to 75 years (mean age = 58.5 years)⁽¹⁵⁾.

In 93% of our patients, the presenting symptom was headache. The rest were presented with vomiting, seizures and visual manifestations.

The smallest lesion operated upon in our study was 2cm while the largest was 8cm (average = 5cm). It should be noted that the size was given to the longest sagittal diameter of the lesion.

By using the supraorbital eyebrow approach, Perneczky treat 93 anterior and middle base meningiomas. They could excise 89.2% of the tumors with fewer complications totally and supposed that basal temporal extensions are the main limitations for the corridor⁽¹⁰⁾.

We did gross total resection in 80% of patients with anterior and middle fossa lesions. The lesions were subtotally removed in 5 cases: 2 meningiomas (diaphragm sellae and planum), two gliomas and one metastasis. Only 1 case of pituitary adenoma had partial resection.

Gross total resection results of anterior cranial base meningiomas found in the literature, and ours (80%), obtained after minimally invasive procedures to these tumors have similar results to conventional craniotomies works.

The extent of resection was significantly affected by the extension, size and attachment of the lesion, less affected by the pathological type, and not affected by the composition or nature of the lesion at surgery.

half of the cases (52%) had extra-axial lesions in Eroglu et al, those cases with intra-axial lesions, microscopic total resection was completed in 74.4% of cases. An endoscope was assist in 37.7% of cases. Orbitofrontal meningiomas were the most common lesion in 27.4% of cases (23 frontal and 6 orbital meningiomas). Simpson grade II and III resections were done in 31.0% and 69.0% of cases, respectively.

Olfactory groove meningiomas lesions were excised in 13.2% cases; all them were Simpson grade III resections⁽¹⁴⁾.

The main complication is that of CSF rhinorrhea that was reported to range between 0 to 7% of cases and was observed in only two cases in our study that were successfully treated by head elevation, tight bandage and clean dry dressings, one patient improved gradually at the end of the first week and the other needed reoperation to close the dura and fixing the bone flap well with mini plates. The complications reported with this approach are no more than accompanied with conventional craniotomies.

Reisch and Pernecky results from 450 cases who managed with the supraorbital procedure with variant pathology (pituitary adenomas, cranial base meningiomas, craniopharyngiomas, intracranial aneurysms, deep-seated brainstem tumors, and other frontotemporal or suprasellar masses). The postoperative complications were summarized:

1) Constants palsy of the frontalis muscle related to injury of the frontal branch of the facial nerve in 25 patients.

2) Constants partial supraorbital hypoesthesia related to injury of the supraorbital nerve was detected in 34 patients.

3) Problems with chewing were detected in 3 cases, without atrophy of the temporalis muscle.

4) Constants hyposmia appeared in 27 patients unilateral, and bilateral with loss of tasting was detected by 9 cases.

5) Wound healing problems observed in 6 patients.

6) Cerebrospinal fluid leak in 12 cases.

7) A subcutaneous cerebrospinal fluid found in 20 cases.

8) Postoperative bleeding with a mass effect was observed in 4 patients; one patient died; the other two patients had a poor outcome despite rapid intervention⁽¹²⁾.

106 cases underwent this technique with Eroglu. Morbidity revealed two (1.9%) cases with temporary ptosis. One (0.9%) case developed a titanium allergic reaction. without cerebrospinal fluid leak or rhinorrhea. Three cases underwent transient diabetes insipidus after resection of parasellar lesions (2 craniopharyngiomas and 1

pituitary adenoma). In 14 cases with olfactory groove meningiomas, 6 (42.8%) developed postoperative loss or decreased olfaction, and 2 (14.2%) developed postoperative anosmia. Five (38.5%) cases underwent another resection of recurrent glioma. A month postoperatively, 95% of cases became with acceptable cosmetic feature⁽¹⁴⁾.

In our study, Transient periorbital edema occurs in all patients and totally resolved by the end of the first week. Supraorbital hypoesthesia was evident in 25 (83.3%) patients (temporary in 20 patients and permanent in 5 patients). Two patients showed superficial wound infection which subsides under antibiotic therapy. There was no temporalis muscle wasting in any patient. Eye brow elevation was lost in 28 patients (subsided in 24 patients and remained in 4 patients). No visual deterioration occurred in any of our patients. Two patients developed diabetes insipidus; one has improved and the other had the disease permanently.

The maximum follow up period for our patients was 12 months that may not be sufficient for detecting recurrence in all lesions (as in meningiomas). During this period 2 patients had recurrence; one had recurrence of sellar meningioma after total resection 6 months later and the other showed regrowth of glioma after subtotal resection.

In our study, 96.6% of our patients had excellent and good outcomes. It should be mentioned that this outcome was not related to the pathology of the underlined pathology. It was affected by the duration of symptoms, extent of surgical excision, and cosmetic results.

Dlouhy et al. assessed the use of this procedure in 45 children. The endoscopic help and provided better visualization and corridor to regions not accessible by conventional microscopic views in all patients. Cosmetic results were excellent; the incision scar was not visible at 6 weeks in all cases. In 3 cases, a small bone defect was detected on the forehead. No frontal sinus opening occurred due to the small size of the frontal sinus in children with no CSF leak or wound infection⁽¹⁶⁾. Mitchell et al. detect that in vascular lesions, it was difficult with using two suction tubes in closing prematurely ruptured aneurysms or support proximal control⁽¹⁷⁾.

Some surgeons avoid this minimally invasive supraorbital approach for vascular pathologies⁽¹⁸⁾. Some authors recommended removal an orbital osteotomy to improve surgical visualization and access for vascular lesions⁽¹⁹⁾⁽²⁰⁾. Another believes led to similar adaptations to conventional procedures to access frontal base and parasellar

pathologies in the past ^{(21) (22)}. some surgeons have mentioned different vascular lesions treated through this approach safely, but it should be limited to those with significant experience and skills with the procedure, and it may not be the best choice for (giant aneurysms, subarachnoid hemorrhage, or vascular lesions of posterior circulation) as conventional approaches ⁽¹⁷⁾⁽²³⁾.

Many modifications have led to what many now consider to be a super cosmetic result with the supraorbital craniotomy and keyhole procedures, have prevented many surgeons afraid of using this approach due to Cosmose ⁽⁹⁾.

The success of the eyebrow incision achieved by a limited skin incision within the eyebrow, little temporalis muscle dissection, a smaller bone flap, and closure with the orbicularis oculi muscle and pericranial fascia. Temporalis muscle atrophy can be avoided with the eyebrow incision, which more common with conventional pterional and frontotemporal craniotomies ⁽²⁰⁾.

Through this approach, orbicularis oculi muscle atrophy can lead to worse cosmetic outcomes due to muscle fibers and nerve injury. This can be avoided by first opening the incision only through the skin and dermis layers, followed by incise the muscle more dorsally and incise along the muscle fibers not across them ⁽²⁴⁾⁽²⁵⁾.

Superior dissection superficial to the orbicularis oculi, pericranium, and temporalis muscle is ideal for formation of a isolated tissue flap used for recovering the keyhole craniotomy flap during closure of wound ^{(12) (17) (23) (26)}.

Proper repositioning of the bone flap important for good cosmetic results. Confirm that the outer cortex of the supraorbital ridge remains normal during the approach. By using of a burr hole cover and titanium plates preventing the defect around the bone flap following bone flap replacement in position. Closure of the skin layer with a subcuticular stitch (e.g., 4-0, 5-0 Prolene or vicryl) without any knots close the edges of the eyebrow together for better cosmose.

Summary and Conclusion

The supraorbital eyebrow approach is considered a minimally invasive keyhole approach that provide wide access to the anterior skull base and parasellar region by using the subfrontal corridor. The approach through the eyebrow allow access to a number of lesions in the sub frontal base with little brain retraction and a smaller injury

of anatomical structures. The minimally invasive procedures have a learning curve, and smaller, simpler lesions should be performed first through this approach before shifting to larger lesions. Preoperative planning and facilities guidance may be used to precisely identify the surgical corridor.

Endoscopy can play an important role in improving visualization through the eyebrow corridor, by its assistance the access of this approach may be extended to include the pituitary fossa, the upper part of clivus, the anterior third ventricle, the interpeduncular cistern, and the medial and anterior temporal lobe and middle fossa. Neuromonitoring may further increase surgical safety.

Consent and Ethical Approval

As per international standard or university standard, patients' written consent and ethical approval has been collected and preserved by the author(s).

List of abbreviations

ACA	Anterior Cerebral Artery
AVMs	Arterio-venous Malformations
CSF	Cerebrospinal Fluid
CT	Computerized tomography
CTA	Computed Tomography Angiography
FMRI	Functional MRI
GBM	Glioblastoma multiforme
ICA	Internal Carotid Artery
ICP	Intracranial Pressure
MCA	Middle Cerebral Artery
MRI	Magnetic Resonance Imaging
MRS	Magnetic Resonance Spectroscopy
ON	Optic Nerve
SAH	Subarachnoid Hemorrhage
SD	Standard Deviation

References:

- 1- Kabil, M. S., & Shahinian, H. K. (2006). The endoscopic supraorbital approach to tumors of the middle cranial base. *Surgical Neurology*, 66(4), 396–401; discussion 401.
- 2- Jallo, G. I., & Bognár, L. (2006). Eyebrow Surgery: The Supraciliary Craniotomy: Technical Note. *Operative Neurosurgery*, 59(suppl_1), ONS-E157.

- 3- Wilson, D. A., Duong, H., Teo, C., & Kelly, D. F. (2014). The supraorbital endoscopic approach for tumors. *World Neurosurgery*, 82(1–2), e243-256.
- Yasargil, M. G. (1984). Microsurgical anatomy of the basal cistern and the vessels of the brain. In *Microneurosurgery*. (Vol. 1, pp. 5-168-217–220). Georg Thieme Verlag.
- 4- Reisch, Stadie, A., Kockro, R., Gawish, I., Schwandt, E., & Hopf, N. (2009). The minimally invasive supraorbital subfrontal key-hole approach for surgical treatment of temporomesial lesions of the dominant hemisphere. *Minimally Invasive Neurosurgery: MIN*, 52(4), 163–169.
- 5- Frazier, C. H. (1913). An Approach to the Hypophysis through the Anterior Cranial Fossa. *Annals of Surgery*, 57(2), 145–150.
- 6- Jane, J. A., Park, T. S., Pobereskin, L. H., Winn, H. R., & Butler, A. B. (1982). The supraorbital approach: Technical note. *Neurosurgery*, 11(4), 537–542.
- 7- Margalit, N. S., Lesser, J. B., Moche, J., & Sen, C. (2003). Meningiomas involving the optic nerve: Technical aspects and outcomes for a series of 50 patients. *Neurosurgery*, 53(3), 523–532; discussion 532-533.
- 8- Reisch, R., Marcus, H. J., Kockro, R. A., & Ulrich, N. H. (2015). The supraorbital keyhole approach: How I do it. *Acta Neurochirurgica*, 157(6), 979–983.
- 9- Ormond, D. R., & Hadjipanayis, C. G. (2013b). The Supraorbital Keyhole Craniotomy through an Eyebrow Incision: Its Origins and Evolution. *Minimally Invasive Surgery*, 2013, 296469.
- 10- Perneczky, A. (1992). Planning strategies for the suprasellar region: Philosophy of approaches. *Neurosurgeons*, 11, 343–348.
- 11- Perneczky, A., Mueller-Forell, W., Lindert, E. V., Perneczky, A., Muller-Forell, W., & Lindert, E. V. (1999). *Keyhole Concept in Neurosurgery: With Endoscope-Assisted Microsurgery and Case Studies* (1st edition). George Thieme Verlag
- 12- Reisch, R., & Perneczky, A. (2005a). Ten-year experience with the supraorbital subfrontal approach through an eyebrow skin incision. *Neurosurgery*, 57(4 Suppl), 242–255; discussion 242-255.
- 13- Figueiredo, E. G., Deshmukh, V., Nakaji, P., Deshmukh, P., Crusius, M. U., Crawford, N., Spetzler, R. F., & Preul, M. C. (2006). An anatomical evaluation of the mini-supraorbital approach and comparison with standard craniotomies. *Neurosurgery*, 59(4 Suppl 2), ONS212-220; discussion ONS220.
- 14- Eroglu, U., Shah, K., Bozkurt, M., Kahilogullari, G., Yakar, F., Dogan, İ., Ozgural, O., Attar, A., Unlu, A., Caglar, S., Cohen Gadol, A. A., & Ugur, H. C. (2019). Supraorbital Keyhole Approach: Lessons Learned from 106 Operative Cases. *World Neurosurgery*, 124, e667–e674
- 15- Gazzeri, R., Nishiyama, Y., Ph.D, & Teo, C. (2014). Endoscopic supraorbital eyebrow approach for the surgical treatment of extraaxial and intraaxial tumors. *Neurosurgical Focus*, 37(4), E20.
- 16- Dlouhy, B. J., Chae, M. P., & Teo, C. (2015). The supraorbital eyebrow approach in children: Clinical outcomes, cosmetic results, and complications. *Journal of Neurosurgery: Pediatrics*, 15(1), 12–19.

- 17- Mitchell, P., Vindlacheruvu, R. R., Mahmood, K., Ashpole, R. D., Grivas, A., & Mendelow, A. D. (2005). Supraorbital eyebrow minicraniotomy for anterior circulation aneurysms. *Surgical Neurology*, 63(1), 47–51.
- 18- Heros, R. C. (2011). The supraorbital “keyhole” approach. *Journal of Neurosurgery*, 114(3), 850–851
- 19- Berhouma, M., Jacquesson, T., & Jouanneau, E. (2011). The fully endoscopic supraorbital trans-eyebrow keyhole approach to the anterior and middle skull base. *Acta Neurochirurgica*, 153(10), 1949.
- 20- Steiger, H.-J., Schmid-Elsaesser, R., Stummer, W., & Uhl, E. (2001). Transorbital Keyhole Approach to Anterior Communicating Artery Aneurysms. *Neurosurgery*, 48(2), 347–352.
- 21- Al-Mefty, O. (1987). Supraorbital-Pterional Approach to Skull Base Lesions. *Neurosurgery*, 21(4), 474–477.
- 22- Delashaw, J. B., Jane, J. A., Kassell, N. F., & Luce, C. (1993). Supraorbital craniotomy by fracture of the anterior orbital roof: Technical note. *Journal of Neurosurgery*, 79(4), 615–618.
- 23- Cheng, C.-M., Noguchi, A., Dogan, A., Anderson, G. J., Hsu, F. P. K., McMenomey, S. O., & Delashaw, J. B. (2013). Quantitative verification of the keyhole concept: A comparison of area of exposure in the parasellar region via supraorbital keyhole, frontotemporal pterional, and supraorbital approaches: Laboratory investigation. *Journal of Neurosurgery*, 118(2), 264–269.
- 24- Lupret, V., Sajko, T., Beroš, V., Kudelić, N., & Lupret Jr., V. (2006). Advantages and Disadvantages of the Supraorbital Keyhole Approach to Intracranial Aneurysms. *Acta Clinica Croatica*, 45(2), 91–94.
- 25- Pernecky, A. (2004). Surgical results, complications and patient satisfaction after supraorbital craniotomy through eyebrow skin incision. *Proceedings of the Joint Meeting Mit Der Ungarischen Gesellschaft Für Neurochirurgie Deutsche Gesellschaft Für Neurochirurgie (DGNC'04)*.
- 26- Zheng, X., Liu, W., Yang, X., Gong, J., Shen, F., Shen, G., Shen, H., Zheng, X., & Fu, W. (2007). Endoscope-assisted supraorbital keyhole approach for the resection of benign tumors of the sellar region. *Minimally Invasive Therapy & Allied Technologies*, 16(6), 363–366.

Tables

Table1

			Minimum	Maximum	Mean (SD)
Age in years			38	67	52.7 (8.32)
			Sex		Total
Age group			Male Frequency (%)	Female Frequency (%)	
	30- <40		0(0)	2(6.67)	
	40- <50		5(16.67)	4(13.33)	
	50- <60		6(20)	6(20)	
60- 70		1(8.33)	6(20)		
Total		12(40)	18(60)	30(100)	

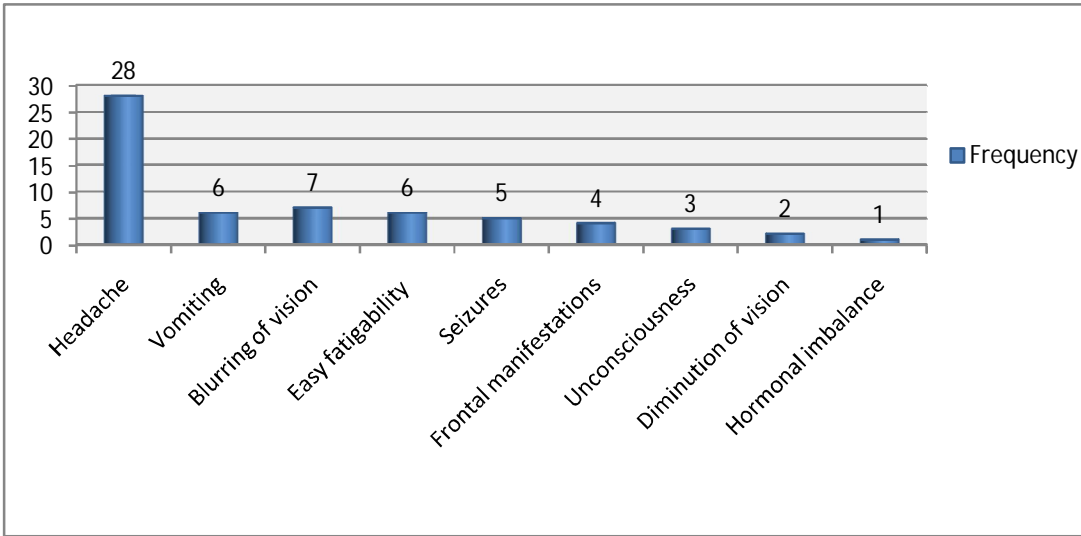


table2

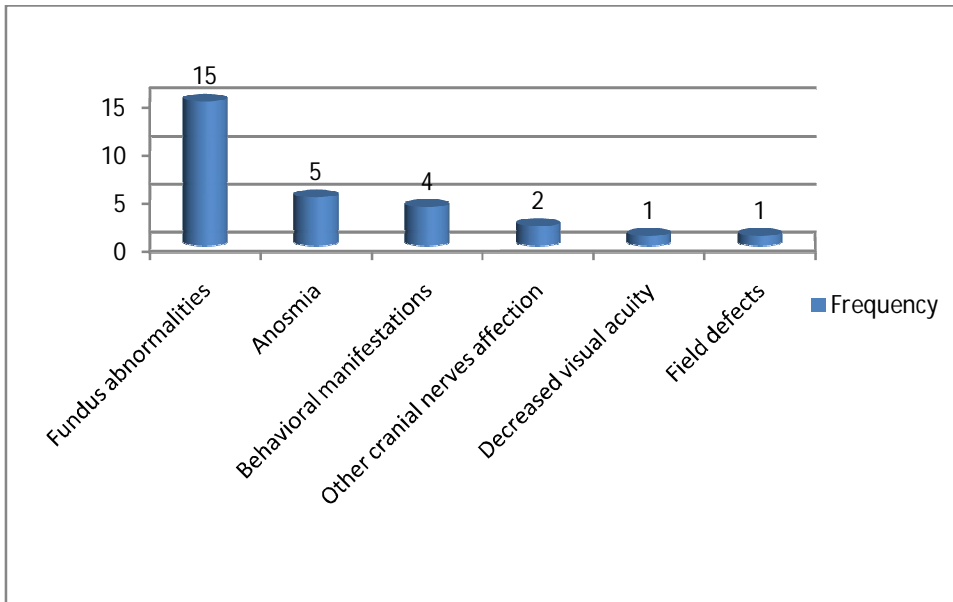


Table3

Nature of lesion	Frequency (%)
Purely solid	20 (66.7)
mixed	9 (30)
cystic	1 (3.33)
total	30 (100)

Table4

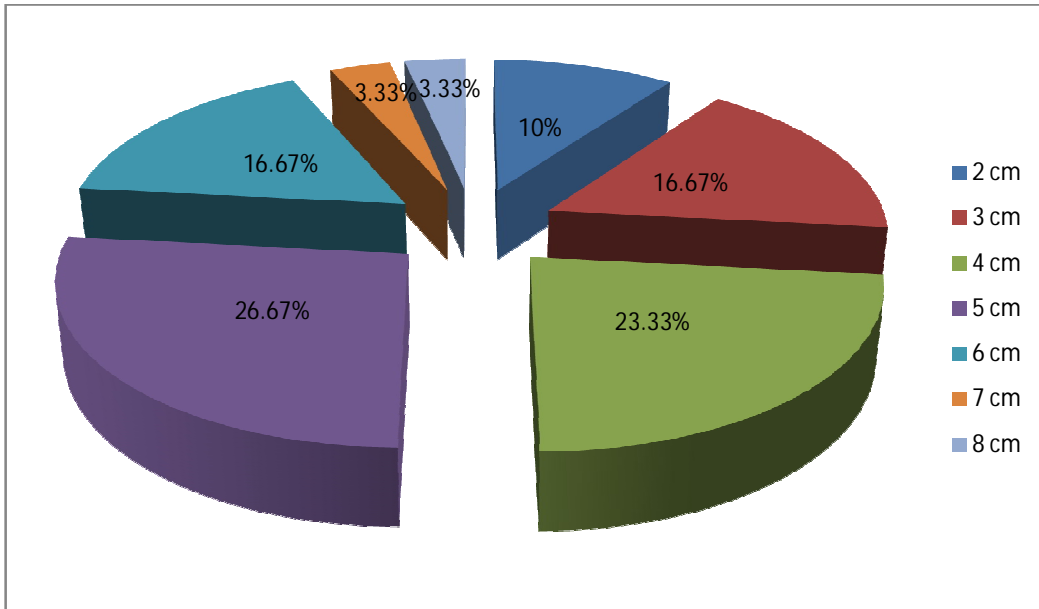


Figure 1

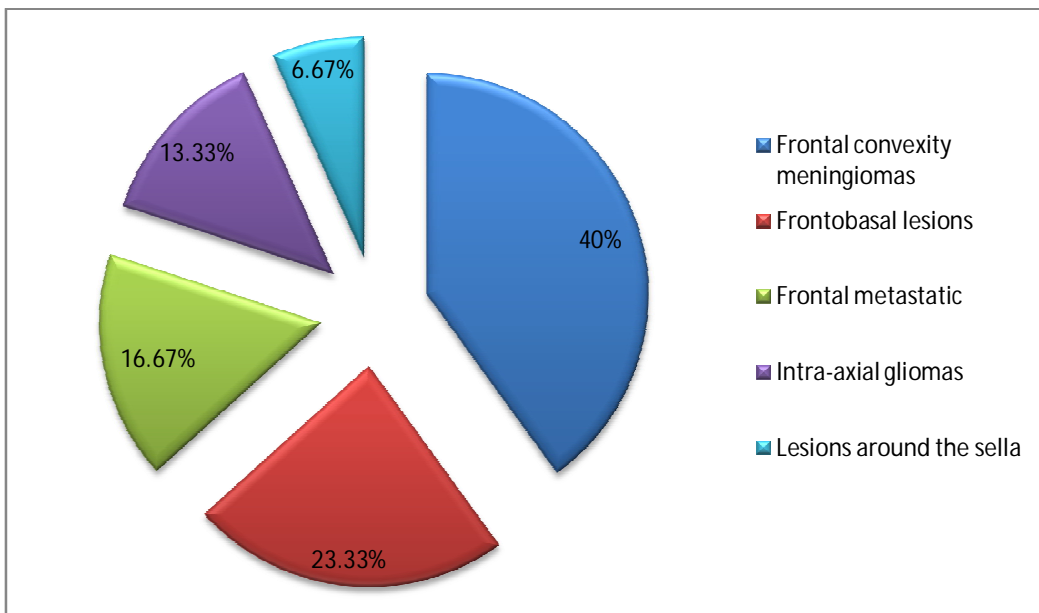


Figure2

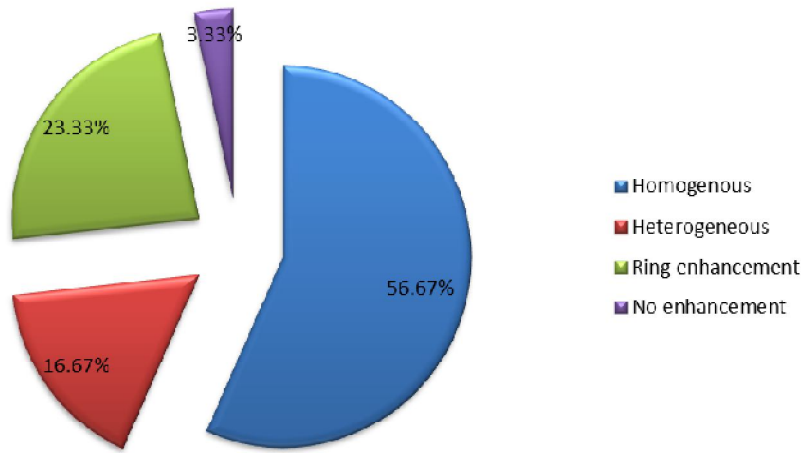


Figure3

Attachment	Frequency (%)
Meninges	19 (63.33)
Optic pathway	2 (6.67)
Main vessels	2 (6.67)
Hypothalamus	1 (3.33)
Bone	4 (13.33)
Optic pathway + main vessels	1 (3.33)
Pituitary stalk + main vessels	1 (3.33)

Table5

Complication	Transient	Permanent
	Frequency (%)	Frequency (%)
Visual deterioration	0 (0)	0
Endocrinal complication	1(3.3)	1(3.3)
Cranial nerve affection	0 (0)	2 (6.7)
Subgaleal collection	7 (23.33)	0 (0)
Superficial wound infection	2 (6.7)	0 (0)
Cosmetic problems	27 (90)	3 (10)
Lost eye brow elevation	24 (80)	4 (13.3)
Periorbital edema	30 (100)	0 (0)
Supraorbital hypoesthesia	20 (66.7)	5 (16.7)
CSF leak	1(3.3)	1 (3.3)

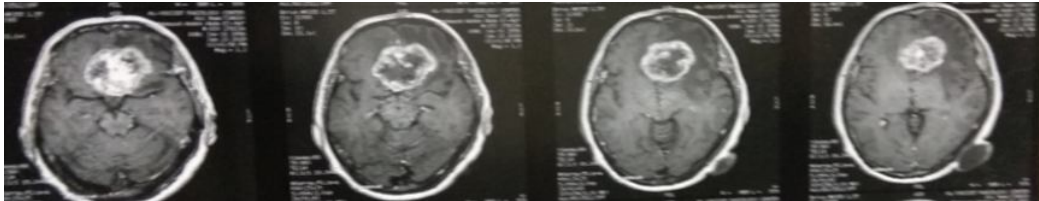
Table6

Cases:

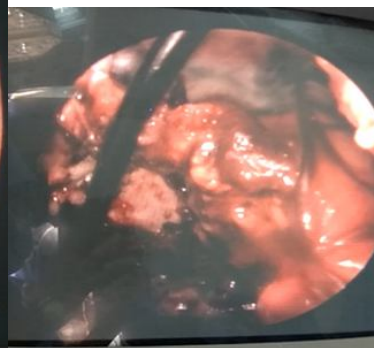
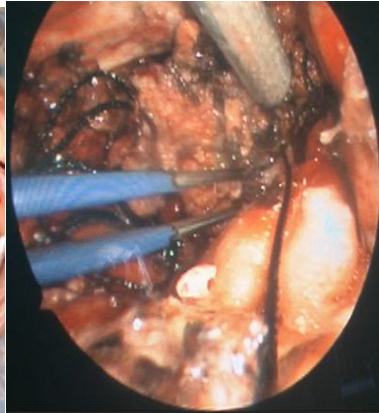
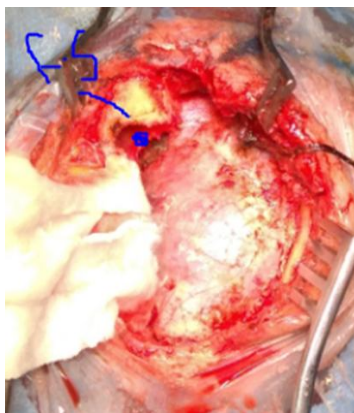
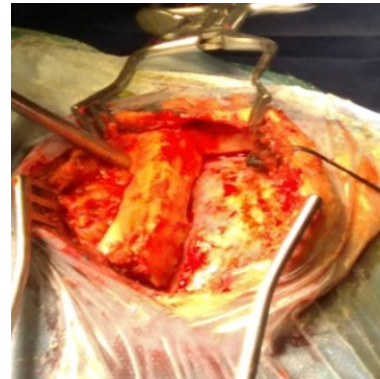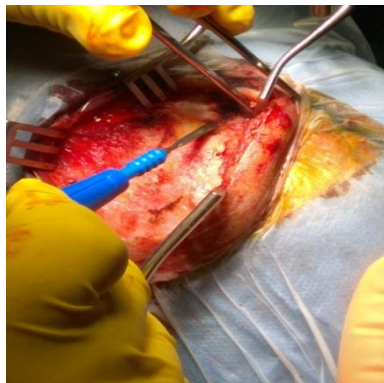
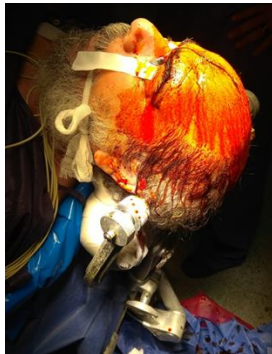Case1: A right handed 60 year old male patient presented by headache and convulsions with no known chronic illness, On examination: the patient was fully conscious and oriented (GCS 15/15), anosmia was detected and all other cranial nerves were intact, CT brain: mass in the olfactory groove was detected with calcification, These imaging characteristics were consistent mostly with an olfactory groove meningioma. The patient underwent elective resection of his tumor by a right supraorbital endoscopic assisted craniotomy through the right eyebrow, Operative time: around 270 minutes, Blood loss: 670 ml. **Postoperative data:**

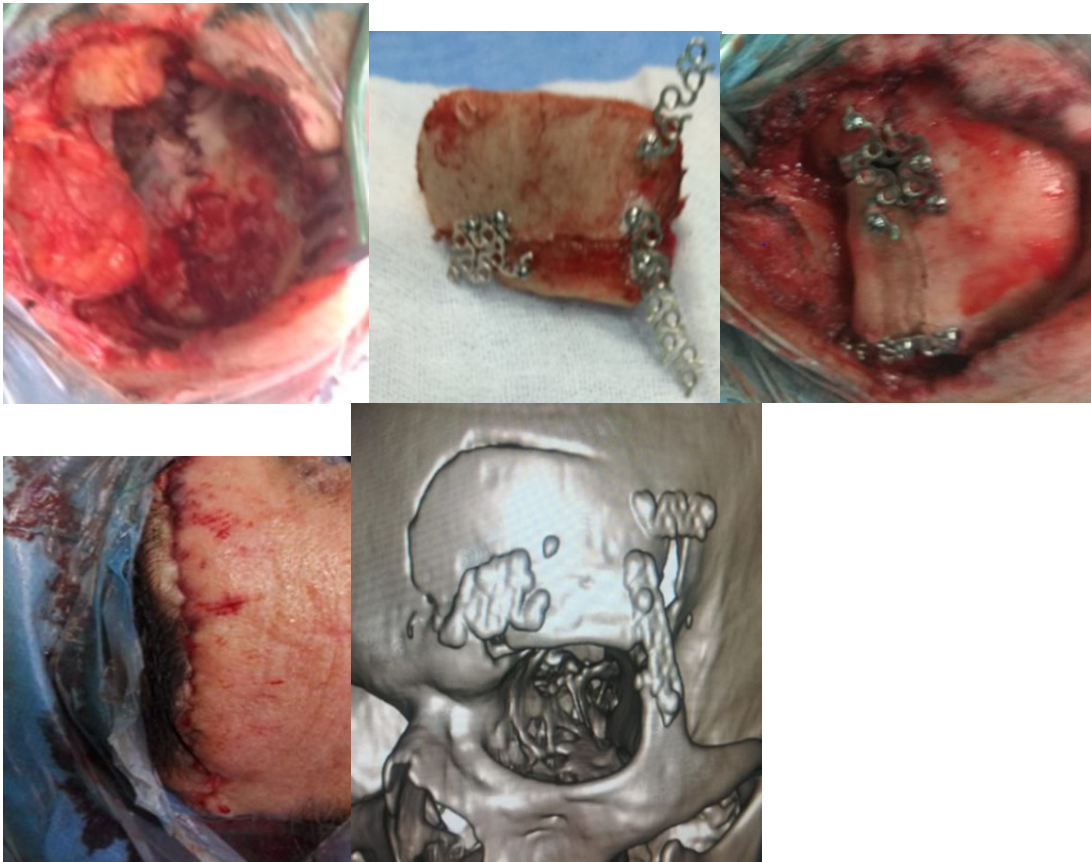
The patient was vitally stable, fully conscious and cranial nerves were intact except anosmia. There was right eye lid edema that had been resolved at day 4. CSF leak happened for 5 days then stopped gradually.

Preoperative:

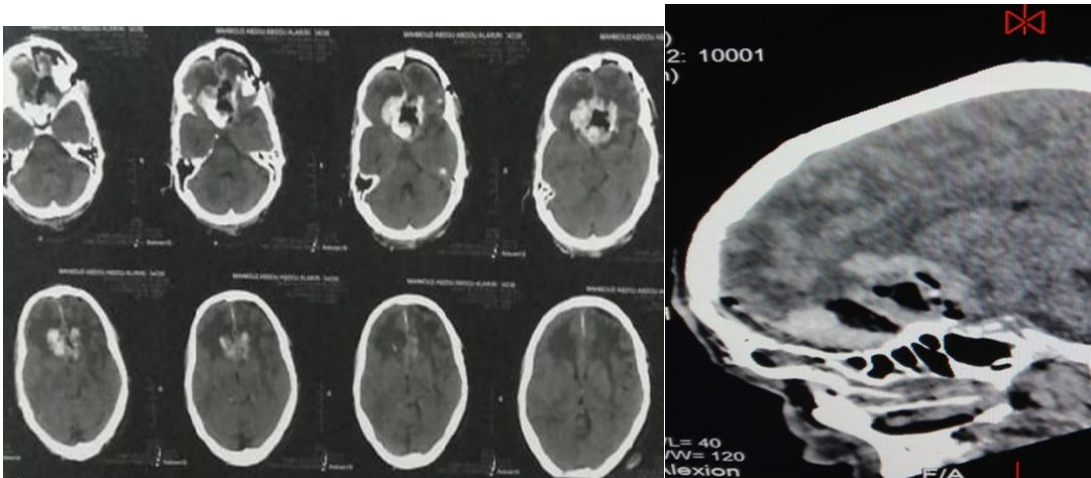


Intraoperative: position, incision, dissection & extension of bone flap





postoperative images

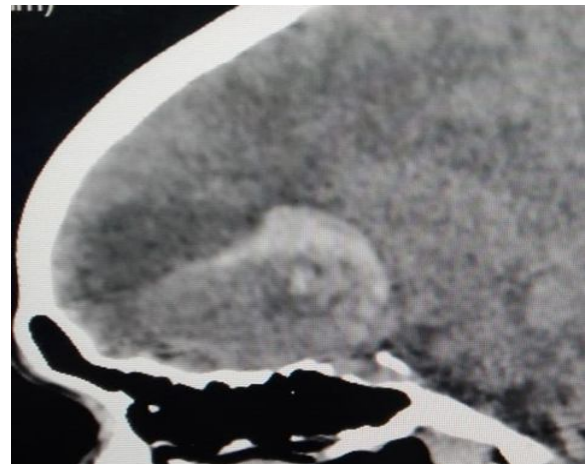
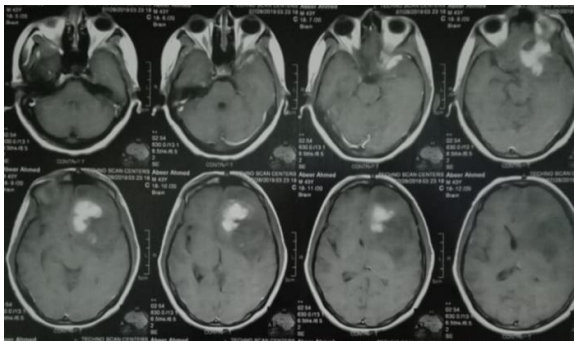


Case2 : A right handed 43 year old female presented by headache of gradual course. The patient had breast cancer, underwent mastectomy then received chemo and radiotherapy, On examination: No cranial nerves abnormality.

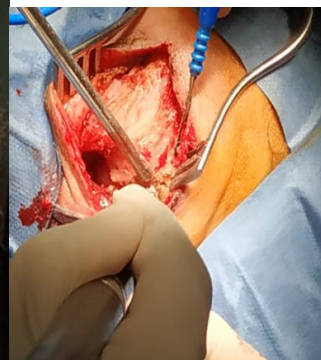
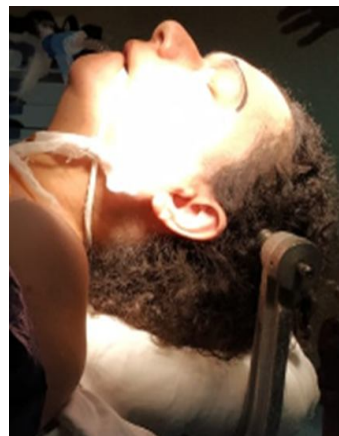
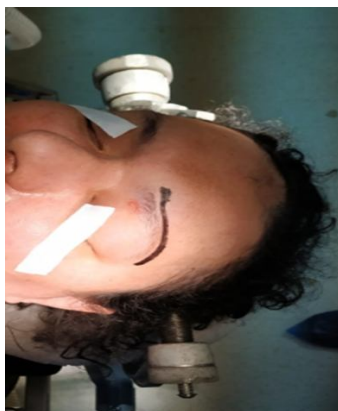CT brain: showed left frontal hyper dense sol, with midline shift, Operative time: around 180 minutes & Blood loss: 300 ml. Her imaging characteristics were most consistent with metastasis. The patient underwent elective resection of her tumor by a left supraorbital endoscopic assisted craniotomy through the left eyebrow. She had a gross total resection of the mass. **Postoperative data:**

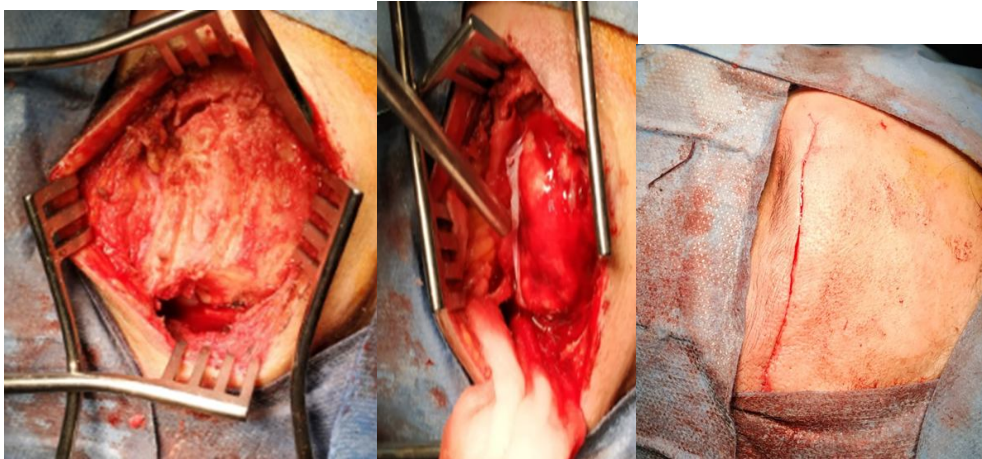
The patient was admitted to the Intensive Care Unit (ICU) for 4 days then discharged to a regular inpatient ward. She gained her conscious level gradually. There was no cranial nerves affection. The wound healed cleanly. The patient was discharged at day 10 postoperative. The histopathological analysis revealed adenocarcinoma.

Preoperative images



Position, incision, dissection



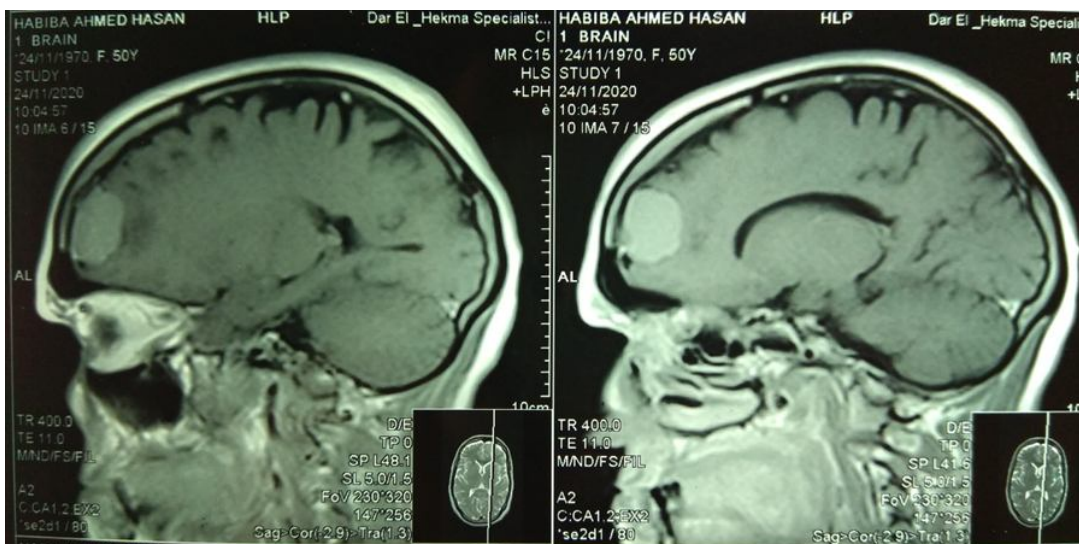


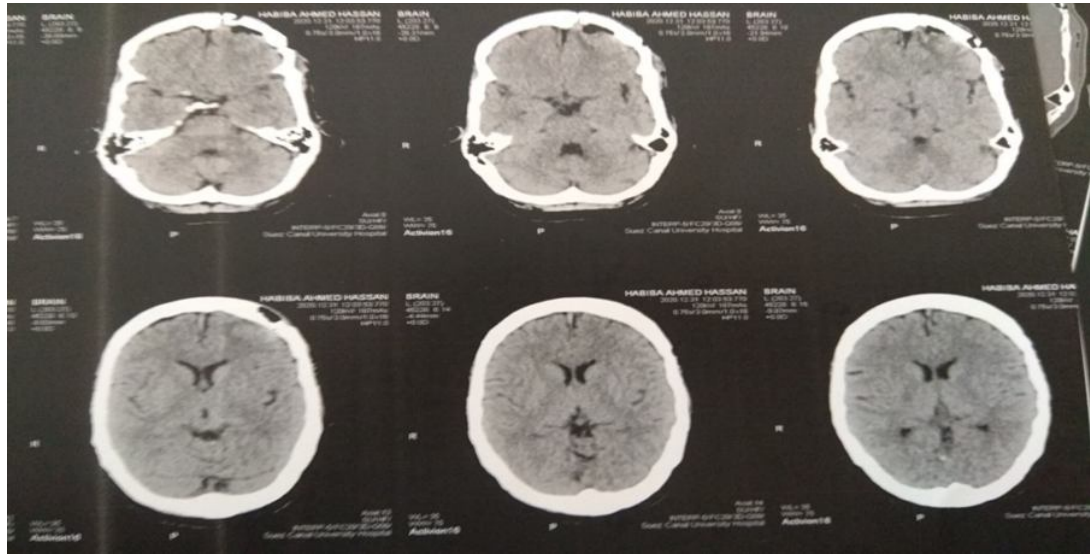
Case 3:

A right handed 50 year old female presented by headache of gradual course.

On examination: No cranial nerves abnormality.

CT brain: showed left frontal hyper dense space occupying lesion. Her imaging characteristics were most consistent with convexity meningioma. The patient underwent elective resection of her tumor by a left supraorbital endoscopic assisted craniotomy through the left eyebrow. She had a gross total resection of the mass, **Postoperative data:** The patient was admitted to the ICU for 10 hours then discharged to a regular inpatient ward. She gained her conscious level immediately. There was no cranial nerves affection. The wound healed cleanly after inflammation for few days. The patient was discharged at day 4 postoperative. The histopathological analysis revealed meningioma WHO1.





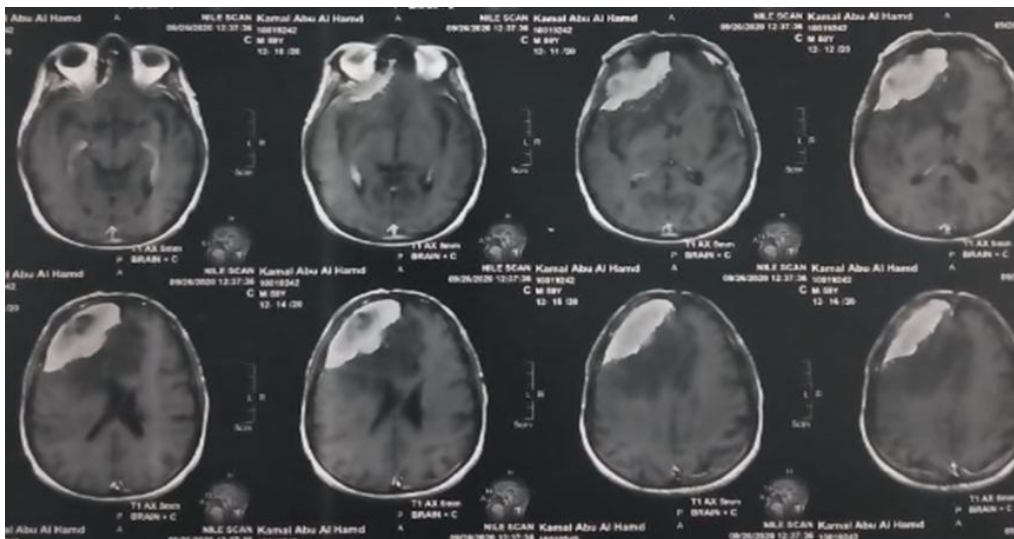
Case 4:

A 59 years old male presented with headache, blurring of vision, and convulsions. He was known to be hypertensive and had chronic liver disease, On examination: He was fully conscious and there was no cranial nerves abnormality, CT brain: Right frontal hyper dense lesion with dural base, MRI of the brain with gadolinium contrast revealed right frontal hyper intense lesion with homogenous intensity with dural base.

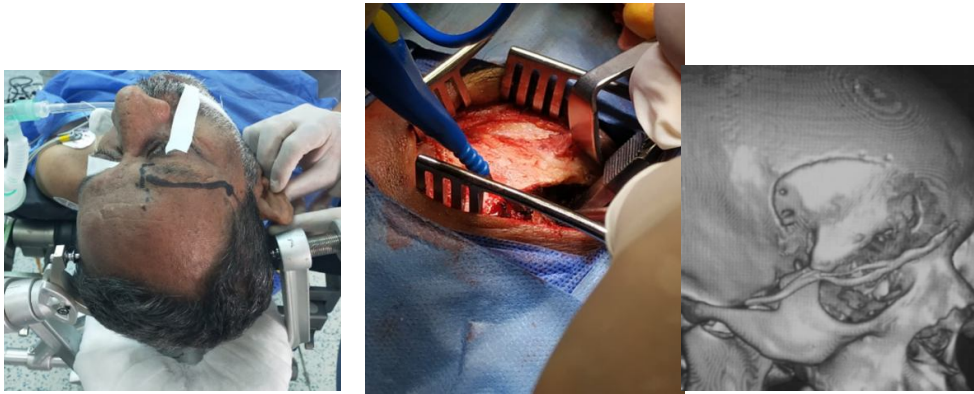
His imaging characteristics were most consistent with a convexity meningioma. The patient underwent elective resection of his tumor by a right supraorbital endoscopic assisted craniotomy through the right eyebrow. He had a gross total resection of a WHO grade II meningioma, Operative time: around 200 minutes& Blood loss: 350 ml.

The patient was admitted to the ICU for 24 hours then discharged to a regular inpatient ward. He was vitally stable, fully conscious and the cranial nerves were intact. There was weak eye lid elevation for few days then improved. The wound healed cleanly. The patient was discharged at day 4 postoperative.

Preoperative images



Position, dissection & bone flap



Postoperative CT brain

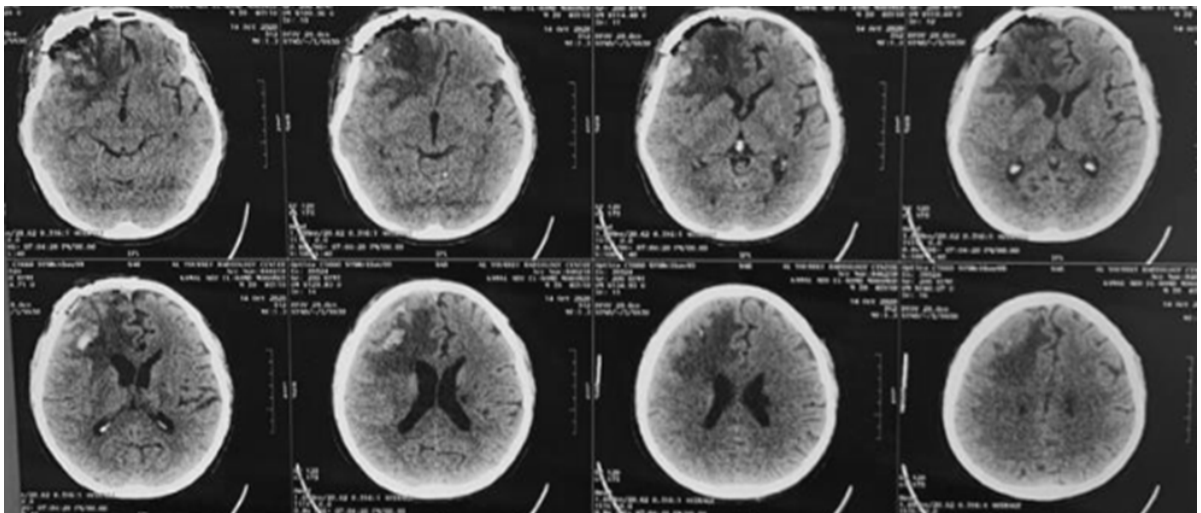
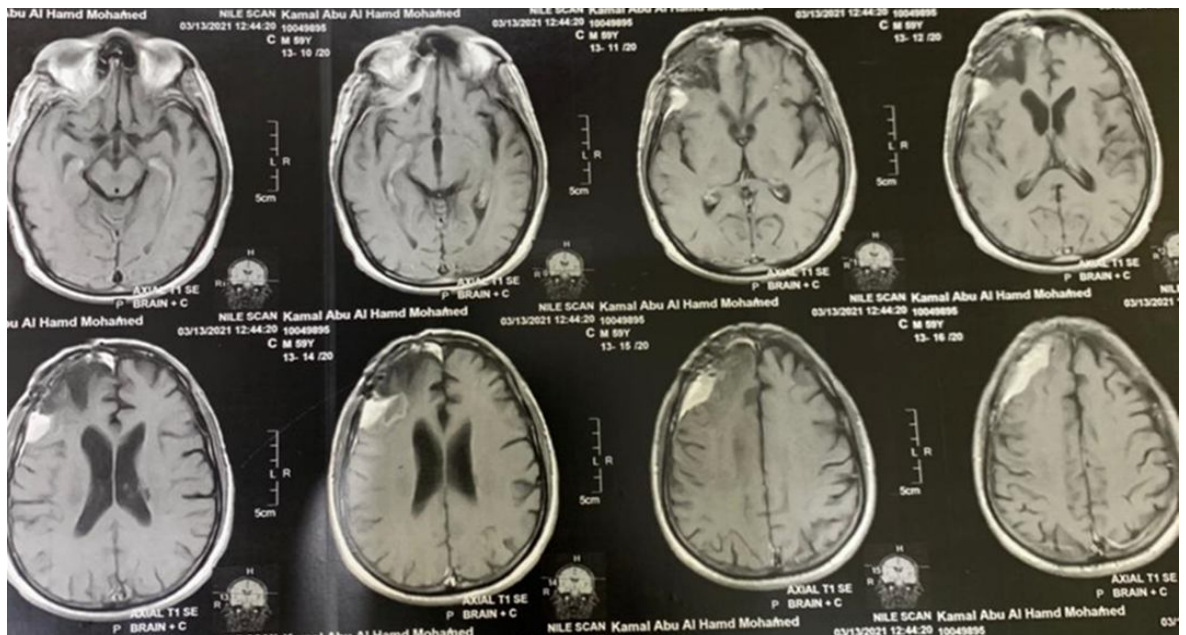


Figure: Follow-up MRI brain with contrast -axial view- 6 months postoperative



Case 5 A right handed 59 year old male presented by disturbed level of consciousness, persistent vomiting, and convulsions. He had chronic renal illness. On examination: GCS was 13/15, Cranial nerves examination: the patient was not cooperative. CT brain revealed left frontal hypo dense lesion with surrounding brain edema. MRI brain with contrast revealed left frontal intra-axial hypo intense lesion in T1 and hyper intense in T2 with irregular ring enhancement. His imaging characteristics were most consistent with glioblastoma multiforme (GBM). The patient underwent emergent resection of his tumor by a left supraorbital endoscopic assisted craniotomy through the left eyebrow. He had a gross total resection of the mass, The patient was admitted to the ICU for 2 days then discharged to a regular inpatient ward. He gained conscious level gradually. The cranial nerves were intact. The wound healed cleanly. The patient was discharged at day 7 postoperative. The histopathological analysis revealed GBM WHO grade 4.

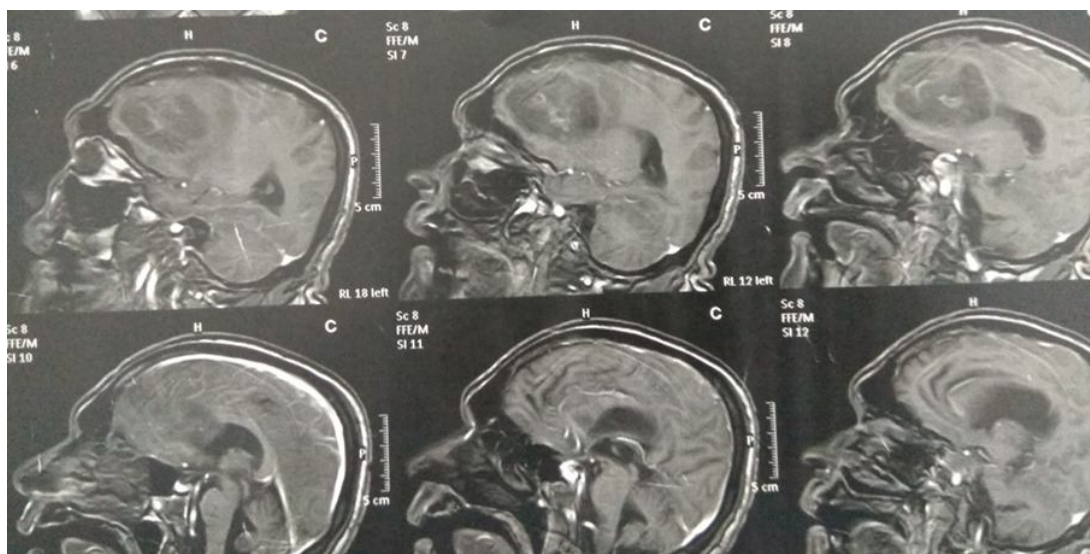
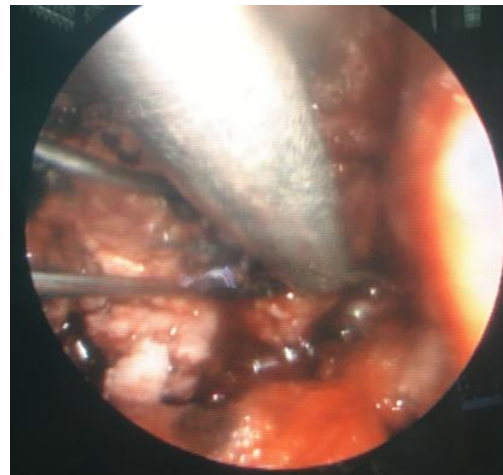
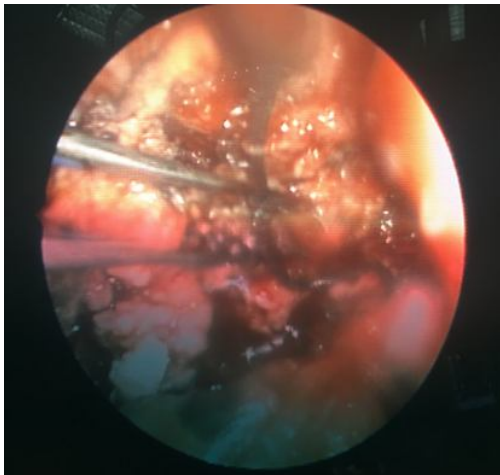
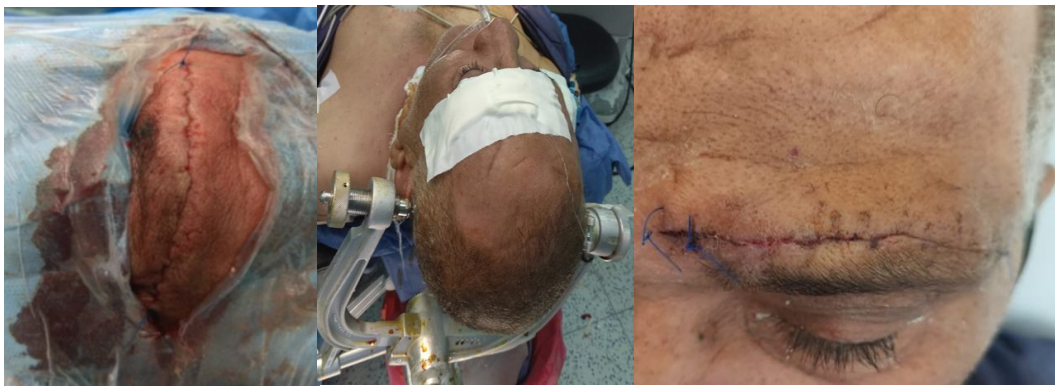


Figure: Pre-operative MRI brain with contrast (sagittal view).



intraoperative endoscopic views



Skin closure

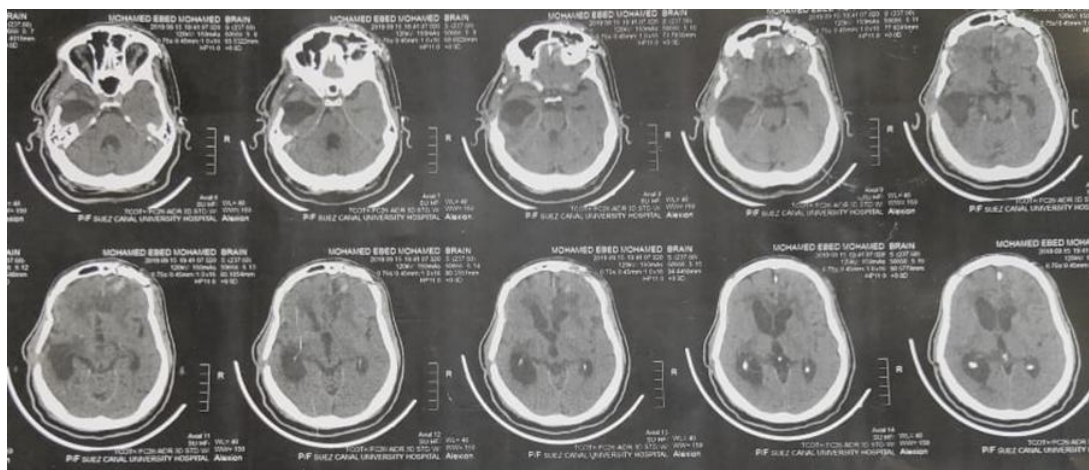
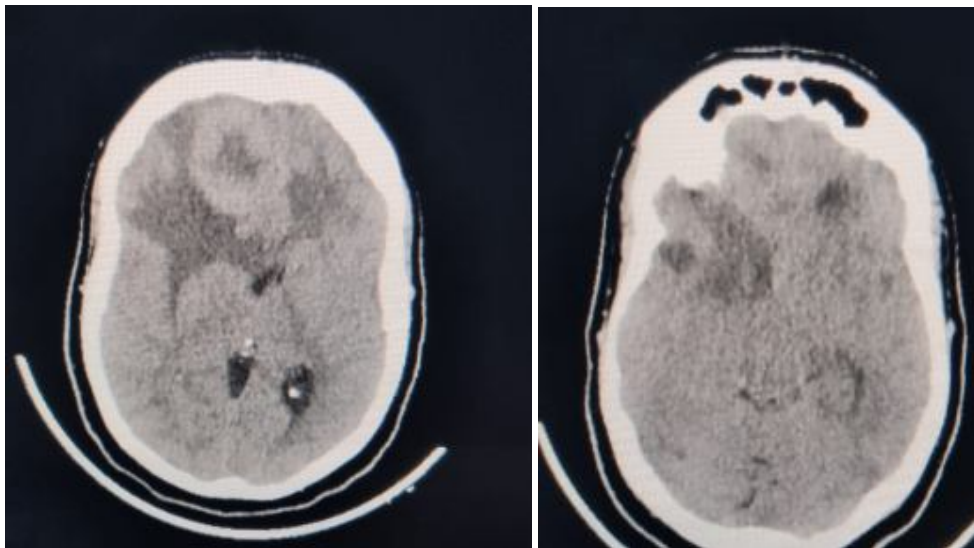
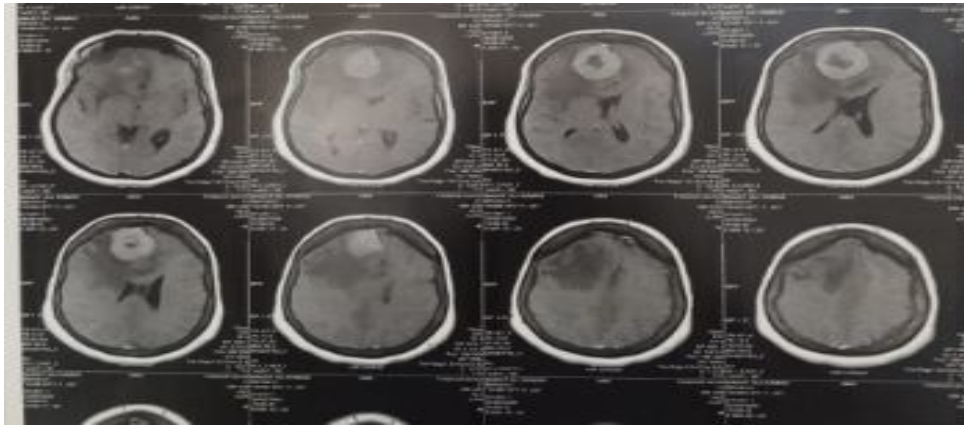
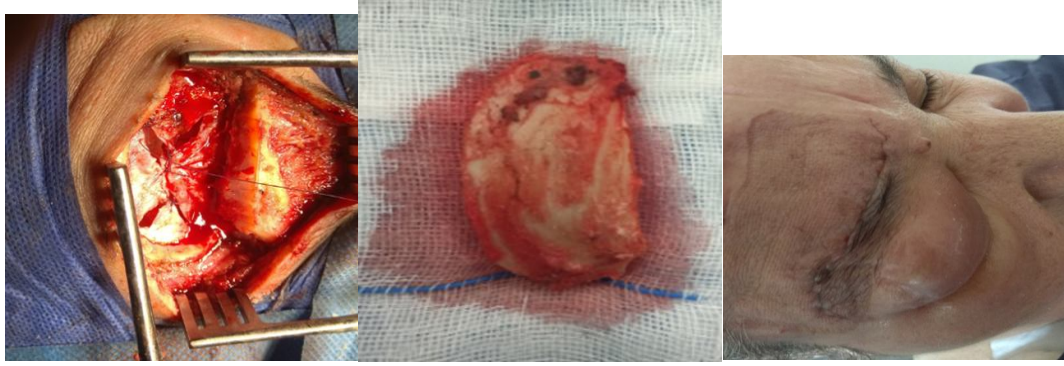


Figure: Post-operative CT brain.

Case 6 A right handed 63 year old female presented by headache of gradual course, disturbed level of consciousness, vomiting, and convulsions. The patient had malignant breast cancer and underwent mastectomy and received chemotherapy and radiotherapy, On examination: GCS 13/15, CT brain showed right frontal isodense space occupying lesion with midline shift. MRI brain with contrast showed right frontal intra-axial space occupying lesion with heterogeneous enhancement. Her imaging characteristics were most consistent with metastasis, **Intraoperative procedures:** The patient underwent elective resection of her tumor by a right supraorbital endoscopic assisted craniotomy through the right eyebrow. Operative time: around 200 minutes& Blood loss: 400 ml. **Postoperative data:** The patient was admitted to the ICU for 4 days then discharged to a regular inpatient ward. She gained conscious level gradually. The cranial nerves were intact. The wound healed cleanly. There was right eye lid edema that had been improved by the end of the first week. The patient was discharged at day 10 postoperative. The histopathological analysis revealed adenocarcinoma.





الملخص العربي

تقييم دور المنظار في استئصال أورام قاع الجمجمة الأمامي والوسطي بواسطة النهج أعلى حجاج العين

يتطلب تطوير إجراء العمليات الجراحية معرفة دقيقة للتكوين التشريحي للمنطقة والذي هو أساس القيام بالعمليات الجراحية بنجاح وأمان, وتجنب إصابة الأعصاب والأوعية الدموية داخل المخ.

يعرف قاع الجمجمة بأنه المنطقة التشريحية التي تفصل محتويات فراغ الجمجمة عن محتويات عظام الوجه وتسمح بمرور الأعصاب والأوردة والشرايين بين المنطقتين بالإضافة إلى أهميتها في حماية المخ , وينقسم قاع الجمجمة عن طريق بعض الحواجز إلى: الغرف الأمامية والوسطى والخلفية.

والتخطيط الناجح للجراحة عن طريق التدخل الأمامي أعلى حجاج العين للمنطقة الأمامية والوسطى للمخ يتضمن التقييم السليم للفحص السريري و الأشعات الخاصة بالمريض قبل الجراحة , ومعرفة التشريح الدقيق والإصابات المرضية المتوقعة للمنطقة المستهدفة.

ويعتبر هذا التدخل من التدخلات المحدودة ويهدف إلى الحفاظ على جميع الأنسجة أثناء الجراحة في محاولة لتقليل المضاعفات مع الحفاظ على النتائج المرجوة من الجراحة, بالإضافة إلى صغر حجم الجرح وفتحة الجمجمة التي تؤدي لنتائج تجميلية أفضل وفترة إقامة أقصر بالمستشفى.

ويستخدم في استئصال الأورام التي تقع في منطقة الغرف الأمامية والوسطى التي تشمل منطقة سرج الحصان وما حولها وذلك بمساعدة المنظار الجراحي الذي يساعد في الرؤية الجيدة و

الإضاءة الممتازة للأماكن التي لا ترى جيدا بالميكروسكوب الجراحي, وكذلك بمساعدة البحار الجراحي للمخ والذي يحدد حجم وأماكن الأورام بدقة والأنسجة المحيطة بها لتسهيل الوصول.

في هذه الدراسة, تم إجراء التدخل الأمامي عن طريق تخدير كلي, وتثبيت رأس المريض بواسطة جهاز تثبيت الرأس بسرير الجراحة و تم وضع الرأس مائلة بزواوية 15-20 درجة إلى الجانب الآخر للورم.

فُتح الجلد على حدود حاجب العين وتم فتح الأنسجة بحرص وترتيب وفُتحت الجمجمة بواسطة الحفار الكهربائي, وبعد ذلك فُتحت الأم الجافية وتم التعامل مع أنسجة المخ بواسطة الميكروسكوب والمنظار الجراحي.

وفي هذه الدراسة اختير 30 مريضا (12 ذكر و 18 أنثى) يعانون من أورام بالحفرة الأمامية ومنطقة سرج الحصان و تم إجراء التدخل الجراحي عن طريق النهج أعلى حجاج العين بواسطة الميكروسكوب الجراحي وبمساعدة المنظار.

و كان الإهتمام منصبا على تقييم هذه الطريقة و أسباب استخدامها ومميزاتها و عيوبها ودراسة كيفية إجرائها ومقارنتها بالطرق الجراحية الأخرى لعلاج أورام غرف قاع الجمجمة الأمامية والوسطى, ودور المنظار الجراحي في استئصال تلك الأورام.

وتبين من خلال النتائج أن هذا النهج أعلى حجاج العين آمنة ومناسبا لمختلف الأورام بتلك الأماكن وذلك بمساعدة المنظار الجراحي وفعال في استئصالها, مع التأكيد على عدم استخدامه في الأورام الكبيرة أو مبهمة الملامح والتي تلتصق بالأوعية الدموية الحيوية والأعصاب المخية, والأورام التي تمتد للحفرة الخلفية لقاع الجمجمة.

ويوفر هذا النهج عدة مزايا منها:

- 1- صغر فتحة الجلد وفتحة الجمجمة.
 - 2- الحفاظ على الشريان السطحي الصدغي.
 - 3- الحفاظ على الفروع الأمامية للعصب الوجهي.
 - 4- ارتفاع الرضى لدي المرضى عن الشكل التجميلي للجلد بعد الجراحة.
- ولذلك نوصي باستخدام هذا النهج مع مراعاة الاختيار المناسب للحالات والتحضير المناسب قبل الجراحة.