

## **Visibility of the mandibular canal: from two-dimensional radiography to three-dimensional imaging**

### **ABSTRACT**

The mandibular canal (MC), located within the mandible, carries the inferior alveolar nerve and the inferior alveolar vessels. This neurovascular bundle is at risk during mandibular surgical procedures. Therefore, an adequate preoperative evaluation of the MC could lead to safer treatment with fewer postoperative complications. The purpose of this paper was to review the most commonly used radiographic techniques in dentistry (periapical, panoramic, and cone-beam computed tomography (CBCT)) as well as their benefits and drawbacks in terms of MC visibility and, as a result, better preoperative planning in dentistry. Although panoramic radiography and CBCT technology are useful for the MC assessment, CBCT exposes the MC image more accurately and is thus regarded as the best technique for pre-surgery radiographic planning.

**Keywords:** Mandibular canal, cone-beam computed tomography, panoramic radiography, three-dimensional image, two-dimensional radiograph

### **1. INTRODUCTION**

The mandibular canal (MC), located within the mandible, carries the inferior alveolar nerve (IAN), which is a branch of the mandibular nerve, the third division of the trigeminal nerve, and the inferior alveolar vessels (artery and vein) [1,2]. The IAN supplies sensation to the mandibular teeth and gingivae and branches into: a) the mental nerve which exits the MC through the mental

foramen supplying sensory innervations to the chin and lower lip and b) the mylohyoid nerve providing motor innervations to the mylohyoid muscle [2,3].

According to its location and path, the IAN is at risk during mandibular surgical procedures [4,5]. Any aggression to the nervous bundle or ramifications may lead to a temporary/permanent loss of tactile sensation of the lower lip and chin [4]. In a study with shocking results performed in 2005, Robert et al. stated that 94.5% of surveyed California oral and maxillofacial surgeons reported instances of injury to the IAN during mandibular surgeries in a 12-month period [4]. Dimensions and paths of the MC are important parameters which decisively contribute to correct planning. Thus, an adequate preoperative visibility of the MC can yield safer treatments with less IAN morbidity [6,7].

In a study investigating the vertical positioning of the IAN in 39 edentulous human cadaveric mandibles, Kieser et al. found 30.7% (12 out of 39) of IAN located in the superior part of the body of the mandible, and 69.2% (27 out of 39) half way or closer to the inferior border of the mandible [8].

On the other hand, Kane et al. who assessed the bucco-lingual position of the MC in 20 patients using computed tomography (CT) found that the IAN and accompanying vessels are situated more or less at 4.7mm from the buccal aspect and at 1.8mm from the lingual side of the mandible at the level of the mandibular first molar [9].

The bucco-lingual position of the MC and the topography of the IAN were investigated using three-dimensional reconstruction by Kim et al. on sixty-two mandible sides. The researchers conclude that 70% of the canals followed the lingual aspect at the ramus and the mandibular body, 15% were located at the middle of the ramus behind the second molar and lingually when passing through the second and first molars, and the last 15% followed the middle or the lingual third of the mandible from the ramus to the body. On the other side, also according to Kim et al., the inferior alveolar vessels were above the IAN in 80% and in 20% lateral to it [10].

Usually the MC is unique but sometimes it may be bifid [6,11,12] and rarely trifold [13]. According to Nasseh and Aoun, bifid MC can be found in every patient even if considered uncommon and hence must be assessed effectively [6].

In fact, bifurcation of the MC was investigated by many authors via different radiographic techniques. Panoramic radiographs were used by Nortje et al. [11] and Langlais et al. [12] who

found, respectively, a prevalence of bifid MC of 0.91% (33 out of 3612) and 0.95% (57 out of 6000).

Other authors used other imaging technology such as CT and cone-beam computed tomography (CBCT) [14,15].

Usually the MC exits the mandible buccally at the mental foramen located at the apical region of the premolars [16-23].

The aim of this article was to review different visibility methods of the MC, their advantages and disadvantages, as well as their clinical application in the dentist's everyday practice.

## **2. RADIOGRAPHIC TECHNIQUES USED IN DENTISTRY**

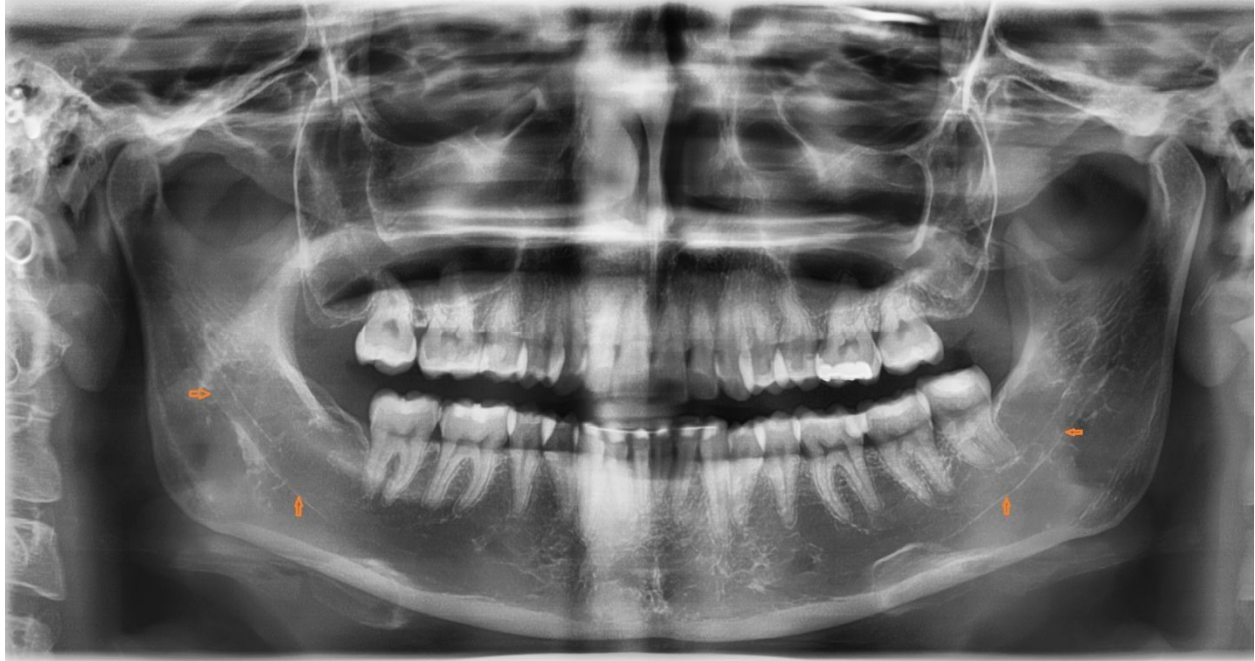In daily dental practice, the radiographic evaluation of the MC is mostly performed on periapical, panoramic and CBCT images with a percentage of visibility of 28%, 32% and 98% respectively [24]. On conventional two-dimensional (2D) radiography, the MC appears as a radiolucent image, with two well-defined radiopaque borders, inferior to the mandibular molars and premolars roots [25]. This typical appearance is mainly due to the principle of the radiographic lines formation. A radiopaque radiographic line is visible whenever the primary X-ray beam is perpendicular to the surface of separation of two different densities. In the case of the MC, the two different densities are due to the trabecular bone and the inferior neurovascular bundle.

### **2.1. Periapical radiography**

Due to their small size and short coverage, periapical radiographs, although having the best 2D image resolution, are not advised for MC evaluation [25].

### **2.2. Panoramic radiography**

Unlike periapical radiographs, the panoramic 2D X-ray offers a full teeth/oral structures overview. Concerning the MC, in the majority of cases, it can be detectable without difficulty allowing the practitioner to evaluate the risk of IAN injury during invasive interventions (Figure 1). Liu et al. had classified its path into four categories of curves: a) linear, b) arc-elliptic, c) spoon-shaped, and d) turning [26].



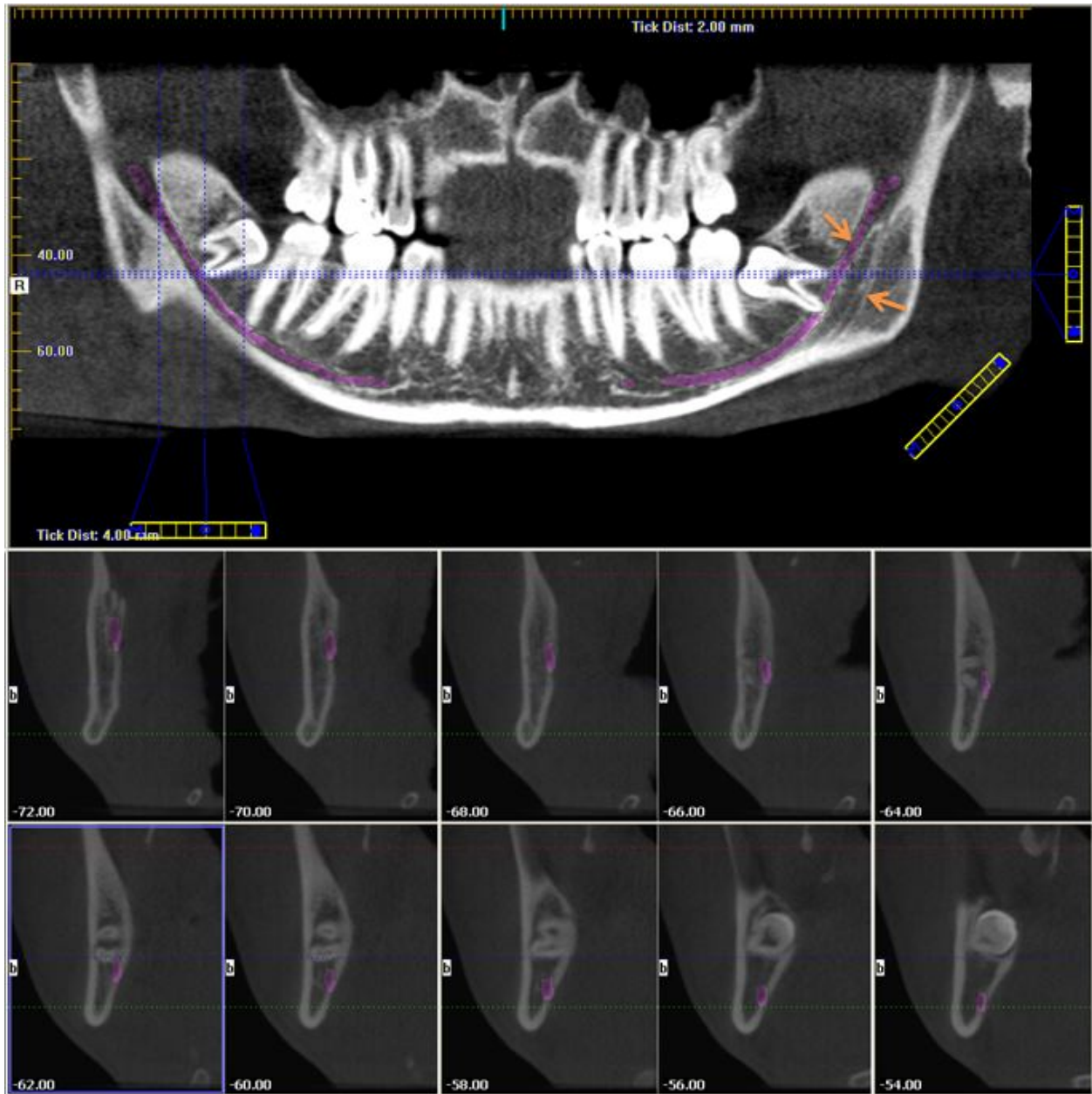
*Figure 1: Digital panoramic radiograph showing the path of the MC (arrows)*

However, this 2D technology lacks 3D information and may not visualize the small details of the MC [24]. Additionally, the MC visibility decreases when its borders become undetectable due to poor bone density or a non-perpendicularity between the canal and the principal beam [27]. Less resolution, elevated distortion and the risk of phantom images are also main disadvantage of this technique [28].

### **2.3. Cone-beam computed tomography**

CBCT has been referred to as the “gold standard” for maxillofacial imaging. This three-dimensional technology exposes the MC image more accurately. De Oliveira-Santos et al. concluded that among 41 % of the MCs not detectable on 2D radiographs, a large majority was visible on CBCT [29].

On CBCT, the MC can be seen and traced manually. The operator must be careful in mapping the reconstruction and following the MC path (Figure 2).



*Figure 2: A CBCT panoramic reconstruction and cross sectional cuts showing the path of the MC; to note the left double MC (arrows).*

Kim et al. developed a new automatic technique to isolate the MC with no intervention from the user. In early experimental results by means of 10 clinical DICOM files, this technique could exactly recognize the MC. This technique possesses, additionally, the utmost segmentation precision [30].

For Başa and Dilek, the average density and thickness of the bone surrounding the MC is not sufficient to resist the action of drilling, especially during implant placement; consequently, the operator must carefully approach the canal [31].

The location and the anatomical variations of the MC (bifid canal, double and accessory mental foramina, the incidence of an anterior loop, etc.) as noticed on CBCT have been largely assessed in the literature [5-8, 11-15].

### 3. CONCLUSION

The neurovascular bundle located in the MC is at risk during invasive surgical interventions in the mandibular regions. Therefore, thorough clinical and radiological assessments before any procedure are essential. Both panoramic radiography and CBCT are useful techniques for MC evaluation; however, CBCT exposes the MC image more accurately and is thus regarded as the best technique for pre-surgery radiographic planning.

#### Disclaimer

This paper is an extended version of a preprint document of the same author.

The preprint document is available in this link: <file:///C:/Users/Editor-28/Downloads/MC+to+Scielo+Preprints.pdf>

[As per journal policy, pre-print article can be published as a journal article, provided it is not published in any other journal]

#### References

1. Juodzbaly G, Wang HL, Sabalys G. Anatomy of mandibular vital structures. Part I: mandibular canal and inferior alveolar neurovascular bundle in relation with dental implantology. J Oral Maxillofac Res. 2010; 1(1): e2.
2. Iwanaga J, Choi PJ, Vetter M, Patel M, Kikuta S, Oskouian RJ, Tubbs RS. Anatomical Study of the Lingual Nerve and Inferior Alveolar Nerve in the Pterygomandibular Space: Complications of the Inferior Alveolar Nerve Block. Cureus. 2018; 10(8): e3109.

3. Wolf KT, Brokaw EJ, Bell A, Joy A. Variant inferior alveolar nerves and implications for local anesthesia. *Anesth Prog.* 2016; 63(2): 84-90.
4. Robert RC, Bacchetti P, Pogrel MA. Frequency of trigeminal nerve injuries following third molar removal. *J Oral Maxillofac Surg.* 2005; 63(6): 732-735.
5. Nair UP, Yazdi MH, Nayar GM, Parry H, Katkar RA, Nair MK. Configuration of the inferior alveolar canal as detected by cone beam computed tomography. *J Conserv Dent.* 2013; 16(6): 518-521.
6. Nasseh I, Aoun G. Bifid mandibular canal: a rare or underestimated entity? *Clin Pract.* 2016; 6(3): 881.
7. Mirbeigi S, Kazemipoor M, Khojastepour L. Evaluation of the course of the inferior alveolar canal: the first CBCT study in an Iranian population. *Pol J Radiol.* 2016; 81: 338-341.
8. Kieser JA, Paulin M, Law B. Intrabony course of the inferior alveolar nerve in the edentulous mandible. *Clin Anat.* 2004; 17(2): 107-111.
9. Kane AA, Lo LJ, Chen YR, Hsu KH, Noordhoff MS. The course of the inferior alveolar nerve in the normal human mandibular ramus and in patients presenting for cosmetic reduction of the mandibular angles. *Plast Reconstr Surg.* 2000; 106(5): 1162-1174.
10. Kim ST, Hu KS, Song WC, Kang MK, Park HD, Kim HJ. Location of the mandibular canal and the topography of its neurovascular structures. *J Craniofac Surg.* 2009; 20(3): 936-939.
11. Nortjé CJ, Farman AG, Grotepass FW. Variations in the normal anatomy of the inferior dental (mandibular) canal: a retrospective study of panoramic radiographs from 3612 routine dental patients. *Br J Oral Surg.* 1977; 15(1): 55-63.
12. Langlais RP, Broadus R, Glass BJ. Bifid mandibular canals in panoramic radiographs. *J Am Dent Assoc.* 1985; 110(6): 923-926.
13. Bogdán S, Pataky L, Barabás J, Németh Z, Huszár T, Szabó G. Atypical courses of the mandibular canal: comparative examination of dry mandibles and x-rays. *J Craniofac Surg.* 2006; 17(3): 487-491.
14. Kuribayashi A, Watanabe H, Imaizumi A, Tantanapornkul W, Katakami K, Kurabayashi T. Bifid mandibular canals: cone beam computed tomography evaluation. *Dentomaxillofac Radiol.* 2010; 39(4): 235-239.

15. Naitoh M, Hiraiwa Y, Aimiya H, Arijji E. Observation of bifid mandibular canal using cone-beam computerized tomography. *Int J Oral Maxillofac Implants*. 2009; 24(1): 155-159.
16. Aoun G, El-Outa A, Kafrouny N, Berberi A. Assessment of the mental foramen location in a sample of fully dentate Lebanese adults using cone-beam computed tomography technology. *Acta Inform Med*. 2017; 25(4): 259-262.
17. Afkhami F, Haraji A, Boostani HR. Radiographic localization of the mental foramen and mandibular canal. *J Dent (Tehran)*. 2013; 10(5): 436-442.
18. Currie CC, Meechan JG, Whitworth JM, Carr A, Corbett IP. Determination of the mental foramen position in dental radiographs in 18-30 year olds. *Dentomaxillofac Radiol*. 2016; 45(1): 20150195.
19. Al-Mahalawy H, Al-Aithan H, Al-Kari B, Al-Jandan B, Shujaat S. Determination of the position of mental foramen and frequency of anterior loop in Saudi population. A retrospective CBCT study. *Saudi Dent J*. 2017;29(1):29-35.
20. Ilayperuma I, Nanayakkara G, Palahepitiya N. Morphometric analysis of the mental foramen in adult Sri Lankan mandibles. *Int J Morphol*. 2009; 27(4): 1019-1024.
21. Wang TM, Shih C, Liu JC, Kuo KJ. A clinical and anatomical study of the location of the mental foramen in adult Chinese mandibles. *Acta Anat (Basel)*. 1986; 126(1): 29-33.
22. Kekere-Ekun TA. Antero-posterior location of the mental foramen in Nigerians. *Afr Dent J*. 1989; 3(2): 2-8.
23. Ngeow WC, Yuzawati Y. The location of the mental foramen in a selected Malay population. *J Oral Sci*. 2003; 45(3): 171-175.
24. Miloro M, Kolokythas A. Inferior alveolar and lingual nerve imaging. *Atlas Oral Maxillofac Surg Clin North Am*. 2011; 19(1): 35-46.
25. Politis C, Ramírez XB, Sun Y, Lambrichts I, Heath N, Agbaje JO. Visibility of mandibular canal on panoramic radiograph after bilateral sagittal split osteotomy (BSSO). *Surg Radiol Anat*. 2013; 35(3): 233-240.
26. Liu T, Xia B, Gu Z. Inferior alveolar canal course: a radiographic study. *Clin Oral Implants Res*. 2009; 20(11): 1212-1218.
27. Kubilius M, Kubilius R, Varinauskas V, Žalinkevičius R, Tözüm TF, Juodžbalys G. Descriptive study of mandibular canal visibility: morphometric and densitometric

analysis for digital panoramic radiographs. *Dentomaxillofac Radiol.* 2016; 45(7): 20160079.

28. Weckx A, Agbaje JO, Sun Y, Jacobs R, Politis C. Visualization techniques of the inferior alveolar nerve (IAN): a narrative review. *Surg Radiol Anat.* 2016; 38(1): 55-63.
29. de Oliveira-Santos C, Souza PH, de Azambuja Berti-Couto S, Stinkens L, Moyaert K, Rubira-Bullen IR, Jacobs R. Assessment of variations of the mandibular canal through cone beam computed tomography. *Clin Oral Investig.* 2012;16(2):387-393.
30. Kim G, Lee J, Lee H, Seo J, Koo YM, Shin YG, Kim B. Automatic extraction of inferior alveolar nerve canal using feature-enhancing panoramic volume rendering. *IEEE Trans Biomed Eng.* 2011; 58(2): 253-264.
31. Başa O, Dilek OC. Assessment of the risk of perforation of the mandibular canal by implant drill using density and thickness parameters. *Gerodontology.* 2011; 28(3): 213-220.

UNDER PEER REVIEW