

A COMPARISON OF POSTOPERATIVE HEALING BETWEEN TWO DIFFERENT FLAPS FOR 3RD MOLAR SURGERY IN CONTROLLED DIABETIC PATIENTS

TITLE PAGE: -

Type of manuscript – CASE PRESENTATION

Title of the article – A COMPARISON OF POSTOPERATIVE HEALING BETWEEN TWO DIFFERENT FLAPS FOR 3RD MOLAR SURGERY IN CONTROLLED DIABETIC PATIENTS

Running title – A COMPARISON OF POSTOPERATIVE HEALING BETWEEN TWO DIFFERENT FLAPS FOR 3RD MOLAR SURGERY IN CONTROLLED DIABETIC PATIENTS

ABSTRACT

BACKGROUND- A flap is a unit of tissue that is transferred from donor site to recipient site while maintaining its own blood supply. Flaps are of various shapes and forms. They can be simple advancements of skin and range up to composites of many different types of tissue. Diabetes Mellitus is a metabolic disease where there is significant elevation of blood glucose level from the normal range for prolonged periods of time. The common signs and symptoms are, frequent urination, increased thirst, increased appetite, lethargy, infections, delayed healing of wounds. The complications of surgical procedures on diabetic patients are: delayed healing, wound dehiscence and decreased immunity, thus increased incidence of infection in the surgical site. Complications of intra-oral surgical procedures include delayed healing, wound dehiscence, bone loss, periodontal derangement of teeth, infection, xerostomia causing more caries, failure of flap due to decreased vascularity.

AIMS AND OBJECTIVES- The study aimed to answer whether Envelope Flap is better than Triangular Flap or vice versa for a mandibular 3rd molar surgery. To examine the complications of choosing a specific flap design in a minor oral

surgery in patients with higher susceptibility to infection due to systemic condition, which is controlled Diabetes Mellitus.

MATERIALS AND METHODS- This study was conducted on 20 patients, who were taken from the out-patient of Department of Oral and Maxillofacial Surgery, Sree Balaji Dental College and Hospital, Chennai. On one side which was picked randomly for all patients, the Triangular flap was used. On the other side, the Envelope flap was used.

CONCLUSION- The statistical analysis P value > 0.05 , which shows that the difference in post operative healing between the two flaps discussed is statistically insignificant. Thus, statistically both flaps are a viable option and both show similar results, although clinically envelope flap shows better overall results.

KEYWORDS

THIRD MOLAR SURGERY, INTRA ORAL FLAP, TRIANGULAR FLAP, ENVELOPE FLAP, MANDIBULAR THIRD MOLAR IMPACTION

INTRODUCTION

A flap is a unit of tissue that is transferred from donor site to recipient site while maintaining its own blood supply. Flaps can be of many different shapes and forms. They can be simple advancements of skin and range up to composites of many different types of tissue. These composites not only consist of soft tissue, but man contain various other forms of connective tissue as well, such as bone or cartilage or both. They may include skin, muscle, bone, fat, or fascia. The difference between a flap and a graft is that flap is transferred with its blood supply intact, and a graft is a transfer of tissue without its own blood supply. Thus, the survival of the graft depends mostly on the blood supply from the recipient site.

Odontectomy is the removal of partly erupted or unerupted teeth or retained roots that cannot be extracted by the forceps technique and therefore must be removed by surgical excision. The most commonly impacted or unerupted teeth are the mandibular and maxillary third molars and the maxillary canines. Among them, the

mandibular 3rd molar is the most commonly impacted tooth. The prevalence of third molar impaction ranges from 16.7% to 68.6%.

The condition of having a normal concentration of glucose in the blood is known as Euglycemia. According to the World Health Organization guidelines, the normal blood glucose levels are: Post prandial blood sugar (2 hour) of 120-140 mg/dL, fasting blood sugar of 80-110 mg/dL and HbA1c of 4-5.6%. If the blood sugar levels are lesser than these ranges, it is known as Hypoglycemia. If the blood sugar levels are elevated than the normal range, it is known as Hyperglycemia.

The normal blood glucose levels in the body are maintained by 2 hormones secreted by the pancreas- Insulin and Glucagon. Insulin decreases the blood sugar level by converting glucose to glycogen and Glucagon increases the blood sugar level when required by converting glycogen to blood glucose.

Diabetes Mellitus is a metabolic disease where there is significant elevation of blood glucose level from the normal range for prolonged periods of time. The common signs and symptoms are, frequent urination, increased thirst, increased appetite, lethargy, infections, delayed healing of wounds.

Diabetes mellitus, if left untreated, can become a serious health risk and can cause diabetic ketoacidosis, pulmonary diseases, cardiovascular disease, stroke, chronic kidney disease, foot ulcers, damage to the nerves, damage to the eyes, cognitive impairment and even death.

Diabetes mellitus are mainly of three types: Type 1, Type 2 and Gestational. Type 1 diabetes mellitus also known as insulin dependent or juvenile diabetes, is caused due to the pancreas's inability to produce insulin. Type 2 diabetes mellitus also known as non-insulin dependent or adult-onset diabetes, is due to insulin resistance, where although insulin production is sufficient, the cells are unable to utilize it. Gestational diabetes occurs in pregnant women without prior history of diabetes.

Type 1 diabetes mellitus has a prevalence of 10% and that of type 2 is 90% of all diabetes mellitus cases.

The complications of surgical procedures on diabetic patients are: delayed healing, wound dehiscence and decreased immunity, thus increased incidence of infection in the surgical site. Delayed healing, wound dehiscence, loss of bone, periodontal

derangement of teeth, infection, rampant caries due to xerostomia, failure of flap due to decreased vascularity are some of the commonly seen complications of intra-oral surgery.

Thus, prior to surgical procedure, the blood sugar levels must be normalized and maintained as such throughout the intra-operative time period, as well as post-operatively until there are satisfactory levels of wound healing. Also, in such patients' meticulous post-operative care must be taken, intraorally which surmounts to proper oral hygiene. Post-operative administration of sufficient antibiotics and Non-Steroidal Anti-Inflammatory Drugs are of paramount importance.

REVIEW OF LITERATURE

The term flap originated in the 16th century from the Dutch word “flappe”, meaning something that is hung broad and loose, fastened only by one side. The history of flap surgery dates as far back as 600 BC, when Sushruta Samita described nasal reconstruction using a cheek flap. The origins of forehead rhinoplasty may be traced back to approximately 1440 AD in India. There is certain historical evidence that suggest flap surgeries might have been performed before the birth of Christ.

Historically, variety of illnesses have been treated through dental extractions. Before the antibiotics were discovered, chronic tooth infections were often linked to a variety of health problems, and so removal of a diseased tooth was a common treatment for various medical conditions. Instruments used for dental extractions date back several centuries.

In 1962, Ash et al, reported that the incidence of periodontal pockets and/or root exposure on the distal aspect of second molars was increased after the removal of completely or partially impacted maxillary and mandibular third molars.

Berwick ^[20], in 1966, described a tongue-shaped flap which extended onto the buccal shelf of the mandible and had its base at the distolingual aspect of the second molar.

In 1970, Groves and Moore examined a total of 59 mandibular second molars following the removal of adjacent impacted mandibular third molars. They attempted to relate three modes of soft tissue flap design to the periodontal status of the second molars following surgery, and concluded that flap design may influence the final post operative healing of the mandibular second molar from a periodontal point of view.

In 1971, Szymd described two different flap designs in detail. The first was an envelope flap with the incision beginning just medial to the external oblique ridge and extending to the middle of the distal line angle of the second molar. From this point, a sulcular incision was extended from the distofacial line angle of the second molar to the mesiofacial line angle of the first molar. This flap may be modified to include a gingivectomy of the tissues overlying the third molar impaction by extension of a second incision from the external oblique line to the distolingual line of the second molar and removal of the resultant wedge of tissue. The second flap described by Szymd was essentially the same as the first except that a vertical incision was extended from the distofacial line angle of the second molar apically and went up to the mucogingival line by about 2 to 3 mm.

Magnus et al ^[21], in 1972, discussed an alternative to an envelope flap. Rather than carrying an incision anteriorly around the gingival margins of the second and first molars, they proposed that the anterior releasing incision be located 0.5 cm apical to the gingival margin of these molars. They stated that “the greatest single factor leading to delay in healing is excessive edema.”

In 1983, George K. B. Sandor ^[65], et al, published a study where they compared the intra operative complications due to a specific systemic condition in oral surgery. Two of the patients with Diabetes Mellitus Type 1 went into syncope during the procedure.

A further advancement in flap surgery came in the 1990s, when perforator flaps were 1st introduced. In these flaps small vessels supply them which generally originate from a named blood supply and penetrate through muscle, muscle septae, or both to give supply to the overlying tissue. For example, the deep inferior epigastric perforator (DIEP) flap, which is now the gold standard for breast reconstruction. Preoperative mapping of perforator flaps is done with Non-contrast MRI.

In 2002, Norbert Jakse ^[60], Vedat Bankaoglu, Gernot Wimmer, Antranik Eskici and Christof Pertl, KARL-FRANZENS UNIVERSITY GRAZ Austria, did a comparative study between envelope flap and modified triangular flap on primary wound healing. The final result was a total of 33% wound dehiscence. In the group where envelope-flap was used, wound dehiscences developed in about 57% of the cases. The relative risk ratio thus calculated was 5.67, with a 95% CI from 1.852 to 12.336. With the modified triangular-flap technique, only 10% of the wounds gaped during wound healing.

In 2018, Hassan Mohajerani, Mohammad Esmaeelinejad, Mehrshad Jafari, Ehsan Amini, Somayeh P Sharabiany ^[63] published a study where they compared incidence of dry socket post operatively in 3rd molar surgery between Envelope Flap and Modified Triangular flap. They found that Degree of dry socket incidence in MTF group was 11.76% and it was 41.17% in EF group (p= 0.042). In the patient follow-up, on the 3rd post operative day, healing degree mean in MTF group was 3.16 ± 1.5 and it was 4.37 ± 1.8 in EF group (p = 0.112). In post-op follow up on 7th post operative day, mean healing degree in MTF group was 0.037 ± 0.6 and it was 0.89 ± 0.73 in EF group (p =0.005).

In 2021, Ji-Yuan Liu, et al ^[66], published a prospective study on 60 patients, where they compared the postoperative pain, swelling, mouth opening, and periodontal status between group A, distal-triangular flap; group B, Szmyd flap; and group C, envelope flap. They concluded No statistical differences were found in the postoperative symptoms and signs of the three flap designs, such as postoperative pain, swelling, mouth opening, and periodontal status (P>0.05).

MATERIALS AND METHODS

SAMPLE SIZE CALCULATION

Sample size calculation was done using G*power software version 3.1.9.7, and was determined to be 10 with confidence interval of 96%. This study was conducted on 20 patients (n=20), which was deemed sufficient for the study, who were taken from the out-patient of Department of Oral and Maxillofacial Surgery.

Patients were first screened for ongoing or recent COVID-19 infection by taking of proper medical history and recording of body temperature.

INCLUSION CRITERIA:

- Patients aged 25-40 years, who are medically fit to undergo the procedure.
- Patients with Bilateral mesioangular impacted mandibular 3rd molar
- Patients with history of controlled Diabetes Melitus and under anti-diabetic therapy
- Patient's consent to be part of the study
- Patients of both genders

EXCLUSION CRITERIA:

- Presence of osseous pathologies
- Immunocompromised patients
- Recent history of myocardial infarction, etc
- Female patients in their 1st or 3rd trimester of pregnancy

FLAP TECHNIQUES USED:

ENVELOPE FLAP- Is a flap which starts as a sulcular incision from the mesial aspect of first molar to the distal aspect of the second molar and a distal relieving incision to the mandibular ramus. It is a commonly used technique for lower third molar surgical extraction. Two or three single interrupted sutures are placed distal to 2nd molar, while making sure of an exact repositioning in the area of the gingival margin, for closure. Also, interdental sutures are replaced between the first and the second molars to better adapt the flap.

THE TRIANGULAR FLAP- This technique was described by Szmyd in 1971. The incision starts at the mandibular ramus, continuing to the distobuccal crown edge of the second molar, then a crevicular incision around the 2nd molar is made and

finally a perpendicular incision is placed obliquely into the mandibular vestibulum from the mesial aspect of the 2nd molar, with a length of about 10 mm. For closure, the same suturing technique as the envelope flap is used distally, whereas the perpendicular incision is only adapted with a single coronally placed suture. The main aim is exact repositioning of the gingival margin in the area of the second molar. The loose adaption in the apical portion allows easy relief of inflammatory exudates.

RANDOMIZATION AND BLINDING- For randomization a DOUBLE Coin-Toss method was employed, where in the 1st coin toss, the side of the mandible was determined, heads for right and tails for left. The 2nd coin toss determined the flap technique to be used, Heads meant Envelope flap and Tails meant Triangular Flap. A total of 20 patients turned up and gave consent for this study. So, we had a total of 40 teeth as the sample size. In each patient one side was chosen using coin toss randomization for one technique and the other side was chosen for the other technique. The two sides were operated 3 months apart from each other. The study had single Blinding model. The surgeon knew which side which flap was going to be used, but the data collection was done by the co-author who was blinded.

Pre-operative probing depth was measured and recorded for 36, 37, 46 and 47 for all the patients. Pre operative mouth opening was measured and recorded. Pre-operative photos of the teeth were taken and stored. Blood sugar levels were checked prior to the surgery through fasting blood sugar and postprandial blood sugar tests, which were done the central laboratory in Sree Balaji Dental College and Hospital.

The patients were thoroughly explained about the study, operative procedures and risks involved. Both informed and written consent in local language was taken prior to the start of the procedures. Blood sugar levels were recorded for all the participant patients. OPG or IOPAR were taken and recorded.

OPERATIVE PHASE:

TRIANGULAR FLAP

On one side which was picked randomly for all patients, the Triangular flap was used. Where local anesthetic (2% lignocaine hydrochloride + 1:800000 adrenaline) was administered through the Inferior Alveolar Nerve Block.

Ward's incision, i.e., anterior releasing incision was placed obliquely at distal line angle of 2nd mandibular molar, crevicular incision was placed in relation to the distal aspect of 2nd molar, extending around the buccal gingival crevice of 3rd molar up to distal line angle of 3rd molar and then posterior releasing incision was placed postero-laterally tracing the anterior border of ascending ramus of mandible, was placed in relation to the impacted mandibular 3rd molar of that side. Mucoperiosteal flap was reflected through a blunt dissection.

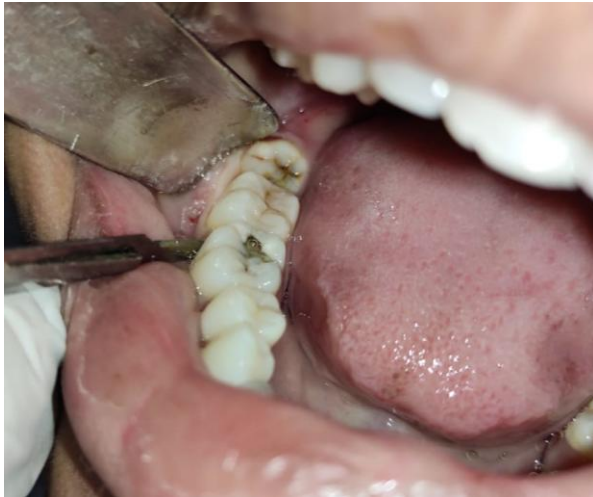

Image 1: Tooth structure

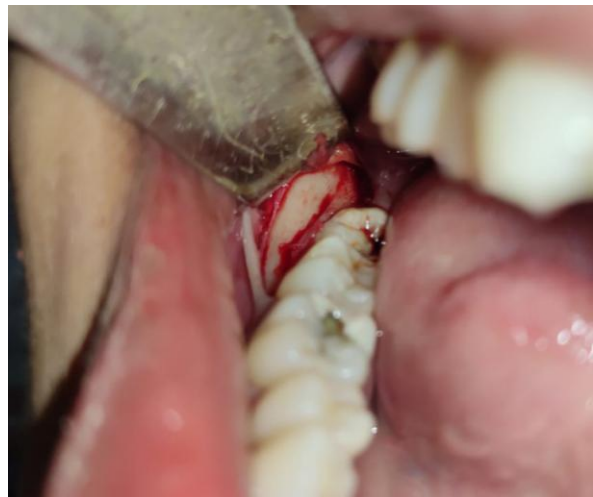

Image 2: Triangular flap

Bone guttering was done around the tooth, using a 703 stainless steel surgical bur mounted on a surgical straight rotatory handpiece.

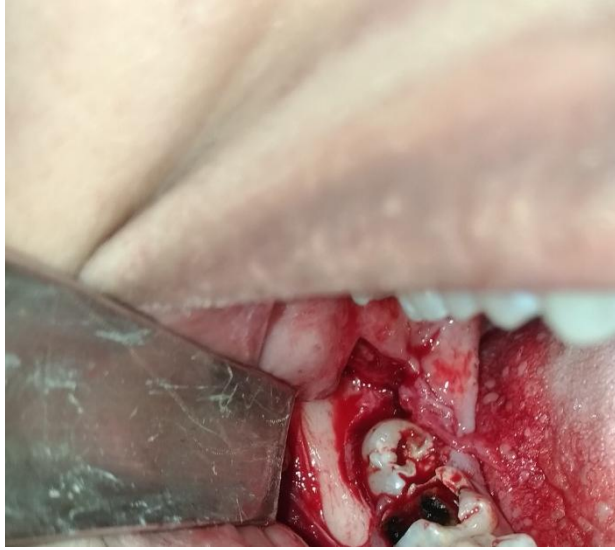

Image 3: Bone guttering

The tooth was elevated out of the socket in toto. Then copious amounts of saline was used to irrigate the socket. The sharp bony edges were smoothed with a bone file. Follicular lining if any was removed.

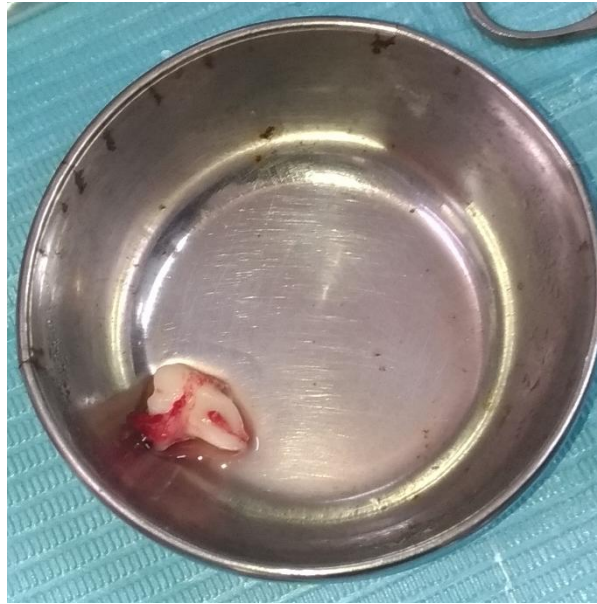

Image 4: Single teeth

3.0 braided silk was used for closure. 4 sutures were used in each patient to achieve a tight closure. The anterior releasing incision was left open to allow the soil to drain out.

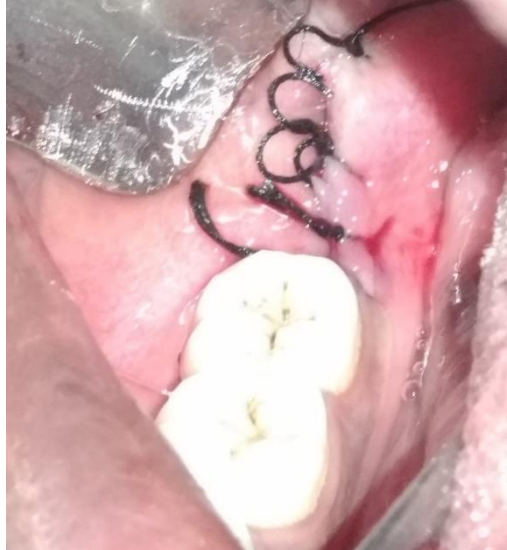


Image 5: incision

Antibiotics and analgesics were prescribed for 5 days. Patient was asked to report after 7 days for review.

ENVELOPE FLAP

On the other side, the Envelope flap was used. Where local anesthetic (2% lignocaine hydrochloride + 1:800000 adrenaline) was administered through the Inferior Alveolar Nerve Block.

Crevicular incision was placed on the buccal gingival crevice, in relation to the distal 1/3rd of the 1st mandibular molar of that side, extended through the buccal gingival crevice of the 2nd molar, then extending it up to the 3rd molar, and finally placing a posterior releasing incision, postero-laterally, which traces the anterior border of the ascending ramus, postero-laterally. Mucoperiosteal flap was reflected through a blunt dissection.

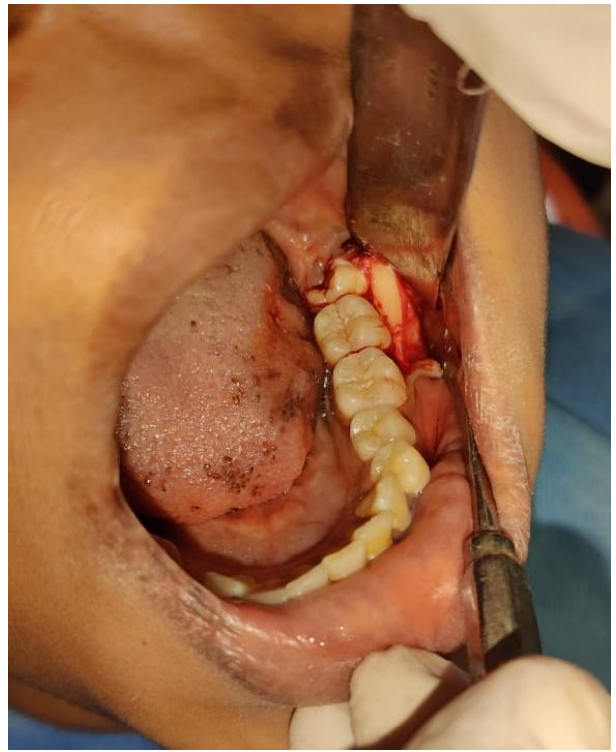
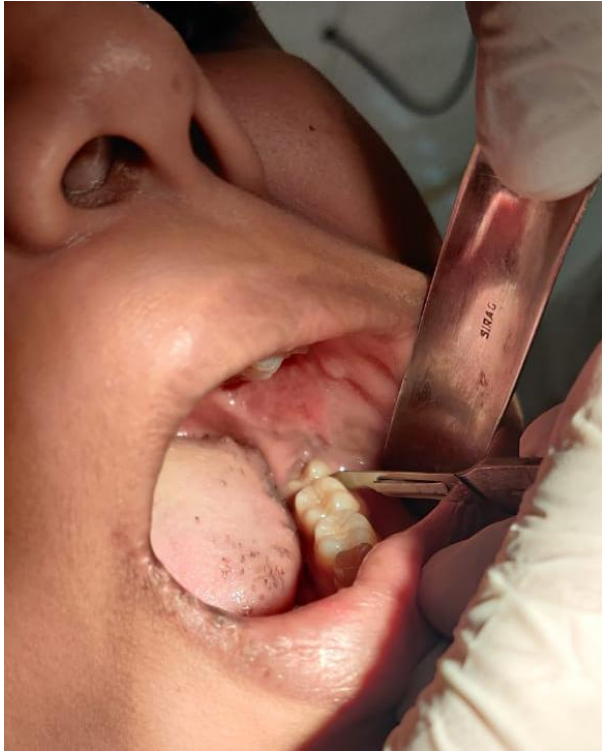

Image 6: Bone guttering

Bone guttering was done around the tooth, using a 703 stainless steel surgical bur mounted on a surgical straight rotatory handpiece.

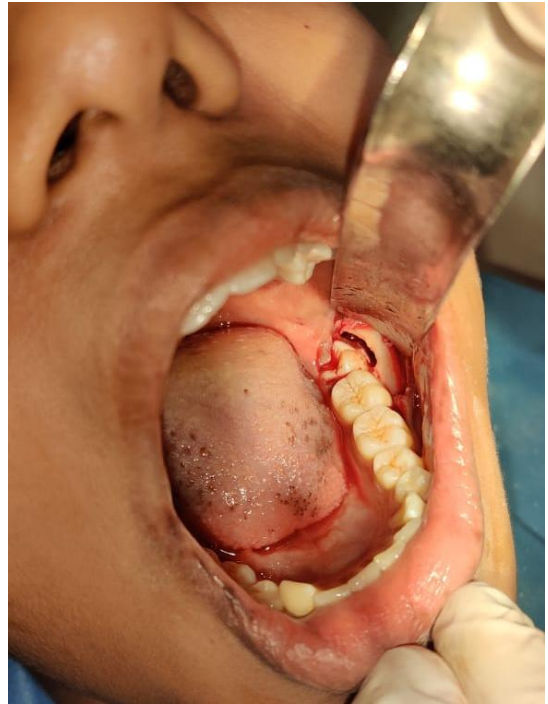
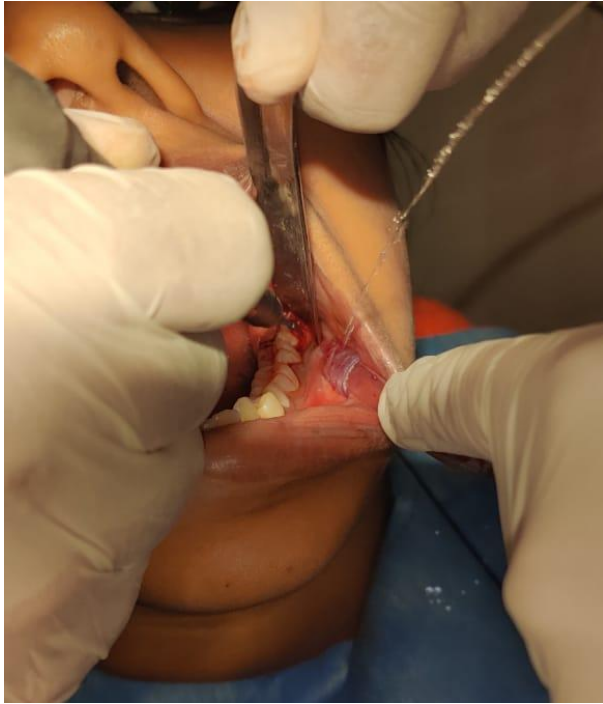

Image 7: Operative phases

The tooth was elevated out of the socket in toto. Copious amounts of saline was used to irrigate the socket. The sharp bony edges were smoothed with a bone file. Follicular lining if any was removed.

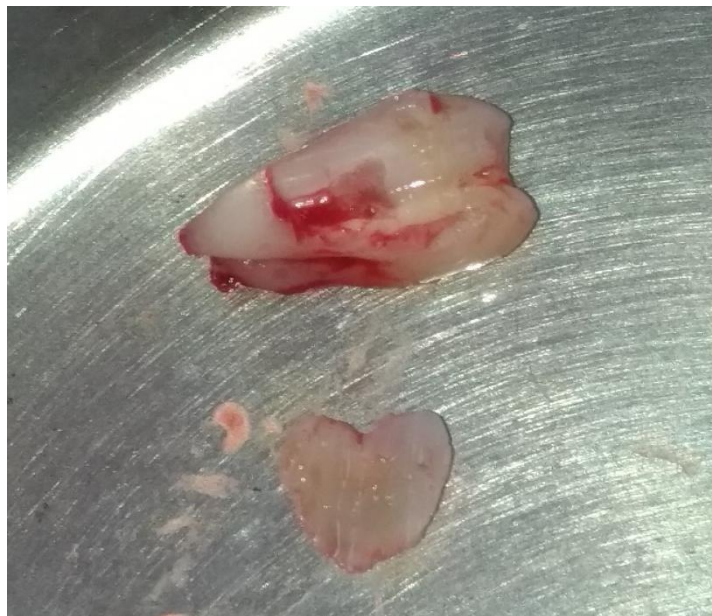

Image 8 sharp bony edges of teeth

Closure was done with a 3.0 braided silk. 5 sutures were used in each patient to achieve a tight closure, 2 interdental sutures mesially, and 3 single interrupted sutures distally. Patient was asked to report after 7 days for review.

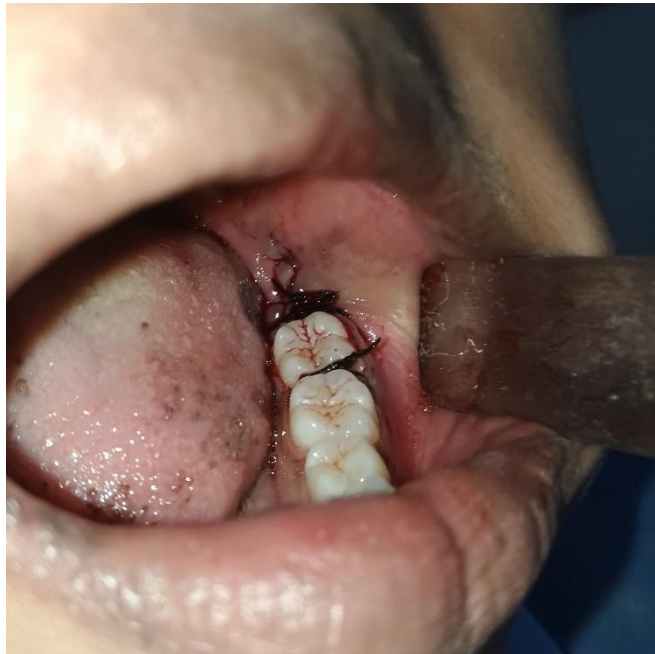

Image 9: Post operative phase

POST-OPERATIVE PHASE:

On the 7th post operative day, mouth opening was recorded. Any other post operative complication was also recorded. Sutures were removed. Patient was then asked to report again 1 month post operatively.

At 1 month post operatively, the probing depth of the 2nd mandibular molar was recorded and patient was prepped to undergo surgical removal of the impacted tooth on the other side using Envelope flap technique.

Post operatively for all the patients, medications were administered for 5 days as per standard protocol. Empirical antibiotic therapy was administered in the form of Tab. Amoxicillin 500 mg + Clavulanic Acid 125 mg and Tab. Metronidazole 400 mg, both thrice per day after food. NSAID was administered in the form of Tab. Aceclofenac 100 mg + Paracetamol 500 mg, thrice per day after food. Anti-Inflammatory Enzyme was administered in the form of Tab. Chymotrypsin + Trypsin 100000 Au thrice per day before food. A combination of Proton Pump Inhibitor and Anti Emetic was also administered in the form of Tab. Pantoprazole 40 mg + Domperidone 30mg.

For both the sides intra operative photos were taken and stored. For all patients proper COVID-19 protocols were followed.

After collection of all data, statistical analysis was done using Microsoft Excel 2016 and Review Manager 5.4.1.

RESULTS

This study was conducted on 20 patients. Both male and female patients were selected. Patients aged 25-40 years with a mean age of 32.9 years were taken. Out of the 20 patients 13 were male and 7 were female.

The raw data was processed in Microsoft Excel 2016 and Review Manager 5.4.1

The study yielded the following results:

POCKET DEPTH POST- OPERATIVELY FOR TRIANGULAR FLAP (mm)	POCKET DEPTH POST- OPERATIVELY FOR ENVELOPE FLAP (mm)
------------------------------------------------------------------------	----------------------------------------------------------------------

4	0
0	0
2	2
4	0
0	0
0	0
8	0
2	2
4	0
4	0
8	0
4	0
0	4
4	0
0	8
0	0
0	0
0	0
2	0
0	4
VARIANCE	VARIANCE
6.852631579	4.421052632

SD= 2.617753155	SD= 2.102629932

TABLE 1

Variance of both sets of data are equal. Thus a 1 tailed T test was done for test of significance.

T-Test for Pocket Depth comparing the two flaps (table 1) gave the following result:

	POCKET DEPTH POST- OPERATIVELY FOR ENVELOPE FLAP (mm)	POCKET DEPTH POST- OPERATIVELY FOR TRIANGULAR FLAP (mm)
Mean	1	2.3
Variance	4.421052632	6.852631579
Observations	20	20
Pearson Correlation	-0.363361125	
Hypothesized Mean Difference	0	
df	19	
t Stat	-1.487600948	
P(T<=t) one-tail	0.076632435	
t Critical one-tail	1.729132812	
P(T<=t) two-tail	0.153264869	
t Critical two-tail	2.093024054	

REDUCTION MOUTH OPENING- OPERATIVELY FOR TRIANGULAR FLAP (mm)	REDUCTION MOUTH OPENING POST- OPERATIVELY FOR ENVELOPE FLAP (mm)
10	0
5	0
0	5
20	5
5	15
15	15
10	5
5	5
0	0
0	0
0	0

5	0
0	0
0	0
0	0
0	0
0	0
0	0
5	0
0	0
VARIANCE	VARIANCE
33.15789474	22.36842105
SD= 5.75828922	SD= 4.729526515

TABLE 2

T-Test for Reduction in mouth opening post-operatively comparing the two flaps (table 2) gave the following result:

	REDUCTION MOUTH OPENING POST- OPERATIVELY FOR ENVELOPE FLAP (mm)	REDUCTION MOUTH OPENING- OPERATIVELY FOR TRIANGULAR FLAP

		(mm)
Mean	2.5	4
Variance	22.36842105	33.15789474
Observations	20	20
Pearson Correlation	0.531456783	
Hypothesized Mean Difference	0	
df	19	
t Stat	-1.301179967	
P(T<=t) one-tail	0.104377745	
t Critical one-tail	1.729132812	
P(T<=t) two-tail	0.208755489	
t Critical two-tail	2.093024054	

Using Review Manager 5.4.1 the following results were obtained:

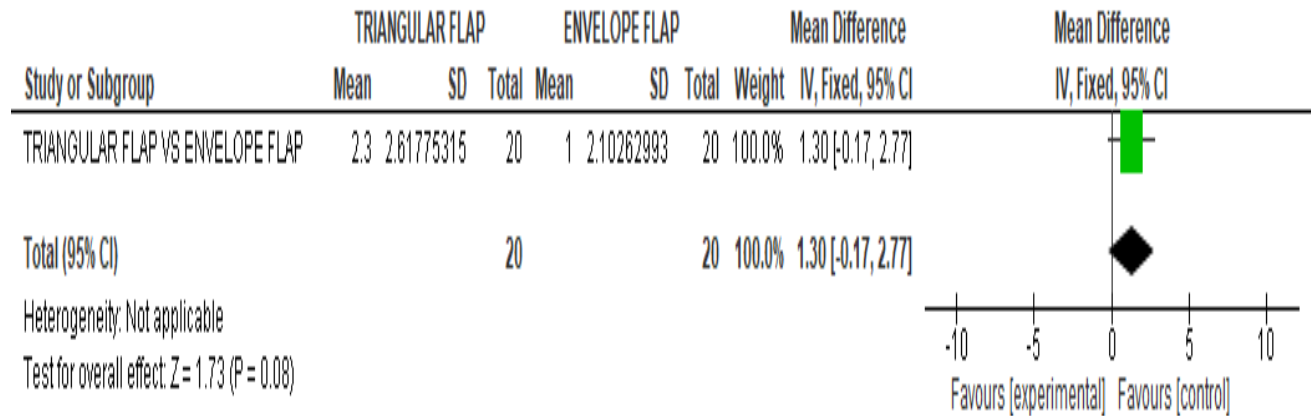


Fig 1. Forest plot comparing post operative pocket depth

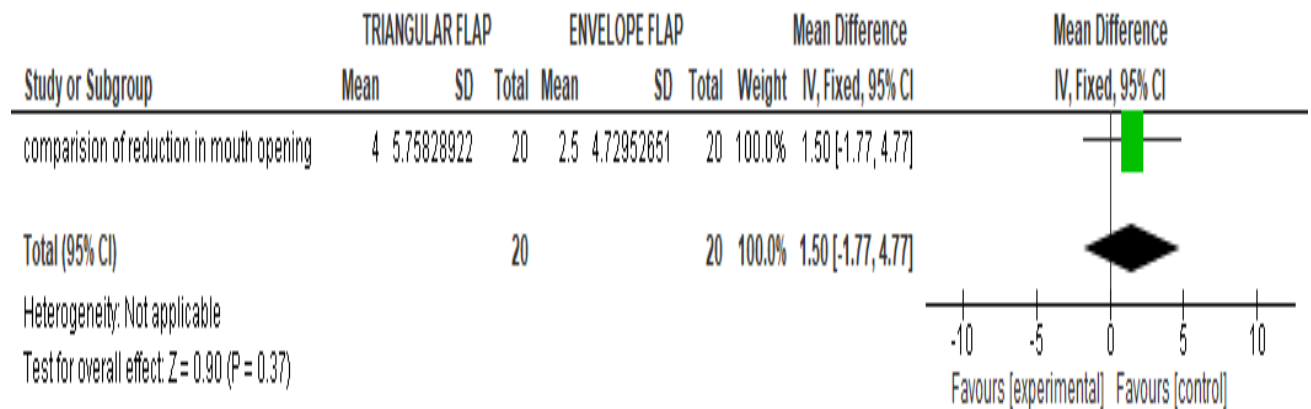


Fig 2. Forest plot comparing post operative reduction in mouth opening

The statistical analysis P value > 0.05, which shows that the difference in post operative healing between the two flaps discussed is statistically insignificant. Thus, statistically both flaps are a viable option and both show similar results, although clinically envelope flap shows better overall results.

DISCUSSION

Coming to the topic at hand, which is about comparison between two intra-oral flap designs for mandibular 3rd molar surgery in controlled diabetes patients, oral

surgical flap is the surgical procedure in which a part of the mucoperiosteal tissue is surgically detached from the underlying bone to gain better visibility and ease of access. The presence of Diabetes Mellitus brings several complications to a surgical procedure pre-operatively, intra-operatively, as well as post-operatively. Pre-operatively, there might be a higher chance of presence of abscess, space infection or even superlative fungal infection such as candidiasis or actinomycosis, which may cause an even greater complication, as seen in a study done in 2018, by Padmanidhi Agarwal, et al, where they presented a case report of palatal Actinomycosis Osteomyelitis due to an impacted maxillary 3rd molar in a patient with Diabetes Mellitus.

For an intra oral flap surgery, common principles which are used are, first, the base of the flap needs to be broader than the free end for adequate blood supply. Second, the incision should be placed at right angles to the underlying bone, while avoiding any important anatomical structures, and it should give adequate visualization. Third, the flap needs to be wider than the probable underlying bone defect and should be delicately handled without causing tension. Fourth, the vertical releasing incision should start from the midpoint of buccal vestibule and stop at mesial or distal to the interdental papilla.

Different flaps have been proposed for various intraoral surgeries, that is, third molar surgery, canine exposure, various periodontal surgery, dental implant preparation, endodontic surgeries, and repair of oroantral communications.

Total of 20 patients were taken for the study. Out of the 20 patients 13 were male and 7 were female. The age range was from 30-40 years. Average age was 32.9 years. So, a total of 40 teeth were taken as the sample pool. Out of the 40 mesio-angular impacted mandibular 3rd molars, 20 were surgically removed using triangular flap and the other 20 were surgically removed using envelope flap. Comparison between the post operative healing on either side was done. Parameters such as pre operative and post operative probing depth, mouth opening, post operative pain and swelling, post operative incidence of infection and dry socket were also tallied and comparison was done between the two flap designs. All patients follow up was done up to 1 month post operatively.

Out of the 20 sides treated with triangular flap, 4 came back with post operative trismus at 1 week post-operatively, and thus restricted mouth opening. Patients

complained of pain and swelling as well. In these patients, mouth opening was restored to normal using Fergusson's Mouth gag and then administration of oral regimen of muscle relaxants and non-steroidal anti-inflammatory drugs for 5 days, supplemented with mouth opening exercises. These patients were asked to report 1 week later for review. At 2 weeks post-operatively, these 4 patients showed satisfactory wound healing and normal mouth opening, so suture removal was done. All the other patients showed normal mouth opening and satisfactory wound healing at 1 week post-operatively. Thus, suture removal was done at 1 week post-operatively. At 1-month post-operative review all patients had excellent healing, normal mouth opening, but 8 of these sides came back with probing depth of more than 5 mm was seen at 1 month post-operatively. These patients were hence advised to undergo periodontal therapy for pocket elimination.

Out of the 20 sides treated with envelope flap, 2 patients came back at 1 week post operatively, with pain and swelling in the ipsilateral submandibular space. Empirical antibiotics and analgesics were administered to these patients for 5 days and were asked to report 1 week later for review. At 2 weeks post-operatively, these two patients showed satisfactory wound healing and no evidence of infection, pain or swelling, thus, suture removal was done. All the other patients showed normal mouth opening and satisfactory wound healing at 1 week post-operatively. Thus, suture removal was done at 1 week post-operatively. Out of the 20 sides treated with envelope flap technique only 3 patients showed probing depth exceeding 5mm in relation to the 2nd mandibular molar at 1 month post-operatively. These patients were asked to undergo periodontal therapy for pocket elimination. All other patients showed excellent wound healing at 1 month post-operatively.

Post-operatively, all the patients did regular testing of blood sugar levels at home to ensure that blood sugar levels didn't exceed normal values.

None of the patients showed evidence of dry socket or increased incidence of post-operative infection, which is in accordance with a study published in 2001 by Takashi Yoshii [59], et al, where they did a study about the post operative healing in 993 patients who underwent surgical removal of mandibular 3rd molar. 85 of those patients had underlying systemic disease, out of which 7 patients had diabetes mellitus, none of whom showed any signs of post-operative infection.

Thus, even though statistically the post-operative difference in healing between the two flaps is insignificant, in overall, envelope flap showed better short term as well as long term post-operative condition.

CONCLUSION

This study has thus shown that although the post-operative difference between the two flaps were statistically insignificant, yet clinically, Envelope flap showed better results. Thus, we need to have more Randomized Control Trials with greater sample size to have a more extensive and definitive result. So finally, we can conclude that the flap design depends on the surgeon's own comfort and it may differ from case to case.

ETHICAL CLEARANCE

Ethical committee clearance was obtained prior to the study. (Ethics Committee Reference No- SBDCH/IEC/12/2019/05).

Consent

As per international standard or university standard, patients' written consent has been collected and preserved by the author(s).

REFERENCES

1. Mavrodi A, Ohanyan A, Kechagias N, Tsekos A, Vahtsevanos K. Influence of two different surgical techniques on the difficulty of impacted lower third molar extraction and their post-operative complications. *Med Oral Patol Oral Cir Bucal*. 2015 Sep 1;20(5):e640-4. doi: 10.4317/medoral.20605. PMID: 26116843; PMCID: PMC4598936.
2. Mahtani A, Santhosh MP. Prevalence of systemic diseases in patients undergoing minor oral surgeries. *Bioinformation*. 2020 Dec 31;16(12):1051-1059. doi: 10.6026/973206300161051. PMID: 34938005; PMCID: PMC8600205.

3. N. H. Luyk, M. Zacharias, S. Wanwimolaruk: Bolus dose with continuous infusion of midazolam as sedation for outpatient surgery. *Int. J. Oral Maxillofac. Surg.* 1992; 21: 172-175
4. Liu, Ji-Yuan et al. "Distal-triangular flap design for impacted mandibular third molars: a randomized controlled trial." *Hua xi kou qiang yi xue za zhi = Huaxi kouqiang yixue zazhi = West China journal of stomatology* vol. 39,5 (2021): 598-604. doi:10.7518/hxkq.2021.05.016
5. All-Atabakhsh A, Rosenberg MB (2012) Ropivacaine: the next dental local anesthetic? *J Mass Dent Soc* 61:14–16
6. McClure JH (1996) Ropivacaine. *Br J Anaesth* 76:300–307
7. Bhargava D, Chakravorty N, Rethish E, Deshpande A. Comparative Analysis of the Anesthetic Efficacy of 0.5 and 0.75 % Ropivacaine for Inferior Alveolar Nerve Block in Surgical Removal of Impacted Mandibular Third Molars. *J Maxillofac Oral Surg.* 2014 Dec;13(4):431-4. doi: 10.1007/s12663-013-0534-3. Epub 2013 May 28. PMID: 26225007; PMCID: PMC4518782.
8. Prasanth T. Management of localized gingival recession by two-stage surgical procedure—Double pedicle flap with CTG and coronally advanced flap: A novel technique. *Journal of Indian Society of Periodontology.* 2009;13(1): 44-47. DOI: 10.4103/0972-124X.51895
9. Praveen G, Rajesh P, Neelakandan R S, Nandagopal C M Comparison of morbidity following the removal of mandibular third molar by lingual split, surgical bur and simplified split bone technique. *Indian Journal of Dental Research*
10. Mohajerani H, Esmaeelinejad M, Jafari M, Amini E, Sharabiany SP. Comparison of Envelope and Modified Triangular Flaps on Incidence of Dry Socket after Surgical Removal of Impacted Mandibular Third Molars: A Double-blind, Split-mouth Study. *J Contemp Dent Pract.* 2018 Jul 1;19(7):836-841. PMID: 30066688.
11. Hashemipour MA, Tahmasbi-Arashlow M, Fahimi-Hanzaei F. Incidence of impacted mandibular and maxillary third molars: a radiographic study in a

Southeast Iran population. *Med Oral Patol Oral Cir Bucal*. 2013 Jan 1;18(1):e140-5. doi: 10.4317/medoral.18028. PMID: 23229243; PMCID: PMC3548634.

12. John Mamoun. Use of elevator instruments when luxating and extracting teeth in dentistry: clinical techniques. *J Korean Assoc Oral Maxillofac Surg*

13. M. Salonen, H. Forssell, O. Lehmijoki, T. Kaila and M. Scheinin: A comparison of two sedative premedications for minor oral surgery under local anaesthesia. *Int. J. Oral Maxillofac. Surg.* 1989; 18: 202-205.

14. MAJOR M . A S H ., EMMETT R. COSTICH, AND JAMES R. HAYWARD. A Study of Periodontal Hazards of Third Molars. *THE JOURNAL OF PERIODONTOLOGY*

15. Faculty of Dental Surgery The Royal College of Surgeons of England 35-43 Lincoln's Inn Fields London. *THE MANAGEMENT OF PATIENTS WITH THIRD MOLAR (syn: WISDOM) TEETH. CURRENT CLINICAL PRACTICE AND PARAMETERS OF CARE*

16. Dragovic M, Pejovic M, Stepic J, Colic S, Dozic B, Dragovic S, Lazarevic M, Nikolic N, Milasin J, Milicic B. Comparison of four different suture materials in respect to oral wound healing, microbial colonization, tissue reaction and clinical features-randomized clinical study. *Clin Oral Investig.* 2020 Apr;24(4):1527-1541. doi: 10.1007/s00784-019-03034-4. Epub 2019 Jul 24. PMID: 31342245.

17. Mohamed A. Shaddad, Anas A. Ahmed, Amal H. Abuaffan, Yousif O. Yousif. Prevalence and Pattern of Impacted Third Molar in a Sample of Sudanese Population. *Indian Journal of Dental Education.*

18. N. It. Luyk, M. Zacharias, S. Wanwimolaruk: Bolus dose with continuous infusion of midazolam as sedation for outpatient surgery. *Int. J. Oral Maxillofac. Surg.* 1992; 21: 172-175

19. Motamedi MH. A technique to manage gingival complications of third molar surgery. *Oral Surg Oral Med Oral Pathol Oral Radiol Endod* 2000;90:140-3.

20. Berwick WA. Alternative method of flap reflection. *Br Dent J* 1966;121:295-6.

21. Magnus WW, Castner DV, Hiatt WR. An alternative method of flap reflection of mandibular third molars. *Mil Med* 1972;137:232-3.
22. Woolf RH, Malmquist JP, Wright WH. Third molar extractions: periodontal implications of two flap designs. *Gen Dent* 1978;26:52-6
23. PHILIP S. GIBBS, ALVIN M. LOSASSO, S. S. MOORTHY, CHARLES E. HUTTON. The Anesthetic and Perioperative Management of a Patient with Documented Hereditary Angioneurotic Edema. *ANESTHESIA AND ANALGESIA*. Current Researches Vol, 56, No. 4, JULY-AUGUST 1977,
24. R. JEFFREY STEPHENS, GEORGE R. AND DENNIS W. FOREMAN, Periodontal Evaluation of Two Mucoperiosteal Flaps Used in Removing Impacted Mandibular Third Molars. *J Oral Maxillofac Surg* 41:719-724, 1993
25. Ranjeet Bodh, Anshul Jain. The flap design of third molar surgery: An overview. *International Journal of Medical and Health Research*. Volume 1; Issue 3; October 2015; Page No. 32-35
26. Thoma KH. The management of malposed inferior third molars. *J Dent Res* 1932; 12:175-208.
27. Kruger GO. Management of impactions. *Dent Clin North Am* 1959; 707-722. Berwick WA. Alternative method of flap reflection. *Br Dent J*. 1966; 20; 121(6):295-6.
28. 22. Henry CB. Excision of developing mandibular third molar by lateral trepanation. *Brit Dental J*. 1969; 127:111-118.
29. 23. Ward TG. Split bone technique for removal lower third molar. *Brit Dent J*. 1956; 101:297-301.
30. 24. Killy HC, Kay LW. The impacted wisdom tooth. Published E & S Livingston Ltd. London, 1979.
31. 25. Tavtigian R. The height of facial radicular alveolar crest following apically positioned flap operations. *J Periodontol*. 1970; 41:412-8.
32. 26. Motamedi MH. A technique to manage gingival complications of third molar surgery. *Oral Surg Oral Med Oral Pathol Oral Radiol Endod* 2000; 90:140-3.

33. Dhanrajani PJ, Jonaidel O. Trismus: aetiology, differential diagnosis and treatment. *Dent Update* 2002; 29:88-94.
34. Wood DL, Hoag PM, Donnenfeld W. Alveolar crest reduction following full and partial thickness flaps. *J Periodontol.* 1972; 43:141.
35. Yaffe A, Fine N, Binderman I. Regional accelerated phenomenon in the mandible following mucoperiosteal flap surgery. *J Periodontol.* 1994; 65:79.
36. Obiechina AE: Update in the technique of third molar surgery. *Annals of Ibadan postgraduate medicine* 2003;1:40-44.
37. Kirk DG, Tong DC, Love RM. Influence of two different flap design on incidence of pain, swelling, trismus, and alveolar osteitis in the week following third molar surgery. *Oral surg Oral med Oral pathol Oral radiol Endod,* 2007; 104:e1-e6.
38. Dolanmaz D, Candirli Celal. Effect of two flap designs on postoperative pain and swelling after impacted third molar surgery. *Oral surg Oral med Oral pathol Oral radiol,*2012
39. Ferish SE, Bouloux GF. General technique of third molar removal. *Oral maxillofacial surg clin nAm,* 2007; 19:23-43
40. Monaco G, Dopriile G, Tavernese L.Mandibular third molar removal in young patients: An evaluation of 2 different flap designs. *J Oral maxillofac surg,* 2009; 67:15-21.
41. Roode GJ, Butow K. An alternative surgical flap design for impacted third molars: A comparison of two different surgical techniques. *SAJD,* 2010; 65:246-251.
42. Naaj IAE, Braun R. Surgical approach to impacted mandibular third molars- Operative classification. *J oral maxillofac surg.* 2010; 68:628-633.
43. Karaka I, Simsek S, Uger D. Review of flap design influence on the health of the periodontium after mandibular third molar surgery. *Oral surg Oral med Oral pathol Oral radiol,* 2007; 104:18-23.

44. Baqain ZH, Shaffi AA, Hamdan AA. Flap design and mandibular third molar surgery: a split mouth randomized clinical study. *International journal of oral and maxillofacial surgery*, 2012; 41:1020-1024.
45. Sandhu A, Sandhu S. Comparison of two different flap designs in the surgical removal of bilateral impacted mandibular third molars. *International journal of oral and maxillofacial surgery*. 2010; 39:1091-1096.
46. Stephens R, George R, Dennis W. Periodontal evaluation of two mucoperiodontal flaps used in removing impacted mandibular third molars. *International journal of oral and maxillofacial surgery*. 1986; 41:719-724.
47. Jakse Nobert, Bankaoglu V, Wimmor G. Primary wound healing after lower third molar surgery: Evaluation of 2 different flap designs. *Oral surg Oral med Oral pathol Oral radiol Endod*, 2002; 93:7-12.
48. Alling CC, Catone GY. Management of impacted teeth. *J oral maxillofac surg*, 1993; 51:3-6.
49. Rafetto LK, Synan W. Surgical management of third molars. *Atlas Oral Maxillofacial Surg clin N Am*, 2012; 20:197-223.
50. Nageshwar. Comma incision for impacted mandibular third molars. *J oral maxillofac surg*. 2002; 60:1506-1509.
51. Obimakinde O.S: Impacted mandibular third molar surgery; an overview. *Dentoscope*, 2009;16 Szmyd L. Impacted teeth. *Dent Clin North Am* 1971; 15:299-318.
52. Suarez-Cunqueiro MM, Gutwald R, Reichman J, Otero- Cepeda XL, Schmezeisen R. Marginal vs paramarginal flap in impacted third molar surgery: a prospective study. *Oral Surg Oral Med Oral Pathol Oral Radiol Endod* 2003; 95:403-8.
53. SIGURD P. RAMFJORD, ROBERT NISSLE: The Modified Widman Flap. *J. Periodontol*. August, 1974.
54. S. M. Al-Amery, W. C. Ngeow, P. Nambiar, M. Naidu: A pilot study on the effects of direct contact of two different surgical burs on the cadaveric lingual nerve. *Int. J. Oral Maxillofac. Surg*. 2018; 47: 1153–1160

55. Tejrav P Kale, Vikram S Pandit, Shankargouda Patil, Vivek Pawar⁴, Nisha Shetty. Lingual Guttering Technique for Removal of Impacted Mandibular Third Molars. *Journal of International Oral Health* 2014; 6(4):9-11
56. Tushar Dubey, Manpreet Singh, Ashish Sharma, Shyamalendu Laskar, Arpit Vashistha. Combination of Articaine and Ketamine V/S Articaine Alone After Surgical Extraction of Impacted Third Molars. *Annals of Maxillofacial Surgery* 2020
57. W. Howard Davis, David A. Hochwald, Ronald M. Kaminishi, Bell'ower, Calij: Modified distolingual splitting technique for removal of impacted mandibular third molars: Technique. *Oral Surg.* July, 1983
58. Qi W, Li JN, Zhao JR, Xing HX, Pan J. [Effect of triangular flap design and healing procedure on the sequelae after extraction of impacted lower third molars]. *Beijing Da Xue Xue Bao Yi Xue Ban.* 2019 Oct 18;51(5):949-953. Chinese. doi: 10.19723/j.issn.1671-167X.2019.05.026. PMID: 31624404; PMCID: PMC7433507.
59. Takashi Yoshii, Yoshihiko Hamamoto Shigetada Muraoka, Atsushi Kohjitani Osamu Teranobu, Shungo Furudoi, Takahide Komori: Incidence of deep fascial space infection after surgical removal of the mandibular third molars: *J Infect Chemother* (2001) 7:55–57
60. Norbert Jakse, Gernot Wimmer, Antranik Eskici, Christof Pertl: Primary wound healing after lower third molar surgery: Evaluation of 2 different flap designs: *Oral Surg Oral Med Oral Pathol Oral Radiol Endod* 2002;93:7-12
61. Praveen G, Rajesh P, Neelakandan R S, Nandagopal C M. Comparison of morbidity following the removal of mandibular third molar by lingual split, surgical bur and simplified split bone technique. *Indian J Dent Res [serialonline]* 2007 [cited 2022 Jan 21];18:15-8
62. Bhargava D, Chakravorty N, Rethish E, Deshpande A. Comparative Analysis of the Anesthetic Efficacy of 0.5 and 0.75 % Ropivacaine for Inferior Alveolar Nerve Block in Surgical Removal of Impacted Mandibular Third Molars. *J Maxillofac Oral Surg.* 2014 Dec;13(4):431-4. doi: 10.1007/s12663-013-0534-3. Epub 2013 May 28. PMID: 26225007; PMCID: PMC4518782.

63. Mohajerani H, Esmaeelinejad M, Jafari M, Amini E, Sharabiany SP. Comparison of Envelope and Modified Triangular Flaps on Incidence of Dry Socket after Surgical Removal of Impacted Mandibular Third Molars: A Double-blind, Split-mouth Study. *J Contemp Dent Pract.* 2018 Jul 1;19(7):836-841. PMID: 30066688.
64. Gholinejad Ghadi N, et al. Fulminant mucormycosis of maxillary sinuses after dental extraction inpatients with uncontrolled diabetic: Two case reports. *Journal De Mycologie Me´dicale* (2018)
65. George K. B. Sandor, Robert W. T. Myall: Patients with long Q-T syndrome: A caveat for the oral surgeon; *Oral Surg.* October, 1983
66. Liu JY, Liu C, Pan J, Qu T, Hua CG. Distal-triangular flap design for impacted mandibular third molars: a randomized controlled trial. *Hua Xi Kou Qiang Yi Xue Za Zhi.* 2021 Oct 1;39(5):598-604. English, Chinese. doi: 10.7518/hxkq.2021.05.016. PMID: 34636210; PMCID: PMC8548220.
67. Felipe Rodriguez F. Extracción de los terceros molares bajo anestesia general [Extraction of the 3rd molars under general anesthesia]. *Rev Cubana Estomatol.* 1983 May-Aug;20(2):115-9. Spanish. PMID: 6587473.