

Multiple Hydatidosis with Rare Cardiac Localization

Case Study

ABSTRACT

The present study highlights the Multiple pulmonary hydatidosis with cardiovascular localization. Cardiovascular localization remains exceptional with an estimated frequency between 0.5 and 2% of all hydatid localizations. Multislice CT with cardiac synchronization, as illustrated by our observation, allows an accurate morphological and extension assessment thanks to its very good spatial resolution and the possibilities of multiplanar reconstructions. Medical antiparasitic treatment is the treatment of choice for inoperable patients due to too many hydatid cysts, or debilitated terrain, or as a complementary treatment to surgery when there is a risk of dissemination.

Keywords: Cardiovascular localization; pulmonary hydatid cyst; hemagglutination; hydatid cyst.

1. INTRODUCTION

Cardiovascular localization remains exceptional with an estimated frequency between 0.5 and 2% of all hydatid localizations [1]. The clinical, radiological and even electrocardiographic signs of the latter lack specificity. The diagnosis is therefore difficult. We report two observations.

2. PATIENTS AND OBSERVATION

Observation 1: Patient aged 21 years, operated 5 years before for a pulmonary hydatid cyst. He presented, 7 months before his hospitalization, hemoptysis of small abundance evolving in a context of fever and alteration of the general state. On admission, the clinical examination revealed a fever of 39°C and snoring in the right hemothorax. The cardiovascular examination revealed no murmurs, no signs of right heart failure, and no signs of PH. The rest of the somatic examination was unremarkable. Chest radiography showed multiple pulmonary opacities with a "balloon-like" appearance. Hydatid serology was strongly positive: indirect hemagglutination: 1/5 120 (threshold: 1/320), Elisa: 0.481 IU/ml (threshold: 0.225). The sedimentation rate was accelerated to 50 mm at the first hour. The blood eosinophil count was elevated to 1700 elements mm³. Chest computed tomography (CT) showed bilateral pulmonary water-dense cystic formations of variable diameter, the largest of which (5/6 cm) was located in the ventral segment of the right upper lobe (Fig. 1), measuring 4 cm long axis in

the right atrium (Fig. 2), and several other cystic formations in both pulmonary arteries, the largest of which measured 2 cm and was located in the right pulmonary artery (Fig. 3). Transthoracic cardiac echocardiography (TTE) showed non-calcified multivesicular cystic images in the right ear and in the trunk of the pulmonary artery, without pulmonary hypertension, valvular or pericardial involvement. Transesophageal echocardiography (TEE) localized the multivesicular hydatid cyst on the lower part of the interatrial septum, with absence of cystic formations at the level of the pulmonary artery (Fig. 4).

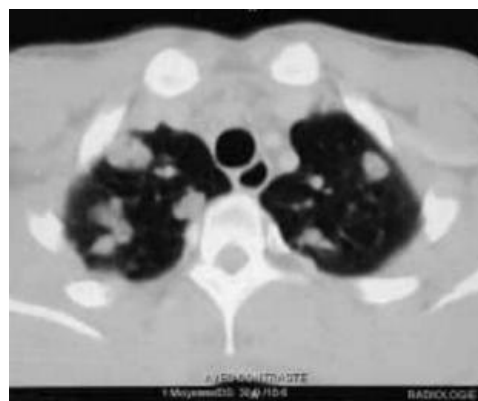


Fig. 1. Chest CT scan. Multiple nodular opacities and bilateral cystic formations

Bronchoscopy showed no bleeding or hydatid membranes and the search for scolex in the bronchial aspiration fluid was negative.

Abdominal ultrasound and brain CT scan did not reveal any other location of the hydatid cyst. The diagnosis of multiple thoracic hydatidosis with pulmonary, cardiac and pulmonary arterial localizations was retained. A medical treatment based on albendazole was started, at a dose of 800 mg per day in 2 doses. Surgical removal of the cardiac and pulmonary arterial cysts, under extracorporeal circulation, was indicated but unfortunately, the patient died following a sudden hemoptysis.

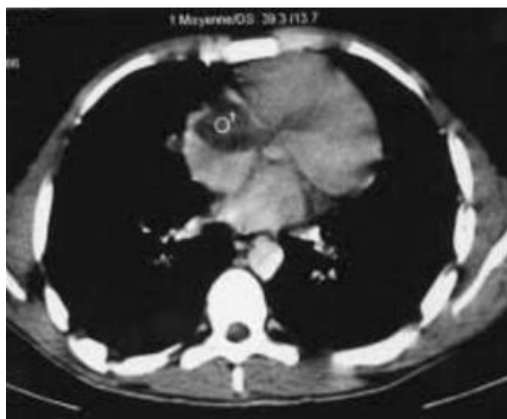

Fig. 2. Thoracic CT scan. Cystic formation of 4 cm in diameter in the right atrium

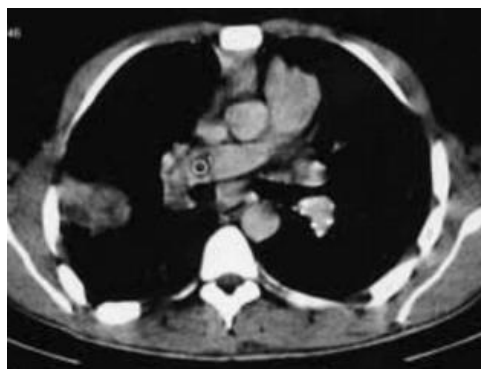

Fig. 3. Thoracic CT scan. Cystic formation of 2 cm in diameter in the right pulmonary artery

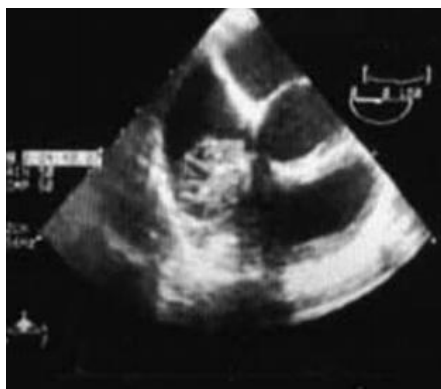

Fig. 4. Transesophageal echocardiography. Multivesicular hydatid cyst on the lower part of the interatrial septum

Observation 2: 19-year-old patient, without toxic habits, rural origin, farmer since the age of 14 years, having dogs in the surroundings. He reported for 1 year a dyspnea of effort associated with thoracic pains with type of burning, clinical picture complicated 3 months before without admission by the installation of episodes of hemoptysis of small abundance, the whole evolving in a context of the deterioration of the general state and feverish feelings. The examination of the chest, found bilateral sibilant rales. The cardiovascular examination and the rest of the somatic examination were quite normal. In front of this picture, a radiography and a thoracic CT scan were requested (Figs. 5,6) showing a balloon-like image made of multiple pulmonary nodules, of liquid density, some of which were the seat of air bubbles with two formations having the same characteristics, the first one in contact with the right atrium and a second one at the level of the oval cystic cardiophrenic recess with calcified wall (Fig. 7). Hydatid serology was strongly positive at 1/5120. TTE echocardiography (Fig. 8, 9) showed a heterogeneous rounded cystic formation in the right atrium measuring 40 mm and a second formation in contact with the posterior wall of the left ventricle measuring 33 mm. Cardiac MRI (Fig. 10) confirmed the presence of a well-limited cystic formation in the right atrium, located in an area of hyposignal, measuring 40 x 22.5 mm, which came into intimate contact with the tricuspid valve, and two other pericardial cystic formations opposite the left ventricle, the largest measuring 33.5 x 27 mm. Abdominal ultrasound did not show any hepatic involvement and brain CT was normal.

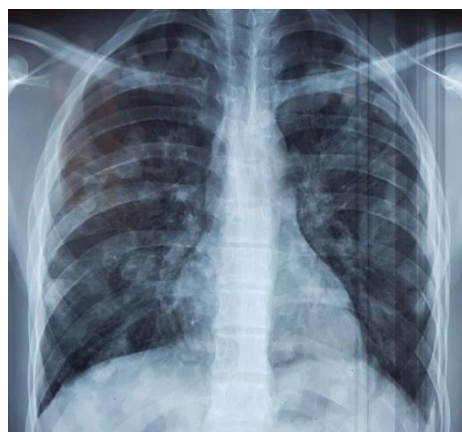

Fig. 5. Chest radiograph. Bilateral nodular opacities showing balloon release

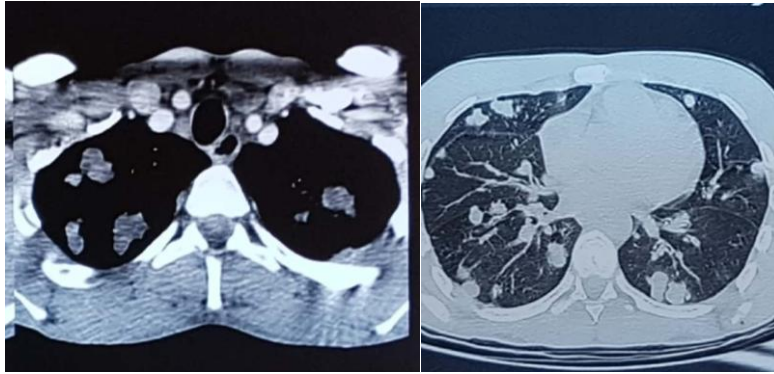


Fig. 6. Chest CT scan. Multiple bilateral cystic formations

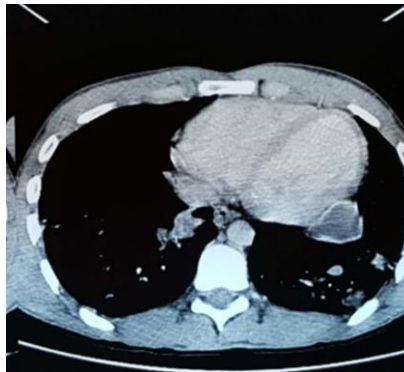

Fig. 7. Thoracic CT scan. Cystic formation at the level of the cardiophrenic recess of 2 cm

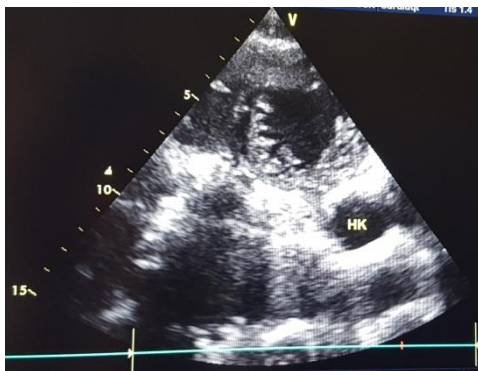
Fig. 9. TTE cardiac ultrasound: Cystic formation in contact with the posterior wall of the left ventricle

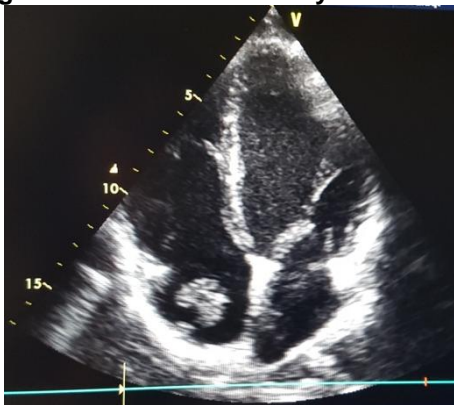

Fig. 8. TTE cardiac ultrasound: Cystic formation in the right atrium

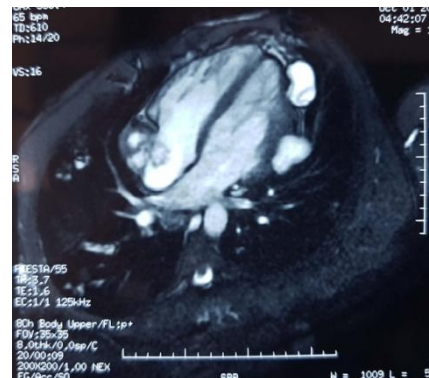

Fig. 10. T2 cardiac MRI: Cystic formation in the right atrium in close contact with the tricuspid valve and two other pericardial cystic formations opposite the left ventricle



In total, there were three cardiac hydatid cysts, one in the right atrium and two in the pericardium opposite the left ventricle, associated with multiple pulmonary hydatidosis. The patient was put on an antiparasitic treatment with albendazole, at a rate of 15mg/kg per day in 28-day courses with a 14-day interruption between the two courses. Cardiac surgery under

extracorporeal circulation was scheduled but the patient was lost to follow-up.

3. DISCUSSION

Cardio-pericardial hydatidosis is rare even in endemic countries, it represents 0.5 to 2% of all hydatid localizations [2] and originates essentially from the coronary circulation, after crossing the hepatic and pulmonary filter [3]. It is characterized by the severity of its spontaneous evolution and the frequency of its complications [4], mainly rupture in the cardiac cavities with systemic or pulmonary dissemination or rupture in the pericardium leading to pericardial tamponade. The heart itself is affected by systemic or pulmonary circulation or by extension from neighboring organs [5]. Cardiac KH is preferentially located in the LV (60%), interventricular septum (10-20%), right ventricle (5-10%), atria (5-8%) and pericardium (4-10%) [6,7,8,9]. It is subepicardial in the LV in 75% of cases explaining the possibility of intrapericardial rupture [10]. The pericardial cyst is secondary, most often to the rupture of a hydatid cyst of the LV. In 20 to 40% of cases, heart KH is associated with other visceral localizations [11,12].

Clinical symptomatology is highly variable, and may be asymptomatic (60%) [13] or revealed by chest pain [14,15]. Chest pain is probably related to functional myocardial ischemia secondary to extrinsic compression of the coronary arteries by KH and in this case it will be associated with ECG abnormalities. Its polymorphism and misleading presentation responsible for the diagnostic delay [11,12].

The diagnosis of KH of the heart is based mainly on imaging: ultrasound, thoracic CT and cardiac MRI. The standard chest X-ray may be normal (20%) in case of small KH [2,13], septal or left atrial location or ruptured cyst in the cavities. It may show either a bulge of the left inferior arch (50%), or a mass with calcified rim (our observation) or fine calcifications in projection of the cardiac shadow, or cardiomegaly in 30% of cases [16].

Multislice CT with cardiac synchronization, as illustrated by our observation, allows an accurate morphological and extension assessment thanks to its very good spatial resolution and the possibilities of multiplanar reconstructions. Multislice volumetric CT allows, in the same session and in a very short time, a very precise local-regional and especially mediastinal morphological assessment [17], a study of the

relations of the cyst with the cardiac cavities and with the coronary vessels in the different planes of space, and an assessment of the diffusion of the disease by a thoraco-abdomino-pelvic acquisition [18]. In addition, CT allows a better counting in case of multiple hydatidosis.

Transthoracic echocardiography allows an accurate anatomical and topographical diagnosis and demonstrates the fluid nature of the cysts [19,20].

MRI with cardiac synchronization is more precise in the topographic analysis. It determines the precise relationship of the cyst with the cardiac structures and the surrounding tissues. It specifies the nature of the internal and external constituents of the cyst as well as the extension of the hydatidosis intra- and extra-thoracic [21]. It sometimes shows a multivesicular aspect of the cyst which is an almost pathognomonic element of hydatidosis [7,15]. It allows a better characterization of aged KH whose content appears in hyposignal or isosignal T1, hypersignal T2 heterogeneous with respect to the myocardial muscle [18] while remaining unchanged after injection of gadolinium.

Positive hydatid serology reinforces the diagnosis of hydatidosis [1]. This is positive in 50 to 80% of cases. However, in several cases of hydatidosis, the serology remains negative. It is recommended to combine two serology techniques: one qualitative and one quantitative and to look for seroconversion after two to three weeks.

The treatment of choice for cardiovascular cysts is surgical. It consists of excision of the cysts to avoid complications that can be fatal in case of rupture, even in asymptomatic patients [18,21]. Medical antiparasitic treatment is the treatment of choice for inoperable patients due to too many hydatid cysts, or debilitated terrain, or as a complementary treatment to surgery when there is a risk of dissemination. The most commonly used product is Albendazole® at a dose of 10 to 15 mg/kg per day in courses of one month at 15-day intervals for six months [18].

The spontaneous evolution of cardiac hydatid cysts is unpredictable; they may calcify or rupture at any time, exposing patients to formidable complications. Among these complications, migration to the pulmonary arteries and peripheral pulmonary embolization are frequent (70% of cases). The cardiac hydatid cyst may also rupture in the myocardium, leading to secondary local echinococcosis, or in the

pericardium, resulting in acute pericarditis or even tamponade, or in the right or left heart chambers, either by direct rupture or via a foramen ovale. The evolution can lead to the death of the patient or to secondary dissemination with cerebral or renal localization. [22].

4. CONCLUSION

Multiple thoracic hydatidosis with pulmonary, cardiac and pulmonary arterial involvement is rare but serious, putting at risk the vital prognosis. It poses a problem of therapeutic management, hence the interest in preventing disseminated forms by early diagnosis and management of cardiac localizations.

Take Home:

- Hydatid cyst remains a public health problem.
- Cardiac localization may be asymptomatic.
- In the case of multiple pulmonary hydatidosis, it is systematic to look for an associated cardiac location and in this case Cardiac ultrasound and MRI allow a positive diagnosis.

CONSENT

As per international standard or university standard, patients' written consent has been collected and preserved by the author(s).

ETHICAL APPROVAL

It is not applicable.

COMPETING INTERESTS

Authors have declared that no competing interests exist.

REFERENCES

1. Mzabi R, Dziri C. Extrahepatic echinococcosis: Diagnosis and treatment. *nRev Prat.* 1990;40:220—4
2. Ben Khalfallah A. Contribution of transesophageal echocardiography in the diagnosis of hydatid cyst of the heart: About a case. *Maghreb Med.* 1996;305
3. El Kouby A, Vaillant A, Comet B, Malmejac C, Houel J. Cardiac hydatidosis. Review of recent literature. About 15 cases. *Ann Chir Thorac cardiovascular.* 1990;44(8):603–10.
4. Ghrairi H, Khouadja MA, Abouda M, Ammar J, Hantous S, Kilani T, et al. Hydatid cyst of the heart and vessels, 4 observations. *Med Press.* 2005;34(2–C1):101–4.
5. Ozer, et al. Hydatid cyst of the heart as a rare cause of embolization: Report of 5 cases and review of published reports. *J Am Soc Echocardiogr.* 2001;14:299–302.
6. Kaplan M, et al. Cardiac hydatid cysts with intracavity expansion. *Ann Thorac Surg.* 2001;71:1587–90.
7. El Majhad A, Lachhab A, Charradi R, Srairi J, Srairi N, Doghmi N, et al. Contribution of magnetic resonance imaging (MRI) in the diagnosis of cardiac hydatid cyst. *East Mediterranean Heart J.* 2011;17(12):996–1000.
8. Challaoui M, Bouhouch R, Akjouj M, Chat L, Alami D. Pericardial hydatidosis: about 3 cases. *J Radiol.* 2003;84:329–31.
9. Elhattaoui M, Charei N, Bennis A, Tahiri A, Chraïbi N. Hydatid cyst of the heart. About 10 cases. *Arch Evol Heart.* 2006;99:19–25.
10. Sabah I, Yacin F, Okay T. Rupture of presumed hydatid cyst of the interventricular septum diagnosed by transesophageal echocardiography. *Heart.* 1998;79:420–1.
11. El Majhad A, Lachhab A, Charradi R, Srairi J, Srairi N, Doghmi N, et al. Contribution of magnetic resonance imaging (MRI) in the diagnosis of cardiac hydatid cyst. *East Mediterranean Heart J.* 2011;17(12):996–1000.
12. Gormus N, et al. The clinical and surgical features of right-sided intracardiac masses due to echinococcosis. *Heart Vessels.* 2004;19:121–4.
13. El Kouby A, Vaillant A, Comet B, Malmejac C, Houel J. Cardiac hydatidosis. Review of recent literature. About 15 cases. *Ann Chir Thorac cardiovascular.* 1990;44(8):603–10.
14. Thameur H, et al. Cardio-pericardial hydatid cysts. *World J Surg.* 2001;25:58–67.
15. Ben Hamda K, Maatouk F, Ben Farhat M. Eighteen year experience with echinococcosis of the heart: clinical and echocardiographic features in 14 patients. *Int J Cardiol.* 2003;91:145–51.
16. Rekik S, Krichene S, Sahnoun M, Trabelsi I. Unusual cause of syncope in a 17-year-old young women: left ventricular hydatid cyst. *Int J Cardiol.* 2008;77:12–4.

17. Baque J, Huart V, Pierrot JM. Hydatid cyst of the interventricular septum of the heart: appearance on multibarett CT and MRI. *J Radiol.* 2003;84:614–6.
18. Kotoulas GK, et al. Evaluation of hydatid disease of the heart with magnetic resonance imaging. *Cardiovascular Interv Radiol.* 1996;19:187–9.
19. Hernigou A., Plainfosse M.C., Merrans S.L., et al. Role of ultrasound in the diagnosis of five hydatid cysts of the heart *Ann Radiol.* 1983; 26: 648-654
20. Orhane G, Ozay B, Tartan Z, et al. Cardiac hydatid cyst surgery, thirty-nine years of experience. *Ann Cardiol Angeiol.* 2008;57:58-61
21. Elkarimi S, et al. Tamponade revealing an intrapericardial hydatid cyst - a case. *Ann Cardiol angeiol (paris)* 2014 [PubMed] [Google Scholar]
22. Boujnan MR, Langar J, Rokbani L, Kchir MM, Charrad A. Hydatid cyst of the heart. Diagnostic characteristics and course. *La Tunisie Medicale.* 1990 Mar 1;68(3):221-3.