

Original Research Article

INCIDENCE OF DIFFICULT INTUBATION IN TMJ ANKYLOSIS PATIENTS IN UNIVERSITY SETTING.

ABSTRACT :

INTRODUCTION : A fusion of the mandibular condyle with the base of the skull causes ankylosis of the temporomandibular joint (TMJ), which results in a lack of joint movement. The anesthesiologist is concerned about prolonged temporomandibular joint ankylosis because of the restricted airway, which makes intubation difficult. Despite the fact that TMJ ankylosis is a well-known risk factor for difficult airway management, the strategies used are based on the anesthesiologists' skill. It's never easy intubating a patient with temporomandibular joint ankylosis. The purpose of this study was to see how common problematic intubation was in TMJ ankylosis patients.

AIM OF THE STUDY: The aim of the present study was to evaluate the incidence of difficult intubation in TMJ ankylosis patients.

MATERIALS AND METHODS: Among the overall data of patients attending Saveetha Dental College, a retrospective analysis of all the cases (patients who underwent TMJ ankylosis surgery) was extracted. Excel spreadsheets were used to enter the data. SPSS software version 19 was used to analyse the data collected. The data were statistically evaluated using the Chi square test.

RESULTS: In this study, it was discovered that the incidence of difficult intubation in TMJ ankylosis surgery was higher in the age group of 5-18 years than in the other age groups. Intubation in children is tough. The chi square test resulted in statistically significant findings ($p < 0.005$).

CONCLUSION: Nasal intubation and fiberoptic intubation were the most common modes of intubation used in TMJ ankylosis surgery, according to the results of this small sample retrospective analysis. The difficulty of intubation was increased in the paediatric age group (5-18 years).

KEYWORDS: Difficult intubation, fiberoptic intubation, tracheostomy, nasal intubation, innovative technique

INTRODUCTION:

Ankylosis of the temporomandibular joint (TMJ) causes a partial or complete inability to open the mouth. TMJ ankylosis is still very common in India. It can be seen in children as young as 2 years old and as old as 60 years old. (1) TMJ ankylosis is caused by trauma or infection. The resulting sequelae include facial asymmetry, malocclusion, anaemia, and starvation. Increased airway blockage is also a result. (2) Airway blockage is caused by structural encroachment on the oropharyngeal and hypopharyngeal lumens, low intrapharyngeal pressure, and oropharyngeal muscle hypotonicity. All of these anatomical abnormalities make ventilation, intubation, and extubation problematic. (3) Surgical treatment is always used. The operations performed include condylectomy, gap arthroplasty, interposition arthroplasty, and artificial joint replacement. (4) In order to avoid complications associated with oral intubation, nasal intubation is generally used during maxillofacial surgery to ensure airway patency. (4,5) In such individuals, a deformed airway is common, and airway control is usually maintained through scheduled awake fiberoptic intubation. (6) Although awake fiberoptic intubation is the procedure of choice in complicated airway procedures, it requires expertise and experience to be deemed the safest method. (7)(8) Another option for maintaining airway patency is a tracheostomy. (9) On the other hand, tracheotomy creates a scar. (9) Because tracheostomy is an intrusive technique with a high rate of post-operative morbidity, it was only used in emergency situations. (10) (11) Because the inability to open the mouth makes direct vocal cord vision difficult, surgery for temporomandibular joint (TMJ) ankylosis is classified as difficult intubation. (12) Severe trismus, mandibular hypoplasia with asymmetrical growth of two parts of the jaw, and restricted mandibular space with pseudo macroglossia in a confined space narrow the pharyngeal channel

in TMJ ankylosis patients. (13) In order to identify the prevalence of difficult intubation in TMJ ankylosis patients, the incidence of difficult intubation is assessed.

Our team has vast research and knowledge, which has resulted in high-quality publications(14),(15),(16),(17),(18–27), (28),(29–31),(32,33).

MATERIALS AND METHODS :

The present study is a retrospective study carried out in a hospital setting under a specific population predominantly South Indian population. It is a single centred study with a small sample size. It was carried out under Institutional Review Board approval. In this study, data of the patients were collected by complete analysis of the data of patients between June 2020 to June 2021 from a patient management software (DIAS). Data including patients name, age, gender, surgical procedure in patients with TMJ ankylosis who underwent surgery were collected. And for further analysis the collected data was cross verified by another examiner. The collected data was tabulated using Excel Spreadsheets and the data was analysed using SPSS software version 19. The statistical study used in the study was Chi square test with p value less than 0.005 and confidence interval of 95%.

RESULTS AND DISCUSSION :

In this study, it was discovered that (58.33 percent) of the male population and (41.67 percent) of the female population participated. The age groupings of 5-18 years were found to be (68.18 percent), 19-50 years were found to be (13.64 percent), and 51-80 years were found to be (13.64 percent) (18.18 percent). In the investigation of the incidence of difficulty in intubation during TMJ ankylosis surgery, nasal intubation was found to be (33.33 percent), tracheostomy was found to be (25 percent), and fiberoptic intubation was found to be (41.67 percent) among the patient population.

Intubation is difficult in children. Because of their restricted mouth opening and limited lower jaw protrusion, children with TMJ ankylosis are likely to have difficulty intubating. Mask ventilation is also challenging due to mandibular hypoplasia and asymmetrical growth of the two parts of the jaw. TMJ ankylosis in children in impoverished nations manifests later in life with a substantially limited mouth opening. The traditional approach of intubation with direct laryngoscopy is usually not possible by this time. The literature mentions several airway management techniques such as tracheostomy, blind nasal intubation, and fiberoptic intubation. To reduce the risk of injury to the patient, the anesthesiologist should carefully assess the patient's airway, identify any potential difficulties, develop a plan with the lowest risk of injury, and have a backup plan ready. However, based on the experience and facilities available, each anesthesiology department should develop standards or algorithms that are unique to their institution. In this study, we have discussed our experience of difficult intubation in TMJ ankylosis patients.

CONCLUSION:

It can be concluded from the present small sampled retrospective study, nasal intubation and fiberoptic intubation were the most frequent difficult intubation done in TMJ ankylosis surgery. Out of which, intubation difficulty was higher in the paediatric age group 5-18 years.

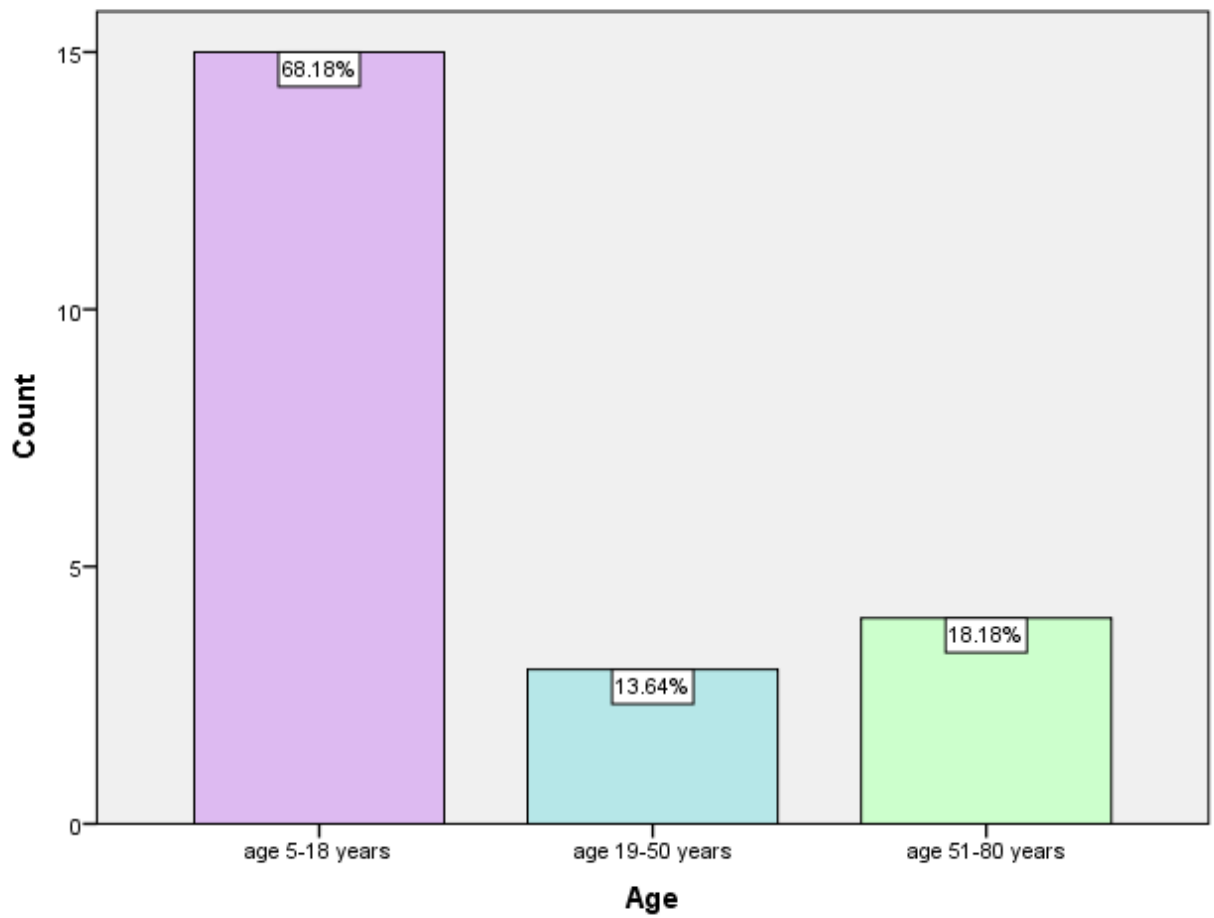


FIGURE 1 : Bar chart depicting the age groups involved in the study, age groups of 5-18 years were found to be (68.18 %) , age groups of 19-50 years were found to be (13.64 %) and age groups of 51-80 years were found to be (18.18 %).

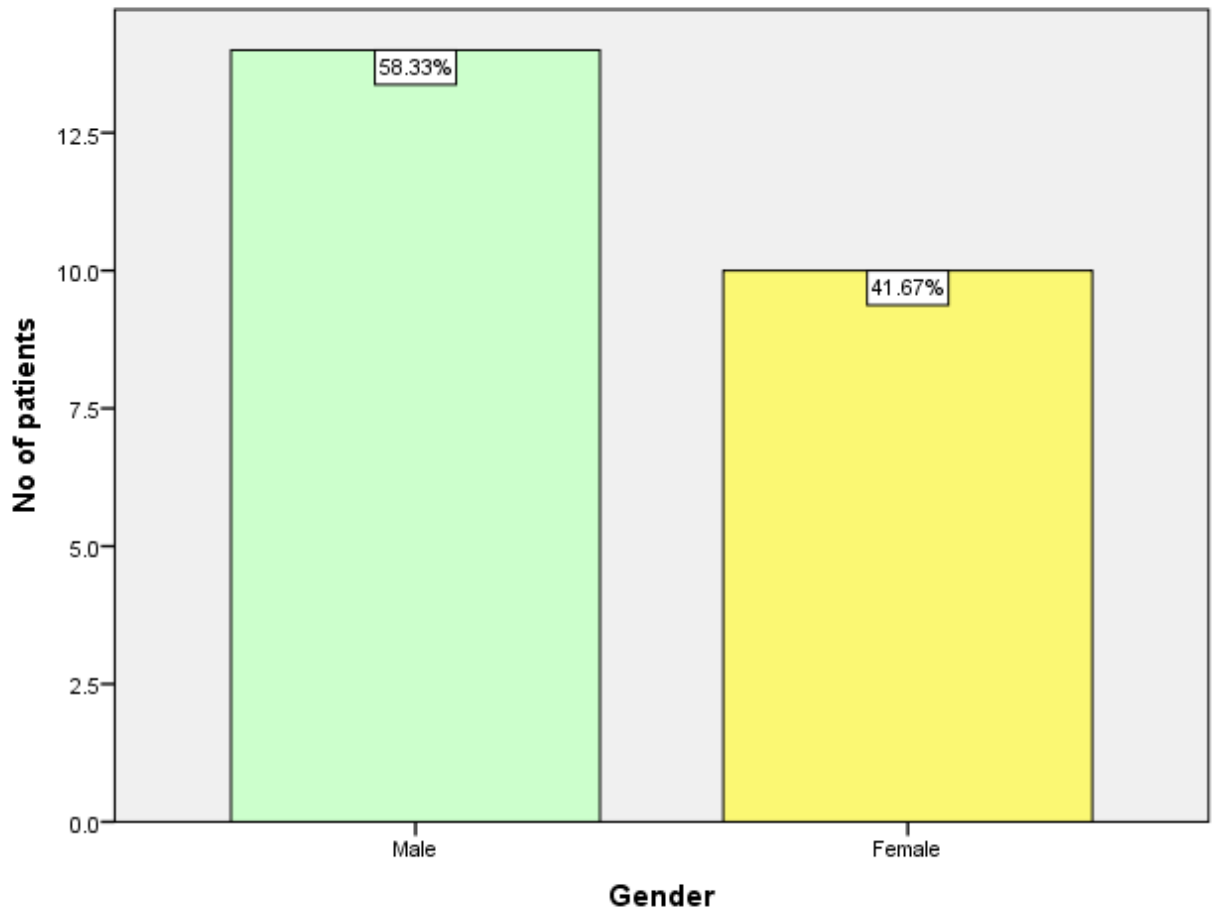


FIGURE 2 : Bar chart showing that (58.33 %) of the male population and (41.67 %) of the female population were involved in the study.

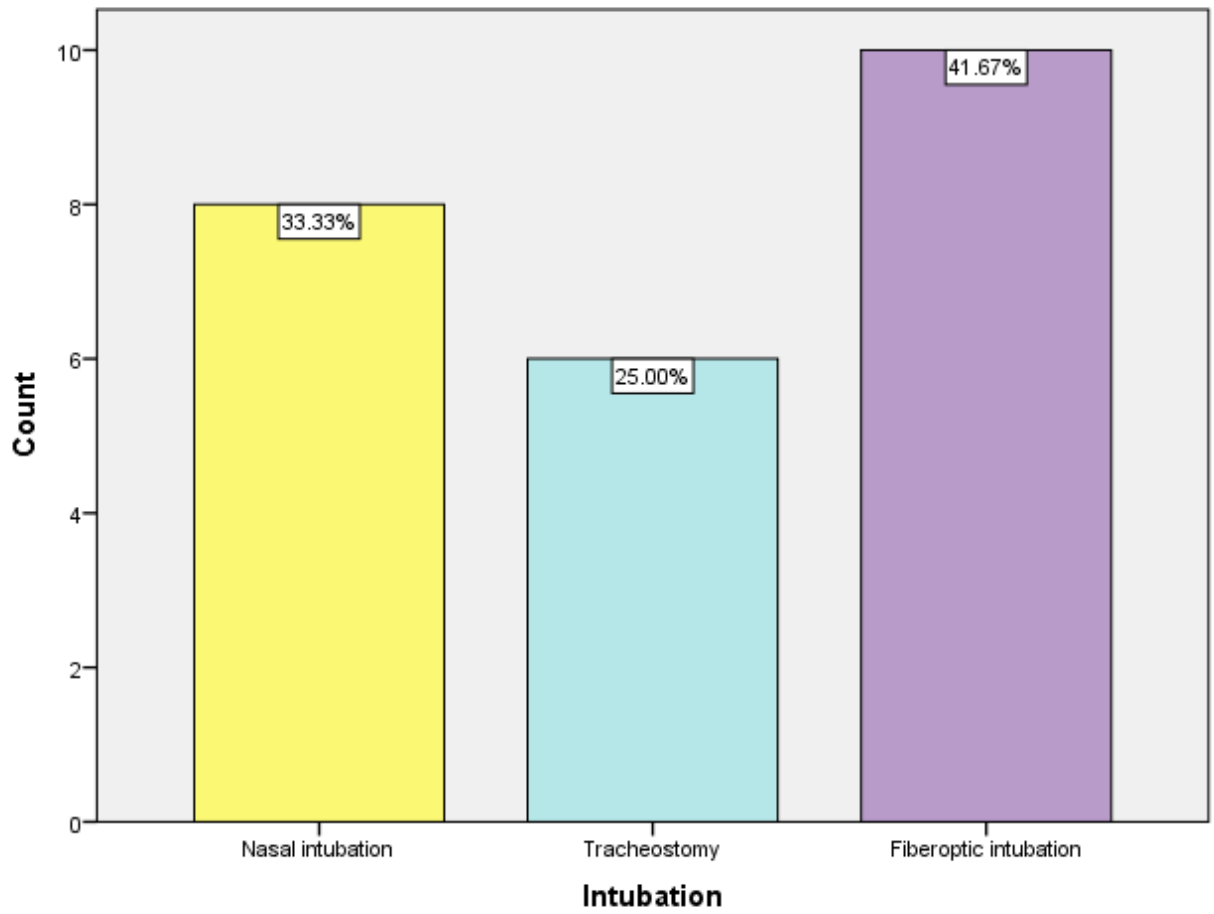


FIGURE 3 : Bar chart showing incidence of difficulty in intubation of TMJ ankylosis surgery that prevalence of nasal intubation was (33.33 %) prevalence of tracheostomy was found to be (25%) and prevalence of fiberoptic intubation was found to be (41.67 %) in the study.

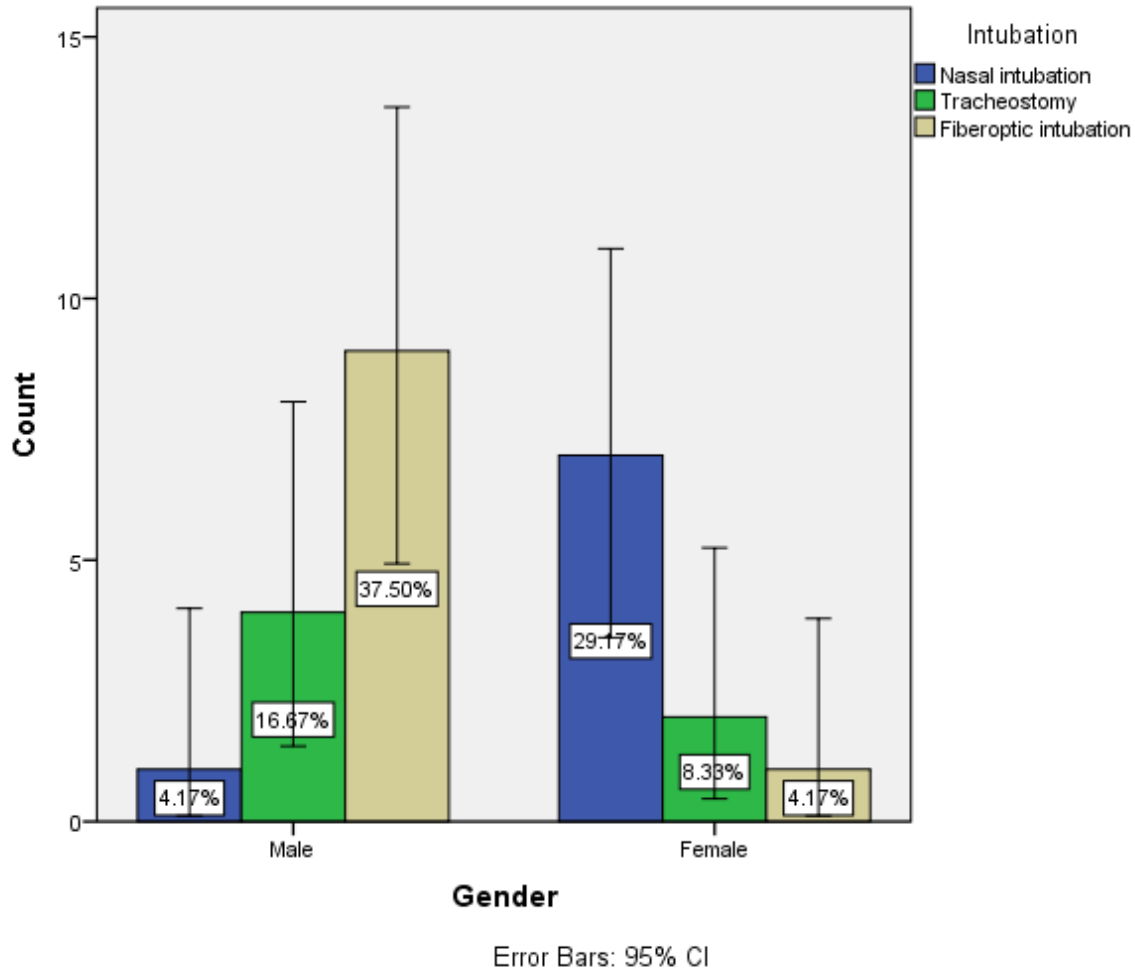


FIGURE 4 : Bar chart depicting correlation between the gender and the incidence of difficult intubation procedures it was observed that most frequent intubation done was fiberoptic intubation (37.50 %) in male population and nasal intubation (29.17 %) in female population. The results obtained in the chi square test were statistically significant. Pearson chi square = 11.211, df=2, p=0.004.

Ethical Approval:

As per international standard or university standard written ethical approval has been collected and preserved by the author(s).

REFERENCES :

1. K M, Mohan K. Anaesthesia for TMJ Ankylosis with the Use of TIVA, Followed by Endotracheal Intubation [Internet]. JOURNAL OF CLINICAL AND DIAGNOSTIC RESEARCH. 2012. Available from: <http://dx.doi.org/10.7860/jcdr/2012/3947.2605>
2. Lone DP, Lone P, Professor A, HOD, Surgery O&. M, Indira Gandhi Govt. Dental College, et al. A Clinical Case Series of 20 Patients with Tmj Ankylosis Treated by Two Different Approaches [Internet]. Vol. 4, Indian Journal of Applied Research. 2011. p. 492–5. Available from: <http://dx.doi.org/10.15373/2249555x/may2014/154>
3. Nkoulou C. S-Guide® versus Gliderite® for videolaryngoscopic intubation of patients with simulated difficult airways [Internet]. Available from: <http://dx.doi.org/10.26226/morressier.57108e32d462b80290b4add8>
4. Klaric V, Herold J. 10 / Identifying predictors of difficult intubation among obese oral surgical patients [Internet]. Available from: <http://dx.doi.org/10.26226/morressier.5aeb0acc07b0d6001a79ab1b>
5. Petit J-S, Boulonnais C, Graftieaux J-P, Malinovsky J-M. Difficult Intubation Related to Ankylosis of Temporomandibular Joint After Craniotomy [Internet]. Vol. 17, Journal of Neurosurgical Anesthesiology. 2005. p. 174–5. Available from: <http://dx.doi.org/10.1097/01.ana.0000171731.41008.93>
6. Rao S, Rai S, Das PK, Kumar S, Malviya D, Tripathi M. Effect of use of High-Flow Nasal Cannula during Fiberoptic Intubation under General Anesthesia: A Randomized Controlled Trial. Anesth Essays Res [Internet]. 2020 Oct;14(4):632–7. Available from: http://dx.doi.org/10.4103/aer.aer_55_21
7. Ciechomski JA. TMJ REPLACEMENT WITH TAILORED PROSTHESIS AND SIMULTANEOUS LEFORT I OSTEOTOMY TO TREAT FACIAL ASSYMETRY DUE TO TMJ ANKYLOSIS SEQUELAE. CASE REPORT [Internet]. Available from: <http://dx.doi.org/10.26226/morressier.578e3b51d462b80292382a7d>
8. Mohanta J, Kumar A, Kaushal A, Talawar P, Gupta P, Jain G. Anaesthesia for Awake Fiberoptic Intubation: Ultrasound-Guided Airway Nerve Block versus Ultrasonic Nebulisation with Lignocaine. Discoveries (Craiova) [Internet]. 2021 Mar 31;9(1):e125. Available from: <http://dx.doi.org/10.15190/d.2021.4>
9. Khanum T, Zia S, Khan T, Kamal S, Khoso MN, Alvi J, et al. Assessment of knowledge regarding tracheostomy care and management of early complications among healthcare

- professionals. *Braz J Otorhinolaryngol* [Internet]. 2021 Aug 6; Available from: <http://dx.doi.org/10.1016/j.bjorl.2021.06.011>
10. Shapiro BA, Glassenberg R, Panchal S. The Incidence of Failed or Difficult Intubation in Different Surgical Populations [Internet]. Vol. 81, *Anesthesiology*. 1994. p. A1213. Available from: <http://dx.doi.org/10.1097/00000542-199409001-01212>
 11. Heir JS, Kupferman ME. A simple approach to facilitating fiberoptic intubation in the difficult airway [Internet]. Vol. 121, *The Laryngoscope*. 2011. p. 310–2. Available from: <http://dx.doi.org/10.1002/lary.21386>
 12. Popat M. *Difficult Airway Management* [Internet]. Oxford University Press; 2009. 170 p. Available from: https://books.google.com/books/about/Difficult_Airway_Management.html?hl=&id=TeEaRpBoWn0C
 13. Gupta A, Kapoor D, Awana M, Lehl G. Fiberscope Assisted Videolaryngoscope Intubation in the Surgical Treatment of TMJ Ankylosis [Internet]. Vol. 14, *Journal of Maxillofacial and Oral Surgery*. 2015. p. 484–6. Available from: <http://dx.doi.org/10.1007/s12663-014-0619-7>
 14. J PC, Pradeep CJ, Marimuthu T, Krithika C, Devadoss P, Kumar SM. Prevalence and measurement of anterior loop of the mandibular canal using CBCT: A cross sectional study [Internet]. Vol. 20, *Clinical Implant Dentistry and Related Research*. 2018. p. 531–4. Available from: <http://dx.doi.org/10.1111/cid.12609>
 15. Wahab PUA, Abdul Wahab PU, Madhulaxmi M, Senthilnathan P, Muthusekhar MR, Vohra Y, et al. Scalpel Versus Diathermy in Wound Healing After Mucosal Incisions: A Split-Mouth Study [Internet]. Vol. 76, *Journal of Oral and Maxillofacial Surgery*. 2018. p. 1160–4. Available from: <http://dx.doi.org/10.1016/j.joms.2017.12.020>
 16. Mudigonda SK, Murugan S, Velavan K, Thulasiraman S, Krishna Kumar Raja VB. Non-suturing microvascular anastomosis in maxillofacial reconstruction- a comparative study. *Journal of Cranio-Maxillofacial Surgery* [Internet]. 2020 Jun 1;48(6):599–606. Available from: <https://www.sciencedirect.com/science/article/pii/S1010518220301098>
 17. Narayanasamy RK, Muthusekar RM, Nagalingam SP, Thyagarajan S, Ramakrishnan B, Perumal K. Lower pretreatment hemoglobin status and treatment breaks in locally advanced head and neck squamous cell carcinoma during concurrent chemoradiation. *Indian J Cancer* [Internet]. 2021 Jan;58(1):62–8. Available from: http://dx.doi.org/10.4103/ijc.IJC_656_18
 18. Wang H, Chinnathambi A, Alahmadi TA, Alharbi SA, Veeraraghavan VP, Krishna Mohan S, et al. Phyllanthin inhibits MOLT-4 leukemic cancer cell growth and induces apoptosis through the inhibition of AKT and JNK signaling pathway. *J Biochem Mol Toxicol* [Internet]. 2021 Jun;35(6):1–10. Available from: <http://dx.doi.org/10.1002/jbt.22758>
 19. Li S, Zhang Y, Veeraraghavan VP, Mohan SK, Ma Y. Restorative Effect of Fucoxanthin in an Ovalbumin-Induced Allergic Rhinitis Animal Model through NF- κ B p65 and STAT3

- Signaling. *J Environ Pathol Toxicol Oncol* [Internet]. 2019;38(4):365–75. Available from: <http://dx.doi.org/10.1615/JEnvironPatholToxicolOncol.2019030997>
20. Ma Y, Karunakaran T, Veeraraghavan VP, Mohan SK, Li S. Sesame Inhibits Cell Proliferation and Induces Apoptosis through Inhibition of STAT-3 Translocation in Thyroid Cancer Cell Lines (FTC-133). *Biotechnol Bioprocess Eng* [Internet]. 2019 Aug 1;24(4):646–52. Available from: <https://doi.org/10.1007/s12257-019-0151-1>
 21. Bishir M, Bhat A, Essa MM, Ekpo O, Ihunwo AO, Veeraraghavan VP, et al. Sleep Deprivation and Neurological Disorders. *Biomed Res Int* [Internet]. 2020 Nov 23;2020:5764017. Available from: <http://dx.doi.org/10.1155/2020/5764017>
 22. Fan Y, Maghimaa M, Chinnathambi A, Alharbi SA, Veeraraghavan VP, Mohan SK, et al. Tomentosin Reduces Behavior Deficits and Neuroinflammatory Response in MPTP-Induced Parkinson's Disease in Mice. *J Environ Pathol Toxicol Oncol* [Internet]. 2021;40(1):75–84. Available from: <http://dx.doi.org/10.1615/JEnvironPatholToxicolOncol.v40.i1.70>
 23. Zhang C, Chen Y, Zhang M, Xu C, Gong G, Veeraraghavan VP, et al. Vicenin-2 Treatment Attenuated the Diethylnitrosamine-Induced Liver Carcinoma and Oxidative Stress through Increased Apoptotic Protein Expression in Experimental Rats. *J Environ Pathol Toxicol Oncol* [Internet]. 2020;39(2):113–23. Available from: <http://dx.doi.org/10.1615/JEnvironPatholToxicolOncol.2020031892>
 24. Gan H, Zhang Y, Zhou Q, Zheng L, Xie X, Veeraraghavan VP, et al. Zingerone induced caspase-dependent apoptosis in MCF-7 cells and prevents 7,12-dimethylbenz(a)anthracene-induced mammary carcinogenesis in experimental rats. *J Biochem Mol Toxicol* [Internet]. 2019 Oct;33(10):e22387. Available from: <http://dx.doi.org/10.1002/jbt.22387>
 25. Saravanakumar K, Park S, Mariadoss AVA, Sathiyaseelan A, Veeraraghavan VP, Kim S, et al. Chemical composition, antioxidant, and anti-diabetic activities of ethyl acetate fraction of *Stachys riedereri* var. *japonica* (Miq.) in streptozotocin-induced type 2 diabetic mice. *Food Chem Toxicol* [Internet]. 2021 Jun 26;155:112374. Available from: <http://dx.doi.org/10.1016/j.fct.2021.112374>
 26. Veeraraghavan VP, Hussain S, Papayya Balakrishna J, Dhawale L, Kullappan M, Mallavarapu Ambrose J, et al. A Comprehensive and Critical Review on Ethnopharmacological Importance of Desert Truffles: *Terfezia clavaryi*, *Terfezia boudieri*, and *Tirmania nivea*. *Food Rev Int* [Internet]. 2021 Feb 24;1–20. Available from: <https://doi.org/10.1080/87559129.2021.1889581>
 27. Wei W, Li R, Liu Q, Devanathadesikan Seshadri V, Veeraraghavan VP, Surapaneni KM, et al. Amelioration of oxidative stress, inflammation and tumor promotion by Tin oxide-Sodium alginate-Polyethylene glycol-Allyl isothiocyanate nanocomposites on the 1,2-Dimethylhydrazine induced colon carcinogenesis in rats. *Arabian Journal of Chemistry* [Internet]. 2021 Aug 1;14(8):103238. Available from: <https://www.sciencedirect.com/science/article/pii/S1878535221002537>

28. Sathya S, Ragul V, Veeraraghavan VP, Singh L, Niyas Ahamed MI. An in vitro study on hexavalent chromium [Cr(VI)] remediation using iron oxide nanoparticles based beads. *Environmental Nanotechnology, Monitoring & Management* [Internet]. 2020 Dec 1;14:100333. Available from: <https://www.sciencedirect.com/science/article/pii/S2215153220302099>
29. Chandrasekar R, Chandrasekhar S, Sundari KKS, Ravi P. Development and validation of a formula for objective assessment of cervical vertebral bone age. *Prog Orthod* [Internet]. 2020 Oct 12;21(1):38. Available from: <http://dx.doi.org/10.1186/s40510-020-00338-0>
30. Ramakrishnan M, Dhanalakshmi R, Subramanian EMG. Survival rate of different fixed posterior space maintainers used in Paediatric Dentistry – A systematic review [Internet]. Vol. 31, *The Saudi Dental Journal*. 2019. p. 165–72. Available from: <http://dx.doi.org/10.1016/j.sdentj.2019.02.037>
31. Felicita AS, Sumathi Felicita A. Orthodontic extrusion of Ellis Class VIII fracture of maxillary lateral incisor – The sling shot method [Internet]. Vol. 30, *The Saudi Dental Journal*. 2018. p. 265–9. Available from: <http://dx.doi.org/10.1016/j.sdentj.2018.05.001>
32. Su P, Veeraraghavan VP, Krishna Mohan S, Lu W. A ginger derivative, zingerone-a phenolic compound-induces ROS-mediated apoptosis in colon cancer cells (HCT-116). *J Biochem Mol Toxicol* [Internet]. 2019 Dec;33(12):e22403. Available from: <http://dx.doi.org/10.1002/jbt.22403>
33. Wan J, Feng Y, Du L, Veeraraghavan VP, Mohan SK, Guo S. Antiatherosclerotic Activity of Eriocitrin in High-Fat-Diet-Induced Atherosclerosis Model Rats. *J Environ Pathol Toxicol Oncol* [Internet]. 2020;39(1):61–75. Available from: <http://dx.doi.org/10.1615/JEnvironPatholToxicolOncol.2020031478>