

Evaluation of Unilateral Sinonasal Lesions

Abstract

Background: Sinonasal lesions are a common occurrence in people of all ages. Nasal and paranasal sinus lesions are quite deceiving; Thus, the presenting characteristics, nasal endoscopy, clinical examination, histopathology, and radiographic findings are all used in conjunction to provide a diagnosis. The aim of this research was to observe a much of higher percentage of unilateral sinus pathology. Comprehensive evaluation of patient age, presenting symptoms, sex, nasoendoscopic examination and computed tomography (CT) or magnetic resonance imaging (MRI) results help in the diagnosis of unilateral sinus disease with finding the same result in patient who had endoscopic sinus surgery performed in ear, nose, and throat (ENT) department of Tanta University Hospital.

Methods: This prospective randomized controlled study was conducted on 100 adult and pediatric patients who were suffering from nasal obstruction, epistaxis, proptosis, headache, and space occupying lesions in one side of nose including inflammatory, benign and malignant lesions. All cases underwent complete taking of history, endoscopic assessment, otorhinological examination, CT, MRI for evaluation of unilateral opacification of paranasal sinuses and other routine preoperative laboratory investigation.

Results: Of all affected sinuses, right maxillary sinus and nasal cavity were the most significantly affected sinuses in malignant tumor group than both inflammatory disease group and benign tumor group ($P = 0.002, 0.001$ respectively) while left maxillary, right ethmoid, left ethmoid, right sphenoid, left sphenoid, right frontal and left frontal showed insignificant differences in affection among the three groups. All performed radiology to the patients was insignificantly different among the three groups ($P = 0.211$). The main symptoms were significantly different among the three groups ($P < 0.001$). Preoperative biopsy taking was significantly increased in malignant tumor group than both inflammatory disease and benign tumor group ($P = 0.001$). Diseases in the patients were significantly different among the three groups ($P < 0.001$). Patients with excellent results of the operation was significantly decreased

in malignant tumor group than benign tumor group ($P = 0.001$). The type of surgery was significantly different among the three groups ($P < 0.001$).

Conclusions: Unilateral nasal polyps are associated with a high rate of malignancy and should be carefully examined using endoscopy and histology.

Keywords: Evaluation, Unilateral, Sinonasal lesions.

Introduction:

Numerous benign and malignant disorders involving the nasal cavity and paranasal sinuses are a frequent presentation in clinical practice ^[1].

Sinonasal lesions are a frequent occurrence in individuals of all ages. Nasal and paranasal sinus lesions are quite deceiving, As a result, the presenting manifestations, nasal endoscopy, clinical examination, radiographic findings, and histopathology are all used in conjunction to arrive at a diagnosis ^[1].

Although unilateral nasal masses are common in ENT clinics, they can be difficult to diagnose due to their clinical resemblance to rhinosinusitis. It is critical to diagnose and treat these tumour, due to they are more likely than bilaterally detected inflammatory masses to be premalignant or malignant and due to their connection to the cerebral parenchyma or the cerebrospinal fluid and because and could have been derived from vascular structures ^[2].

Due to their hidden nature and late manifestation, neoplastic lesions of the nose and paranasal sinus are one of the most difficult disorders for otolaryngologists to diagnose and treat, Thus, the physician should maintain a high index of suspicion in all patients with unilateral nasal mass to rule out a neoplastic cause ^[1].

A thorough workup, including radiological and histological classification is critical for managing sinonasal lesions.

Nowadays, Endoscopic nasal facilities have a great role in management of most non neoplastic and neoplastic lesions with minimal problems following surgery ^[2].

The aim of this research was to observe a much of higher percentage of unilateral sinus pathology. Comprehensive assessment of the patient's sex, age, exhibiting symptoms, nasoendoscopic investigation and CT or MRI results aid in the diagnosis of unilateral sinus disease with finding the same result in patient who had endoscopic sinus surgery performed in ENT department of Tanta University Hospital.

Patients and Methods:

This study was a prospective randomized controlled trial which conducted on 100 Adult and pediatric patients who are suffering from nasal obstruction, epistaxis, proptosis, headache and space occupying lesions in one side of nose including inflammatory, benign and malignant lesions at Tanta University Hospital, otorhinolaryngology Department, hospitals from April 2019 to December 2020. The study was done after being approved from Tanta University

research ethical committee. All patients enrolled in the trial provided signed informed consent.

Bilateral sinonasal pathologies were excluded.

All individuals included in this trial underwent the following: Preoperative (complete history taking, endoscopic investigation, otorhinological examination, CT, MRI for evaluation of unilateral opacification of paranasal sinuses, routine preoperative laboratory investigation, biopsy if needed, each patient is discussed by the team for planning of appropriate approaches, each approach will be evaluated as regards, its accessibility, values, limitation, difficulties, and risks, maintaining the privacy of the patients in the form of: A) The results are to be used solely for study purposes and not for publication in the media, B) The images and videos will show only the area of the surgery without revealing the patient's face, C) All the procedures used in the research have no conflict with religion or low or social rules)

Due to multiplicity of the causes of unilateral sinonasal lesions we had categorized the lesions and procedures for 3 groups; group A: Inflammatory lesions, group B: Benign lesions and group C: Malignant lesions.

According to radiological and histopathological examination approaches were either:

Endoscopic endonasal, external osteoplastic, endoscopic with reconstruction, endoscopic with craniotomy, intra operative frozen section and histopathological examination of the excised tumor was done to ensure complete excision by examining margins in the case of malignant tumors, postoperative follow up was done every three months for inflammatory cases for six months, and every three months for 6 months for benign cases and after 6 months for a year, and in malignant cases was every month for 6 months then every 3 months for one year.

Follow up protocol was: Clinical examination, endoscopic examination, imaging in cases suspected to have recurrence and biopsy and histopathological examination of the site the tumor in cases of suspected recurrence.

Assessment of clinical examination, biopsy result, tumor sites and extensions, imaging and different approaches.

Major complications were defined in the study to be: Neurological like CSF leak, orbital like visual loss and intra or post-operative mortality.

Minor complications include mainly scars, residual lesions were defined as lesions detected immediately post-operative or was recognized intraoperative but can't be managed due to

difficult manipulation or emerging of complication and recurrences were reappearance of the lesion after period of cure.

Statistical method

The IBM, Illinois, Chicago, USA, SPSS version 19 (Statistical Package for Social Studies) was used to organise, tabulate, and statistically analyse the collected data. The range, mean, and standard deviations of numerical values were computed. This method was used to examine differences in mean values among the groups studied because the data were not normally distributed. The chi square test or Monte Carlo exact test was used when the chi square test was found to be inappropriate for categorical variables, and differences between subcategories were tested. The significance level was set at p 0.05.

Results:

Age of the patients was insignificantly different among the three groups (P = 0.097). Sex of the patients was insignificantly different among the three groups (P = 0.594). **Table 1**

Table 1: Age and sex in all studied groups

Age in years	Inflammatory disease (n=67)		Benign tumor (n=27)		Malignant tumor (n=8)	
	N	%	N	%	N	%
<20	8	11.9	4	14.8	1	12.5
20-29	19	28.4	1	3.7	1	12.5
30-39	18	26.9	4	14.8	0	0.0
40-49	8	11.9	10	37.0	3	37.5
50-59	5	7.5	5	18.5	1	12.5
60-69	8	11.9	2	7.4	2	25.0
70-79	1	1.5	1	3.7	0	0.0
Range	7-70		10-76		16-66	
Mean± SD	35.91 ± 15.34		41.89±16.16		44.25±17.32	
Kruskal-Wallis test	4.673					
p	0.097					
Males	35	52.2	16	59.3	3	37.5
Females	32	47.8	11	40.7	5	62.5
p	0.594					

Of all affected sinuses, right maxillary sinus and nasal cavity were the most significantly affected sinuses in malignant tumor group than both inflammatory disease group and benign tumor group ($P = 0.002, 0.001$ respectively) while left maxillary, right ethmoid, left ethmoid, right sphenoid, left sphenoid, right frontal and left frontal showed insignificant differences in affection among the three groups. **Table 2**

Table 2: Sinus affected in all studied groups

Sinus affected	Inflammatory disease (n=67)		Benign tumor (n=27)		Malignant tumor (n=8)		P value
	N	%	N	%	N	%	
Right maxillary	25	37.3	9	33.3	8	100.0	0.002*
Left maxillary	22	32.8	7	25.9	0	0.0	0.140
Right ethmoid	6	9.0	4	14.8	1	12.5	0.509
Left ethmoid	14	20.9	4	14.8	0	0.0	0.371
Right sphenoid	5	7.5	4	14.8	1	12.5	0.664
Left sphenoid	4	6.0	2	7.4	1	12.5	0.550
Right frontal	10	14.9	7	25.9	1	12.5	0.412
Left frontal	14	20.9	2	7.4	0	0.0	0.152
Nasal cavity	17	25.4	10	37.0	8	100.0	0.001*

* Significant as P value <0.05.

All performed radiology (CT, MRI, and PET) to the patients was insignificantly different among the three groups ($P = 0.211$). **Table 3**

Table 3: Performed radiology in all studied groups

Radiology	Inflammatory disease (n=67)		Benign tumor (n=27)		Malignant tumor (n=8)	
	N	%	N	%	n	%
CT	42	63.0	13	50.0	2	37.2
MRI and CT	23	33.3	12	47.5	4	57.2
MRI	2	3.7	0	0.0	1	2.9
CT, MRI, and PET CT	0	0.0	1	2.5	1	2.9
p	0.211					

The main symptoms were significantly different among the three groups ($P < 0.001$) as follow: asymptomatic patients and nasal obstruction were significantly decreased in malignant tumor group than both inflammatory disease group and benign tumor group while proptosis and oral swelling were significantly increased in malignant tumor group than both inflammatory disease group and benign tumor group, but epistaxis was insignificantly different among the three groups.

Preoperative biopsy taking was significantly increased in malignant tumor group than both inflammatory disease and benign tumor group ($P = 0.001$). Table 4

Table 4: Main symptoms and Pre-operative biopsy in all studied groups

Main symptoms	Inflammatory disease (n=67)		Benign tumor (n=27)		Malignant tumor (n=8)	
	N	%	N	%	N	%
Nasal obstruction	60	82.1	18	66.7	0	0.0
Epistaxis	7	1.5	9	33.3	1	12.5
Proptosis	0	0.0	0	0.0	3	37.5
Oral swelling	0	0.0	0	0.0	4	50.0
P value	<0.001*					
Preoperative biopsy						
None	55	82.1	20	74.1	0	0.0
Done	12	17.9	7	25.9	8	100.0
X ²	27.749					
p	0.001*					

* Significant as P value <0.05

Diseases in the patients were significantly different among the three groups ($P < 0.001$). **Table 5**

Table 5: Diseases in all studied groups

Disease	Inflammatory disease (n=67)		Benign tumor (n=27)		Malignant tumor (n=8)	
	N	%	n	%	N	%
Inflammatory sinusitis	25	37.3	0	0.0	0	0.0
Antero-choanal polyp	18	26.9	0	0.0	0	0.0
Fungal sinusitis	13	19.4	0	0.0	0	0.0
Mucocele	5	7.5	0	0.0	0	0.0

Acute invasive fungal sinusitis	4	6.0	0	0.0	0	0.0
Silent sinus syndrome	2	3.0	0	0.0	0	0.0
Angiofibroma	0	0.0	4	14.8	0	0.0
Inverted papilloma	0	0.0	14	51.9	0	0.0
Ossified fibroma	0	0.0	3	11.1	0	0.0
Osteoma	0	0.0	4	14.8	0	0.0
Monostatic fibrous dysplasia	0	0.0	2	7.4	0	0.0
Adenocystic carcinoma	0	0.0	0	0.0	2	25.0
Fibrous histiocytoma	0	0.0	0	0.0	1	12.5
Mucoepidermoid carcinoma low grade	0	0.0	0	0.0	2	25.0
Mucoepidermoid carcinoma high grade	0	0.0	0	0.0	2	25.0
Adenocarcinoma	0	0.0	0	0.0	1	12.5
P value	<0.001*					

* Significant as P value <0.05

Patients with excellent results of the operation was significantly decreased in malignant tumor group than benign tumor group (P = 0.001).

Pre- and post-operative follow up of the patients by NOSE score, most patients with nasal obstruction due to inflammatory and benign lesions improved after surgical procedure and post-operative follow up and care and totally improved after 6 months, while cases with malignant lesions were mostly satisfactory just long follow up and post-operative scars or radiotherapy treatment.

The type of surgery was significantly different among the three groups (P <0.001) as follow: endoscopic intervention only was significantly decreased in malignant tumor group than both inflammatory disease group and benign tumor group while endoscopic intervention with craniotomy was significantly increased in malignant tumor than both inflammatory disease group and benign tumor group but endoscopic intervention with reconstruction and external osteoplastic intervention were insignificantly different among the three groups. **Table 6**

Table 6: Results of operation and type of surgery in all studied groups

Results	Benign tumor (n=27)		Malignant tumor (n=8)	
	N	%	N	%
Excellent	18	66.7	18	66.7

Satisfactory	9	33.3	9	33.3		
P	0.001*					
Type of surgery	Inflammatory disease (n=67)		Benign tumor (n=27)		Malignant tumor (n=8)	
	N	%	N	%	N	%
Endoscopic	67	100.0	24	88.9	6	75.0
Endoscopic with craniotomy	0	0.0	0	0.0	2	25.0
Endoscopic with reconstruction	0	0.0	1	3.7	0	0.0
External osteoplastic	0	0.0	2	7.4	0	0.0
P value	<0.001*					

* Significant as P value <0.05

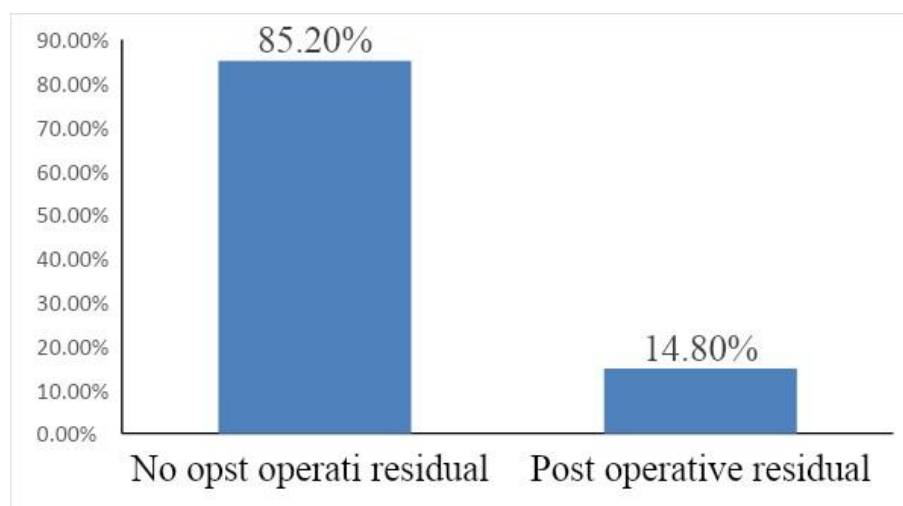


Figure 1: Distribution of cases with benign tumor in relation to post-operative residual

Discussion

Patients with Sinonasal tumours may appear with rhinorrhea and nasal blockage to their otorhinolaryngologist. Persistent nasal obstruction on one side may suggest the presence of a sinonasal lesion, which may be inflammatory or malignant. While the majority of sinonasal masses are benign polyps, neoplastic lesions do occur, particularly in unilateral diseases. Adults with unilateral sinonasal tumour are frequently misdiagnosed with inverted papilloma or malignant lesion. However, other workers indicated that the most common sinonasal lesions were simple nasal polyps and squamous cell cancer [3].

Our results were supported by study of Alshoabi et al. ^[4] as They reported that the study's 82 patients with CRS ranged in age from 4 to 90 years (mean: 34.4817.74 years), with 45 (54.88 percent) being female. The majority of patients were in their second to fifth decades, with a peak in the third decade ($p < 0.001$). The most often encountered lesion (31.4 %) was inflammatory polyps, followed by allergic polyps (30.5 %). 9.8 % of lesions were nasopharyngeal carcinoma (NPC).

In the study of Eid and Eissa ^[5], nasal involvement was the most common type, occurring in ten cases, in eight patients, with varying degrees of nasal and sinus involvement, and only two patients with purely unilateral nasal disease; One depicts a nasal mass between the inferior and middle turbinates, while another is epicentered on the traditional location of the lateral nasal wall, opposite the middle meatus. In one example of bilateral bi-nasal illness, the nasal lesions were predominantly big with limited frontal sinus extension. Two patients presented with a combination of maxillary sinus and nasal illness. Three instances exhibited nasal and ethmoidal involvement, with two cases exhibiting minor frontal sinus extension and one exhibiting maxillary extension. Two cases involved both the nasal and maxillary sinuses. Three cases involved only the maxillary sinus. Two patients had involvement of the sphenoid-ethmoidal sinus.

Sharma et al. did a study in which they discovered ^[6], Lesions with unilateral involvement accounted for 68% of all lesions, while lesions with bilateral involvement accounted for 32% of all lesions while Bakari et al., ^[7] stated that 55.3 % had unilateral sinonasal masses, whereas 44.7 % had bilateral lesions. Agreeing to Bist et al. ^[8] The majority of sinonasal masses (66.36 %) were unilateral in nature, whereas just 25.45 % were bilateral in nature. In a work by Lathi et al. ^[9] in 48.2 % of patients, unilateral presentation was observed; in 51.8 %, bilateral presentation was observed. Gupta et al. ^[10] discovered that 83.6 % of their overall patients presented unilaterally, while 16.4 % presented bilaterally.

Clinical diagnosis of a patient with a single-sided sinonasal tumour is a significant clinical challenge due to the diverse nature of the underlying etiologies. A thorough evaluation of the patient include examining the patient's age, nasal endoscopic examination, symptoms, and CT findings ^[11].

In the research of Nair et al. ^[11], in inflammatory situations, CT scans indicated sinus opacity, the existence of high attenuation areas without bony erosions, and intrasinous densities, as opposed to sinus opacity with bone expansion and weakening in mucocoeles. The keratocyst maxilla and inverted papilloma had sinus opacity with erosion, whereas the malignant lesions had sclerosis, erosion, and significant soft tissue invasion. On CT scan, a few cases such as

mucormycosis, mucopyocele, and keratocyst maxilla displayed similar results such as bone weakening and erosion consistent with malignant lesions, although inverted papilloma in its early stages was readily mistaken for an inflammatory illness.

According to Alshoabi et al. ^[4] The findings indicated a high degree of congruence between clinical diagnosis and histopathological findings, ($p < 0.001$) and kappa=0.215 as a measure of agreement. Additionally, the data indicated a substantial correlation between the radiologist's CT diagnoses and the histology findings. ($p < 0.001$). The findings indicated a high degree of congruence between clinical and radiological diagnosis of bilateral sinonasal lesions. Each case of sinonasal polyposis was inflammatory and allergic in nature, but none was malignant. This finding is congruent with that of Wong et al. ^[12] who demonstrated that there is relatively little discrepancy between clinical and histological diagnosis of bilateral nasal polyps.

Also, Hameed et al. ^[13] revealed that Between 2018 and 2019, 200 patients with signs and symptoms of sinonasal disorders were enrolled in a retrospective study at the Department of ENT. Sinonasal diseases were considered if they manifested as masses in the para nasal sinus, or nasopharynx, nasal cavity, and if they were associated with symptoms of nasal obstruction, hyposmia, discharge, headache, or recurrent epistaxis. Prior to endoscopic surgery, clinical evidence of sinonasal illnesses was detected via nasal endoscopy and CT, and malignant cases were avoided. Nasal endoscopic procedures were conducted utilising 0°, 30°, and 70° Hopkins's rod endoscopes with a 4 mm working diameter.

Lee ^[14], and Rudralingam et al., ^[15] conducted a study in which CT is an advantageous technique for revealing bone degradation and elucidating the aetiology of fungal infections. Bone erosion may be observed in patients with inverted papilloma. In the study of Kandukuri and Phatak ^[16], they detected a defect on the anterior wall of the maxillary sinus in one patient with inverted papilloma and also a defect on the lamina papyracea in another patient with inverted papilloma.

In the study of Sharma et al. ^[6], The most often encountered manifestation of sinonasal tumours was nasal obstruction (56%), followed by nasal discharge (34%) and then post nasal discharge (22 %). Bist et al., (11) observed that nasal obstruction (87.27 %) is the most often reported presenting symptom, followed by nasal discharge (69.09 %) and headache (60.90 %).

Gupta et al. ^[10] observed that sinonasal tumours were most frequently associated with nasal obstruction (94.5 %) and rhinorrhea (90.2 %). Bakari et al. (73) reported that nasal obstruction (97.4 %), rhinorrhea (94.7 %), allergy symptoms (52.6 %), and anosmia were the most common presenting symptoms (34.6 %). Lathi et al., (75) The most prevalent presenting

complaint (97.3%) was nasal obstruction, followed by rhinorrhea (49.1%), hyposmia (31.3%), intermittent epistaxis (17.9%), headache (16.9%), swelling over the face (11.6%), and eye-related symptoms (10.7 %).

Rhinorrhea, hyposmia, nasal obstruction, cheek swelling, epistaxis, facial pain, proptosis, unsteady tooth, and diplopia are all clinical manifestations of sinonasal disease. In previous study of Tritt et al. ^[1], Epistaxis and discomfort were the most often reported symptoms in patients with neoplastic diseases. This is also their observation, as we discovered that epistaxis was a common presenting symptom associated with malignant lesions.

Our results were supported by study of Kandukuri and Phatak, ^[16] as they reported that The most often encountered benign pathology was nasopharyngeal angiofibroma, which was also observed in the Goma et al. investigation. ^[17]. The most frequently encountered malignant pathology was squamous cell carcinoma of the maxillary sinus, which was also observed in Azzam et al. ^[18] Goma et al. ^[17] and Chow et al. ^[18] investigation's.

However, in the study of Sharma et al. ^[6], inverted papilloma and nasopharyngeal angiofibroma were seen in 6.52 % and 5.43 % of benign neoplastic sinonasal masses, respectively. 6.52 % had a malignant sinonasal mass. Chavan et al.,^[19] The nasal polyp was identified as the most frequently seen benign sinonasal mass in 51.7 %; 20.4 % revealed an antrochoanal polyp; and 12.24 % indicated nasopharyngeal angiofibroma. Bakari et al. ^[7] reported that In their investigation, benign non-neoplastic lesions accounted for around 77.6 %, while 2.6 % were malignant and 19.7 % lacked a pathologic diagnosis.

According to Belli et al. ^[20], nasal polyp was seen among all lesions, and also benign lesions.. adults were more likely to have nasal polyps than children, and men were more likely to have nasal polyps than women. 158 patients had a nasal polyp identified (81.03 %). The second most frequently encountered tumour was a Schneiderian papilloma. Schnederian papilloma is classified as inverted, oncocytic or, fungiform. They discovered inverted (92.31%), oncocytic (3.85%) and fungiform (3.85%), schnederian papillomas in proportionate proportions of patients with schnederian papillomas in this investigation. regarding malignant lesions, we confronted squamous cell carcinoma developed on the background of inverted papilloma, high-grade dysplasia, squamous cell carcinoma, β -cell non-Hodgkin lymphoma, adenoid cystic carcinoma and malignant melanoma. They determined that five males and three females had malignant lesions. Squamous cell carcinoma was the most often encountered malignant lesion (SCC).

Tanna et al. ^[21] has described a minimally invasive endoscopic method for this with equivalent efficacy and decreased morbidity. The majority of patients had FESS (transnasal

endoscopic sinus surgery) in conjunction with medial maxillectomy. There were no perioperative problems seen in their investigation. Following review of the study's findings, the following clinical implications were noted: patients had a shorter hospital stay. Additionally, it was described by Sautter et al.^[22]. Endoscopic surgery was identified as the preferred surgical method for sinonasal inverted papillomas, as validated by global standards. It was the benchmark for treating such lesions, with a significantly lower recurrence rate than external methods. Furthermore, various reasons for a pure endoscopic approach to sinonasal diseases were described in the literature in this investigation. The benefits mentioned included eliminating face incision and thereby limiting scar formation, as well as little pain and swelling. In comparison to open surgery, patients did not have dysesthesia.

A definitive diagnosis based on CT and MRI imaging is required, to surgically treat sinonasal inverted papilloma (IP). In the investigation of Hameed et al.^[13], without much effort, sinonasal IP might be successfully treated with EMMM (endoscopic modified medial maxillectomy). EMMM provides excellent visibility and maneuverability. As a result, EMMM was deemed a very favourable technique for the treatment of sinonasal IP. Endoscopic techniques, particularly in Dacryo-Cysto-Rhinostomy, fronto-ethmoidectomy, and medial maxillectomy, prevent scarring, external incisions, and disfigurement. Rhinosporidiosis was most frequently observed in the inferior meatus, nasal septum, and turbinates, as well as the posterior choana. All lesions are removed, and the pedicle cauterised for improved visualisation, ensuring that remaining lesions and recurrence are uncommon. Rhinosporidiosis is defined by polypoid, papillomatous lesions of the mucosa that are friable, painless and bleeding to the touch. The most frequent form is septum implantation, which causes nasal obstruction, epistaxis, and mucopurulent rhinorrhea. The therapy is generally agreed upon to be thorough surgical excision of the lesion and cauterization of its peduncle^[23].

Gotlib et al.^[24] According to their 5-year study, disease-specific survival with endoscopic endo nasal surgery was 91.4 %, indicating that endoscopic surgery was optimal. By contrast, the prevalence of intra-orbital problems and sinonasal disease invasion was shown to range between 3.7 and 47.6 % by Clayman et al.^[25] Vairaktaris, Marilita et al.^[26] noticed intracranial invasion of sinonasal illnesses and associated neoplasia in more than 5.8 % of their patients. In the study of Hameed et al.,^[13] In 2% of individuals, intra orbital complications were detected in the form of orbital cellulitis alone. Likewise, although the incidence of mucormycosis was not determined in this study, a review of the literature indicates that its prevalence ranges between 8.1 and 11.24 %, as Patel et al.^[27] observed.

Conclusions:

Inflammatory disease was found in 67 patients, benign tumor was found in 27 patients and malignant tumor in 8 patients. The most prevalent disease in inflammatory group was inflammatory sinusitis (37.3%), the most common disease in benign group was Inverted papilloma (51.9%) & the most common disease in malignant group was adenomyotic carcinoma (25%), low-grade mucoepidermoid carcinoma (25%) and mucoepidermoid carcinoma high grade (25%). Histopathology confirmation should be kept for dubious instances exclusively. Unilateral nasal polyps are associated with a high rate of malignancy and should be carefully examined using endoscopy and histology.

Ethical Approval:

As per international standard or university standard written ethical approval has been collected and preserved by the author(s).

Consent

As per international standard or university standard, patients' written consent has been collected and preserved by the author(s).

References

1. Tritt S, McMains KC, Kountakis SE. Unilateral nasal polyposis: clinical presentation and pathology. *Am J Otolaryngol.* 2008;29:230-2.
2. Calus L, Van Bruaene N, Bosteels C, Dejonckheere S, Van Zele T, Holtappels G, et al. Twelve-year follow-up study after endoscopic sinus surgery in patients with chronic rhinosinusitis with nasal polyposis. *Clin Transl Allergy.* 2019;9:30.
3. Uysal I, Misir M, Polat K, Altuntaş EE, Atalar MH, Tuncer E, et al. Primary malignant melanoma of the nasal cavity. *J Craniofac Surg.* 2012;23:e2-5.
4. Alshoabi SA, Binnuhaid AA, Gameraddin MB, Alsultan KD. Histopathological analysis of sinonasal lesions associated with chronic rhinosinusitis and comparison with computed tomography diagnoses. *Pak J Med Sci.* 2020;36:146-50.

5. Eid M, Eissa L. Imaging of sino-nasal inverted papilloma: How can we emphasize the usefulness of the “striated pattern” sign? Egyptian Journal of Radiology and Nuclear Medicine. 2020;51:1-16.

6. Sharma R, Sahni D, Uppal K, Gupta R, Singla G. A clinicopathological study of masses of nasal cavity paranasal sinuses and nasopharynx. *Int J Otorhinolaryngol Head Neck Surg.* 2017;3:253-8.
7. Bakari A, Afolabi OA, Adoga AA, Kodiya AM, Ahmad BM. Clinico-pathological profile of sinonasal masses: an experience in national ear care center Kaduna, Nigeria. *BMC Res Notes.* 2010;3:186.
8. Bist SS, Varshney S, Baunthiyal V, Bhagat S, Kusum A. Clinico-pathological profile of sinonasal masses: An experience in tertiary care hospital of Uttarakhand. *Natl J Maxillofac Surg.* 2012;3:180-6.
9. Lathi A, Syed MM, Kalakoti P, Qutub D, Kishve SP. Clinico-pathological profile of sinonasal masses: a study from a tertiary care hospital of India. *Acta Otorhinolaryngol Ital.* 2011;31:372-7.
10. Gupta R, Moupachi SS, Poorey VK. Sinonasal masses: a retrospective analysis. *Indian J Otolaryngol Head Neck Surg.* 2013;65:52-6.
11. Nair S, James E, Awasthi S, Nambiar S, Goyal S. A review of the clinicopathological and radiological features of unilateral nasal mass. *Indian J Otolaryngol Head Neck Surg.* 2013;65:199-204.
12. Wong JS, Hoffbauer S, Yeh DH, Rotenberg B, Gupta M, Sommer DD. The usefulness of routine histopathology of bilateral nasal polyps - a systematic review, meta-analysis, and cost evaluation. *J Otolaryngol Head Neck Surg.* 2015;44:46.
13. A S, R.T A, Dilna D. A Cross Sectional Study of Sinonasal Pathologies and Their Endoscopic Surgical Management. *Journal of Evidence Based Medicine and Healthcare.* 2020;7:2442-7.
14. Lee JY. Unilateral paranasal sinus diseases: analysis of the clinical characteristics, diagnosis, pathology, and computed tomography findings. *Acta Otolaryngol.* 2008;128:621-6.

15. Rudralingam M, Jones K, Woolford TJ. The unilateral opaque maxillary sinus on computed tomography. *Br J Oral Maxillofac Surg.* 2002;40:504-7.
16. Kandukuri R, Phatak S. Evaluation of Sinonasal Diseases by Computed Tomography. *J Clin Diagn Res.* 2016;10:Tc09-tc12.
17. Gomaa MA, Hammad MS, Abdelmoghny A, Elsherif AM, Tawfik HM. Magnetic resonance imaging versus computed tomography and different imaging modalities in evaluation of sinonasal neoplasms diagnosed by histopathology. *Clin Med Insights Ear Nose Throat.* 2013;6:9-15.
18. Chow JM, Leonetti JP, Mafee MF. Epithelial tumors of the paranasal sinuses and nasal cavity. *Radiol Clin North Am.* 1993;31:61-73.
19. Chavan SS, Deshmukh S, Pawar V, Sarvade K, Kirpan V, Kumbhakarna N, et al. Case study of clinicopathological correlation of benign sinonasal masses. *World Articles Ear Nose Throat.* 2012;5.
20. Belli S, Yildirim M, Eroglu S, Emre FK. Single-sided sinonasal mass: A retrospective study. *North Clin Istanbul.* 2018;5:139-43.
21. Tanna N, Edwards JD, Aghdam H, Sadeghi N. Transnasal endoscopic medial maxillectomy as the initial oncologic approach to sinonasal neoplasms: the anatomic basis. *Archives of Otolaryngology–Head & Neck Surgery.* 2007;133:1139-42.
22. Sautter NB, Cannady SB, Citardi MJ, Roh HJ, Batra PS. Comparison of open versus endoscopic resection of inverted papilloma. *Am J Rhinol.* 2007;21:320-3.
23. Nicolai P, Berlucchi M, Tomenzoli D, Cappiello J, Trimarchi M, Maroldi R, et al. Endoscopic surgery for juvenile angiofibroma: when and how. *Laryngoscope.* 2003;113:775-82.

24. Gotlib T, Osuch-Wójcikiewicz E, Held-Ziółkowska M, Kuźmińska M, Niemczyk K. Endoscopic transnasal management of sinonasal malignancies - our initial experience. *Wideochir Inne Tech Maloinwazyjne*. 2014;9:131-7.
25. Clayman GL, Adams GL, Paugh DR, Koopmann CF, Jr. Intracranial complications of paranasal sinusitis: a combined institutional review. *Laryngoscope*. 1991;101:234-9.
26. Vairaktaris E, Moschos MM, Vassiliou S, Baltatzis S, Kalimeras E, Avgoustidis D, et al. Orbital cellulitis, orbital subperiosteal and intraorbital abscess: report of three cases and review of the literature. *J Craniomaxillofac Surg*. 2009;37:132-6.
27. Patel A, Kaur H, Xess I, Michael JS, Savio J, Rudramurthy S, et al. A multicentre observational study on the epidemiology, risk factors, management and outcomes of mucormycosis in India. *Clin Microbiol Infect*. 2020;26:944.e9-.e15.