

Comparative study on Hair Transplantation with or without Platelets Rich Plasma Effect in Treatment of Cicatricial Alopecia

Abstract

Background and aim: Scarring is an important clinical problem that occurs because of skin damage. Each year, around 100 million individuals in the Western world develop new scars, some of which pose substantial issues for those who are affected. The purpose of this work was to compare the effect of platelets rich plasma (PRP) on hair transplantation in treatment of cicatricial alopecia

Methods: This randomized control study was performed on 45 cases with 2ry cicatricial alopecia. The alopecic area of each patient was divided into two halves: 1st half (A) [hair transplantation without PRP injection] and 2nd half (B) [hair transplantation after intradermal injection of autologous PRP in recipient site intra-operative and two weeks postoperative]. Each patient was submitted to general examination, local examination of the donor and recipient sites, and laboratory investigations.

Results: Our study suggests that it after hair transplantation is an effective treatment for cicatricial alopecia (CA).

Conclusion: PRP has a high concentration of growth factors such as platelet-derived growth factor, vascular endothelial growth factor, and epidermal growth factor. Our study suggests that PRP is an effective treatment for CA.

Keywords: Platelet rich plasma, Hair Transplantation, Transforming growth factor, Vascular endothelial growth factor, Cicatricial Alopecia.

UNDER PEER REVIEW

Introduction

Scarring is an important clinical issue that occurs because of skin injury. Each year, around 100 million individuals in the Western world develop new scars, some of which pose substantial problems for those who are affected. Visible hairless scars on the scalp caused by tumor removal, trauma, or other surgical procedures may be noticeable even if they are narrow ^[1].

Reconstruction of scalp hair, frontal hairline, brows, eyelashes, moustache, side locks, or a beard around the chin animates the face, instils confidence, and interrupts the cycle of self-pity by providing a sense of completion and camouflage scars. Hair transplantation may be done alone or in combination with other reconstructive treatments. Hair transplants for scar camouflage were first utilized in the 1970s. During this time punch grafting was used as a therapy procedure. Standard punch grafting is what caused the look of "doll's hair" in general ^[2].

Hair transplantation has improved over the years, and the present technique of employing follicular unit grafts has resulted in very natural-looking restorations for a range of regions, including the scalp, eyebrows, eyelashes, and beard regions. Hair may be obtained for facial hair transplants from the occipital and temporal regions, the same donor location utilized for scalp restoration ^[3].

Platelet-rich plasma (PRP) is a plasma derivative that includes a high concentration of platelets approximately five times that of normal plasma (1,000,000 platelets/L on 5 mL plasma). Numerous experimental and clinical research have utilized autologous PRP because of its benefits in stimulating angiogenesis and cell proliferation and improving healing. Platelets in blood plasma include three types of growth factors: platelet-derived growth factor (PDGF), vascular endothelial growth factor (VEGF), and transforming growth factor (TGF). These are protein molecules that, in contact

with their respective receptors, act in tissue angiogenesis, stimulating the healing and growth of new organic structures ^[4]. This experiment aimed to compare the efficacy of PRP on hair transplantation in the management of cicatricial alopecia.

Patients and Methods

This randomized control study was performed on 45 patients with 2^{ry} cicatricial alopecia at The Plastic and Reconstructive Surgery Department, Tanta University Hospitals from January 2019 to January 2020, after approval of the study by the local ethical committee and obtaining written fully informed consent from the patients.

Patients with 2^{ry} cicatricial alopecia in hair bearing skin and patients with any type of hair (silky, curly or normal hair) were included in the study.

Patient with general debilitating diseases as diabetes or autoimmune diseases, patients with active skin diseases in recipient or donor sites, patients with no available donor sites and patients older than 50 years were excluded.

The alopecic area of each patient was approximately divided into two halves. The 1st half (A) received hair transplantation without PRP injection, and the 2nd half (B) received hair transplantation after intradermal injection of autologous platelet rich plasma (PRP) in the recipient site intra-operatively and two weeks postoperative.

Each patient underwent general examination, local examination of the donor and recipient sites, laboratory investigations.

Statistical analysis

SPSS version 23 (SPSS Inc., Chicago, IL) was used to assemble and analyze the data. Means (standard deviation [SD]) were used to present continuous variables, whereas relative frequency distributions and percentages were used to depict categorical variables. The Man-Whitney test was used to compare continuous variables. Statistical significance established at $p \leq 0.05$.

Results

Most of patients had injection at anterior half of scar (53.3%), then posterior part of scar (31.11%). Mean number of transplanted hair (1.36 ± 0.24 hair) ranged from (1-2 hair). Most common site of cicatricial was left side of the face (51.11%), then anterior scalp (20%), posterior scalp (22.22%) and right checks (6.7%). Most of cases due to old trauma (82.22%) and only two cases were due to burn (17.78%) as shown in **Table 2 and Fig 1-4**.

Table 1: Disease characteristics of patients.

Characteristics	(N=45)
Site of injection	
Anterior half of scar	24 (53.3%)
Posterior part of scar	14(31.11%)
Right check "anterior 1/2	3(6.7%)
Right eyebrow	1(2.22%)
Left half of scar	3(6.7%)
Site of cicatricial alopecia	
Left side of the face	23(51.11%)
Anterior scalp	9(20%)
Posterior scalp	10(22.22%)
Right check	3(6.7%)
Cause of cicatricial alopecia	
Old trauma	37(82.22%)
Burn	8(17.78%)

Data are expressed as number and percentage.

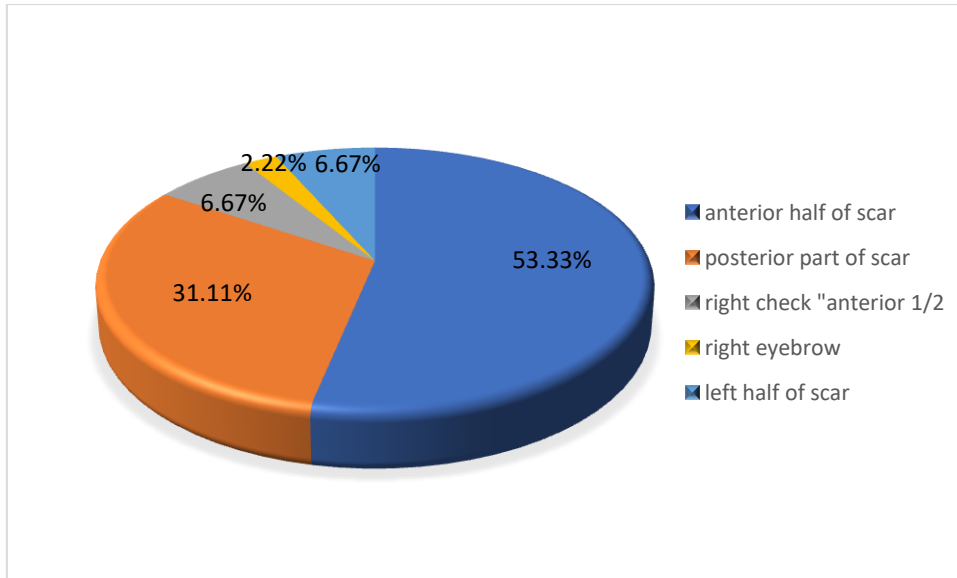


Figure 1: Sites of injection

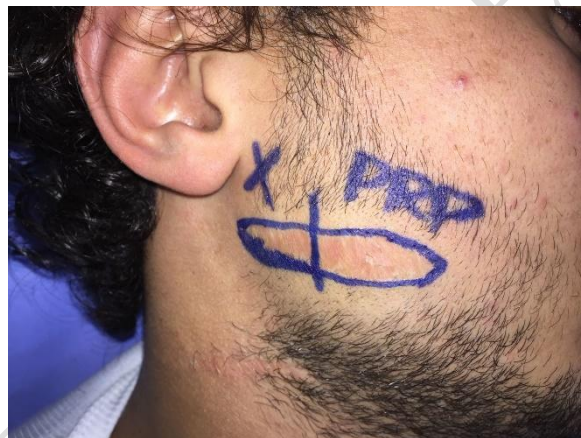

Figure 2: Sites of injection. Blue: without PRP, Red: with PRP

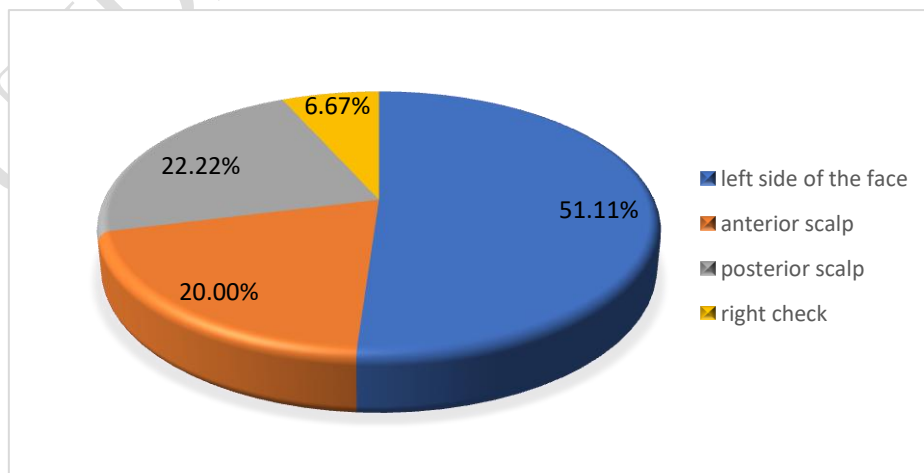


Figure 3: Site of Cicatricial alopecia

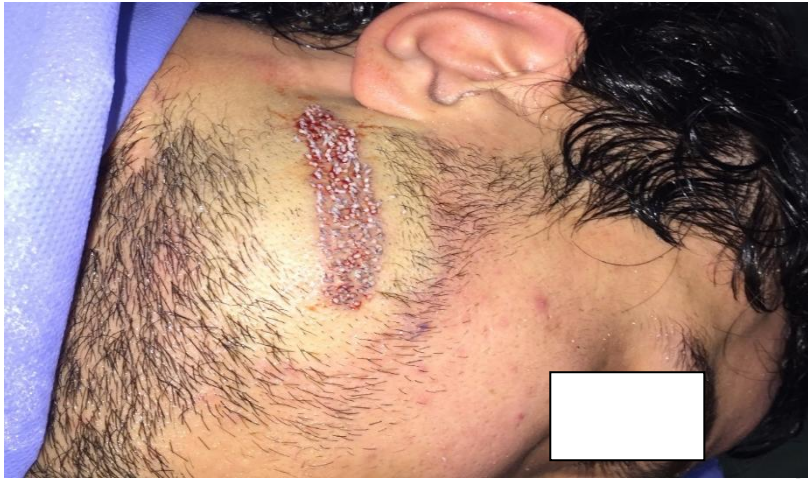

Figure 4: Site of Cicatricial alopecia after complete hair transplantation at the site of cicatricial alopecia

Post operatively, patients had mean hair count of $(14.89 \pm 3.37 \text{ hair})$, mean hair density of $(22.2 \pm 4.52 \text{ mm})$ as shown in **table 3 and Fig 5 - 8**.

Table 2: Postoperative hair characteristics.

Characteristics	(N=45)
Hair count	
(Mean \pm SD)	14.89 ± 3.37
Range	(10-20)
Hair density	
(Mean \pm SD)	22.2 ± 4.52
Range	(15-30)

Data are expressed as mean \pm standard deviation and range.

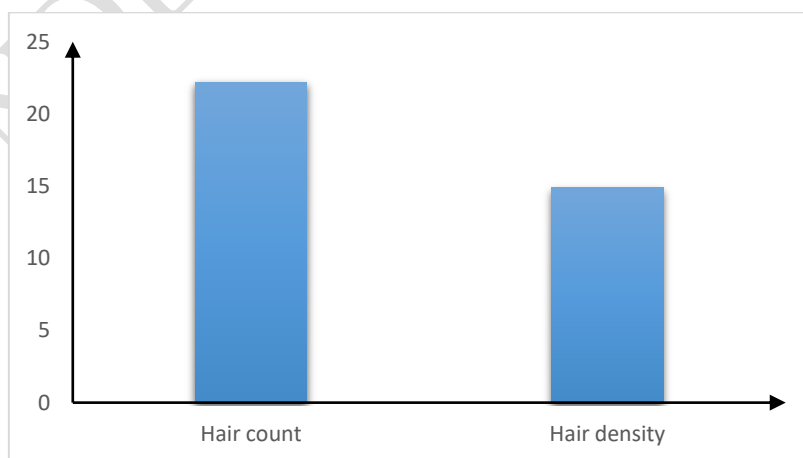


Figure 5: Postoperative hair characteristics.

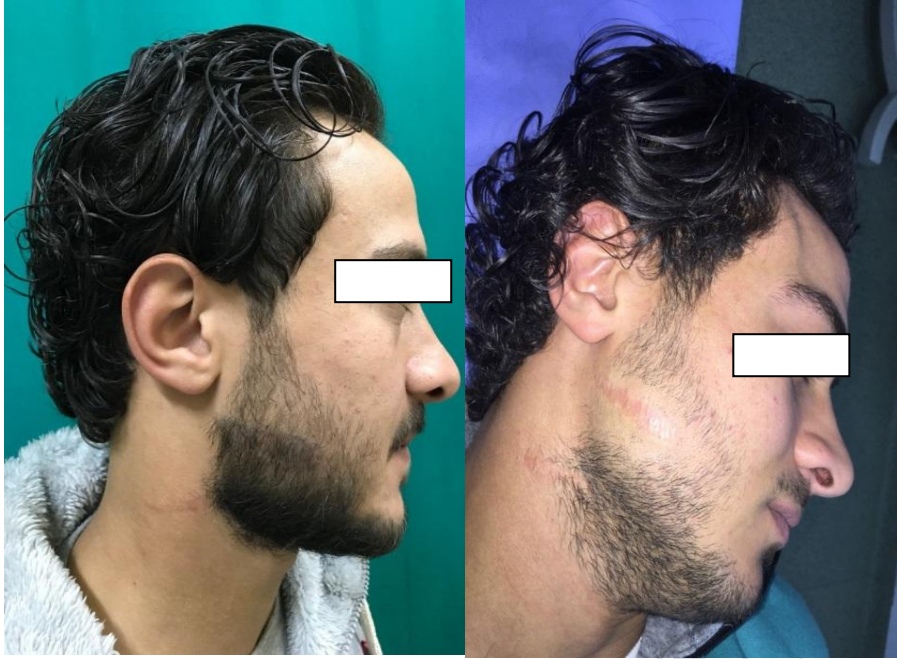

Figure 6: Pre and postoperative patient after hair transplantation.

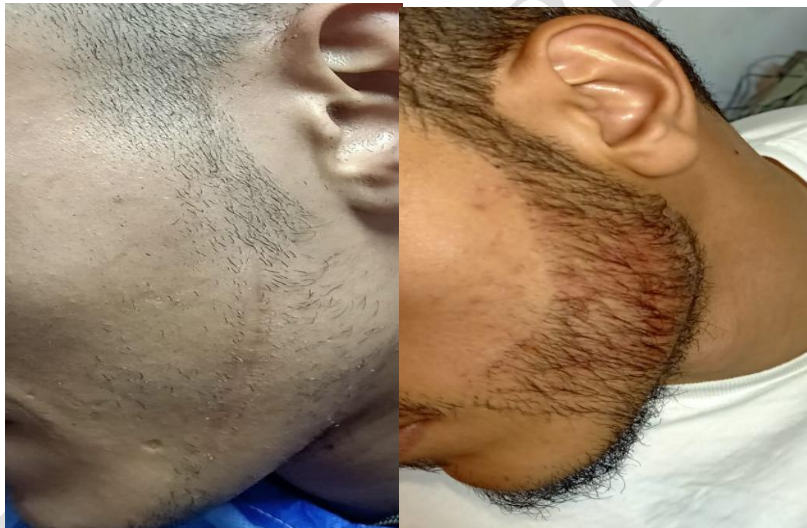

Figure 7: Pre and Postoperative patient after hair transplantation.

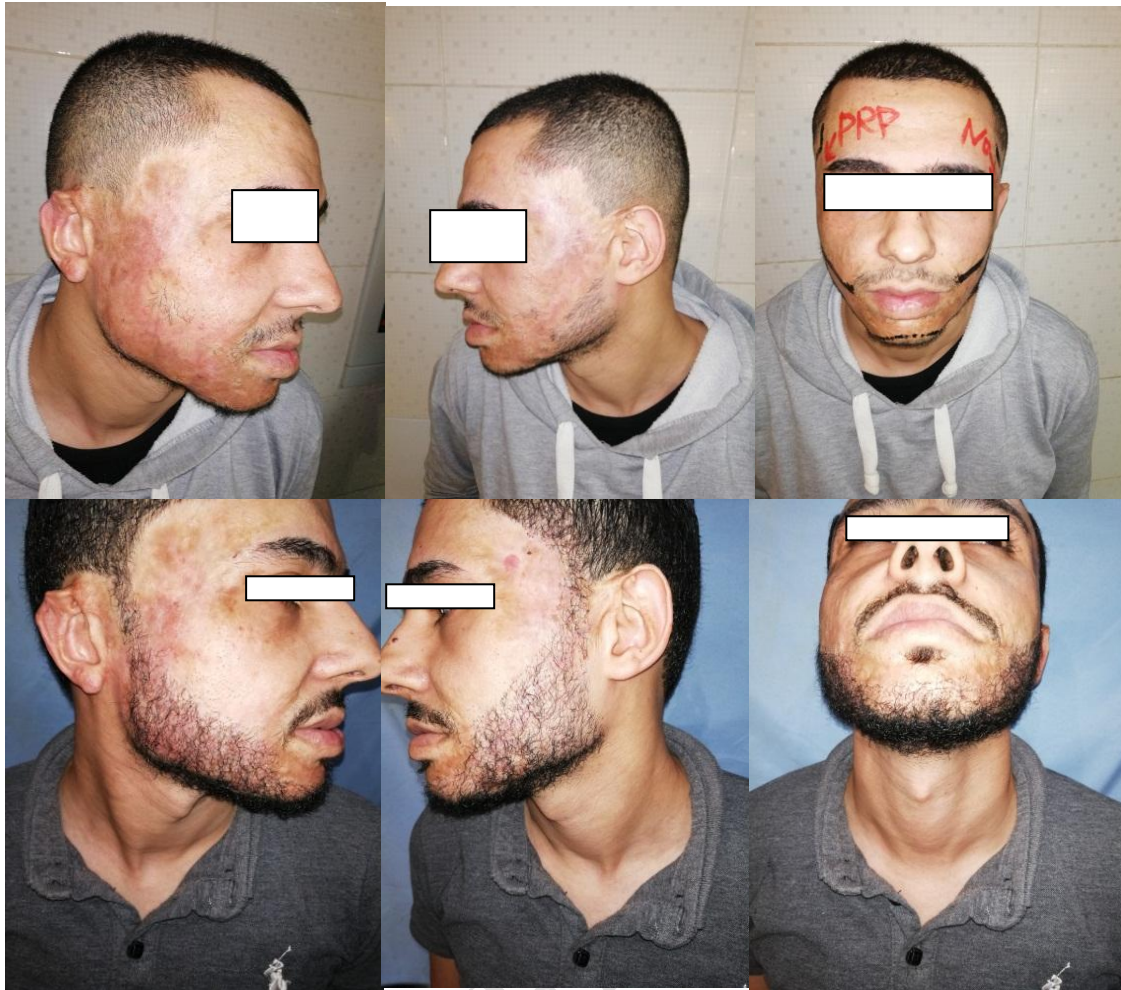

Figure 8: Pre and Postoperative patient after hair transplantation

The mean hair count was significantly higher among group B (17.5 ± 3.5 hair) than group A (11.8 ± 0.71 hair) ($P=0.012$). Also, mean hair density was significantly higher among group B (27.5 ± 3.4 mm) than group A (15.4 ± 0.6 mm) ($p<0.001$). So PRP is better or there is no difference between these results as shown in **table 3 and fig 9**.

Table 3: Postoperative hair characteristics in both groups.

	Group (A) (N=45)	Group (B) (N=45)	P-value
Hair count	11.8 ± 0.71	17.5 ± 3.5	0.012*¹
Hair density	15.4 ± 0.6	27.5 ± 3.4	<0.001*

Data are expressed as mean \pm standard deviation, 1: Man-Whitney test used, *: significant as $p<0.05$.

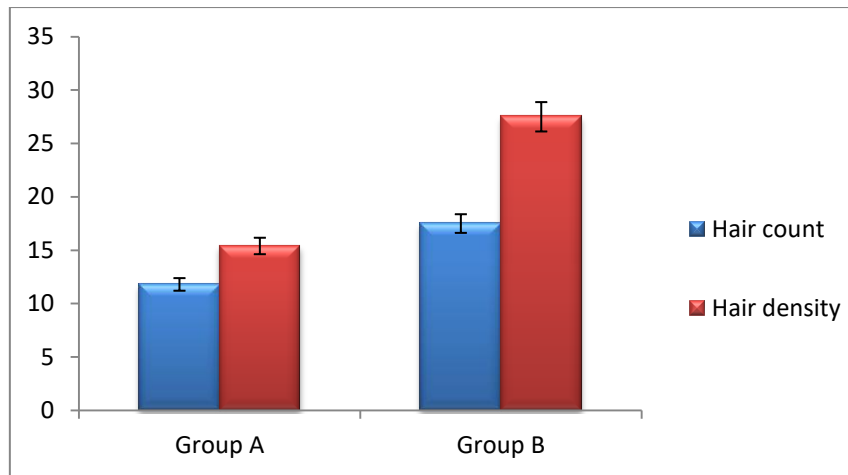


Figure 9: post-operative hair characteristics in both groups.

Discussion

Cicatricial alopecia refers to a group of skin disease that eventually result in the irreversible loss of pigmented terminal hairs. They may cause physical discomfort as well as significant emotional and psychological distress in individuals. For many patients, obtaining effective and safe medical treatment is a difficulty ^[5].

Surgical hair restoration can be an excellent reconstructive option, but many patients have limited donor resource from extensive hair loss affecting the donor region limiting the role of hair restoration surgery ^[6].

(PRP) provides patients with a possible new therapy alternative for scarring alopecia ^[7].

Our patients had mean age of 27.4 ± 7.7 with male predominance (86.7%). They had mean age of disease onset of 22.8 ± 7.2 and mean age at diagnosis of disease of 27 ± 7.6 , while had a mean duration of disease of 4.8 ± 2.3 years.

This agrees with 2017 International Society of Hair Restoration Surgery (ISHRS) practice census results, 597,181 patient hair transplant surgeries were performed over the globe. Between the ages of 30 and 50, 85.7 % of patients were males and 14.3 % were women ^[8].

Our study found that the most common site of Cicatricial was left side of the face (51.11%), then anterior scalp (20%), posterior scalp (22.22%) and right checks (6.7%). Most of cases due to old trauma (82.22%) and only two cases were due to burn (17.78%).

In agreement with **Su et al.**,^[9] study who reported that Secondary cicatricial alopecia may be triggered by a numerous of cutaneous inflammatory processes or by physical trauma to the skin and its appendages.

In our study, group A of hair transplantation had a mean hair count of (11.8 ±0.71), mean hair density of (15.4 ±0.6) and a mean hair diameter of (0.57±0.47).

In a recent review which reported that, Although hair growth was initially great in patients who had successfully endured at least two years of stable illness after hair transplantation, recipient dominance resulted in graft site recurrence in many instances by four years post-transplant^[6].

PRP is a biological product defined as a component of the plasma fraction of autologous blood with a platelet concentration greater than the pre-centrifugation baseline. Consequently, PRP includes not only a high concentration of platelets, but also a full complement of clotting factors loaded with a variety of growth factors believed to encourage hair growth. Although not fully understood, the proposed mechanism of action of PRP is as follows: Platelet activation with thrombin or calcium chloride Degranulation of platelets Growth factors are released Increase dermal papilla cell proliferation by activating extracellular-regulated kinase and Akt signaling Anti-apoptotic properties^[7].

Our study found that, the mean hair count was significantly higher among PRP group (17.5 ± 3.5) than hair transplantation group (11.8 ±0.71) (P=0.012). Also, mean hair density was significantly higher among PRP group (27.5 ± 3.4) than hair

transplantation group (15.4 ± 0.6) ($p < 0.001$). While hair diameter showed insignificant difference between both groups ($p = 1.00$).

In agreement with Dina, et al. ^[10] study, who noticed a general improvement in hair density following PRP treatment in both patients with cicatricial alopecia. Considering the etiology of PCAs, numerous properties of PRP may contribute to a favorable therapy response. To begin, PRP has been shown to increase beta catenin's transcriptional activity, resulting in the differentiation of stem cells into hair follicle cells.¹ Additionally, PPR generates increased expression of MMP-1 and MMP-3, which degrades damaged extracellular matrix and stimulates the synthesis of new collagen via enhanced procollagen type 1.1 production. Additionally, PRP platelet granules include anti-inflammatory, proangiogenic cytokines like as TGF- β and TGF- β 1, which may contribute to PRP's efficiency in PCAs. ¹

Also, Alves et al. ^[7] reported that PRP has been shown to be helpful in treating androgenetic alopecia (AGA) in ten of twelve researches, with 6 of those studies exhibiting a statistically significant improvement in objective measures such as improved hair thickness and increased hair number following PRP therapy ^[11, 12].

Four additional studies showed hair improvement (e.g., hair density, diameter) with PRP, although no p -values or statistical analysis was described ^[13, 14].

Although Alves et al. ^[7] suggested that PRP is a potential treatment option for AGA.

Conclusion

Platelet-rich plasma is rich in growth factors such as PDGF, (VEGF), and epidermal growth factor. Our study suggests that it after hair transplantation is an effective treatment for Cicatricial alopecia.

COMPETING INTERESTS DISCLAIMER:

Authors have declared that no competing interests exist. The products used for this research are commonly and predominantly used products in our area of research and country. There is absolutely no conflict of interest between the authors and producers of the products because we do not intend to use these products as an avenue for any litigation but for the advancement of knowledge. Also, the research was not funded by the producing company rather it was funded by personal efforts of the authors.

References

1. Rongioletti F, Christana K. Cicatricial (scarring) alopecias: an overview of pathogenesis, classification, diagnosis, and treatment. *Am J Clin Dermatol.* 2012;13:247-60.
2. Unaeze J, Ciocon D. Hair transplantation. *Evidence-Based Procedural Dermatology: Springer NY;* 2012. p. 377-92.
3. Lam S. Hair Restoration. 2013. p. 517-38.
4. Le ADK, Enweze L, DeBaun MR, Dragoo JL. Platelet-Rich Plasma. *Clin Sports Med.* 2019;38:17-44.
5. Callender VD, Reid SD, Obayan O, McClellan L, Sperling L. Diagnostic Clues to Frontal Fibrosing Alopecia in Patients of African Descent. *J Clin Aesthet Dermatol.* 2016;9:45-51.
6. Ekelem C, Pham C, Atanaskova Mesinkovska N. A Systematic Review of the Outcome of Hair Transplantation in Primary Scarring Alopecia. *Skin Appendage Disord.* 2019;5:65-71.
7. Alves R, Grimalt R. A Review of Platelet-Rich Plasma: History, Biology, Mechanism of Action, and Classification. *Skin Appendage Disord.* 2018;4:18-24.
8. Puig CJ, Beehner ML, Cotterill PC, Elliott VW, Haber RS, Harris JA, et al. Core competencies for hair restoration surgeons

- recommended by the International Society of Hair Restoration Surgery. *Dermatol Surg.* 2009;35:425-8.
9. Su HJ, Cheng AY, Liu CH, Chu CB, Lee CN, Hsu CK, et al. Primary scarring alopecia: A retrospective study of 89 patients in Taiwan. *J Dermatol.* 2018;45:450-5.
10. Dina Y, Aguh C. Use of Platelet-Rich Plasma in Cicatricial Alopecia. *Dermatol Surg.* 2019;45:979-81.
11. Dhana A, Gumedze F, Khumalo NP. Regarding 'Frontal fibrosing alopecia: possible association with leave-on facial skincare products and sunscreens; a questionnaire study'. *Br J Dermatol.* 2017;176:836-7.
12. Lin WH, Xiang LJ, Shi HX, Zhang J, Jiang LP, Cai PT, et al. Fibroblast growth factors stimulate hair growth through β -catenin and Shh expression in C57BL/6 mice. *Biomed Res Int.* 2015;2015:730139.
13. Anitua E, Pino A, Martinez N, Orive G, Berridi D. The Effect of Plasma Rich in Growth Factors on Pattern Hair Loss: A Pilot Study. *Dermatol Surg.* 2017;43:658-70.
14. Kumaran MS. Platelet-rich plasma in dermatology: boon or a bane? *Indian J Dermatol Venereol Leprol.* 2014;80:5-14.