

Presentation of Small Bowel Volvulus in East Africa

Richard Wismayer^{1,2}

¹Department of Surgery, Habib Medical School, IUIU University, Kampala, Uganda

²Department of Surgery, Masaka Regional Referral Hospital, Masaka, Uganda

Corresponding author: Richard Wismayer^{1,2};

ABSTRACT

Introduction: A benign gastrointestinal surgical condition involving torsion of part or all of a segment of small bowel on its mesenteric axis is small bowel volvulus (SBV). The clinical presentation is similar to acute mesenteric ischaemia and hence a preoperative clinical diagnosis is difficult to obtain. In developing countries, as a presenting surgical cause of small bowel obstruction it has contributed to a significant burden. The aim of this case report was to discuss a typical case of small bowel volvulus in a developing country and highlight the importance of resuscitation and early surgical intervention.

Presentation of case: A 35 year old lady admitted to hospital with a 3 day history of colicky central abdominal pain. She reported a long period of fasting and sudden ingestion of food. On physical examination her abdomen was moderately distended with minimal tenderness. Laboratory investigations were normal and a plain abdominal X-ray revealed features suggestive of small bowel obstruction. After resuscitation the patient was taken for a laparotomy where evidence of SBV was found. An omental band adhesion was divided, the volvulus untwisted and the small bowel was all viable. The patient made an uneventful postoperative recovery.

Discussion: The incidence of SBV is higher in Africa, Asia and the Middle East compared to the Western world. Secondary SBV is more commonly found in older age groups however primary SBV is more common in children. The most common complaints of SBV includes abdominal pain, abdominal distention and vomiting. The mortality rate due to SBV has been found to be decreasing with early diagnosis due to abdominal CT scanning. This reduction in mortality is due to a reduction in the incidence of gangrene of the SBV.

Conclusions: Due to the high mortality and variable presentation, surgeons must consider small bowel volvulus a probably diagnosis in a patient with abdominal pain and features of small bowel obstruction. Early surgical intervention is necessary to reduce the morbidity and mortality from SBV.

Keywords: Small bowel volvulus; abdominal pain; small bowel obstruction; Africa

Introduction

A rare cause of mechanical small bowel obstruction is small bowel volvulus. The origin of the word volvulus means to roll or turn and is derived from the Latin word 'volvere'. The incidence rate of small bowel volvulus is low (1.7-5.7 per 100,000 populations) in the Western world however high (24-60 per 100,000 populations) in Africa, Middle Eastern countries and Asia (1). Small bowel volvulus is defined as a benign gastrointestinal surgical condition involving torsion of parts or all of a segment of small bowel on its mesentery (2). The presumed factors

responsible for primary small bowel volvulus include absence of mesenteric fat, mobility of the small bowel, unusual length of the small bowel segment, constipation or diarrhoea, physical exercise and laxity of the abdominal wall (2-5). Secondary small bowel volvulus may occur due to the presence of acquired underlying conditions such as bands, postoperative adhesions, pregnancy, diverticular disease and tumours (2).

Malrotation of the small bowel and defective fixation of the mesentery may result in neonatorum volvulus (5). Therefore depending on the aetiology, small bowel volvulus may be primary or secondary. Small bowel volvulus should be suspected in patients presenting with central abdominal pain following a meal which is resistant to opioid analgesia and with severity which is out of proportion to clinical examination should raise suspicion of small bowel volvulus (6,7). Since making a clinical diagnosis at presentation is difficult then an abdominopelvic CT scan is the investigation of choice and may demonstrate the “whirl sign” (8-10). Prevention of bowel necrosis and the resultant increased morbidity and mortality may be prevented with early diagnosis and urgent surgical intervention (8,10). The mortality rate for small bowel volvulus with viable bowel is 20-25% in Africa and India whilst in the Western world the mortality is 3-13%. The mortality rate has been reported to be in the range of 20-100% with gangrenous small bowel (11). A 35-year old lady presenting with small bowel volvulus to our hospital and experiencing early surgical intervention with a favourable prognosis is reported.

Case Presentation

A 35-year old lady from Masaka presented to the Casualty Department of Masaka Regional Referral Hospital with a 3-day history of colicky central abdominal pain. Masaka Regional Referral Hospital is located in the city of Masaka in South-Central Uganda and is the Regional Referral Hospital for many surrounding districts in the region.

She had been admitted to hospital on three occasions for the same complaint. She reported a long period of fasting and sudden ingestion of food. The only past medical history was a previous laparotomy for a torsed ovarian cyst. She also recently had a gastroduodenoscopy 6 months ago which revealed evidence of gastritis and gastric erosions and is currently on omeprazole. On physical examination her vitals were stable apart from a tachycardia of 110 beats per minute. The abdomen was moderately distended with minimal tenderness and high pitched bowel sounds. On digital rectal examination an empty rectum was evident without soling of the examining finger. All haematological, electrolytes, renal function tests, liver function tests were within normal range. A plain abdominal radiograph revealed multiple air fluid levels centrally which are features suggestive of small bowel obstruction.

The patient had an NG tube and urinary catheter inserted and was started on intravenous Ringer’s lactate. Whilst on the surgical ward 6 hours later the patient developed worsening abdominal pain and the bowel obstruction did not resolve.

After resuscitation, this patient was consented for an exploratory laparotomy. At laparotomy, the ileum was found to be twisted in a clockwise direction along its mesenteric axis with an omental band adhesion. No evidence of any bowel perforation was found and the proximal ileum and

jejunum was distended whilst the large bowel distal to the site of twisting was found to be collapsed. The omental band adhesion was divided and the volvulus was untwisted.

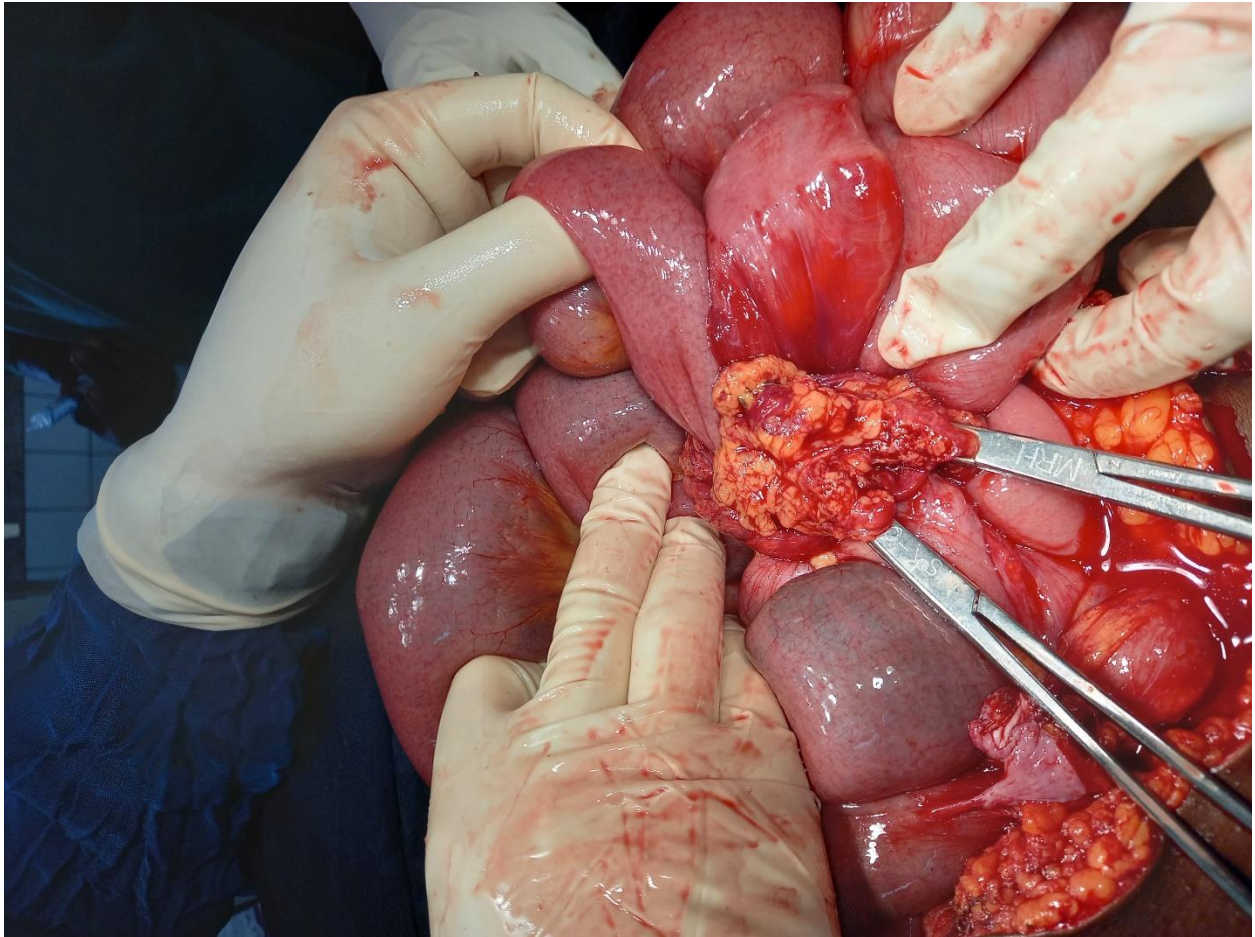


Figure 1: Small bowel volvulus found at laparotomy

There was no fixation of the twisted segment done and the small bowel was viable. At laparotomy there was no evidence of malrotation or internal hernias. The patient made an uneventful postoperative recovery on the surgical ward and was discharged on the 5th postoperative day.

Figure 1 and figure 2 show the findings at laparotomy with an omental band adhesion responsible for the twist in small bowel. The small bowel is viable with no evidence of ischaemia or gangrene.

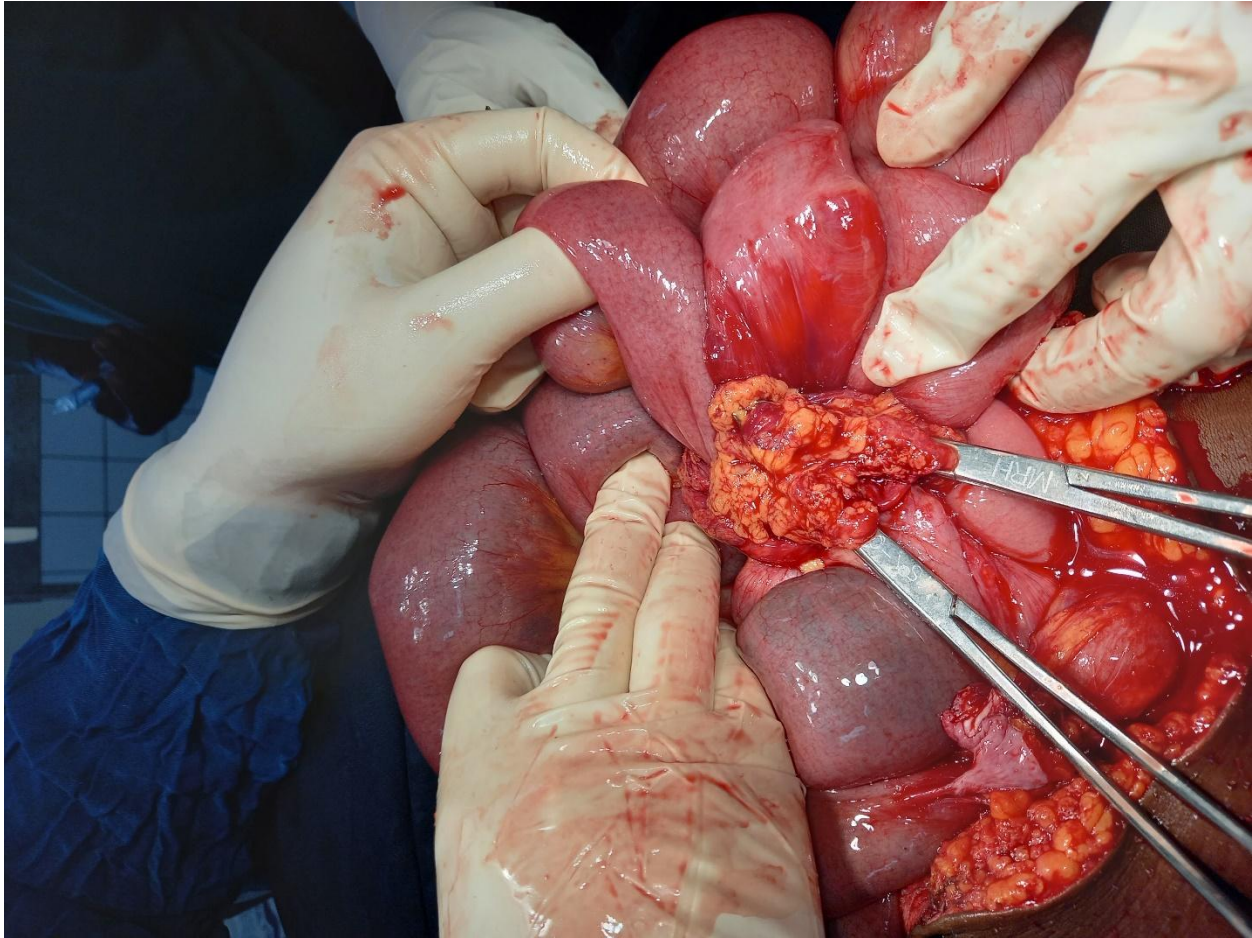


Figure 2: The twist in the small bowel caused by the omental band adhesion at laparotomy

Discussion

The patient reported in this report revealed a diagnosis of small bowel volvulus at laparotomy. Recurrent episodes of abdominal pain and the absence of CT scanning resulted in difficulty making a preoperative diagnosis. The long period of fasting followed by the sudden ingestion of food is a known predisposing factor for small bowel volvulus. This was most likely the precipitating factor in the reported patient.

The patient's past history of a laparotomy predisposed her to abdominal adhesions and an omental band adhesion was primarily responsible for the small bowel volvulus. This resulted in our patient presenting with a form of secondary small bowel volvulus. Following resuscitation this patient was taken for laparotomy and all the small bowel was found to be viable after release of the omental band adhesion. Had there been a delay in taking this patient for laparotomy then she would have developed bowel ischaemia and gangrene which would have been associated

with a poor prognosis. This patient made an uneventful postoperative recovery and was eventually discharged a few days later.

The incidence of small bowel volvulus is low in the Western World (1.7 – 5.7 per 100,000 populations) compared to 24-60 per 100,000 populations in Africa, Asia and the Middle East (1). Compared to African, Middle Eastern and Asian countries the annual occurrence of small bowel volvulus is low (2, 5, 11-15). The occurrence of small bowel obstruction has been found to account for 6.9% of all bowel obstructions and 0.6 case per year in a 57-year data review carried out in the USA (11). During the period 1930-1958 there was a reduction in the prevalence of small bowel volvulus from 6.9% to 3.3% (15). In Iran, Vaez-Zadeh et al., (1969) reported the incidence of small bowel volvulus causing small bowel obstruction was 41% (5).

Studies carried out in Ethiopia have reported that a sizeable portion of bowel obstruction is caused by small bowel volvulus, Demissie M et al., 2001 (41.7%) (2); Soressa K et al., 2016 (30.3%) (16); Gizaw TA et al., 2016 (36.4%) (17); Tegegne A et al., 1992 (18.3%) (18). In Nepal, 50% of bowel obstructions were found to be due to small bowel volvulus (4). Dietary factors may be responsible for the discrepancy in the prevalence of small bowel volvulus.

As a bulky bolus of food enters the proximal jejunum, a loop falls into the pelvis and the empty distal bowel loop rises into the right upper quadrant. A rapid emptying of the stomach causes the distal bowel to spread across the left upper quadrant. When the distal loop fills up a 360° twist takes place in the left upper quadrant (5). In developed countries, secondary small bowel volvulus is more common whilst in developing countries primary small bowel volvulus is more common (19). Studies in Uganda and Ethiopia have shown that primary small bowel volvulus accounts for 100% and 94.9% of small bowel volvulus respectively (2,14). Whilst studies in the UK and USA showed that 89% of small bowel volvulus was due to secondary small bowel volvulus (11,12). The risk factors documented in the literature are a bulky and poorly digestible diet taken at long intervals, hypermobility of the mesentery and hypermobility of the gut (2,11,12,20).

There has been speculation in the literature that African populations have long mesenteries which allow for an abnormal mobility of a segment or all of the small bowel. Therefore patients with volvulus have shorter mesenteric attachments and longer mesenteries when compared to normal individuals (5,22). The aetiology of primary small bowel volvulus is mainly due to diet. Following a period of fasting an abrupt change of dietary habit with the ingestion of a large amount of bulky food leads to an induction of forceful small bowel peristalsis and hence small bowel volvulus (11,12,20). Underlying identified predisposing conditions such as malrotation, midgut nonrotation, bands or postoperative adhesions may account for cases of secondary small bowel volvulus. In Western developed countries the prevalence of secondary small bowel volvulus is 70-90% of the total number of cases of small bowel volvulus (11).

Secondary small bowel volvulus is more commonly found in older age groups however primary small bowel volvulus is more common in children. Studies from different countries have shown that the mean age is 42 years in Iran, 34 years in Ethiopia, 67 years in the USA and 59 years in the UK (2,5,11,18). In developing countries the incidence of small bowel volvulus has a male predominance. The male:female ratio has been found to be 8.8:1 in Ethiopia, 9.25:1 in Iran, 1:1.2 in the USA and 1:1.12 in the UK (2,5,11,12). The discrepancy in sex may be due to a lax abdominal wall due to childbearing and a spacious female pelvis allowing for spontaneous

reduction of the volvulus (2,5,11). Small bowel volvulus tends to be more common in rural residents due to the consumption of a high fibre diet, long time fasting and more childbearing women) (18).

Abdominal pain which is out of proportion to physical findings may be the presentation of small bowel volvulus and this further complicates its differentiation from acute mesenteric ischaemia (23). The most common complaints of small bowel volvulus includes abdominal pain (94-100%), abdominal distention (55-100%) and vomiting (83-100%) (11). A study showed that the most frequent physical signs were visible peristalsis in 64.9% and abdominal tenderness in 85.1%. The morbidity and mortality associated with small bowel volvulus results when ischaemic gangrenous bowel develops. Access to healthcare facilities and early diagnosis determines the prevalence of gangrenous small bowel volvulus. The prevalence of gangrenous small bowel volvulus is 43% in the UK, 46% in the USA and 28.7% in Ethiopia (2,11,12). The high incidence of gangrenous small bowel volvulus reported in the USA and UK was in the 1950's and recently there has been an increase in early diagnosis through CT scanning, hence decreasing the prevalence of gangrenous small bowel volvulus.

An abdominal CT scan is the investigation of choice and may demonstrate the “whirl sign”, rotation of the mesentery and mesenteric vessels, dilated bowel loops and signs of intestinal ischaemia with the presence of gas in the portal vein, air in the bowel wall and free peritoneal fluid (1,21).

The mortality rate due to small bowel volvulus is decreasing due to early diagnosis and a reduction in the incidence of gangrene. However, small bowel volvulus still has a high mortality rate with reports showing a mortality of 13.3% in Ethiopia, 15% in Iran, 26% in Nepal, 9% in the USA and 28% in the UK (2,4,5,11,12).

Conclusions

Due to the high mortality and variable presentation, surgeons must consider small bowel volvulus as a probable diagnosis in a patient with abdominal pain and features of small bowel obstruction. A high index of clinical suspicion to identify small bowel volvulus is required. Early surgical intervention is required to reduce the morbidity and mortality of small bowel volvulus.

Consent

The author declares that written and informed consent was obtained from the patient for publication of this case report.

Ethical Approval

As per international standard or university standard, ethical approval has been collected and preserved by the author.

Acknowledgments

The author wishes to thank clinical staff in the Department of Surgery of Masaka Regional Referral Hospital for their contribution in data collection and their contribution towards the clinical management of the patient. The author also wishes to extend his warm thanks to nursing staff, medical officers and anesthesiologists who worked with him in the surgery theatres of Masaka Regional Referral Hospital.

Competing Interests

Author has declared that no competing interests exist.

References

1. Iwuagwu O, Deans GT. Small bowel volvulus: a review. *J R Coll Surg Edinb.* 1999;44:150–5.
2. Demissie M. Small intestinal volvulus in Southern Ethiopia. *East Afr Med J.* 2001;78(4):208–11. <https://doi.org/10.4314/eamj.v78i4.9065>.
3. Warambo MW. Acute volvulus of the small intestine. *East Afr MedJ.* 1971;48:209–12.
4. McDonald IO, Hawker DB. Small bowel volvulus - the commonest abdominal emergency in Nepal. *Bristol Med Chir J.* 1980;95(355-356):4–8.
5. Vaez-Zadeh K, Dutz W, Nowrooz-Zadeh M. Volvulus of the small intestine in adults: a study of predisposing factors. *Ann Surg.* 1969;169(2):265–71. <https://doi.org/10.1097/0000658-196902000-00014>.
6. Islam S, Hosein D, Dan D, *et al* Volvulus of ileum: a rare cause of small bowel obstruction. *Case Reports* 2016;2016:bcr2016216159.
7. Patial T, Chaddha S, Rathore N, Thakur V. Small Bowel Volvulus: A Case Report. *Cureus.* 2017 May 28;9(5):e1281. doi: 10.7759/cureus.1281. PMID: 28663941; PMCID: PMC5489345.
8. Katis PG, Dias SM. Volvulus: a rare twist on small-bowel obstruction. *CMAJ.* 2004;171:728.
9. Ruiz-Tovar J, Morales V, Sanjuanbenito A, Lobo E, Martinez-Molina E. Volvulus of the Small Bowel in Adults. *The American Surgeon.* 2009;75(12):1179-1182. doi:[10.1177/000313480907501206](https://doi.org/10.1177/000313480907501206).

10. Lepage-Saucier M, Tang A, Billiard JS, Murphy-Lavallée J, Lepanto L. Small and large bowel volvulus: Clues to early recognition and complications. *Eur J Radiol.* 2010 Apr;74(1):60-6. doi: 10.1016/j.ejrad.2009.11.010. Epub 2009 Dec 16. PMID: 20006456.
11. Roggo A, Ottinger LW. Acute small bowel volvulus in adults. A sporadic form of strangulating intestinal obstruction. *Ann Surg.* 1992;216(2):135-41. <https://doi.org/10.1097/00000658-199208000-00003>.
12. Frazee RC, Mucha P, Farnell MB, van Heerden JA. Volvulus of the small intestine. *Ann Surg.* 1988;208:565-8.
13. Welch GH, Anderson JR. Volvulus of the small intestine in adults. *World J Surg.* 1986;10:496-9.
14. De Souza LJ. Volvulus of the small bowel. *Br Med J.* 1976;1:1055-6.
15. Welch CE. Intestinal obstruction. Chicago: Year Book Publishers; 1958. p. 14.
16. Soressa U, Mamo A, Hiko D, Fentahun N. Prevalence, causes and management outcome of intestinal obstruction in Adama hospital, Ethiopia. *BMC Surg.* 2016;16:38.
17. Ayenew Z, Gizaw AT, Workneh D, Fentahun N. Outcome of non-traumatic surgical acute abdomen in Nekemte referral hospital Southwest Ethiopia: a retrospective cross-sectional study. *Surgery Curr Res.* 2016;7:282. <https://doi.org/10.4172/2161-1076.1000282>.
18. Tegegne A. Small intestinal volvulus in adults of Gonder region, northwestern Ethiopia. *Ethiop Med J.* 1992;30:211 1-7.
19. Awedew, A.F., Belay, W.B., Amsalu, B.T. *et al.* Small bowel volvulus (SBV) in Northcentral Ethiopia. *BMC Surg* **20**, 221 (2020). <https://doi.org/10.1186/s12893-020-00886-6>.
20. Barabde M, Tiwari S, Lavankar V. Small bowel volvulus: a rare twist in an adult. *Int J Sci Rep.* 2016;2(2):44-7.
21. Fisher J. Computed tomographic diagnosis of volvulus in intestinal malrotation. *Radiology.* 1981;140:145-146.
22. Duke JH, Yar MS. Primary small bowel volvulus: cause and management. *Arch Surg.* 1977;112:685-688.

23. Primary midgut volvulus in adults: Report of two cases and review of the literature. Papadimitriou G, Marinis A, Papakonstantinou A. *J Gastrointest Surg.* 2011;15:1889.