

CASE REPORT ON
SACRO-COCCYGEAL TERATOMA IN 5 YEAR OLD GIRL: A CASE REPORT OF LATE
PRESENTATION.

Abstract

Introduction: The Sacro-coccygeal teratoma is rare tumour that appears near the distal end of the tailbone in new-borns (coccyx). It's the most common congenital tumour, and it can appear at any time throughout pregnancy. It occurs in about 1/35000 to 1/40000 of all live births. Female new-borns are more likely to have this birth defect than male ones. Sacro-coccygeal teratoma can cause critical disturbance in defecation function of infant although this disease is extremely rare benign tumour. Appropriate early recognition can prevent progression to this devastating outcome. In this case report, we present a Sacro-coccygeal teratoma originating from gluteal region. The case is used to highlight important nursing management, clinical consideration and how to prevent further complications. We describe a Case of Sacro-coccygeal teratoma in 5 year girl child presenting with increased gluteal swelling of 15 days duration. In addition she had difficulty in passing stool and urine and also difficulty in sitting.

Keywords: Teratoma, sacrococcygeal, coccyx, gluteal region, tumour, new born. .

Introduction:

Sacro-coccygeal teratoma are rare tumours that grow in the sacrococcygeal region at the distal end of the spine, where the tailbone (coccyx) join the spine. Although the majority of these tumours are benign (noncancerous), they can grow to be extremely large and, once diagnosed, must always be surgically removed.(1) A tumour that develops out from its anatomic location and is made up of diverse tissues

produced from the layers of three germ cell , Ectoderm, mesoderm, and endoderm tissues are found in SCT (2) It frequently appears at the coccyx, where the greatest number of primitive cells can be found for an extended period of time.(3)There are two types of tumours: benign (mature) and malignant (immature) (composed of embryonic elements). Neonatal teratomas (68%) and older children have more mature teratomas (73%).(4)

Case Report:

Patient Identification: A 5-year-old girl, admitted in our hospital on 31st May 2021 with complaint of bilateral gluteal swelling since birth, initially small lesion size. Now within 15 days back that increase gluteal swelling associated with tenderness and difficulty in passing stool and urine and difficulty in sitting. She is 14 kg and height is 101 cm.

Present medical history: A 5-year-old girl was hospitalized in our hospital for evaluation of gluteal swelling. She had complained of gluteal tenderness due to swelling since 15 days before. Patient's difficulty in passing stool and sitting had developed since 3 days before. The patient had suggestive of large mass with fat and cystic areas in the gluteal region and pelvis hematomas mass with fatty and single areas Sacro-coccygeal teratoma. at the birth due to magnetic resonance imaging (MRI), and now with above complaint patient was referred to our hospital for further management. her AFP (Alpha-fetoprotein) is 1.41ng/mL. The child is weak and inactive on admission.

Past medical history: Patient was followed-up from birth where an MRI pelvis and gluteal region was done report was that large mass with fat and a cystic area in the gluteal region and pelvic hematoma with fatty and single areas.

Family history: There were four members in the family. The marriage of the parents was non-consanguineous marriage. All other members of the family were not having complaint in their health except for a patient who was being admitted in hospital.

Investigation:

History collection, Physical examination (regular pelvic or rectal examination) Blood examination, MRI, Ultrasonography radiological screening, etc. Physical examination at admission disclosed abdominal distention and rectal mass. MRI revealed a large mass with fatty and cystic areas involving gluteal regions accompanying haemorrhages in pelvic regions (11 by 13cm). Blood counts revealed normocytic mildly hypochromic anaemia haemoglobin, 8.5 g/dL; MCHC 34.1%, MCV 71.6fl, MCH 24.4picogm, total RBC count 3.53 million/cu mm, increased total WBC count 13100/cu mm, decreased total platelet count 4.78lack/cu mm, Serum laboratory data were normal: including serum levels of alpha-fetoprotein (1.41ng/mL) and beta human chorionic gonadotropin (2.39 mIU/mL).

Management: The patient underwent surgery according to planned. Patient maintained oxygen and N₂O. Patient prepared and draped according to standard surgical protocol. Complete resection surgery was done and the specimen was sent for histopathological examination. Complete surgical removal is the suggested first treatment for SCT (i.e., complete resection). A little SCT is best approached via the perineum; a large SCT may necessitate an additional approach via the abdominal. The coccyx, as well as sections of the sacrum, should be resection. Reattaching of the small ligaments with muscles once linked to a pelvis should be part of the procedure, thereby recreating the posterior perineum. If don't, more likely to get a perineal hernia later in life. This case belonged to Child Health Nursing, Paediatrics department, therefore nursing care played a vital role in every aspect.

Therapeutic intervention: Blood transfusion, Inj. Cefotaxime 750mg IV x BD, Syr. Azee 200 mg - 4ml x OD, Tab. Folic Acid 5mg x OD

Pathogenesis:

SCTs are hypothesised to have originated from Hensen's node (primitive knot), a rounded and raised region at the cranial end of the primitive streak.(5)

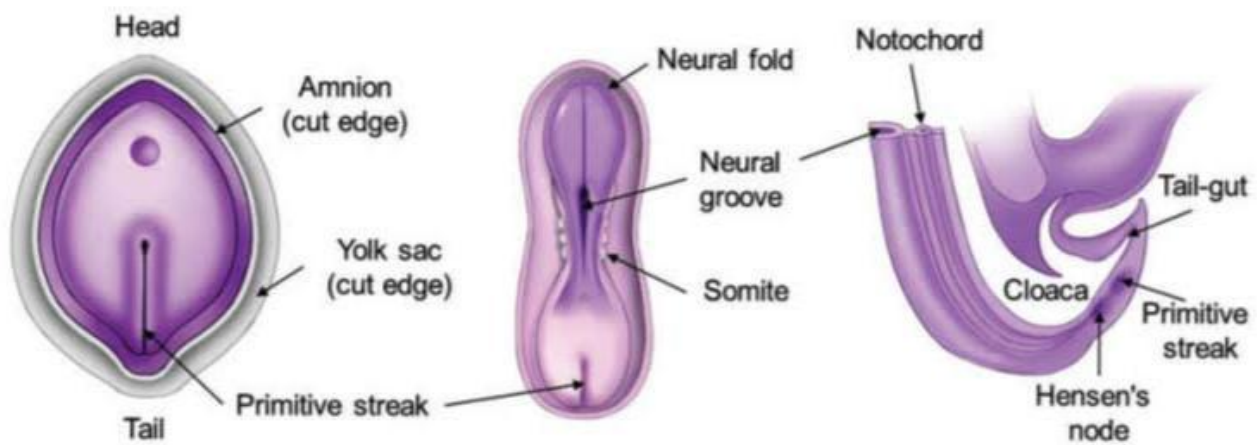


Fig :1 Embryology in development of the caudal region. Drawing of a 16-day embryo (left) shows the primitive streak, which is the longitudinal ridge of ectodermal cells at the caudal end of the bilaminar embryonic disc. Drawing of a 20-day embryo (middle) demonstrates that the primitive streak moves caudally and undergoes regression. Drawing of a four-week embryo (right) shows a regressed primitive streak and Hensen's node located ventral to the developing sacrum and coccyx.

Histopathology examination shown the tumour belong to cystic teratoma. Tumour tissue consists of glial tissue, connective tissue, smooth muscle tissue, skeletal muscle tissue, adipose tissue, bronchus epithelium, squamous epithelium, and eccrine gland. The cysts that form papillae are lined by columnar epithelium. Other cysts are lined by squamous epithelium. No evidence of malignancy was found. In

both lipomas and SCTs can also have calcification, fat, septum, and soft tissue components. Fat, calcification, cystic, and soft tissue component observations are not specific for teratomas, although their presence increases the likelihood of a correct diagnosis such as Sacrococcygeal chordoma, retro rectal abscess, and tail gut cyst are among the other possible diagnosis.

Discussion:

A 5-year-old girl, admitted in our hospital on 31st May 2021 with complaint of bilateral gluteal swelling since birth, initially small lesion size. Now within 15 days back that increase gluteal swelling associated with tenderness and difficulty in passing stool and urine and difficulty in sitting.

Sacrococcygeal teratoma is a tumour that develops in the sacrococcygeal area that incorporate tissue from many primitive germ layers.(6) Its cause remains unknown (7) The classification of SCT according to AAPSS American Academy of pediatrics surgical section (AAPSS) in 1973 described as follows:

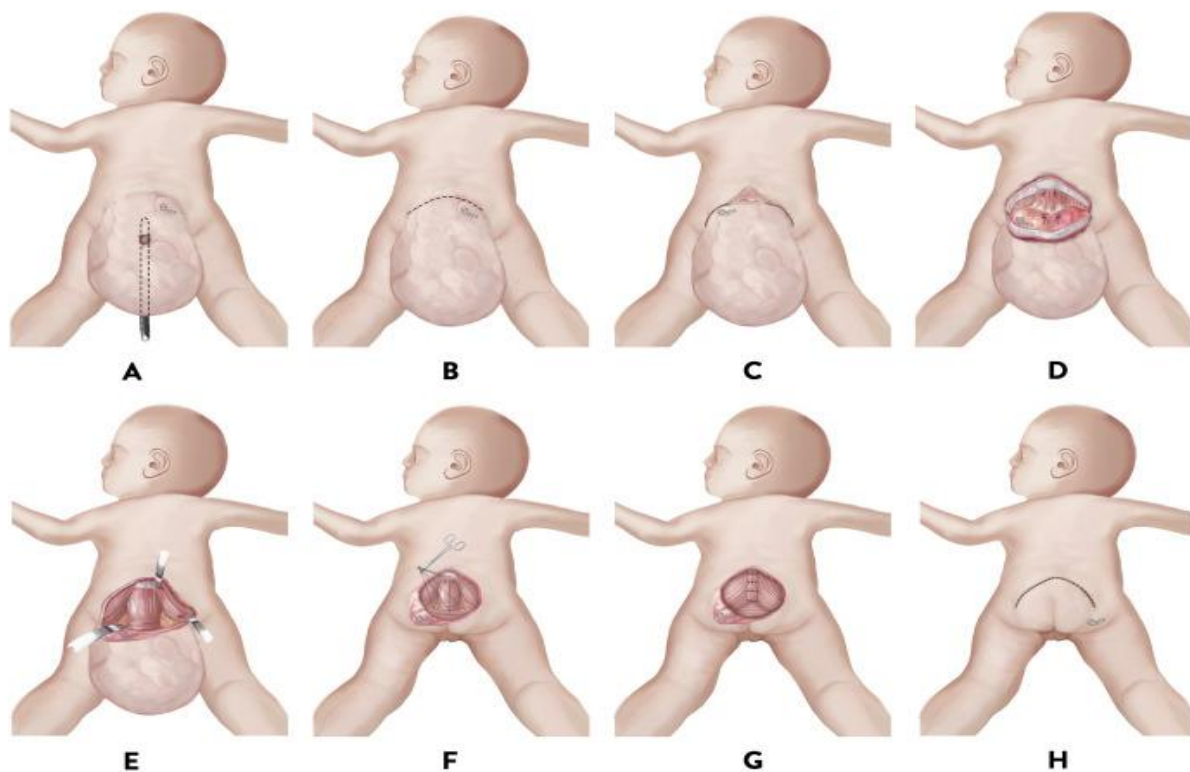


Fig.2 (A) A Hegar dilator is placed in the anus to avoid any injury to the rectum or use sterile gauze rolls with plenty of jellies as an alternate way. (B-C) An inverted V skin incision (chevron incision) is performed. (D) The middle sacral vessels are ligated and cut. (E) The tumor dissected off the muscle. (F) Reconstruct the pelvic floor.(G) The medial edge of gluteus maximus is closed in the midline over the sacrum and the lower part of levator string. (H) Close the skin with 5/0 nylon suture.

The clinical manifestation of SCT is determined by its location and extent. In Sacro-coccygeal teratoma early detection and management are important because it has higher risk of malignancy transformation which increases with age.(6) Sacro-coccygeal teratoma can cause critical disturbance in defecation function of infant although this disease is extremely rare benign tumour. In the newborn period, ten percent of cases are cancerous, and if resection is delayed, more than half of the cases are malignant. Rapidly growing tumours are more likely to induce maternal obstetric complications such as tumour rupture, premature labour, or dystocia during the perinatal period. (8) CT and MRI scans can be used to assess the tumor's connection to surrounding structures and identify the surgical excision plane.(9) AFP, carcinoembryonic antigen, and HCG are useful biochemical indicators that are raised in patients with malignant tumours and can be used to detect recurrences after surgery.(10) To having Knowledge about these complications and successful training in the healthcare team to identify them is necessary priority and counselling the mother about the screening of high risk pregnancy. The diagnosis of SCT should be considered in all cases, according to some experts. Pain in the sacrococcygeal area and a palpable presacral lump were reported by patient. (6)The differential diagnoses based on radiological features include: meningocele, rectal duplication cyst, lipoma, and liposarcoma.(11) 3.5 years after surgery, routine check-ups that include a rectal examination to detect any local recurrence and an AFP level to detect any distant metastasis are required.(12,13)

Conclusion:

Sacro-coccygeal teratoma (SCT) is perhaps the most frequently diagnosed tumour in infants, with a reported incidence of 1:35000-40000 babies born, with girls will be more typically affected (4:1). Antenatal ultrasonography, MRI has been used to identify an Sacro-coccygeal teratoma. Surgical dissection with a full excision of the coccyx is the primary treatment for SCT; malignant tumors may require adjuvant chemotherapy. In most situations, the best outcome comes from early diagnosis and proper surgical surgery.

Ethical Clearance: Taken from institutional ethics committee.

Consent Disclaimer:

As per international standard or university standard, patient's consent has been collected and preserved by the authors.

Source of Funding: Self

Conflict of Interest: Nil.

Reference:

1. Philadelphia TCH of. Sacrococcygeal Teratoma (SCT) [Internet]. The Children's Hospital of Philadelphia; 2014 [cited 2021 Nov 27]. Available from: <https://www.chop.edu/conditions-diseases/sacrococcygeal-teratoma-sct>
2. Berman JJ. Tumor classification: molecular analysis meets Aristotle. *BMC Cancer*. 2004 Mar 17;4:10.
3. Primitive Streak - an overview | ScienceDirect Topics [Internet]. [cited 2021 Nov 27]. Available from: <https://www.sciencedirect.com/topics/neuroscience/primitive-streak>

4. Ahmed A, Lotfollahzadeh S. Cystic Teratoma. In: StatPearls [Internet]. Treasure Island (FL): StatPearls Publishing; 2021 [cited 2021 Nov 27]. Available from:
<http://www.ncbi.nlm.nih.gov/books/NBK564325/>
5. Ohara T. Sacrococcygian Teratoma in a Newborn: Four Years After the Surgery-A Case Report. *Am J Biomed Sci Res*. 2021 Mar 12;12(2):158.
6. Diaz-Aguilar D, Terterov S, Scharnweber R, Merna C, Wang S, Rahman S. Adult sacrococcygeal teratoma with coccygectomy: A case report with a review of the literature. *Surg Neurol Int*. 2017 Oct 24;8:260.
7. Shrestha H, Shrestha R. Sacrococcygeal Teratoma: A Case Report. *J Nepal Med Assoc*. 2020 Jul 31;58:508–11.
8. Shonubi AMO, Musa AA, Akiode O, Salami BA, Kingu HJC, Adnan SM. Mature sacrococcygeal teratoma: a case report and literature review. *West Afr J Med*. 2004 Jun;23(2):176–9.
9. Chopra. An unusual perioperative event in a complex pediatric surgery [Internet]. [cited 2021 Dec 14]. Available from: <http://asja.eg.net/article.asp?issn=1687-7934;year=2016;volume=9;issue=1;spage=134;epage=135;aulast=Chopra;type=3>
10. Cui S, Han J, Khandakar B, Friedman B, Nunez D, Sara GA, et al. Recurrent Adult Sacrococcygeal Teratoma Developing Adenocarcinoma: A Case Report and Review of Literatures. *Case Rep Pathol*. 2021 Nov 27;2021:e5045250.

11. Sheikh A, Solanki S, Solanki F, Hussain S, Sharma D, Sharma D, et al. Giant Mature Sacrococcygeal Teratoma in an Adult - a Case Report. *Internet J Surg* [Internet]. 2008 Dec 31 [cited 2021 Dec 14];21(1). Available from: <https://ispub.com/IJS/21/1/6779>
12. Cheikh D, Ibrahima D, Samba F, Oumar N, Omar S, Gabriel N. Giant Sacrococcygeal Teratoma in Newborns: Management of Two Cases in an Underdeveloped Country. *Ann Surg Perioper Med ASPM* [Internet]. 2018 Apr 20 [cited 2021 Dec 14]; Available from: <https://scitemed.com/article/401/Giant-Sacrococcygeal-Teratoma-in-Newborns-Management-of-Two-Cases-in-an-Underdeveloped-Country>
13. Legbo J, Opara We, Legbo J. Mature sacrococcygeal teratoma: case report. *Afr Health Sci*. 2008 Mar;8(1):54–7.