

## Case study

### Sinonasal Anatomical Variations in Chronic Rhinosinusitis

#### Abstract

**Background:** There is a wide range of anatomical variations affecting the nose, paranasal sinuses (PNS). These variations may cause impairment of mucociliary drainage of the PNS resulting in sinusitis.

**Aim:** The aim of this study was to determine the incidence of anatomic variations of the different structures of the nose in a group of patients with chronic rhinosinusitis without nasal polyposis and compare them with cases didn't have sinusitis.

**Methods:** This case control study included 140 patients who had diagnostic criteria of CRS according to EPOS 2020. Cases were collected from February 2020 to February 2021 from the outpatient clinic of Otorhinolaryngology Department of Tanta University Hospital. Patients were divided into two equal groups: The first group was the study group including 70 patients who had chronic rhinosinusitis as detected by Computed tomography (CT) of paranasal sinuses. The second group was the control group including 70 patients who had normal CT of paranasal sinuses.**Results:** There was significant relation between the studied anatomical variations and chronic rhinosinusitis for Septal deviation, Haller cells, Supra agger frontal cell and Supra bulla frontal cell.

**Conclusions:** The relation between anatomical variations and sinusitis is not clear till now. Some studies showed statistically significant association between common anatomical variations and the presence of sinusitis while in other studies no statistically significant relationship. In our study there was significant statistical relation between Septal deviation, Haller cells, Supra agger frontal cell and Supra bulla frontal cell and chronic rhinosinusitis.

**Keywords:** Sinonasal, Anatomical Variations, Chronic Rhinosinusitis

## **Introduction:**

Chronic rhinosinusitis (CRS) is defined as the presence of two or more symptoms one of which should be either nasal blockage/ obstruction/ congestion or nasal discharge (anterior/posterior nasal drip) with/without facial pain/pressure and with/without reduction or loss of smell for 12 weeks or more <sup>(1)</sup>. About 4.5 to 12% of population suffer from chronic rhinosinusitis <sup>(2)</sup>.

The range for overall CRS-related healthcare costs was \$6.9 to \$9.9 billion USD per 2014 year. Indirect costs were estimated as \$13 billion USD per 2014 year <sup>(3)</sup>. Moreover, CRS has been shown to have negative impacts on sinonasal symptoms, sleep, mood and lower airway function, quality of life and work productivity <sup>(4,5)</sup>.

Computed tomography (CT) is the investigation of choice for the evaluation of patients with CRS. It is an important aspect of pre-operative planning of the patients <sup>(6)</sup>. It gives an idea about the pneumatization of paranasal sinuses, the severity of disease, anatomical and pathological variations better than any other method <sup>(7)</sup>.

The severity of CRS on CT scan is scored according to Lund-Mackay scoring system as: 0= no abnormality, 1= partial opacification and 2= total opacification. The sinus groups include the maxillary, frontal, sphenoidal, anterior ethmoidal and posterior ethmoidal sinuses. Osteomeatal complex is scored as 0 (not obstructed) and 2 (obstructed). Thus, a total score is from 0 to 24 <sup>(8)</sup>.

Anatomical variations of the lateral nasal wall are highly important since they play a role in obstruction or drainage of the osteomeatal complex. Moreover, anatomical variations can affect the outcomes and safety of surgical procedures performed in this region <sup>(9)</sup>.

Numerous sinonasal anatomic variants exist and are frequently seen on sinus CT scans. The most common ones are Agger nasi cells, infraorbital ethmoidal (Haller) cells, sphenoethmoidal (Onodi) cells, nasal septal deviation, and concha bullosa <sup>(10)</sup>.

The aim of this study was to determine the incidence of anatomic variations of the different structures of the nose in a group of patients with chronic rhinosinusitis without nasal polyposis and compare them with cases didn't have sinusitis.

## **Patients and Methods:**

This case control study includes 140 patients as calculated by applying Stephan Thompson equation and the power of study was 90%. Patients had diagnostic criteria of CRS according to EPOS 2020. Patients were divided into two groups: The first group was the study group

including 70 patients who had chronic rhinosinusitis as detected by Computed tomography (CT) of paranasal sinuses. The second group was the control group including 70 patients who had normal CT of paranasal sinuses. Cases were collected from February 2020 to February 2021 from the outpatient clinic of Otorhinolaryngology Department of Tanta University Hospital.

Patients having sinonasal polyposis, previous sinonasal surgery, facial trauma and sinonasal neoplasm with altered normal nasal anatomy were excluded from the study.

The study was undertaken after an ethical approval was granted by Tanta University Hospital Ethics Committees. Informed consent was received from all participants prior to enrollment in the study.

**Diagnostic criteria of CRS according to EPOS 2020:** Presence of two or more symptoms, one of which should be either nasal blockage / obstruction / congestion or nasal discharge (anterior / posterior nasal drip), with or without facial pain/pressure and with or without reduction or loss of smell. For  $\geq 12$  weeks; without resolution of symptoms.

CT scan of the nose and paranasal sinuses was multi slices with coronal and axial cuts. CT machine was Bright speed GE made in China and TOSHIBA made in Japan.

The severity of chronic sinusitis (in the case group) on CT scan was scored according to Lund-Mackay scoring system (Radiologic grading of sinus systems proposed by Lund and Mackay) as: 0= no abnormality, 1= partial opacification and 2= total opacification. The sinus groups include the maxillary, frontal, sphenoidal, anterior ethmoidal and posterior ethmoidal sinuses. Osteomeatal complex was scored as: 0 (not obstructed) and 2 (obstructed). Thus, a total score is from 0 to 24.

The results of CT scan of all patients were interpreted by a radiologist and otorhinolaryngologist for detecting any of the following anatomical variations as nasal septal deviation, concha bullosa, agger nasi cells, infraorbital ethmoidal (Haller) cells, sphenoidal (Onodi) cells and frontal recess cells.

#### **Statistical analysis:**

Data were analyzed using Stata® version 14.2 (StataCorp LLC, College Station, TX, USA). Normality of numerical data distribution was examined using the Shapiro-Wilk test. Non-normally distributed numerical data were presented as median and interquartile and

intergroup differences were compared using the Wilcoxon rank sum test (for two-group comparison) or the Kruskal-Wallis test (for comparison of multiple group). The Jonckheere-Terpstra trend test was used for comparison of multiple ordered groups. The Conover post hoc test was used for pair-wise comparisons following the Kruskal-Wallis test or the Jonckheere-Terpstra test if needed with application of the Bonferroni correction for multiple comparisons.

**Results:**

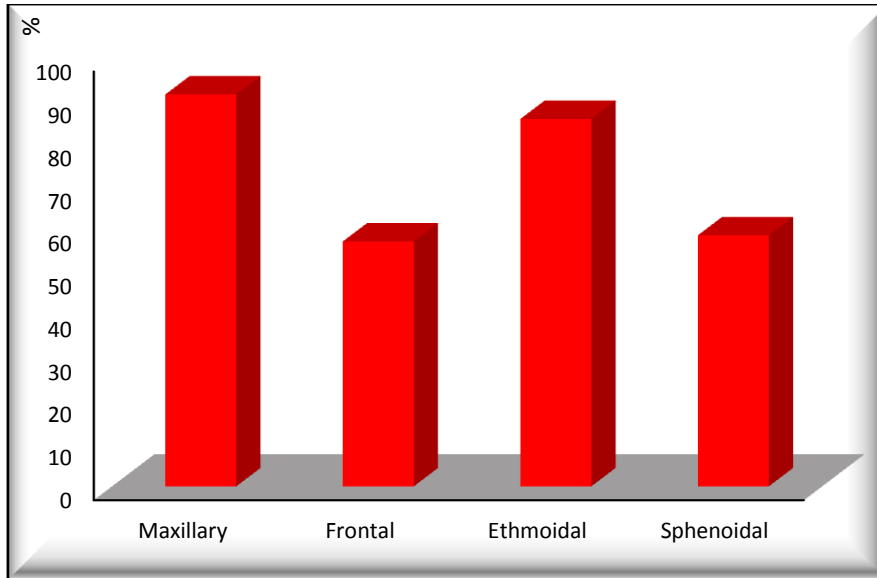
Patients’ characteristics were discussed in the following table. [Table 1]

**Table 1: Demographic characteristics of study and controls.**

Variable		Group				Chi-Square	
		Study		Control		X <sup>2</sup>	P-value
		N	%	N	%		
Gender	Male	35	50.00	31	44.29	0.459	0.498
	Female	35	50.00	39	55.71		
<b>Mann-Whitney Test</b>						<b>Z</b>	<b>P-value</b>
Age	Median (IQR)	39 (32.75-45)		38.5 (32.75-46.25)		0.040	0.968

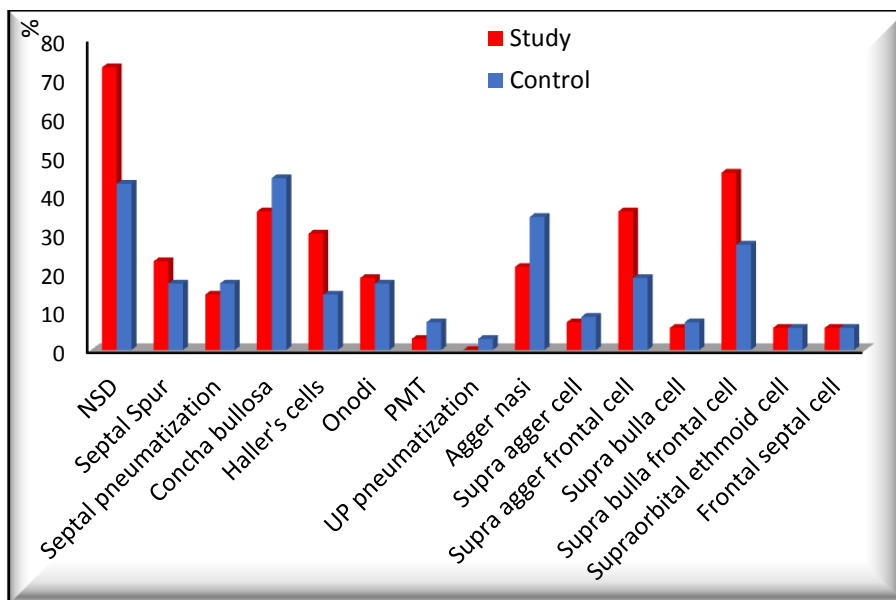
Data are ratio or median (interquartile range), Fisher’s exact test, X<sup>2</sup>: Chi-Square test

In our study maxillary and ethmoidal sinuses were involved in sinusitis more than frontal and sphenoidal sinuses. Four groups of sinuses (pansinusitis) were involved in sinusitis more than three groups followed by two groups and finally one group. [Figure 1]

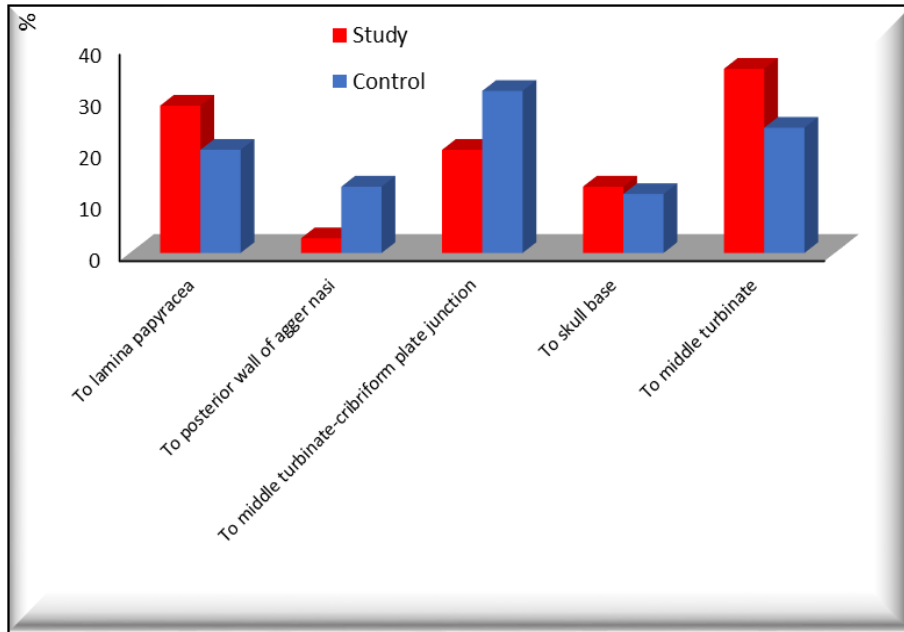


**Figure 1: Prevalence of individual paranasal sinus group involvement on CT scan in study group.**

Among all anatomical variations of nose and paranasal sinuses, the relation between nasal septal deviation and CRS was statistically significant and the relation between Haller cell and maxillary sinusitis was statistically significant and the relation between supra agger frontal cells (SAFC) and supra bulla frontal cells (SBFC) and frontal sinusitis was statistically significant. **[Figure 2]**



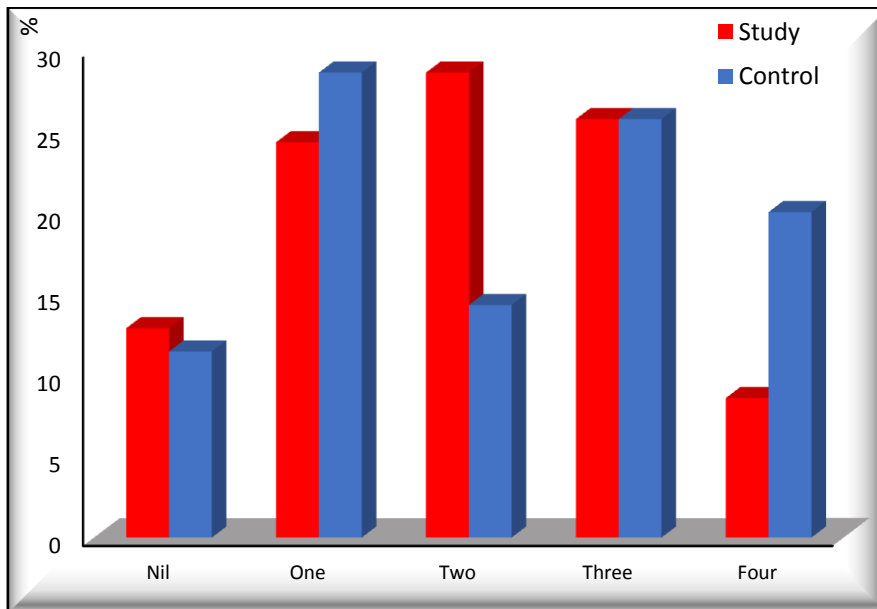
**A**



**B**

**Figure 2: Prevalence of individual anatomical variations (A) and Prevalence of various variations in uncinete process attachment (B) in study and control groups.**

There was no statistically significant difference regarding the number of anatomical variations between study and control. [Figure 3]



**Figure 3: Number of anatomical variations in study and control groups.**

There was no statistically significant relation between Lund-Mackay score and individual anatomical variations. [Table 2]

**Table 2: Relation between the Lund-Mackay score and number of anatomical variations in study group.**

		Lund-Mackay		M-W Test	
		M	IQR	Z	P-value
NSD	Present	14	8-18	-1.007	0.314
	Absent	16	8-20		
Septal Spur	Present	15.5	7.25-20	-0.323	0.747
	Absent	14	8-19		
Septal pneumatization	Present	15	12.5-21.25	-1.255	0.210
	Absent	14	8-19		
Concha bullosa	Present	16	8-19	-0.025	0.980
	Absent	14	8-20		
Agger nasi	Present	16	9-20	-1.867	0.062
	Absent	14	8-18		
Supra agger cell	Present	8	6.5-21.5	-0.412	0.680
	Absent	15	8-19		
Supra agger frontal cell	Present	14	8-20	-0.055	0.956
	Absent	15	8-19		
Supra bulla cell	Present	18	16-22.25	-1.790	0.073
	Absent	14	8-19		
Supra bulla frontal cell	Present	14.5	8-18.75	-0.461	0.645
	Absent	14.5	8-20		
Supraorbital ethmoid cell	Present	11	7.25-21.5	-0.343	0.732
	Absent	15	8-19.25		
Frontal septal cell	Present	18.5	10-21.75	-1.181	0.238
	Absent	14	8-19		
Haller's cells	Present	14	10.5-19.5	-0.649	0.516
	Absent	15	7.5-19.5		
Onodi cells	Present	14	7-18	-1.076	0.282
	Absent	15	8-20		
PMT	Present	16	7-25	-0.318	0.750
	Absent	14.5	8-19		
<b>Kruskal-Wallis Test</b>				<b>X<sup>2</sup></b>	<b>P-value</b>
UP attachment to	lamina papyracea	13.5	8-19.5	3.958	0.412
	posterior wall of	8	7-9		

	<b>AN</b>				
	<b>MT-CP junction</b>	16.	11.5-		
		5	21.25		
	<b>skull base</b>	16	10.5-18.5		
	<b>middle turbinate</b>	15	7.5-17.5		

M= Mean, M-W Test= Mann-Whitney Test. PMT= Paradoxical middle turbinate. UP= Uncinate process. AN= Agger nasi. MT-CP= Middle turbinate-cribriform plate.

There was no statistically significant relation between the Lund-Mackay score and number of anatomical variations in the study group. [Table 3]

**Table 3: Relation between the Lund-Mackay score and number of anatomical variations in study group.**

Variable		Lund-Mackay score				Kruskal-Wallis Test	
		Median	Interquartile range			X <sup>2</sup>	P-value
<b>No. of anatomical variations</b>	<b>Nil</b>	15	6.5	-	18	3.659	0.454
	<b>One</b>	13	7	-	17.5		
	<b>Two</b>	16	12.5	-	20		
	<b>Three</b>	14.5	8	-	20		
	<b>Four</b>	12	7.75	-	17.5		

There is no correlation between Lund-Mackay score and the number of anatomical variations. [Table 4]

**Table 4: Correlation matrix showing the correlation among the Lund-Mackay score and number of anatomical variations.**

Correlations		
Spearman's rho	Lund-Mackay score	
	Ratio	P-value
<b>No of anatomical variations</b>	0.113	0.350

## Discussion

Anatomic variations of paranasal sinus structures may predispose patients to recurrent sinusitis and, in selected cases, to headache <sup>(11)</sup>. However, the relative importance of anatomic variations is still a matter of discussion and variable results have been reported <sup>(12)</sup>. **Stallman et al.** <sup>(13)</sup>, **Kim et al.** <sup>(14)</sup> and **Lerdlum et al.** <sup>(15)</sup> showed no specific association of anatomic variations in rhinosinusitis and claimed that local, systemic, environmental factors or intrinsic mucosal disease were more significant in the pathogenesis of CRS.

Nasal septal deviation is present in 20-31% of the general population and severe deviation has been noted as a contributing factor for sinusitis <sup>(16, 17)</sup>. However, some studies have not demonstrated a causal relationship between nasal septal deviation and sinusitis <sup>(13, 18)</sup>. In our study the prevalence of septal deviation was presented by 51 (72.86%) cases of study group and 30 (42.86%) cases of control group, which was statistically significant.

Concha bullosa incidence was reported to range from 9% to 20% based on initial anatomical dissections. The significance of this most common anatomic variation of the middle turbinate lies in the potential secondary deformity of the turbinate, which increases the probability of obstruction of the middle meatus and lead to recurrent ethmoid sinusitis <sup>(19)</sup>.

**Bolger et al.** <sup>(11)</sup> reported three types of the middle turbinate pneumatization: the vertical lamella was pneumatized in 46.2% of cases (“lamellar cell”) in the inferior bulbous portion in 31.2% of patients and in the entire middle turbinate in 15.7% of cases (“true” concha bullosa).

Unilateral or bilateral concha bullosa was detected in 49.3% of patients. According to data from the literature, the incidence of positive CT findings for concha bullosa varies from 14% to 62% <sup>(11, 13, 19, 20, 21, 22, 23, 24)</sup>. In particular, incidences of 37.5%, 44% and 48.1%, respectively, were reported by **Krzeski et al.** <sup>(21)</sup>, **Stallman et al.** <sup>(13)</sup> and **Ozcan et al.** <sup>(20)</sup>.

There are different opinions in the literature concerning concomitance with mucosal pathologies. Herein, multivariate analysis showed that bilateral concha bullosa was associated with sinusitis bilateral maxillary ( $p < 0.05$ ) in agreement with previous reports <sup>(20)</sup>, while other studies found no direct relationship <sup>(13, 25, 26)</sup>. **Stallman JS et al.** <sup>(13)</sup> reported a significant relationship between the presence of concha bullosa and deviation of the nasal septal on the contralateral side ( $p < 0.0001$ ).

Another common anatomic variant was the presence of infraorbital ethmoid cells, also known as Haller cells. These are found between the maxillary sinus and the orbit and can increase the risk of orbital injury during ethmoidectomy<sup>(27)</sup>. In previous studies, a variable incidence of Haller cells has been noted. In particular, **Kennedy et al.**<sup>(22)</sup> and **Meloni et al.**<sup>(28)</sup> both reported rates of 10%, while **Arslan et al.**<sup>(29)</sup> reported rate of 6% and **Bolger et al.**<sup>(11)</sup> an incidence of 45.1%. Possible reasons for this discrepancy include differences in interpretation of Haller cells or in the technique of CT scanning.

In our study, the incidence of Haller cells was 21 (30%) of study group and 10 (14.29%) in control group which was statistically significant in relationship with sinusitis, in agreement with what reported by **Van Alyea**<sup>(30)</sup>.

Although the sphenoethmoidal (Onodi) cell is an anatomic variant that is not associated with sinusitis, its presence poses an increased incidence of surgical complications for risk of injury to optic nerves or carotid arteries<sup>(19, 29)</sup>.

In our work, these cells were present in 13 (18.57%) of study group and 12 (17.14%) of control group. **Nouraei et al.**<sup>(19)</sup> reported an incidence of 4.7%, while **Stallman et al.**<sup>(13)</sup> reported an incidence of Onodi cells from 3.4-51%.

The reported prevalence of the agger nasi cell varies widely among investigators. In anatomic dissection, **Messerklinger**<sup>(31)</sup> encountered the agger nasi cell in 10- 15% of specimens. **Kantarci et al.**<sup>(32)</sup>, however, noted this cell in 47% of specimens, while **Krzeski**<sup>(21)</sup> reported its presence in 52.9% of cases and **Van Alyea**<sup>(30)</sup> in 89% of individuals. **Kennedy and Zinreich**<sup>(22)</sup> noted the presence of the agger nasi cell in nearly all patients evaluated. Similarly, **Bolger et al.**<sup>(11)</sup> reported that it was present in 98.5% of cases and found clinical significant of agger nasi cells in diagnosis and treatment of sinusitis and can be an important factor in selected cases of frontal sinusitis, so recognition of it help in diagnosis and treatment of recurrent or chronic frontal sinusitis.

In our study, agger nasi cells were detected in 15 (21.43%) of study group and 24 (34.29%) of control group. The incidence rates reported in the literature, from 3% to 100%<sup>(11, 21, 22, 23, 33)</sup>, may in part be related to the different method of analysis employed by **Krzeski et al.**<sup>(21)</sup>.

In our study, supra agger frontal cells was found in 25 (35.71%) of study group and 13 (18.57%) of control group which was statistically significant. **Tran et al.**<sup>(34)</sup> assumed that

type 1 and type 2 cells (using the Bent and Kuhn classification) likely correspond to supra agger cells with type 3 and type 4 (Bent and Kuhn classification) likely representing supra agger frontal cells. The quoted prevalence rates for these cells were highly variable, ranging from 16.3 per cent to 56 per cent for T1 and T2 cells and from 5.6 per cent to 13 per cent for T3 and T4 cells, respectively<sup>(35)</sup>.

**Seth et al.**<sup>(36)</sup>, reported the prevalence of supra bulla frontal cells in study was 21.1%. This prevalence rate was higher than those in the North American and Vietnamese groups, which were 5.5% and 4.3% respectively<sup>(35,37)</sup>.

In our study, supra bulla frontal cell founded in 32 (45.71%) of study group and 19 (27.14%) of control group and it was statistically significant.

Of all the sinuses, **Otto KJ and DelGaudio JM**<sup>(38)</sup> found that recurrence is most likely to develop in the frontal sinus and **Goldstein GH and Kennedy DW**<sup>(39)</sup> say that frontal sinusitis is strongly associated with the need for revision surgery. **Nakayama et al.**<sup>(40)</sup> found that the posterior side of the frontal recess cells remained relatively common: supra bullar cells (SBCs) were found in 12.2%, supra bulla frontal cells (SBFCs) in 20.3% and supraorbital ethmoid cells in 23.7% (SBCs and SBFCs were independent risk factors for opacification of the frontal sinus at 3 months after surgery and SOECs location might not affect the frontal sinus drainage pathway). In contrast, the anterior side of the frontal recess cells, agger nasi cells, supra agger cells and supra agger frontal cells remained at < 10.0%. Frontal septal cells persisted in 25.0% (FSC shift the drainage pathway posterolaterally, the frontal sinus can be easily opened for adequate ventilation even if the lamellae of the FSCs remain).

### **Conclusions:**

The relation between anatomical variations and sinusitis is not clear till now. Some studies showed statistically significant association between common anatomical variations and the presence of sinusitis while in other studies no statistically significant relationship. The results were that there is no significant relation between the studied anatomical variations and chronic rhinosinusitis except for Septal deviation, Haller cells, Supra agger frontal cell and Supra bulla frontal cell.

## References:

- Fokkens WJ, Lund VJ, Mullol J, Bachert C, Alobid I, et al. EPOS 2020: European position paper on rhinosinusitis and nasal polyps 2020. A summary for otorhinolaryngologists. *Rhinology* 2020; 29:1- 464. .1
- DeConde AS, Soler ZM. Chronic rhinosinusitis: Epidemiology and burden of disease. *American Journal of Rhinology & Allergy* 2016; 30: 134-9. .2
- Smith KA, Orlandi RR, Rudmik L. Cost of adult chronic rhinosinusitis: a systematic review. *The Laryngoscope* 2015; 125: 1547-56. .3
- Soler ZM, Mace J, Smith TL. Symptom-based presentation of chronic rhinosinusitis and symptom-specific outcomes after endoscopic sinus surgery. *American Journal of Rhinology* 2008; 22: 297-301. .4
- Alt JA, Smith TL. Chronic rhinosinusitis and sleep: a contemporary review. *International Forum of Allergy & Rhinology* 2013; 3: 941-9. .5
- Babu PR, Prasad BD, Sowmya L, Sasanka K. A Correlation study of paranasal sinuses between operative endoscopic findings in FESS and preoperative CT scan. *Journal of Evolution of Medical and Dental Sciences* 2016; 5: 36-41. .6
- Ashiya Goel A, Gupta V, Raheja V, Goel S. A study to correlate the endoscopic and CT findings in chronic rhinosinusitis. *Indian Journal of Anatomy and Surgery of Head, Neck and Brain* 2018; 4: 114-7. .7
- Dua K, Chopra H, Khurana AS, Munjal M. CT scan variations in chronic sinusitis. *Indian Journal of Radiology Imaging* 2005; 15: 315. .8
- Abhishek S, Kapadia B, Patil NG, Shubhangi G. Anatomical Variations of Nose and Para-Nasal Sinuses; CT Scan Review. *International Journal of Advance Research, Ideas and Innovation in Technology* 2017; 3: 244-9. .9
- Shpilberg KA, Daniel SC, Doshi AH, Lawson W, Som PM. CT of Anatomic Variants of the Paranasal Sinuses and Nasal Cavity. *American Journal of Roentgenology* 2015; 204: 1255-60. .10
- Bolger WE, Parsons DS, Butzin CA. Paranasal sinus bony anatomic variations and mucosal abnormalities: CT analysis for endoscopic sinus surgery. *The Laryngoscope*. 1991; 101: 56-64. .11
- Nair S. Correlation between symptoms and radiological findings in patients of chronic rhinosinusitis: a modified radiological typing system. *Rhinology*. 2009; 47: 181. .12
- Stallman JS, Lobo JN, Som PM. The incidence of concha bullosa and its relationship to nasal septal deviation and paranasal sinus disease. *American Journal of Neuroradiology*. 2004; 25: 1613-8. .13
- Jun Kim H, Jung Cho M, Lee JW, Tae Kim Y, Kahng H, et al. The relationship between anatomic variations of paranasal sinuses and chronic sinusitis in children. *Acta oto-laryngologica*. 2006; 126: 1067-72. .14
- Lerdlum S, Vachiranubhap B. Prevalence of anatomic variation demonstrated on screening sinus computed tomography and clinical correlation. *Journal of the Medical Association of Thailand*. 2005; 88: 110-5. .15
- Sarna A, Hayman LA, Laine FJ, Taber KH. Coronal imaging of the osteomeatal unit: anatomy of 24 variants. *Journal of computer assisted tomography*. 2002; 26: 153-7. .16

- Hamdan AL, Bizri AR, Jaber M, Hammoud D, Bairo T, et al. Nasoseptal variation in relation to sinusitis. A computerized tomographic evaluation. *Le Journal medical libanais. The Lebanese medical journal.* 2001; 49: 2-5. .17
- Scribano E, Ascenti G, Loria G, Cascio F, Gaeta M. The role of the ostiomeatal unit anatomic variations in inflammatory disease of the maxillary sinuses. *European Journal of radiology.* 1997; 24: 172- 4. .18
- Nouraei SA, Elisay AR, Dimarco A, Abdi R, Majidi H, et al. Variations in paranasal sinus anatomy: implications for the pathophysiology of chronic rhinosinusitis and safety of endoscopic sinus surgery. *Journal of Otolaryngology-Head and Neck Surgery.* 2009; 38: 32. .19
- Ozcan KM, Selcuk A, Özcan I, Akdogan O, Dere H. Anatomical variations of nasal turbinates. *Journal of Craniofacial Surgery.* 2008; 19: 1678-82. .20
- Krzeski A, Tomaszewska E, Jakubczyk I, Galewicz-Zielińska A. Anatomic variations of the lateral nasal wall in the computed tomography scans of patients with chronic rhinosinusitis. *American journal of rhinology.* 2001; 15: 371-5. .21
- Kennedy DW, Zinreich SJ. The functional endoscopic approach to inflammatory sinus disease: current perspectives and technique modifications. *American Journal of Rhinology.* 1988; 2: 89-96. .22
- Earwaker J. Anatomic variants in sinonasal CT. *Radiographics.* 1993; 13: 381-415. .23
- Calhoun KH, Waggenpack GA, Simpson CB, Hokanson JA, Bailey BJ. CT evaluation of the paranasal sinuses in symptomatic and asymptomatic populations. *Otolaryngology, Head and Neck Surgery.* 1991; 104: 480-3. .24
- Mladina R, Skitarelić N, Casale M. Two holes syndrome (THS) is present in more than half of the postnasal drip patients? *Acta otolaryngologica.* 2010; 130: 1274-7. .25
- Polavaram R, Devaiah AK, Sakai O, Shapshay SM. Anatomic variants and pearls functional endoscopic sinus surgery. *Otolaryngologic Clinics of North America.* 2004; 37: 221-42. .26
- Başak S, Akdilli A, Karaman CZ, Kunt T. Assessment of some important anatomical variations and dangerous areas of the paranasal sinuses by computed tomography in children. *International journal of pediatric otorhinolaryngology.* 2000; 55: 81-9. .27
- Meloni F, Mini R, Rovasio S, Stomeo F, Teatini GP. Anatomic variations of surgical importance in ethmoid labyrinth and sphenoid sinus. A study of radiological anatomy. *Surgical and Radiologic Anatomy.* 1992; 14: 65-70. .28
- Arslan H, Aydınlioğlu A, Bozkurt M, Egeli E. Anatomic variations of the paranasal sinuses: CT examination for endoscopic sinus surgery. *Auris Nasus Larynx.* 1999; 26: 39-48. .29
- Van Alyea OE. Ethmoid labyrinth: anatomic study, with consideration of the clinical significance of its structural characteristics. *Archives of Otolaryngology.* 1939; 29: 881-902. .30
- Messerklinger W. On the drainage of the normal frontal sinus of man. *Acta otolaryngologica.* 1967; 63: 176-81. .31
- Kantarci M, Karasen RM, Alper F, Onbas O, Okur A, et al. Remarkable anatomic variations in paranasal sinus region and their clinical importance. *European journal of radiology.* 2004; 50: 296- 302. .32

- Bayram M, Sirikci A, Bayazit YA. Important anatomic variations of the sinonasal .33  
anatomy in light of endoscopic surgery: a pictorial review. *European radiology*. 2001;  
11: 1991-7.
- Tran LV, Ngo NH, Psaltis AJ. A radiological study assessing the prevalence of frontal .34  
recess cells and the most common frontal sinus drainage pathways. *American journal  
of rhinology & allergy*. 2019; 33: 323-30.
- Bent JP, Cuijty-Siller C, Kuhn FA. The frontal cell as a cause of frontal sinus .35  
obstruction. *American journal of rhinology*. 1994; 8: 185-92.
- Seth N, Kumar J, Garg A, Singh I, Meher R. Computed tomographic analysis of the .36  
prevalence of International Frontal Sinus Anatomy Classification cells and their  
association with frontal sinusitis. *The Journal of Laryngology & Otology*. 2020; 134:  
887-94.
- Choby G, Thamboo A, Won TB, Kim J, Shih LC, et al. Computed tomography .37  
analysis of frontal cell prevalence according to the International Frontal Sinus  
Anatomy Classification. *International forum of allergy & rhinology* 2018; 8: 825-30.
- Otto KJ, DelGaudio JM. Operative findings in the frontal recess at time of revision .38  
surgery. *American journal of otolaryngology*. 2010; 31: 175-80.
- Goldstein GH, Kennedy DW. Long-term successes of various sinus surgeries: a .39  
comprehensive analysis. *Current allergy and asthma reports*. 2013; 13: 244-9.
- Nakayama T, Asaka D, Kuboki A, Okushi T, Kojima H. Impact of residual frontal .40  
recess cells on frontal sinusitis after endoscopic sinus surgery. *European Archives of  
Oto-Rhino-Laryngology*. 2018; 275: 1795-801.