

**Evaluation of rehabilitation of surgically repaired flexor hand tendons and ultrasonographic follow up of their healing**

**Running Head:** Rehabilitation and ultrasound evaluation of repaired flexor tendons

**Abstract:**

**Objectives:** To evaluate the role of early rehabilitation of surgically repaired flexor hand tendons in improvement of clinical outcome and the role of musculoskeletal ultrasound in follow up of their healing.

**Patients and methods:** Thirty patients with 31 repaired flexor tendons. Assessment was done after 2<sup>nd</sup>, 4<sup>th</sup>, 8<sup>th</sup> and 12<sup>th</sup> weeks of rehabilitation by visual analogue scale (VAS), total active motion of injured fingers (TAM), grip strength, hand assessment tool (HAT) score and ultrasound (US).

**Results:** There was a significant development in pain assessed by VAS, TAM, grip strength and HAT score of the affected hand ( $p < 0.001$ ). Ultrasonographic assessment of healing flexor tendons showed significant improvement in defect size, thickness, vascularity, echogenicity and margination. There was positive correlation between margination of healing flexor tendon with VAS, hand grip and HAT score.

**Conclusions:** Application of proper rehabilitation programs has a great impact on improving the functional outcome after surgical repair of flexor hand tendons. High-frequency ultrasound is used to follow up tendon healing after surgical repair and to assess the state of tendon repair in relation to clinical result.

**Key words:** musculoskeletal ultrasound, hand assessment tool, rehabilitation of repaired flexor hand tendons

**Introduction:**

The hand is a very complicated organ with several joints, numerous ligaments, tendons, and nerves of different types. The hand, together with the brain, is the most interesting and complicated human organ we possess. No other species on the planet possesses hands capable of grasping, holding, moving, and manipulating items in the way that human hands do. Any damage to the hand's supporting structures bears the risk of severe disability. (1)

Injuries to the hands account for 20% of all injuries treated. Road traffic accidents, physical trauma (e.g., crush damage, contusions), and assault are the most common causes of open hand injury. (2). Tendon damage is the second most common injury found in the hand. If they not repaired, this can cause severe functional damage. (3)

Early application of well selected rehabilitation programme after surgical repair of flexor hand tendons improves the gliding function of the healing tendons, helps to strengthen tensile strength, improve the range of motion of the damaged tendon, and stimulate morphological repair . This improves functional outcome and decrease the time needed by the patient to return to work. (4)

Evaluation of tendon recovery condition in relation to clinical outcomes necessitates regular follow-up. It is possible to observe real-time tendon repair in the human hand using musculoskeletal ultrasound, a non-invasive imaging method. (5)

**Patients and methods:**

This study was performed on 30 patients with 31 repaired flexor hand tendons two weeks after process. They were collected from the out-patient clinic of the Physical Medicine, Rheumatology and Rehabilitation Department, Tanta University Hospitals. We exclude patients with collagen disease, congenital hand deformities, bone fractures, nerve injuries, fingertip injuries, burn injuries, or thumb tendon repair from the study. All participants provided written informed consent. The research was done in line with the ethical principles of the Declaration of Helsinki. The study was accepted by Tanta University's Faculty of Medicine's Local Research Ethics Committee.

Patients underwent a modified Duran protocol of rehabilitation. A custom fabricated dorsal protective splint was used to put wrist in 20° flexion, metacarpophalangeal (MCPs) in 40°-50° flexion, and proximal interphalangeal joint (PIPs) in neutral position. (6) All patients received pulsed electro-magnetic field therapy (PEMF) for one hour, 3 times/week over the site of injury. The treatment started 1-2 days after repair and continued for 4 weeks (7). Some physical modalities such as paraffin wax bath and ultrasound therapy were added to prevent complications like joint stiffness and adhesive scars. (8) A full history was taken from all patients. At the second, fourth, eighth, and twelfth weeks of recovery, a visual analogue scale (VAS) was used to evaluate pain. The scale was represented at 10 cm line. Its means the extreme pain from zero to maximum pain at 10, each patient was asked to make point on this scale representing his /her degree of pain intensity (9). Total active motion (TAM) of the

injured fingers was evaluated by goniometer at the 8th and 12th weeks according to Strickland's Classification using the following equation:

$$\frac{(\text{PIP} + \text{DIP}) \text{ flexion} - (\text{PIP} + \text{DIP}) \text{ extension deficit} \times 100}{175} = \% \text{ of normal active PIP+DIP motion. (10)}$$

175

Grip strength of the affected hands was evaluated at the 8th and 12th weeks using a modified sphygmomanometer technique. Percentage decrease of hand grip compared to the normal hand was calculated (11). Hand Assessment Tool (HAT) score was evaluated at the 8th, 12th weeks. Seven factors were evaluated by fourteen questions firm grip, good hand skills, pain, extension, neurotic indications, gross grip, and aesthetics. Each question answered was scored and a total score was obtained using the equation  $[(\text{sum of } n \text{ responses})/n - 1] \times 25$ , n is the number of items (12).

The Tanta University Educational Hospital's Physical Medicine, Rheumatology, and Rehabilitation Department's ultrasound unit used SAMSUNG MEDISON (UGEOH60) linear array transducers with frequencies at the range of 9-13 Hz to evaluate all patients at the 4th, 8th, and 12th weeks.

Technique: The patients were seated facing the examiner. The transducer was placed directly on the patient's skin with gel. By scanning in both transverse and longitudinal directions, the location of the tendon repair was established. The transducer was kept perpendicular to the tendon in order to prevent the effect of anisotropy. Bony landmarks were used to locate the corresponding position on the contralateral uninjured digit.

Ultrasound measurement definitions (13):

Defect size: its definition was the distance (mm) between the discernible limits of the hypo-echoic area of healing tendon and the adjacent normo-echoic tendon.

**Tendon thickness:** Linear measurement (mm) was conducted in the transverse plane at midpoint of tendon restoration on the injured digit and also at corresponding site on the uninjured hand.

**Vascularity:** it was measured using the Power Doppler (PD) mode in the transverse plane. The PD signals were scored as follows: grade 0 = no detectable PD signal, grade 1 = mild vascularity  $\leq 30\%$  of transverse area, grade 2 = moderate vascularity  $\leq 60\%$ , grade 3 = severe vascularity  $> 60\%$ .

**Echogenicity:** it was evaluated according to the following scale: grade 0 = normal tendon, grade 1 = reduced reflectivity up to 25%, grade 2 = reduced reflectivity 25%–50%, grade 3 = reduced reflectivity 50%–75%, grade 4 = reduced reflectivity 75%–100% of the transverse area.

**Margination:** tissue margins was defined as scored according to the following scale: grade 1 = margins well defined, grade 2 = slightly less definition between borders, grade 3 = margins irregular, grade 4 = borders blend.

**Statistical analysis:** Data were given to the computer and examined using IBM SPSS software package version 20.0. (Armonk, NY: IBM Corp) Qualitative data was described using number and percent. Comparisons between different periods of follow up were accomplished using ANOVA test and Wilcoxon signed ranks test. Pearson and Spearman coefficient were used to associate between quantitative variables. Statistical significance was defined as a P value of  $< 0.05$ .

### **Results:**

In our study, 21 participants were males (70%) and 9 participants were females (30%). The patients' age ranged from 16-48 years. 19 patients (63.3%) had right side

injury and 11 patients (36.6%) had left side injury. The little finger was the most injured finger (36.6%).

There was significant development in pain evaluated by VAS after the 4th, 8th and 12th weeks of the rehabilitation program in comparison with the 2nd week, and after the 8th and 12th weeks in comparison with the 4th week ( $p < 0.001$ ).

There was a significant development in TAM of injured fingers, grip strength, and HAT score of the affected hand after the 12th week of the rehabilitation program in comparison with the 8th week ( $p < 0.001$ ).

#### **Ultrasonographic assessment:**

There was a significant decrease in defect size after the 8th and 12th weeks of the rehabilitation program when compared with the 4th week, and after the 12th week when compared with the 8th week.

There was a significant reduction in thickness after the 8th and 12th weeks of the rehabilitation program when compared with the 4th week, and after the 12th week when compared with the 8th week. Also, there was a significant increase in thickness of healing tendons after the 4th, 8th and 12th weeks of the recovery process in comparison to the normal hand.

There was a significant reduction in vascularity after the 8th and 12th weeks of the rehabilitation program when compared with the 4th week. There was significant improvement in echogenicity after the 8th and 12th weeks of the recovery process in comparison with the 4th week, and after the 12th week when compared with the 8th week.

There was significant improvement in margination after the 8th and 12th weeks of the rehabilitation program when compared with the 4th week.

There was a positive correlation between margination of the healing tendon assessed by ultrasound and VAS. In addition, there was a positive correlation between margination of the healing flexor tendon assessed by ultrasound with hand grip and HAT score.

### **Discussion:**

The hand is involved in almost every physical activity and hence exposed to injury from a number of different etiologies including mechanical trauma, accidents and burn injuries. The term "hand trauma" refers to any closed or open injury to the wrist and /or the hand, including skin, muscle, tendon, bone and joint, nerve and /or vessels. Some of the most common injuries to the body are those to the hands. There are between 6.6 percent and 28.6 percent of all injuries, and 28 percent of musculoskeletal system-related injuries. (14)

In order to speed up tendon recovery, strengthen the tissue, and prevent adhesions from forming, early physical therapy and splinting are essential. (15)

ultrasound (a non-invasive and easily accessible imaging modality) is used to monitor tendon recovery (16)

This study involved 30 participants after surgical restoration of flexor hand tendons. As regard clinical manifestations, pain was assessed by VAS. Our study showed that there was significant development in pain evaluated by VAS after the 4th, 8th and 12th weeks of the rehabilitation program when compared with the 2nd week, and after the 8th and 12th weeks when compared with the 4th week. This is explained by applying early motion protocols that decrease the possibility of stiffness and adhesions and by

using pulsed electro-magnetic field therapy (PEMF) which helped to resolve oedema and enhance tendon repair, thus decreasing postoperative pain. Also, some physical modalities were added, such as a paraffin wax bath and ultrasound therapy, which helped to decrease pain, joint stiffness, and adhesive scars.

We found that total active motion (TAM) of the injured finger enhanced after the 12th week when compared with the 8th week. This is in agreement with the results of Rrecaj et al (17) who used Strickland classification to assess the range of motion of injured flexor tendons after using a Duran rehabilitation protocol. They found that there was improvement of range of motion of the wounded flexor tendons after the 12th week of the rehabilitation program in comparison to the 8th week. This is explained by an improvement in pain assessed by VAS and the application of more advanced exercises in the rehabilitation protocol which results in improved total active motion of the injured fingers.

Grip strength of the affected hand significantly improved after the 12th week when compared with the 8th week. This is explained by application of strengthening and resisted exercises which lead to improved grip strength in the affected hand.

Kitis et al (18) reported that the mean grip strength of the injured hand was 81% of that of normal hand after 12 weeks in patients who used a controlled passive movement rehabilitation protocol for flexor tendons. Grip strength was measured using a Jamar dynamometer. Many studies that assessed grip strength after 6 months or one year reported that it improved for the first 6 months and then reached a steady state at one year, as described by Libberecht et al (19).

On evaluating the functional result of the patients using HAT score, our results showed that HAT score significantly decreased after the 12th week when compared

with the 8th week. This can be explained by the improved TAM of the injured finger, grip strength of the affected hand, and pain assessed by VAS which lead to improvement of hand functions and thus a decreased HAT score.

With regard to ultrasound assessment, our results showed that defect size of the healing tendon was significantly decreased after the 12th week when compared with the 4th and 8th weeks. This is explained by the natural healing process that consists of 3 stages; inflammatory, proliferative, and remodelling. (20)

Thickness of the healing tendons was significantly increased when compared with the normal hand. This is in line with the findings of Bühler et al (13) who reported that surgically repaired tendons were 94% to 369% thicker than the uninjured contralateral ones at mid-repair location. Furthermore, there was a significant decrease in tendon thickness after the 12th week when compared with the 4th and 8th weeks. These results can be explained by the healing process; in the proliferative stage there is rapid proliferation of fibroblasts resulting in synthesis of collagen, proteoglycans, and other components of the extracellular matrix. High cellularity and formation of vascular network in a healing tendon make its thickness higher than normal tendon thickness, then in the remodelling stage which begins 6-8 weeks after injury there is a decrease in cellularity and reduced matrix synthesis and this decreases tendon thickness. (21)

We found that vascularity of healing flexor tendons was significantly decreased after the 12th week when compared with the 4th week. This is can be explained by the natural healing process because in proliferative stage, an extensive blood vessel network is present. Then the remodelling stage starts 6-8 weeks after injury, during the latter half of this stage, tenocyte metabolism and tendon vascularity decline. (22)

Echogenicity of the healing flexor tendon was significantly improved after the 12th week when compared with the 4th and 8th weeks. This is in agreement with the results of Puippe et al (23) who found that echogenicity changes during the healing process toward more hyperechogenic structures inside the suture site. They explained their results by stages of tendon repair; in the early inflammatory and proliferative stages, tendons seemed predominantly hypoechogenic, which can be explained by the high amount of blood vessels and oedema, but in the remodelling phase, the increase of organised collagen fibres causes a higher echogenicity within the tendon.

We found that margination of the healing flexor tendon was significantly improved after the 12th week when compared with the 4th week. This can be explained by phases of tendon healing similar to echogenicity. In the early inflammatory and proliferative stages, tendons seemed predominantly hypoechogenic with ill-defined edges, which can be explained by the high amount of blood vessels and oedema. While in the remodelling phase, the increase of organised collagen fibres lead to a higher echogenicity within the tendon and also well-defined tendon margins.

Regarding the correlation data, there was a positive correlation between margination of the healing flexor tendon assessed by ultrasound with VAS, hand grip and HAT score. Our findings can be explained by the well-defined tendon margins that may indicate good healing process which results in good clinical and functional outcome.

**Conclusion:** Application of proper rehabilitation programs has a great impact on improving the functional outcome after surgical repair of flexor hand tendons. High-frequency ultrasound is used to follow up tendon healing after surgical repair and to evaluate tendon healing status in relation to clinical outcome.

**Competing interests disclaimer:**

The authors have stated that there are no conflicts of interest. This study relies on products that are widely utilised in our field of study and country. No conflict of interest exists between the writers of the products and those who make them because we do not aim to utilise these products as a means of litigation, but rather for the progress of knowledge. Also, The research was not supported by the producing firm, but rather by the writers' own efforts.

**References:**

- 1.Kumar H, Singh K, Rani P,Boparai RS,Singh J. Evaluation of extensor tendon repair of hand. *Int. J. Orthop. Sci.* 2018; 4:377-382.
- 2.Ghosh S, Sinha RK, Datta S, Chaudhuri A, Dey C, Singh A. A study of hand injury and emergency management in a developing country. *Int J Crit Illn Inj Sci.* 2013;3(4):229-234.
- 3.Schöffl V, Heid A and Küpper T. Tendon injuries of the hand. *World J Orthop* 2012;3: 62–69.
- 4.Tang JB. Tendon injuries across the world: treatment. *Injury* 2006; 37:1036-1042.
- 5.Smith J, Finnoff J. Diagnostic and interventional musculoskeletal ultrasound: Part 2. Clinical applications. *PM&R.* 2009; 1:162-177.
- 6.Lund AT. Flexor tendon rehabilitation: a basic guide. *Operat Tech Plast Reconstr Surg* 2000; 7:20-24.
7. Gordon GA. Designed electromagnetic pulsed therapy: Clinical applications. *J Cell Physiol* 2007; 212:579-582.
8. Sibtain F, Khan A and Shakil-Ur-Rehman S. Efficacy of Paraffin Wax Bath with and without joint mobilization techniques in rehabilitation of post-traumatic stiff hand. *Pak J Med Sci* 2013; 29:647-650.

9. Kahl C and Cleland JA. Visual analogue scale, numeric pain rating scale and the McGill Pain Questionnaire: an overview of psychometric properties. *Phys Ther Rev* 2005; 10:123-128.
10. Galanakis I, Aligizakis A, Katonis P, Vavouranakis H, Stergiopoulos K, Hadjipavlou A. Functional evaluation after primary flexor tendon repair in zone II. *Acta Orthop Belg.* 2003 Jun;69(3):252-6.
11. Pujianita L, Prabowo T and Prananta MS. Prediction of Jamar Grip Strength Value Using Modified Aneroid Sphygmomanometer Cuff Method. *Int. J. Integr. Health Sci.* 2017; 5:1-7.
12. Naidu SH, Panchik D and Chinchilli VM. Development and validation of the hand assesment tool. *J Hand Ther* 2009; 22:250-256.
13. Bühler M, Johnson G and Meikle G. Longitudinal in vivo ultrasound observations of the surgically repaired zone II flexor digitorum profundus tendon. *Ultrasound Med Biol* 2015; 41:3018-3022.
14. Desai B, Makwana H, Shah D, Patei P. Epidemiology of hand injuries in adults presenting to a tertiary trauma care centre: A descriptive study. *Int. J. Orthop. Sci.* 2018; 4:434-438.
15. Howell JW and Peck F. Rehabilitation of flexor and extensor tendon injuries in the hand: current updates. *Injury* 2013; 44:397-402.
16. Baz A, Hussien A, Samad H, El-Azizi H. Diagnostic performance of high-resolution ultrasound in pre-and postoperative evaluation of the hand tendons injuries. *Egypt J Radiol Nucl Med* 2021; 52:1-10.

17. Rrecaj S, Martinaj M, Murtezani A, Ibrahim-Kaçuri D, Haxhiu B, Zatriqi V. Physical therapy and splinting after flexor tendon repair in zone II. *Med Arch*. 2014;68(2):128-31.
18. Kitis PT, Buker N and Kara IG. Comparison of two methods of controlled mobilisation of repaired flexor tendons in zone 2. *Scand J Plast Reconstr Surg Hand Surg* 2009;43(3):160-165.
19. Libberecht K, Lafaire C and Van Hee R. Evaluation and functional assessment of flexor tendon repair in the hand. *Acta Chir Belg* 2006; 106:560-565.
20. Thomopoulos S, Parks WC, Rifkin DB, Derwin KA. Mechanisms of tendon injury and repair. *J Orthop Res*. 2015;33(6):832-9.
21. James R, Kesturu G, Balian G, Chhabra AB. Tendon: biology, biomechanics, repair, growth factors, and evolving treatment options. *J Hand Surg Am*. 2008;33(1):102-12.
22. Sharma P and Maffulli N. Biology of tendon injury: healing, modeling and remodeling. *J Musculoskelet Neuronal Interact* 2006; 6:181-190.
23. Puipe GD, Lindenblatt N, Gnannt R, Giovanoli P, Andreisek G, Calcagni M. Prospective morphologic and dynamic assessment of deep flexor tendon healing in zone II by high-frequency ultrasound: preliminary experience. *AJR Am J Roentgenol*. 2011;197(6): W1110-7.

**Table (1):** Distribution of the studied cases according to demographic data, side of injury and injured finger

	No.	%
<b>Gender</b>	<b>(n=30)</b>	
Male	21	70
Female	9	30
<b>Occupation</b>	<b>(n=30)</b>	
Student	6	20

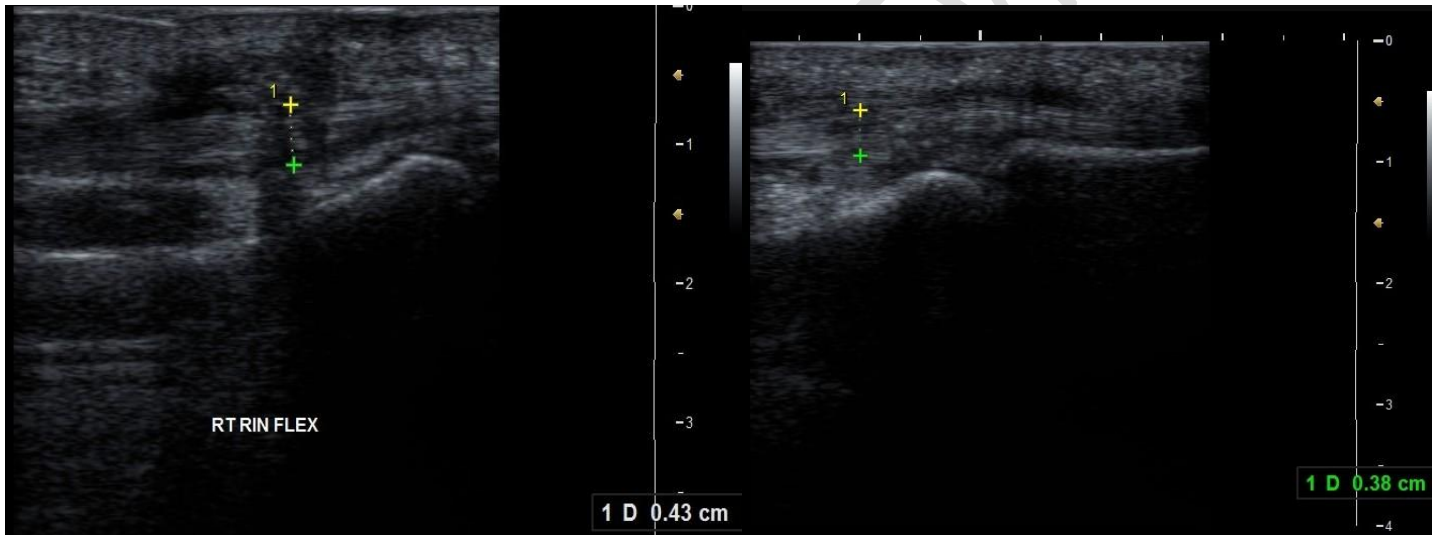
Manual worker	14	46.6
Housewife	10	33.3
<b>Side of injury</b>	<b>(n=30)</b>	
Right	19	63.3
Left	11	36.6
<b>Injured finger</b>	<b>(n=31)</b>	
Little	11	36.6
Ring	8	25.8
Middle	7	22.5
Index	5	16.1

**Table (2): Correlation between visual analogue scale (VAS), total active motion (TAM), Hand grip, hand assessment tool (HAT) score with ultrasound (US) findings.**

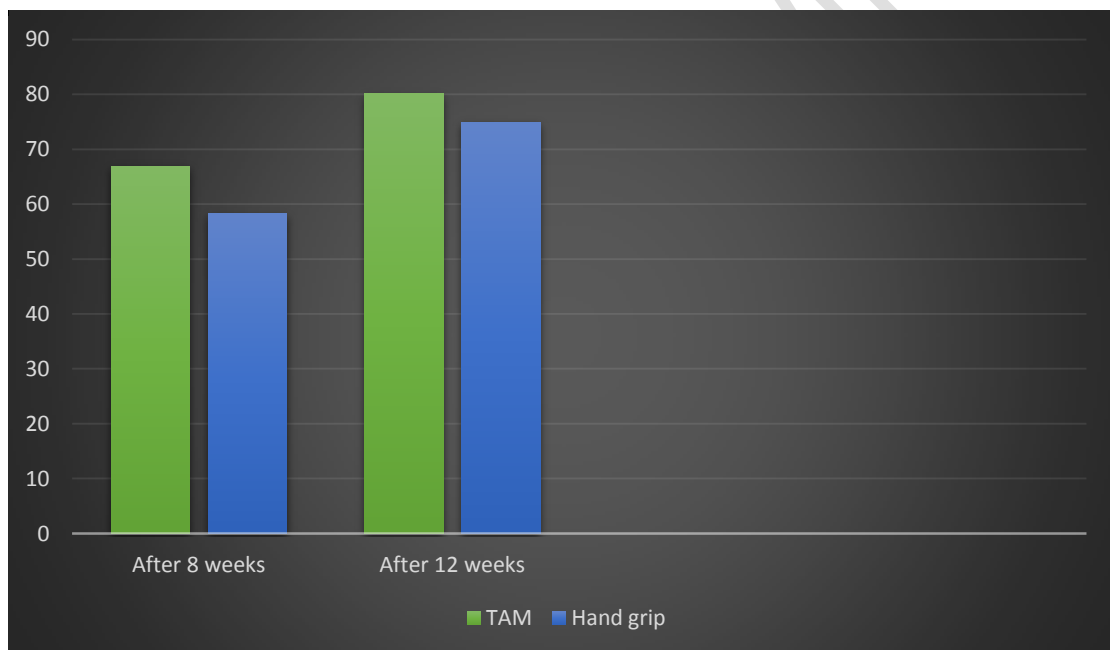
Change in US findings	Change in VAS (4 to 12 weeks)		Change in TAM (8 to 12 w)		Change in Hand grip (8 to 12 w)		Change in HAT score (8 to 12 w)	
	$r_s$	$p$	$r$	$p$	$r$	$p$	$r_s$	$p$
<b>Decrease in defect size</b>	0.236	0.368	0.456	0.096	0.106	0.706	0.453	0.371
<b>Decrease in thickness in mm</b>	-0.372	0.348	-0.023	0.565	0.062	0.825	0.067	0.792
<b>Change in vascularity</b>	0.267	0.326	-0.467	0.089	0.100	0.722	-0.126	0.564
<b>Decrease in echogenicity</b>	0.162	0.268	0.367	0.187	0.296	0.285	-0.078	0.778
<b>Decrease in margination</b>	0.710*	0.019*	0.192	0.569	0.593*	0.046*	0.826*	<0.001*

$r_s$ : Spearman coefficient       $r$ : Pearson coefficient

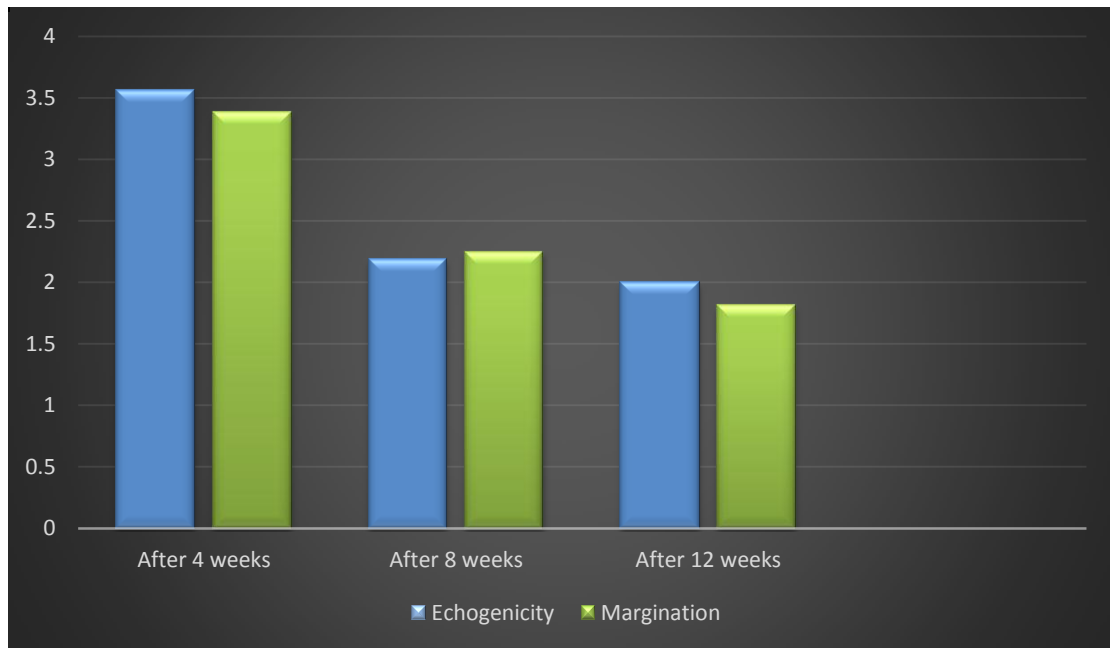
\*: Statistically significant at  $p \leq 0.05$



**Image 1:** Thickness of cut FDP in right ring finger after 4<sup>th</sup> and 12<sup>th</sup> weeks of surgical repair respectively.



**Figure 1:** Assessment of total active motion (TAM) and grip strength of the affected hand (% of normal side) after 8th and 12th weeks of rehabilitation program.



**Figure 2:** Assessment of echogenicity and margination of healing flexor tendon by ultrasound after 4th, 8th and 12th weeks of rehabilitation program.

UNDER PEER REVIEW