

Original Research Article

Prospective Study: The Analgesic Efficacy of Ultrasound-Guided Erector Spinae Plane Block versus Serratus Plane Block in Patients Undergoing Modified Radical Mastectomy

Abstract:

Background: Breast Cancer is the most commonly occurring cancer affecting women undergoing modified radical mastectomy, causing acute pain, and in high percentage of patients it progresses to chronic pain syndromes. The Erector Spinae Plane Block (ESPB) and Serratus Anterior Plane Block (SAPB) are options of regional anesthesia that can produce reliable analgesia. In this study we aimed to evaluate the analgesic efficacy of ultrasound guided ESPB and SAPB in patients underwent modified radical mastectomy operation.

Patients and Methods: Patients were randomly classified using computer generated numbers concealed in sealed opaque envelopes into three equal groups; 30 patients were enrolled in each group. Group I: Control Group (C): Patients received intravenous (IV) systemic analgesia only, Group II: ESPB group: Patients received ipsilateral ultrasound guided ESPB using 20 ml bupivacaine 0.25% at the level of the 4th thoracic segment (T4). and Group III: SPB group: Patients received ipsilateral serratus plane block using 30 ml bupivacaine 0.25% at the level of the 5th rib.

Results: In this study, 113 patients were assessed for eligibility, 16 patients did not meet the criteria and 7 patients refused to participate in the study. The remaining 90 patients were randomly allocated into three groups (30 patients in each). All patients (90) were followed-up and analyzed statistically.

Conclusion: Ultrasound-guided SAPB and ESPB provided effective post-operative analgesia in patients undergoing modified radical mastectomy with lower pain scores, less peri operative analgesic consumption and longer duration of analgesia in SAPB.

Keywords: erector spinae plane block, serratus plane block and serratus anterior muscle

Introduction:

Breast cancer is the most common nonepidermal female cancer for which surgery is a primary form of treatment^(1, 2). Most of patients who undergo breast cancer surgery experience acute postoperative pain and may develop persistent chronic pain after surgery⁽³⁾.

Persistent untreated pain may adversely affect various body systems including endocrine, cardiovascular, immune, neurologic, and musculoskeletal systems and require aggressive treatment of pain as well as the resulting complications⁽⁴⁾.

Methods used to control pain following breast surgeries include pharmacological analgesics, both oral and intravenous, as well as more

invasive techniques utilizing local anesthetics, such as erector spinae plane block (ESPB) and serratus plane block (SPB)⁽⁵⁾.

Ultrasound-guided ESPB is a regional analgesic technique originally described by Forero et al for the management of thoracic neuropathic pain. It recently gained popularity because it is much safer and easily administered than other alternative regional techniques⁽⁶⁾.

ESB is reported to have analgesic effect on somatic and visceral pain by affecting the ventral rami of spinal nerves and rami communicantes that include sympathetic nerve fibers, as local anesthetics spread through the paravertebral space⁽⁷⁾.

SPB have been proposed as alternative for post mastectomy analgesia with the advantages of simplicity and ease of performance^(8,9). SPB, initially described by Blanco, can provide complete analgesia of the lateral part of the thorax through blockade of lateral cutaneous branches of the thoracic intercostal nerves between the serratus anterior muscle (SAM) and the external intercostal muscle⁽⁸⁾

Aim of the work

The aim of this study was to compare the preemptive analgesic efficacy of ultrasound-guided erector spinae plane block versus serratus plane block in patients undergoing modified radical mastectomy.

Patients and methods

This prospective randomized controlled double-blind study was carried out on 90 female patients scheduled for unilateral modified radical mastectomy in Oncology Surgery Department, Tanta University Hospital from November 2019 to April 2020 after approval from Institutional Ethical Committee. All patients and investigators were blinded through the whole duration of the study.

An informed written consent was obtained from all patients. Every patient received an explanation of the purpose of the study. All participants' data were confidential with secret codes and in a private file for each patient. Research results were only used for scientific purpose.

• Inclusion criteria:

Female patients, aged 21-60 years, American Society of Anesthesiologists (ASA) physical status I- II, scheduled for unilateral modified radical mastectomy.

• Exclusion Criteria:

Patient refusal, coagulation disorders, body mass index > 35 kg/m², uncooperative or psychiatric patients, infection at the injection site, drug or alcohol abuse and patients with history of allergy to local anesthetics.

• Group allocation

Patients were randomly classified using computer generated numbers concealed in sealed opaque envelopes into three equal groups; 30 patients were enrolled in each group.

• **Group I: Control Group (C):** Patients received IV systemic analgesia only

• **Group II: Erector Spinae Plane Block (ESPB) group:** Patients received ipsilateral ultrasound guided ESPB using 20 ml bupivacaine 0.25% at the level of the 4th thoracic segment (T4).

• **Group III: Serratus Plane Block (SPB) group:** Patients received ipsilateral serratus plane block using 30 ml bupivacaine 0.25% at the level of the 5th rib.

• **Preoperative:** Evaluation of medical and surgical histories of the patient, clinical examination. assessment of the laboratory investigations including complete blood picture, prothrombin time and activity, liver functions and renal functions and the study protocol,

ESPB, SPB and the visual Analog Scale (VAS) for pain assessment (0-100; where 0 represents no pain and 100 represents the worst pain) were explained to each patient during the preoperative visit.

- **Intraoperative** On arrival at the preoperative holding area, a peripheral intravenous (IV) line was secured and all patients were pre-medicated using midazolam 0.03 mg/kg IV. In the operating room (OR), all patients were connected to standard monitors including noninvasive blood pressure, electrocardiogram, and pulse oximetry. General anesthesia technique was standardized for all patients. Anesthesia was induced using IV propofol 2 mg/kg, cisatracurium 0.15 mg/kg, and fentanyl 1µg/kg. After endotracheal intubation, anesthesia was maintained with isoflurane 1 MAC in oxygen–air mixture in (50%–50%) and cisatracurium increments. Patients were mechanically ventilated with ventilatory parameters adjusted to maintain end-tidal carbon dioxide between 35 and 40 mmHg. After induction of general anesthesia, the regional anesthetic technique was performed according to

group allocation by a dedicated anesthesiologist who has no subsequent role in the study.

Blocks were performed by ultrasound machine Philips CX50 Extreme edition equipped with high and low frequency probes

Technique of ultrasound guided ESPB⁽¹⁴⁾: Patients were placed in the lateral decubitus position. In the majority of patients we use a high frequency (10-15 MHz) linear-array transducer because it provides a high resolution image; however a low-frequency (5-2MHz) curvilinear probe is useful in more obese patients where the transverse processes lie at a depth greater than 4 cm. The ultrasound probe was positioned longitudinally at the level of the T4 spinous process and then placed 3 cm laterally from the midline to the side involved in the surgery. The ultrasound landmarks, T4 transverse process, and the overlying trapezius, rhomboideus, and erector spinae muscles were identified. Under aseptic conditions, an 18-gauge echogenic needle was inserted in-plane at an angle of 30–40° in the cranial-to-caudal direction until the tip contacted the T4 transverse process. After the hydrodissection with 2–3 mL of isotonic saline solution confirmed the

correct needle tip position, 20 mL of 0.25% bupivacaine was injected in the interfascial plane between the transverse process and erector spinae muscle. Local anesthetic spread in a fascial longitudinal pattern deep to the erector spinae muscle was visualized using ultrasound guidance.

Technique of ultrasound-guided SPB (8):

While the patient in the supine position arm abducted, the ultrasound probe was placed over the mid-clavicular region of the thoracic cage in a sagittal plane. Ribs were counted until the fifth rib is identified in the mid axillary line. The latissimus dorsi (superficial and posterior), teres major (superior) and serratus muscles (deep and inferior) were identified overlying the fifth rib. The needle depth required to reach the identified region was between 1-2 centimeters. As an extra reference point, the thoracodorsal artery was used; this aids in the identification of the plane superficial to the serratus muscle. 30 mL 0.25% bupivacaine was injected between latissimus dorsi and serratus anterior muscles at the 5th rib level in the mid axillary line.

• Postoperative Postoperatively, patients were admitted to the post anesthesia care unit (PACU), where 1 g of IV paracetamol was infused immediately after admission and then repeated every 6 hours.

All parameters and study outcomes were recorded by a research anesthesiologist who is blinded to group assignment.

Postoperative pain was assessed using VAS at admission to the PACU and 30 minutes, 1 hour, 2 hours, 4 hours, 6 hours, 8 hours, 12 hours, 18 hours, and 24 hours postoperatively. Rescue analgesia in the form of 3 mg IV morphine was given if the VAS is ≥ 40 up to 10 mg every 4 hours as needed for severe acute pain in hospitalized patients at low risk for respiratory depression⁽¹⁰⁾ and the total 24 h consumption was recorded. Time to the first rescue analgesic request was also recorded.

- Measurements: • Demographic data (age, BMI and ASA physical status) and duration of surgery.
- Intraoperative fentanyl consumption.
- VAS was recorded at PACU, 0.5, 1, 2, 4, 6, 8, 12, 18 and 24 hours postoperatively.
- Postoperative rescue analgesia (morphine) consumption in the first 24 h.
- Time to the first rescue analgesic request.
- Any intraoperative or postoperative complications such as nausea,

vomiting, hematoma, hypotension,
bradycardia, or pneumothorax

- Patient satisfaction was assessed using a 3-point scale (1= unsatisfied 2= fair 3= satisfied).

Statistical analysis

Statistical analysis was performed using the Statistical Package for the Social Sciences version 25 (IBM Inc., Chicago, IL, USA).

Shapiro-Wilks normality test and histograms were used to test the distribution of quantitative variables to select accordingly the type of statistical testing: parametric or nonparametric.

Parametric variables (e.g. age) were expressed as mean and standard deviation (SD) and were compared using F test among the three groups with post hoc (LSD) test to compare each two groups. Comparison between two variables within the same group was compared by paired T test.

Non-parametric variables were expressed as median and interquartile range (IQR) and were analyzed using Kruskal-Wallis test; further analysis was performed by Mann-Whitney (U) test to compare each two groups. Comparison between two variables within the same group was compared by Wilcoxon test.

P value \leq 0.05 was considered statistically significant.

Results

Table (1) shows Comparison of demographic data (age, Weight, height, BMI and ASA status) among the three

groups. Demographic data were comparable between the studied groups P value (0.181, 0.349, 0.655, 0.282, 0.690) respectively.

Table (2) figure (1) shows comparison of VAS score among the studied groups.

VAS was significantly different among the three groups at 0.5, 1, 2, 4, 6, 8,12,18 and 24 hours (P <0.001)

VAS was decreased significantly in ESPB group compared to Control group at 0, 0.5, 1, 2, 4, 6, 8,12,18 and 24 hours P1 less than 0.05 at all times Also VAS was decreased significantly in SAPB group than in control group in 0, 0.5, 1, 2, 4, 6, 8,12, 18 and 24 h P2 less than 0.05 at all times.

There was insignificantly different between group II and group III regarding vas.

Table (3) figure (2) shows complications among groups

Nausea and vomiting occurred in 9 (30%) patients in group I, in 3 (10%) patients in group II and in 2 (60.7%) patients in group III. Hypotension occurred in 4 (13.3%) patients in group I, in 3 (10 %) patients in group II and in 3 (10 %) patients in group III.

Nausea and vomiting increased significantly in group I than group III and group II (P = 0.026) and showed insignificantly different between group II and group III. Hypotension showed insignificant difference among the three groups (P = 0 and 0.894 respectively).

Table (4) figure (3) shows patients satisfaction among the 3 groups.

Regarding patient satisfaction, there was no statistically significant difference

among the 3 groups comparison (P =0.108)

Table (1): Comparison between the studied groups according to demographic data

		Group I (C group)	Group II (ESPB)	Group III (SAPB)	P value
Age (years)	Mean ±SD	49.4 ± 6.24	49.9 ± 6.56	46.8 ± 7.86	0.181
Weight (kg)	Mean ±SD	75.11 ± 10	73.83 ± 9.7	71.55 ± 9.0	0.349
Height (cm)	Mean ±SD	165.5 ± 5.58	164.7 ± 5.16	166 ± 5.02	0.655
BMI (kg/m ²)	Mean ±SD	27.4 ± 3.3	27.2 ± 3.5	26.0 ± 3.0	0.282
ASA	ASA I	26 (86.7%)	28 (93.3%)	27 (90%)	0.690
	ASA II	4 (13.3%)	2 (6.7%)	3 (10%)	

Data is presented as (Mean ± SD) or patient number (%)

χ^2 : Chi square test

MC: Monte Carlo

F: F for ANOVA test

p: p value comparing between the three groups

Table (2): Visual analogue scale (VAS) among the three groups

		0h	0.5h	1h	2h	4h	6h	8h	12h	18h	24h
Group I control (n = 30)	Mean	32.3	39.3	50.0	38.0	42.3	43.7	43	42	52	33.7
	SD	8.98	14.13	10.83	13.24	7.28	11.59	9.88	10.31	10.31	11.89
Group II ESP (n = 30)	Mean	26.7	28.7	23.7	25	23	29.7	31.3	32.7	41	25.3
	SD	7.1	8.2	10.3	13.8	15.1	10.9	13.8	17.2	9.2	8.6
Group III SAPB (n = 30)	Mean	23.7	26	22	24.3	22.7	27	29.3	32.3	37	23.7
	SD	10.6	9.7	11.6	7.7	11.1	10.9	14.8	10.4	12.1	7.6
P value		0.001*	0.001*	0.001*	0.001*	0.001*	0.001*	0.001*	0.007*	0.001*	0.001*
P1		0.017*	0.001*	0.001*	0.001*	0.001*	0.001*	0.025*	0.007*	0.011*	0.001*
P2		0.001*	0.001*	0.001*	0.001*	0.001*	0.001*	0.001*	0.005*	0.001*	0.001*
P3		0.205	0.349	0.556	0.829	0.912	0.357	0.554	0.924	0.148	0.501

Data is presented as Mean (±SD)

*significant change as P value <0.05, P1: P value between group I and group II, P2: P value between group I than group III, P3: P value between group II and group III

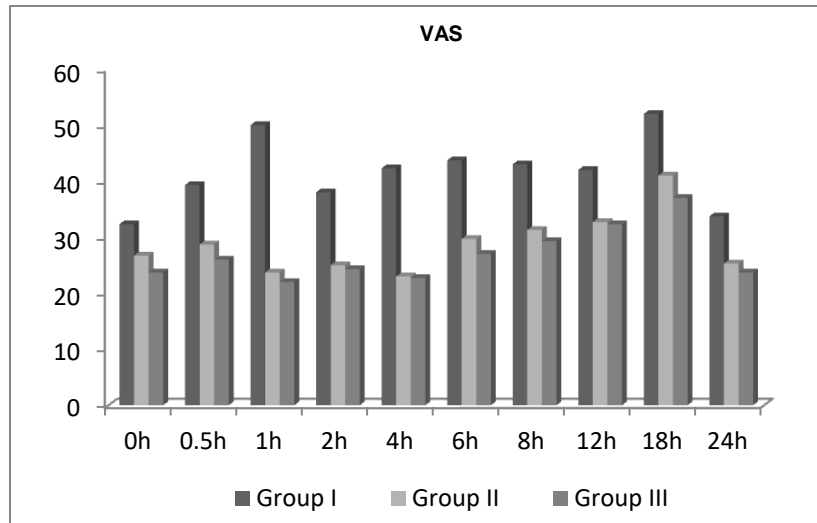


Figure (1): Visual analog scale (VAS) among the three groups

Table (3): Complications among groups

	Group I (n = 30)	Group II (n = 30)	Group III (n = 30)	P value	P1	P2	P3
Nausea and vomiting	9 (30%)	3 (10%)	2 (6.7%)	0.026*	0.053	0.020*	0.640
Hypotension	4 (13.3%)	3 (10%)	3 (10%)	0.894	0.688	0.688	1.0

Significant change as P value <0.05, P1: P value between group I and group II, P2: P value between group I than group III, P3: P value between group II and group III

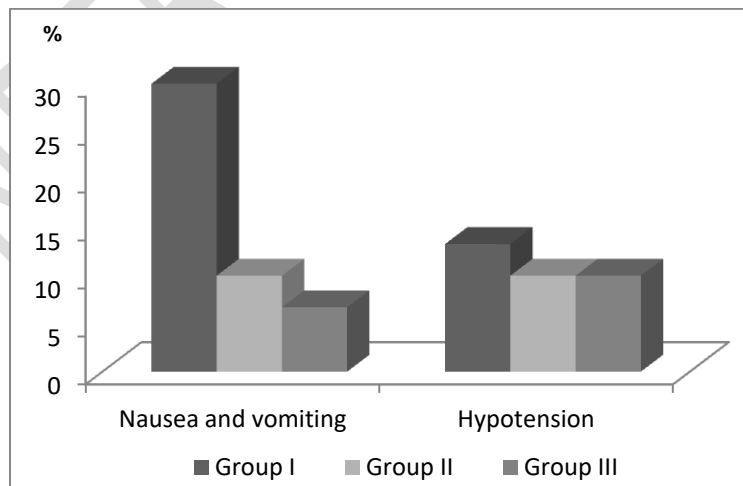


Figure (2): Complications among groups

Table (4): Patient satisfaction in groups

	control group (n = 30)	ESPB group (n = 30)	SAPB group (n = 30)
Very satisfied	15 (50 %)	20 (66.7%)	25 (83.3%)
Satisfied	8 (26.7 %)	5(16.7%)	3 (10%)
Not satisfied	7 (23.3%)	5 (16.7%)	2 (6.7%)
P value	0.108		

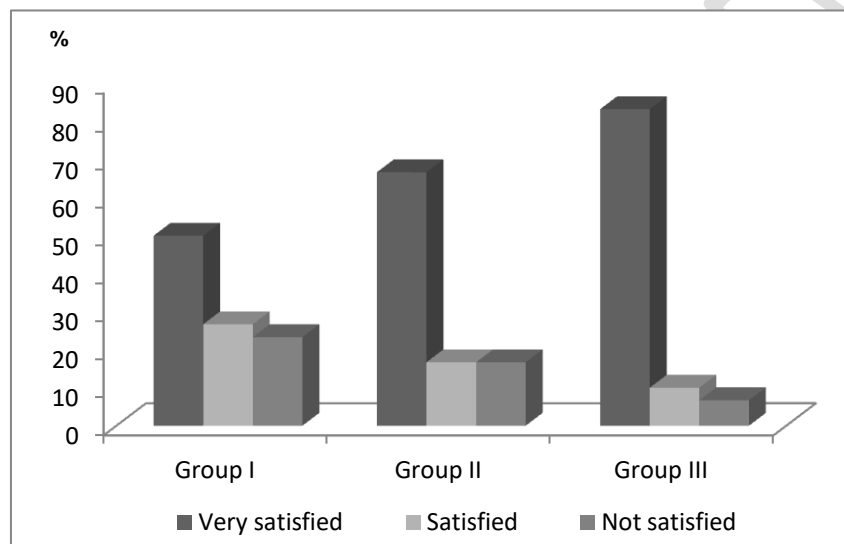


Figure (3): Patient satisfaction in groups

Discussion

Female cancer breast statistics shows that in every eight women, there is one develops cancer breast during their lifetime ⁽¹¹⁾. The most common surgical procedure for cancer breast is modified radical mastectomy (MRM), which removes entire breast with axillary evacuation and a generous amount of skin ⁽¹²⁾. Patients undergoing breast surgery experience marked acute pain postoperatively (about 60%). The axillary component of the surgery is

responsible of the majority of this pain ⁽¹³⁾.

Regional anaesthesia has a promising role in pain management after breast surgeries. Thoracic epidural ⁽¹⁴⁾, interscalene brachial plexus block ⁽¹²⁾, paravertebral block ^(15, 16) pectoral nerve I and pectoral nerve II blocks ⁽¹⁷⁾ have been used in different studies with good results. A newly described technically simple regional block, ultrasound-guided erector spinae plane (US-guided ESP) block can also be used effectively for this purpose ^(7, 18, 19). This block can

be given for MRM surgery as an adjuvant to anaesthesia similar to the thoracic epidural block which is considered the gold standard for postoperative pain management, but without its haemodynamic side effects

SPB have been proposed as alternative for post mastectomy analgesia with the advantages of simplicity and ease of performance^(8, 9). SPB initially described by Blanco, can provide complete analgesia of the lateral part of the thorax through blockade of lateral cutaneous branches of the thoracic intercostal nerves between the serratus anterior muscle (SAM) and the external intercostal muscle⁽⁸⁾.

The aim of this study was to compare the preemptive analgesic efficacy of ultrasound-guided erector spinae plane block versus serratus plane block in patients undergoing MRM. Primary outcome was the total rescue analgesia consumption in the first 24 hours postoperative. Secondary outcomes were postoperative VAS, time to first rescue analgesic request and intraoperative fentanyl consumption.

Patients were randomly classified using computer generated numbers concealed in sealed opaque envelopes into three equal groups; 30 patients were enrolled in each group.

Group I Control Group (C): Patients received IV systemic analgesia only.

Group II (ESPB) group: Patients received ipsilateral ultrasound guided ESPB using 20 ml bupivacaine 0.25% at the level of the 4th thoracic segment (T4).

Group III (SPB) group: Patients received ipsilateral serratus plane block using 30 ml bupivacaine 0.25% at the level of the 5th rib.

The specific mechanism of the ESP block involves local anesthetic diffusion in a cephalad-to-caudal direction in the erector spinae plane. It may enter the paravertebral space through the connective tissue complex attached to the transverse process, and then on through the intervertebral foramen. Therein, the ventral and dorsal branches of the spinal nerve are blocked⁽²⁰⁾

Our study showed that ultrasound guided SAPB and ESPB provided effective post-operative analgesia in patients undergoing MRM with lower VAS score than controlled group, in addition the total rescue analgesia consumption in the first 24 hours postoperative was decreased significantly in SAPB and ESPB than control group and was decreased significantly in SAPB group than ESPB group. Also there was a significant delay in the onset of first rescue analgesia post operatively in SAPB group than ESPB and control group. However, fentanyl needs intraoperatively decreased significantly in SAPB and ESPB than control group.

The incidence of PONV is lower in SAPB and ESPB groups than control group other complications in groups was insignificantly different also patient satisfaction more in SAPB and ESPB groups than control group.

Up to date there is no available trial comparing the analgesic efficacy of (ESPB) versus (SAPB) in patient undergoing modified radical mastectomy operation.

in our result VAS score is nearly similar in SAPB and ESPB groups but the amount of total rescue morphine is higher in ESPB than SAPB group this explained by that SAPB apply good analgesia to axilla and nipple areola

complex by blocking anterior divisions of the lateral cutaneous branches of the T4 and T5 intercostal nerves and the terminal branches of the ACBs

Our results were agreed with **AMIN S.R et al (21)**. Who conducted prospective study on 60 female patients undergoing mastectomy surgery. Patients were randomized into two groups: the (TPVB) group (n=30) included patients who received paravertebral block at T4 with 20 ml of bupivacaine 0.25% and adrenalin 5 µg/ml and the SAPB group (n=30) patients who received serratus intercostal plane block with 0.4 ml/kg bupivacaine 0.25% plus adrenalin 5 µg/ml. Both performed as single injection at the end of surgery. They concluded that The total dose of rescue analgesic in the first 24 hours postoperative was significantly lower in SAPB compared with the TPVB and visual analog scale scores were significantly lower in the SAPB group compared with the TPVB group at 12th and 16th hour postoperatively. Time to the first analgesic dose was significantly longer in the SAPB compared with the TPVB. There was no significant difference between the study groups regarding the hemodynamic parameters and incidence of postoperative nausea and vomiting. .

Also, **Bakeer A.H et al (22)** investigated One-hundred and eighty adult females scheduled for MRM were randomly allocated to groups. PECS group patients received a PECSII block with 30mL of bupivacaine 0.25%, whereas SAPB group received a serratus anterior plane block (SAPB) using the same volume of bupivacaine 0.25% before induction of anesthesia. The control group received general anesthesia alone. They revealed that Both PECSII and serratus blocks

were associated with reduced postoperative morphine consumption compared to the control group ($p<0.001$). Both blocks were associated with reduced intraoperative fentanyl requirements, VAS scores, and PONV as compared with the control group. Also, they were associated with prolonged time to first rescue analgesia and better sedation scores in comparison with the control group. However, there were no differences between both blocks for all outcomes.

In addition, **Mazzinari G. Et al. (23)** carried out double-blind, randomized controlled study on 60 adult females undergoing oncologic breast surgery. After general anesthesia, patients were randomly allocated to either conventional analgesia (control group, n=30) or single-injection serratus block with L-bupivacaine 0.25% 30mL (study group, n=30) First 24-hour total morphine consumption (primary outcome), pain scores at 1, 3, 6, 12, and 24 hours, time-to-first opioid rescue analgesia, and adverse effects were recorded and revealed that 24 hours' opioid dose was greater in the control group Proportional odds model showed that the study group has a lower probability of receiving opioid drugs (while mastectomies have a higher probability of receiving them .Pain scores in the study group were significantly lower throughout the follow-up period. Control group subjects needed earlier morphine rescue and had a higher risk of rescue dose requirement.

Moreover, **Singh S et al. (24)** investigated 40 females ASA 1 or 2 posted for MRM randomly allocated into Group 1 (control group) and group 2 (ESP group). Patients in Group 1 received only general anaesthesia (GA)

and were managed for pain postoperatively according to routine protocol, while group 2 (ESP group) patients received pre-operative unilateral US-guided ESP block (20 mL 0.5% bupivacaine) followed by GA. They found that: Postoperative morphine consumption was significantly less in patients receiving US-guided ESP block compared to control group. and. All the patients in control group required supplemental morphine postoperatively compared to only two patients requiring that in US-guided ESP block group

Also, **Gad M et al** ⁽²⁵⁾: investigated fifty patients who were allocated randomly into two groups. Forty-seven patients were included in the final analysis after exclusion. ESP block group (E group, n = 24) received 20 mL of 0.25% levobupivacaine plus 0.5 µg/kg dexmedetomidine. PECS block group (P group, n = 23) received 30 mL of 0.25% levobupivacaine plus 0.5 µg/kg dexmedetomidine divided into 10 mL that was injected between the two pectoralis muscles in the interfascial plane and the other was 20 mL injected between the serratus anterior and the pectoralis minor. They found that Postoperative morphine consumption and stress hormone level in P group were significantly lower than E group. The pain scores and number of patients requested analgesic postoperatively showed significantly higher values in E group. Hemodynamic parameters, fentanyl needed intraoperatively and the incidence of postoperative complications recorded no significant difference between the two groups.

Furthermore, **Ahmed M.I et al** ⁽²⁶⁾ investigated sixty female patients scheduled for elective mastectomy. Patients were allocated into 2 groups. Group (TE) patients underwent

ultrasound guided single-shot TEA (thoracic epidural analgesia), while group (ES) were handled with ultrasound guided single-shot ESP block. Peri-operative details, Post-operative hypotension, visual analogue scale (VAS) assessment of pain, number of post-operative morphine boluses, and patient satisfaction were recorded. They found that Group (ES) patients reported significantly lower pain scores according to VAS ($P < 0.001$). Hypotension was more recorded in group (TE) patients, Required post-operative morphine boluses were significantly lower in group (ES), More patients were highly satisfied in group ES (60%) than group TE (30%) ($p = 0.037$).

Moreover, **Ghamry M.R et al.** ⁽²⁷⁾ evaluated the efficacy of use erector spinae plane block (ESPB) and Thoracic paravertebral block (TPVB) in controlling post-mastectomy pain. 70 adult female patients, scheduled for modified radical mastectomy. Patients randomized into two groups, receiving 20 ml of 0.25% bupivacaine: group I (TPVB) and group II (ESPB). They found Post-operative 24 h morphine consumption and time of the first request for analgesia were comparable between both groups. There was no significant difference in the intra-operative fentanyl consumption. There was also no significant difference in VAS between both groups over the 24 h of study. Four patients in group I developed pneumothorax with no significant differences between both groups. Incidence of nausea and vomiting was comparable between both groups. All patients displayed a stable haemodynamic profile.

Conclusion

Based on our findings, the Ultrasound-guided SAPB and ESPB provided effective post-operative analgesia in patients undergoing modified radical mastectomy with lower pain scores, less peri operative analgesic consumption and longer duration of analgesia in SAPB.

COMPETING INTERESTS DISCLAIMER:

Authors have declared that no competing interests exist. The products used for this research are commonly and predominantly use products in our area of research and country. There is absolutely no conflict of interest between the authors and producers of the products because we do not intend to use these products as an avenue for any litigation but for the advancement of knowledge. Also, the research was not funded by the producing company rather it was funded by personal efforts of the authors.

References

1. Terkawi AS, Tsang S, Sessler DI, Terkawi RS, Nunemaker MS, Durieux ME, et al. Improving Analgesic Efficacy and Safety of Thoracic Paravertebral Block for Breast Surgery: A Mixed-Effects Meta-Analysis. *Pain physician*. 2015;18(5):E757-80.
2. Biskup E, Vetter M. How to overcome endocrine resistance in early and metastatic breast cancer. *Ann Oncol*. 2018;1(1005):1-6.
3. Poleshuck EL, Katz J, Andrus CH, Hogan LA, Jung BF, Kulick DI, et al. Risk factors for chronic pain following breast cancer surgery: a prospective study. *The journal of pain*. 2006;7(9):626-34.
4. Greenberg E. The Consequences of Chronic Pain. *J Pain Palliat Care Pharmacother*. 2012;26:64-7.

5. Abstracts and Highlight Papers of the 37th Annual European Society of Regional Anesthesia & Pain Therapy (ESRA) Congress 2018: Invited Speakers. *Reg Anesth Pain Med*. 2018;43(7):1-41.
6. Forero M, Adhikary SD, Lopez H, Tsui C, Chin KJ. The Erector Spinae Plane Block: A Novel Analgesic Technique in Thoracic Neuropathic Pain. *Reg Anesth Pain Med*. 2016;41(5):621-7.
7. Bonvicini D, Tagliapietra L, Giacomazzi A, Pizzirani E. Bilateral ultrasound-guided erector spinae plane blocks in breast cancer and reconstruction surgery. *Journal of clinical anesthesia*. 2018;44:3-4.
8. Blanco R, Parras T, McDonnell JG, Prats-Galino A. Serratus plane block: a novel ultrasound-guided thoracic wall nerve block. *Anaesthesia*. 2013;68(11):1107-13.
9. Chakraborty A, Khemka R, Datta T. Ultrasound-guided truncal blocks: A new frontier in regional anaesthesia. *Indian journal of anaesthesia*. 2016;60(10):703-11.
10. Birnbaum A, Esses D, Bijur PE, Holden L, Gallagher EJ. Randomized double-blind placebo-controlled trial of two intravenous morphine dosages (0.10 mg/kg and 0.15 mg/kg) in emergency department patients with moderate to severe acute pain. *Annals of emergency medicine*. 2007;49(4):445-53. e2.
11. DeSantis C, Ma J, Bryan L, Jemal A. Breast cancer statistics, 2013. *CA: a cancer journal for clinicians*. 2014;64(1):52-62.
12. Kaya M, Oğuz G, Şenel G, Kadioğulları N. Postoperative analgesia after modified radical mastectomy: the efficacy of interscalene brachial plexus block. *Journal of anesthesia*. 2013;27(6):862-7.
13. Fecho K, Miller NR, Merritt SA, Klauber-Demore N, Hultman CS, Blau WS. Acute and persistent postoperative pain after breast surgery. *Pain medicine (Malden, Mass)*. 2009;10(4):708-15.
14. Doss NW, Ipe J, Crimi T, Rajpal S, Cohen S, Fogler RJ, et al. Continuous thoracic epidural anesthesia with 0.2%

ropivacaine versus general anesthesia for perioperative management of modified radical mastectomy. *Anesthesia and analgesia*. 2001;92(6):1552-7.

15. Kairaluoma PM, Bachmann MS, Korpinen AK, Rosenberg PH, Pere PJ. Single-injection paravertebral block before general anesthesia enhances analgesia after breast cancer surgery with and without associated lymph node biopsy. *Anesthesia and analgesia*. 2004;99(6):1837-43.

16. Schnabel A, Reichl SU, Kranke P, Pogatzki-Zahn EM, Zahn PK. Efficacy and safety of paravertebral blocks in breast surgery: a meta-analysis of randomized controlled trials. *British journal of anaesthesia*. 2010;105(6):842-52.

17. Blanco R. The 'pecs block': a novel technique for providing analgesia after breast surgery. *Anaesthesia*. 2011;66(9):847-8.

18. Singh S, Chowdhary N. Erector spinae plane block an effective block for post-operative analgesia in modified radical mastectomy. *Indian journal of anaesthesia*. 2018;62(2):148-50.

19. Finneran JJT, Gabriel RA, Khatibi B. Erector Spinae Plane Blocks Provide Analgesia for Breast and Axillary Surgery: A Series of 3 Cases. *Reg Anesth Pain Med*. 2018;43(1):101-2.

20. Chin K, Adhikary S, Sarwani N, Forero M. The analgesic efficacy of pre-operative bilateral erector spinae plane (ESP) blocks in patients having ventral hernia repair. *Anaesthesia*. 2017;72(4):452-60.

21. Amin SR, Abdelrahman EA, Afify EES, Elsayed EM. Ultrasound-Guided serratus anterior plane block versus thoracic paravertebral block for postmastectomy analgesia. *BMFJ*. 2018;35(3):429-36.

22. Bakeer AH, Kamel KM, Abdelgalil AS, Ghoneim AA, Soud AHA, Hassan ME. Modified Pectoral Nerve Block versus Serratus Block for Analgesia Following Modified Radical Mastectomy: A

Randomized Controlled Trial. *J Pain Res*. 2020;13:1769.

23. Mazzinari G, Rovira L, Casasempere A, Ortega J, Cort L, Esparza-Miñana JM, et al. Interfascial block at the serratus muscle plane versus conventional analgesia in breast surgery: a randomized controlled trial. *Reg Anesth Pain Med*. 2019;44(1):52-8.

24. Singh S, Kumar G, Akhileshwar. Ultrasound-guided erector spinae plane block for postoperative analgesia in modified radical mastectomy: A randomised control study. *Indian journal of anaesthesia*. 2019;63(3):200-4.

25. Gad M, Abdelwahab K, Abdallah A, Abdelkhalek M, Abdelaziz M. Ultrasound-guided erector spinae plane block compared to modified pectoral plane block for modified radical mastectomy operations. *Anesthesia and analgesia*. 2019;13(2):334-33.

26. Ahmed I, Abdelraouf HS. Ultrasound guided Erector Spinae Plane block versus thoracic epidural for post-mastectomy analgesia. *AIMJ*. 2020;1(2):120-4.

27. El Ghamry MR, Amer AF. Role of erector spinae plane block versus paravertebral block in pain control after modified radical mastectomy. A prospective randomised trial. *Indian journal of anaesthesia*. 2019;63(12):1008-14.