

Isolated Extra-osseous Ewing Sarcoma of Vagina-A rare presentation

Abstract

Primary Ewing Sarcoma of vagina is an extremely rare presentation. The atypical site of occurrence and the lack of ample data predispose it to become a substantial challenge in early diagnosis and management. We report a case of isolated Ewing Sarcoma of vagina in a 31 year old female patient who presented with abnormal vaginal discharge and bleeding for around 2 months and was found to have a vaginal mass on clinical examination. The diagnosis was obtained on the basis of sequential investigations with magnetic resonance imaging (MRI), histopathologic and immunohistochemical (IHC) analysis of the lesion followed by the detection of pathognomonic EWSR1 gene rearrangement by FISH (Fluorescent in situ hybridization). The patient was treated aggressively with multimodal strategy including systemic chemotherapy (VAC/IE protocol), followed by surgical resection of the residual disease and local therapy with radiation. However, she had developed local disease recurrence during her treatment which was further salvaged with a combination of systemic chemotherapy (VIT protocol), En-bloc resection and local radiotherapy followed by maintenance Pazopanib to which she had poor tolerance and the interim scan showed development of

multiple hepatic metastases. The patient was transitioned to palliative care and she succumbed to her disease very rapidly.

Introduction:

Ewing Sarcoma is a malignant tumor of bone and soft tissues around the bone such as cartilage or nerves, having more propensity to develop in the long bones. Extra osseous sites of occurrence are heterogenous while vagina still being the rarest (1).

Ewing Sarcoma Family of Tumors (EFT) comprises of a group of small round blue cell tumors naming Osseous Ewing Sarcoma, Extraosseous Ewing Sarcoma, Askin Tumors and Peripheral Primitive Neuroectodermal Tumors (2). Embrologically Ewing Sarcoma Family of Tumors (EFT) tend to derive from the same mesenchymal stem cell origin and hence they are supposed to share the similar histologic and immunohistochemical characteristics (3). In most cases the diagnosis is obtained by a combination of histopathology, immunohistochemistry and molecular analysis.

Histologically all EFTs are composed of small round blue cells with high nuclear to cytoplasm ratio. Expression of CD99 on IHC is highly sensitive for Ewing Sarcoma but lacks specificity (4). In addition, Molecular analysis is considered to be a useful adjunctive tool in confirming the diagnosis and distinguishing amongst different members of the EFT with significant sensitivity and specificity. Reciprocal translocation (11;22)(q24;q12) resulting in the formation of EWSR1-FLI1 fusion gene, is the most common variant which is detectable in up to 85-90% of cases of EFT and is pathognomonic for Ewing Sarcoma (5,6).

Ewing Sarcoma is an overall rare occurrence and represents only 1% of all childhood cancers (7). The most common age of diagnosis is second decade of life, but may present as early as newborn and as late as into the eighth decade, with slightly increased frequency in males. Studies have shown that Extraosseous Ewing Sarcoma has higher mean age (usually in the third or fourth decade of life) than Ewing Sarcoma of bone (8). Racial distribution is more inclined towards Caucasians while African Americans and Asians are rarely affected.

Isolated Ewing Sarcoma of vagina is an extremely rare presentation. This case aims to present different diagnostic modalities, proposed local and systemic treatments to help conclude the proper management in patients with such unusual clinical entity.

Case presentation:

A 31-year-old female with no prior comorbidities presented with complaints of abnormal vaginal discharge and inter-menstrual and post-coital bleeding for about two months, she was nulliparous with no prior history of menstrual irregularities or abnormal vaginal discharge. General physical and systemic examination was unremarkable however her per vaginal examination revealed a firm mass of about 6x5 cm attached to the left posterolateral wall and cervix could not be reached.

Considering her history and examination findings, all relevant workup was carried out. Magnetic resonance imaging of the pelvis reveals a large well capsulated heterogeneously enhancing mass lesion in the region of vagina isointense on T1 and hyperintense on T2 weighted images, measuring 75.8 x 66.8 x 65.5 mm, superiorly abutting the cervix, laterally extending into the paravaginal area, posteriorly abutting the rectum and anterosuperiorly abutting the bladder with intact fat plane. However, no pelvic wall infiltration or pelvic lymphadenopathy was noted. (Figure 1-2)

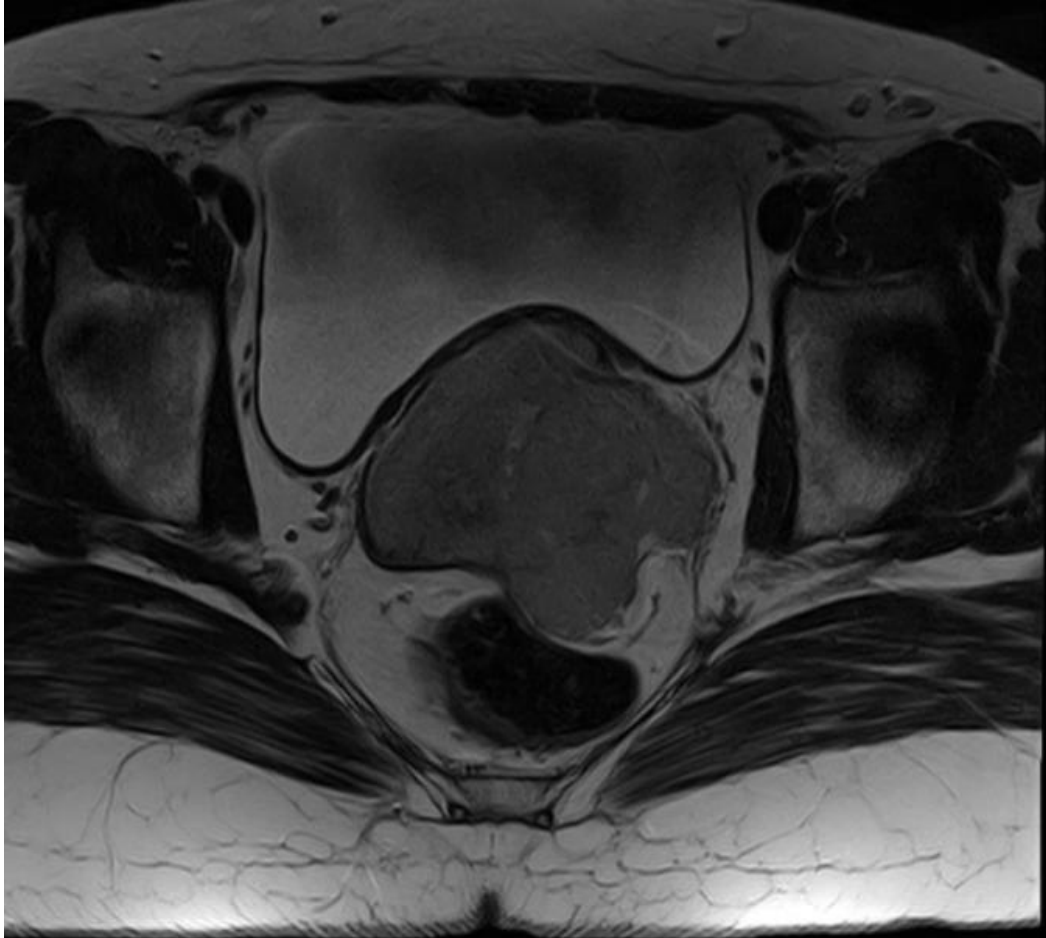

Figure 1. An axial section MRI of the pelvis showing a large encapsulated heterogenous mass

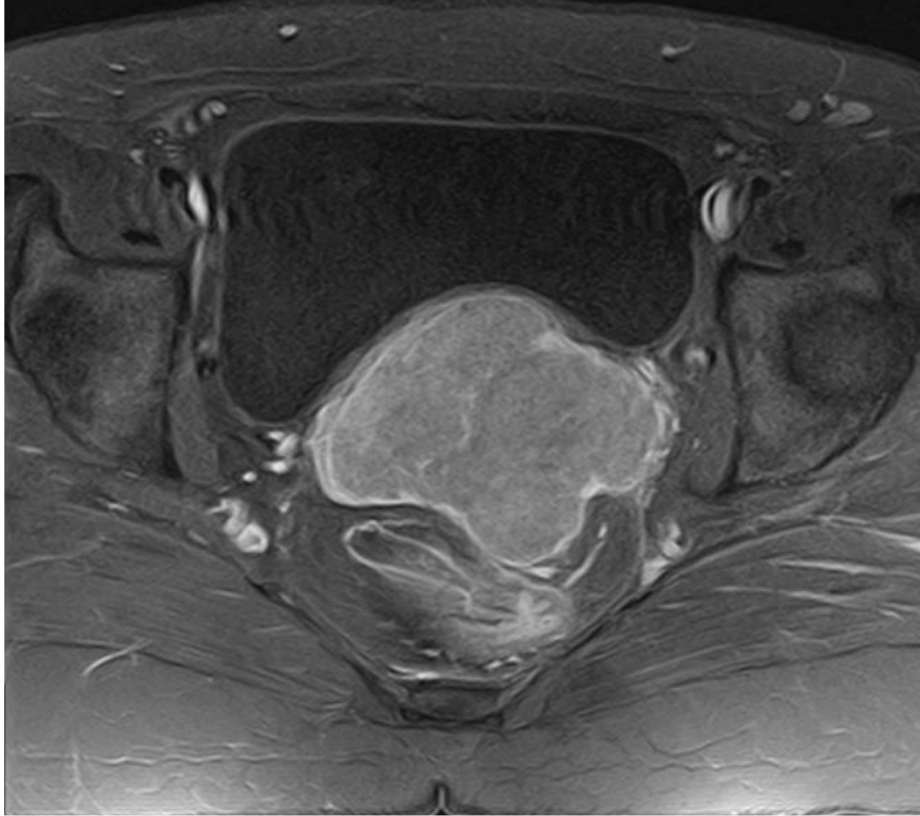

Figure 2.

She further underwent examination under anesthesia which showed a vascular mass of about 6x5cm at the posterolateral wall of vagina. Histopathology revealed squamous mucosa with tumor cells showing high mitotic activity, arranged in clusters and sheets with hyperchromatic nuclei and scanty cytoplasm, Immunohistochemical (IHC) stains showed positivity towards CD99, cyclin-D1 and FLI-1 (Figure 3,4,5,6). A differential diagnosis of malignant undifferentiated neoplasm vs Ewing sarcoma was made. The case was further discussed in the multidisciplinary tumor board meeting and concluded to further confirm the case by the detection of EWSR1 gene translocation (22q12) by FISH which came out to be positive and hence the definitive diagnosis of Ewing Sarcoma of vagina was established.

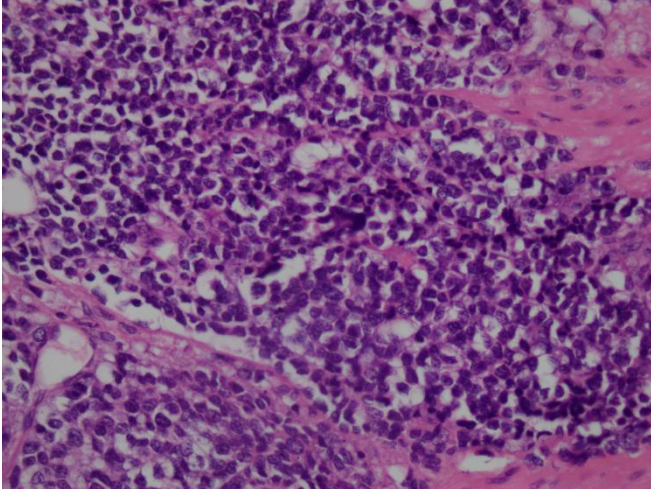


Figure 3. A cross section of the histology specimen showing hyperchromatic cells

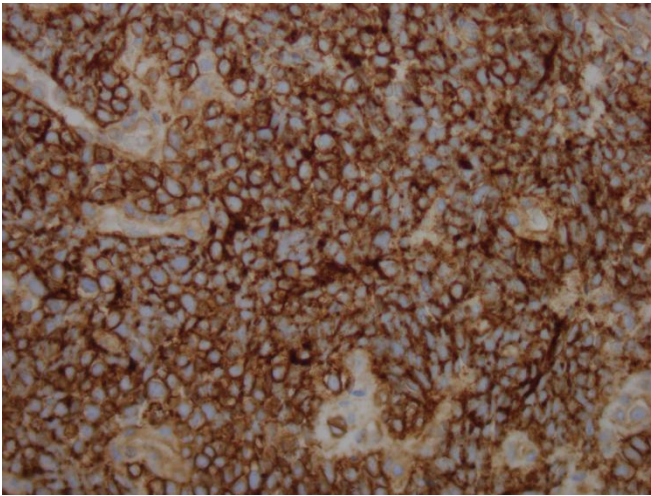


Figure 4. Immunohistochemical staining showing CD99 positivity

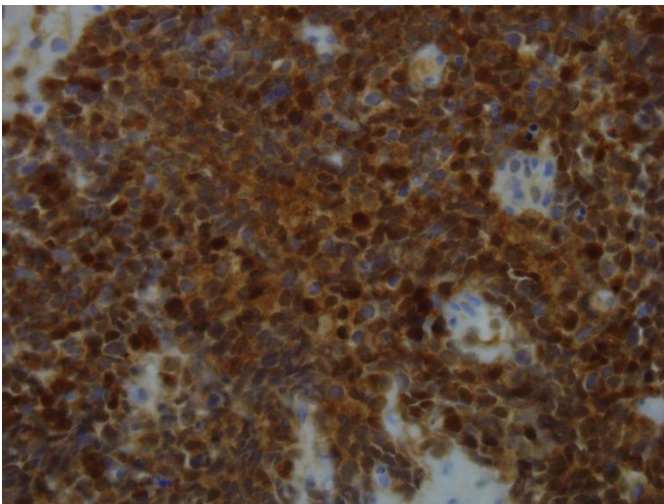


Figure 5. IHC: CYCLIN-D1

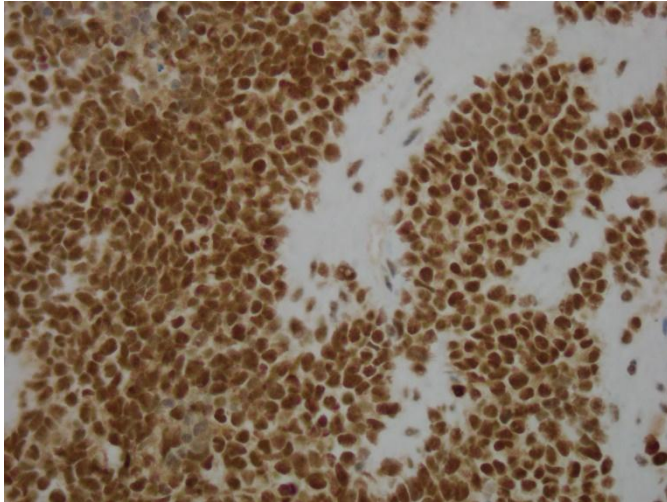


Figure 6. IHC: Fli-1

Her staging PET (positron emission tomography) scan did not show any evidence of visceral or skeletal metastatic disease.

The patient was managed with neoadjuvant chemotherapy, VAC (Vincristine/Doxorubicin/Cyclophosphamide) alternating with IE (Ifosfamide /Etoposide) every three weeks for total of 6 cycles. Disease re-evaluation with repeat imaging showed significant interval reduction in size of the mass suggesting a good response to chemotherapy. She then underwent wide local excision of the residual tumor (less than 5% of the tissue exhibits residual malignancy in the histopathology specimen), followed by local radiotherapy but unfortunately during her treatment, she had developed local disease recurrence with interval appearance of a soft tissue mass involving posterior fornix of vagina extending up to the rectum, she was then started on VIT protocol (Vincristine, Irinotecan, Temozolomide), MRI pelvis showed responsive disease after 3 cycles. Her case was further discussed in multidisciplinary tumor board meeting and she underwent total abdominal hysterectomy with en-bloc resection of the vaginal tumor along with LAR (lower anterior resection) and colostomy formation. Post operatively she received local radiotherapy followed by systemic treatment with Pazopanib. She had poor tolerance to systemic treatment requiring repeated hospital admission. Interim scan showed disease progression with interval development of multiple hepatic metastases, the patient was taken over by palliative care team and she eventually succumbed to her disease very rapidly.

Discussion:

Ewing Sarcoma Family of Tumors (EFT) is a highly malignant tumor of bone and soft tissues around the bone such as cartilage or nerves. The EFT can develop in almost any bone or soft tissue but most commonly arise in the pelvis, axial skeleton and femur (1). Extrasosseous soft tissue occurrence is heterogenous but predominantly have been reported to occur in paravertebral region, lower extremities, chest wall, retroperitoneum, pelvis and hip and intracranial regions, however female genital tract is still believed to be a rare site for these tumors to occur.

Ewing sarcoma family of tumors (ES Ewing Sarcoma/EOS Extra Osseous Sarcoma/PNET Primitive Neuroectodermal Tumor) share identical histological features (i.e. sheets of undifferentiated small-round-blue-cells with high nuclear to cytoplasm ratio), and hence the Immunohistochemical markers such as CD99, LCA, vimentin and cytokeratin can be used to distinguish among these members (9). Cytogenetic analysis by chromosomal gene rearrangement, EWSR1 t(22q12), can also be a useful adjunctive tool in the diagnosis of Ewing sarcoma tumors which is detectable in up to 85-90% of cases (5, 6). Its presence can differentiate Ewing Sarcoma from other sarcomas and provides prognostic and therapeutically relevant information.

25 years based literature review shows that very few cases, nearly 30, of isolated Extrasosseous Ewing Sarcoma related to female genital tract, have been reported till date. The average age of presentation was noticed to be greater than 30 years in most cases and average tumor size being greater than 5cm (10, 11). Approximately 70% of cases showed membranous positivity for CD99 and vimentin and a very few cases were tested for the pathognomonic EWSR1 translocation by FISH. Most of the cases were treated with multimodal strategy including surgery, chemotherapy and radiotherapy. Many of them did not show any metastases at the time of presentation but a very few with mostly of tumor size above 5cm showed liver, bone, lymph nodal or cranial metastases.

Table1. Shows the literature review of all the reported cases of vaginal Ewing Sarcoma worldwide till date. (10, 11)

No.	Author	Age(years)	Tumor size(cm)	IHC profile	Metastases	Treatment	Cytogenetic analysis (EWSR-FLI-1 fusion gene)
1	Habib et al. (1992)	23	1.5	Cytoke ratin, EMA	-	-	
2	Scherr et al. (1994)	10	6.5	-HBA-71	-	Surgery	
3	Paredes et al. (1995)	29	5	Viment in	NA	Surgery, CT and RT	
4	Nirenberg et al. (1995)	20	12	PAS	NA	Surgery,CT and RT	
5	Farley et al. (2000)	35	4	CD99	No	CT and RT	
6	Vang et al. (2000)	35 28	3 0.9	CD99	No	Surgery, CT and RT	T (PCR)
7	Takeshima et al. (2001)	45	3	NSE and	No	Surgery	NA

				Vimentin			
8	Lazure et al. (2001)	15	20	CD99	NA	Surgery and CT	T (PCR)
9	Petkovic et al. (2002)	45	9	CD99	NA	CT and RT	
10	Gaono-Luviano et al. (2003)	34	4	CD99	No	Surgery, CT and RT	
11	Liao et al. (2004)	30	5	CD99, FLI-1	No	Surgery and CT	
12	McCluggage et al. (2007)	19 20 30 40	4 6.5 3 8	CD99, FLI-1 - CD99, FLI-1 CD99, Vimentin, FLI-1	NA	CT NA Surgery and CT CT	T (PCR) T (PCR)
13	Al-Tamimi et al. (2009)	47	3	CD99, Vimentin	No	Surgery, CT and RT	-
14	Yip et al. (2009)	27	2	CD99, Vimentin, Synaptophysin, CD56, NSE	Cranial	Surgery, RT and CT	-
15	Rekhi et al. (2010)	17	10	CD99, Vimentin, BCL2, FLI-1	No	CT and RT	T (FISH)
16	Pang et al. (2012)	54	4	CD99	Inguinal lymph nodes	RT	-

17	Machado et al. (2013)	32	8	ND	Bone	Surgery and CT	T
18	Das et al. (2014)	50	7	CD99, Vimentin	No	CT and RT	-
19	Modi et al. (2015)	30	6	CD99	Bone	CT and RT	T
20	Patel et al. (2016)	45	5.7	ND	Liver	CT and RT	-
21	Maolin et al. (2020)	54	7.5	CD99	No	Surgery and CT	-
22	This case (2020)	31	7.5	CD99, Vimentin	No	CT, Surgery and RT	T (FISH)

CT: Chemotherapy, EWSR1: Ewing sarcoma RNA protein1, FISH (fluorescent in situ hybridization, IHC: Immunohistochemistry, NSE: Neuron specific enolase, PCR: Polymerase chain reaction, RT: Radiotherapy

The main factors determining prognostic significance include the presence or absence of metastases, the primary tumor location and size, older age, response to therapy and the presence of certain chromosomal translocations ([12](#), [13](#)). Although less patients have overt metastases at the time of presentation but many are considered to have subclinical metastasis and hence should be treated aggressively with multimodal approach to improve the overall disease free survival and to reduce the relapse rate which is up to 80-90% in patients with localized disease who receive local therapy alone.

Recommendations:

Multimodal treatment approach is the standard of care for these tumors. Extrasosseous Ewing Sarcoma responds to the same chemotherapy regimen as Osseous Ewing Sarcoma and should be treated similarly ([14](#)). Standard chemotherapy includes alternating cycles of Vincristine/ Doxorubicin/ Cyclophosphamide (VAC) to Ifosfamide/ Etoposide (IE) followed by local therapy to achieve cytoreduction by either surgery, RT or both ([15](#)). And then additional cycles of the same chemotherapy regimen should be offered as adjuvant treatment. Addition of intensive multi agent chemotherapy for localized disease has shown remarkable overall survival benefits with a five-year survival rate up to 70%. Systemic chemotherapy can be offered in patients with metastatic disease with overall survival rate up to 33%.

Conclusion:

Female genital tract is a very uncommon site for Ewing Sarcoma to occur. Our case enlightens the importance of early diagnosis and the use of different diagnostic modalities in patients with unusual clinical presentation. It reinforces the importance of IHC profile along with cytogenetic analysis in

confirming the diagnosis of Ewing Sarcoma at unusual site like vagina. It also explains the poor outcome of this disease such as in this case and encourages the clinicians to integrate aggressive multimodal treatment strategy in such patients for overall survival benefit.

References:

1. <https://www.ncbi.nlm.nih.gov/pmc/articles/PMC4799471/>
2. <https://www.ncbi.nlm.nih.gov/pmc/articles/PMC5686981/#:~:text=The%20term%20round%20cell%20tumor,cells%20that%20are%20slightly%20larger>
3. <https://www.uptodate.com/contents/clinical-presentation-staging-and-prognostic-factors-of-the-ewing-sarcoma-family-of-tumors#H12>
4. <https://www.ncbi.nlm.nih.gov/pmc/articles/PMC5788584/>
5. <https://www.uptodate.com/contents/epidemiology-pathology-and-molecular-genetics-of-the-ewing-sarcoma-family-of-tumors/print>
6. <https://emedicine.medscape.com/article/990378-overview#a5>
7. <https://www.cancer.net/cancer-types/ewing-sarcoma-childhood-and-adolescence/statistics>
8. [https://rarediseases.org/rare-diseases/ewing-sarcoma/#:~:text=The%20annual%20incidence%20of%20Ewing,\(more%20than%20five%20years](https://rarediseases.org/rare-diseases/ewing-sarcoma/#:~:text=The%20annual%20incidence%20of%20Ewing,(more%20than%20five%20years)
9. https://www.uptodate.com/contents/epidemiology-pathology-and-molecular-genetics-of-the-ewing-sarcoma-family-of-tumors?search=Ewing%20sarcoma&source=search_result&selectedTitle=3~96&usage_type=default&display_rank=3#H6
10. <https://www.wjnet.com/2307-8960/full/v7/i21/3671-T3.htm>
11. <https://medcraveonline.com/JCPCR/primary-vaginal-ewing-sarcoma-or-primitive-neuroectodermal-tumor-with-liver-breast-and-lung-metastasis-in-a-45-year-old-woman.html>
12. <https://www.uptodate.com/contents/clinical-presentation-staging-and-prognostic-factors-of-the-ewing-sarcoma-family-of-tumors#H12>
13. <https://emedicine.medscape.com/article/990378-overview#a7>
14. <https://www.uptodate.com/contents/treatment-of-ewing-sarcoma>
15. <https://emedicine.medscape.com/article/990378-guidelines>