

Complete response to Pembrolizumab in a patient with Lynch syndrome: a case report

Abstract

Background: Lynch syndrome LS is a life-threatening condition caused by heterozygous mutations in mismatch repair genes (MMR). People with this syndrome are at increased risk of developing different types of cancers, such as colorectal carcinomas, endometrial cancer, and ovarian cancers.

Case report: The present case report discusses the case of a 36-year-old non-diabetic non-alcoholic female who came to the oncology department with a known history of Lynch syndrome. The patient had a significant past medical history. In 2003, she was diagnosed with left colon cancer for which she had left hemicolectomy followed by adjuvant chemotherapy. In 2004, she developed duodenal cancer for which she had Whipple surgery. Then, she developed ovarian cancer on both sides, which was also treated by surgery and adjuvant chemotherapy. After that, she developed uterine cancer, treated by surgery and adjuvant chemotherapy. The patient had a total colectomy and she underwent two ileostomy procedures. In 2014, immunohistochemistry testing confirmed the diagnosis that she was suffering from Lynch syndrome. Additionally, cancer sequencing panel testing in 2016 and MSH testing in 2018 further confirmed the diagnosis of Lynch syndrome as only the loss of nuclear expression of the PMS2 gene was revealed. Then in 2018, she developed a peritoneal metastasis of ovarian origin. This was the first time she started Pembrolizumab immunotherapy, that was finished at the end of 2019. One intriguing fact is that all her diseases cleared up and she continues to live normal

life four years after stopping immunotherapy and she is in complete remission. Also, all her tumor markers have dropped down and normalized.

Conclusion: Carrying the PMS2 germline mutation confers an extraordinarily high risk of developing LS-associated cancers. To decrease the morbidity and mortality associated with LS-related cancers, intensive clinical monitoring, pembrolizumab therapy, and preventive surgeries are strongly advised.

Keywords: PMS2 gene, Lynch syndrome, colon cancer, multiple cancers, genetic mutations.

Introduction

Lynch syndrome is an autosomal dominant condition, previously recognized as hereditary nonpolyposis colorectal cancer(1). It is linked to an increased risk of acquiring colorectal and other types of cancer. The pathophysiology includes DNA mismatch repair (MMR) genetic mutations, including those in EPCAM, PMS2, MSH2, MLH1, and MSH6(2, 3). The MMR proteins work as dimers (MSH6 with PMS2 and MLH1 with MSH2), and mutations in either of these genes make the MMR system inactive. This allows for the buildup of unstable mismatched DNA in highly repeated microsatellite sequences (microsatellite instability, or MSI) and the steady increase in instability with larger numbers of erroneous DNA segments, leading to eventual gene expression change and carcinogenesis(4).

Lynch syndrome is the most prevalent hereditary cause of endometrial cancer and colorectal cancer (lifetime risk up to 70 percent)(5). It is characterized by rapid carcinogenesis, multiple cancer diagnoses, and cancer development at younger ages. In addition, it is related to an increased risk of epithelial tumors in various organs, including the renal pelvis, central nervous system, pancreas, small intestine, stomach, ovaries, as well as skin cancer (such as sebaceous neoplasia in the Muir-Torre variant)(6). Due to the high lifetime risk of cancer, it is crucial that practitioners are able to identify patients with LS and provide both the patient and at-risk family members with life-saving therapies(7). The following case report describes a patient who presented multiple cancers and was later diagnosed with Lynch syndrome caused by losing the PMS2 gene.

Case report: A 36-year-old non-diabetic, non-alcoholic female with a known family and personal history of Lynch syndrome was presented to the oncology department 19 years back.

She is HRD-positive (Homologous recombinant deficiency).

In 2003, the patient was admitted to the hospital with a major complaint of abdominal pain. At that time, a colonoscopy revealed left colon cancer with no polyposis. She underwent a left hemicolectomy in the United Arab Emirates in June 2003. Additionally, there is no information about the stage of colon cancer, it was stage 3, but she did receive six cycles of adjuvant FOLFOX chemotherapy. The next year, in November 2004, she developed jaundice and was found to have duodenal cancer stage T2N0 and received treatment in Jordan with the Whipple procedure. No adjuvant treatment was given.

Moreover, the next year, in 2005, she again went for a colonoscopy and the colonoscopy revealed a few polyps but the tumor was benign. After the 2005 colonoscopy, a yearly colonoscopy was performed except in 2008. In 2009, the patient was again diagnosed with high-grade dysplasia (HGD) of the colon. She underwent polypectomy. Furthermore, on 27 January 2014, she was subjected to a colonoscopy that revealed hundreds of polyps with a biopsy confirming HGD. One polyp from the transverse colon showed invasive carcinoma with multiple polyps in the rectum. Later, on 3 April 2014, she underwent a total colectomy in Al Noor hospital.

Histopathology showed multifocal (largest is 3x1.5 cm in the rectum) mucinous adenocarcinoma moderately differentiated, grade 2, PT3PN1 (2/36 LN) M0, +LV invasion, negative margin. Pre-operational, computed tomography (CT) scan showed no metastasis. She received six cycles of adjuvant FOLFOX chemotherapy again.

At the end of the year, December 2014, she was diagnosed with serous papillary carcinoma when a biopsy of a left ovarian mass was performed. Although immunohistochemistry showed wt1 negative, the histology was typical for ovarian cancer. She received six cycles of carboplatin+

Taxol. Moreover, on 11 May 2015, she underwent laparotomy, left salpingo-oophorectomy, and omentectomy at Tawam for the removal of the tumor and this was a fertility preserving surgery as per patient wishes.

Additionally, on 19 April 2016, the Cancer NextGen Sequencing Panel showed a homozygous mutation in the PMS2 gene (c.697C>T, p.Gln233*). Doctors suggested that biallelic pathogenic variants in PMS2 caused constitutional mismatch repair deficiency syndrome. During this time, the patient was counseled for that purpose. Later, in June 2016, laparotomy was performed with resection of the peritoneal adenocarcinoma with part of small bowel. Pathology showed primary ovarian metastasis. The patient was given carboplatin and Taxol that was later switched to gemcitabine and Avastin due to intolerability.

Later in November 2017, she progressed in the peritoneal cavity. She was found to be very reluctant to take any chemotherapy, since she had already taken carboplatin + Taxol before. Then, she was given Olaparib 400 mg orally two times a day, but she was found to be non-compliant. The patient stopped the Olaparib medication by herself in March 2018.

So, when she came to our hospital on 25 July 2018, S/P total abdominal hysterectomy and right side salpingo-oophorectomy were performed. S/P Level 1 exploratory laparotomy, extensive adhesiolysis, and ileostomy creation procedures were performed.

Pathology profile revealed stage II serous carcinoma of the endometrium with extensive involvement of cervical stroma (pT2 N0 M0) multifocal mucinous adenocarcinoma moderately differentiated, Grade 2, with lymphovascular invasion (pT3 pN1 (2/36) M0). At that time, BRCA 1 and 2 Biomarkers were negative.

On 15 August 2018, the pathology profile demonstrated serous carcinoma of the endometrium and extensive involvement of cervical stroma pT2 Nx Mx. Parametrium-free, lymphovascular

invasion was also identified, however, lymph nodes were not involved. Beam radiotherapy due to open vaginal fistulas was not recommended.

Adjuvant chemotherapy is category IIB based on national comprehensive cancer network (NCCN) guidelines. As tumor size is large, 6 cm., and positive lymphovascular invasion are both adverse risk factors, we recommended Cisplatin + Taxol X 6 cycles.

The referral was made to Tawam hospital to discuss the pros and cons of external beam radiotherapy and brachytherapy. We were concerned because there was a risk of developing additional fistulas from external beam radiotherapy. For brachytherapy, there was an issue that the patient was a virgo intacta and may get vaginal stenosis. Also, there was a risk of fistula.

Then on 16 October 2018, immunohistochemistry (IHC) testing for Mismatch Repair (MMR) revealed only the loss of nuclear expression of PMS2, which suggests a high probability of Lynch syndrome (sequencing and/or large deletion/duplication testing of germline PMS2 may be indicated).

Then in the following month, on 28 November 2018, a CT scan of the chest, abdomen, and pelvis were taken. Findings revealed appearances in the right iliac fossa with soft tissue density lesions and adjacent mesenteric lymph nodes. Furthermore, on 5 December 2018, a positron emission tomography scan was performed that revealed multifocal FDG avid deposits in the mesentery, pelvis, and peritoneum in association with the recurrent disease.

The case was discussed with a multidisciplinary team and no decision about the surgical procedure was made. No radiotherapy was performed. At the end of the month, the patient received Pembrolizumab according to the viewed NCCN guidelines (MSI is HIGH, patient is a candidate for Immunotherapy Pembrolizumab). After the use of Pembrolizumab, the patient only complained about small joint pain and was referred to a rheumatologist for that. After six

months, on 18 June 2019, a CT scan of the abdomen and pelvis was performed, which showed no evidence of metastasis or disease recurrence. PET scan demonstrated no focal FDG uptake to suggest any metabolic active disease. On 23 October 2019, the patient stopped receiving Pembrolizumab immunotherapy due to a change in her insurance.

Furthermore, after eight months, the patient was again advised to undergo a CT scan of the pelvis and abdomen. According to the laboratory investigation, no significant abnormality in loop ileostomy or its connections found. The patient was also referred for further clinical correlation and evaluation. At that time, the patient was vitally stable but hypotensive and afebrile. Blood tests were found to be normal. However, the patient was vitamin D deficient. She was advised to continuously take vit D orally weekly. Other biomarkers ECOG =0, Carcinoembryonic antigen (CEA) stable, Carbohydrate antigen 125 (CA125), and cancer antigen (CA 15-3) were found to be within normal limits (Figure 1).

Additionally, it was clearly shown that CA 19-9 was decreasing from 123 units/ml to 99 units/ml -->91 -->82 > 68 >62 >>54.7 >> 38 units/ml. On 17 June 2021, CT scans of the abdomen and pelvis were performed. According to the results, no metastasis in the chest, abdomen, or pelvis was seen. However, there was peripheral patchy consolidation in the right middle lobe which could be due to an intercurrent chest infection. Additionally, a mild increase in CEA, CA125, and CA 19-9 was also found, which could be due to a recent severe flu-like illness/UTI. As recent PET and CT scans were negative (no metabolic active disease) and tumor markers were decreasing, we suggested she should not take Pembrolizumab further and kept her under observation. The patient agreed to this.

As expected, the outcomes were favorable, resulting in a significant improvement in the patient's symptoms and overall condition. All tumor markers decreased again and normalized and the

patient was reassured. The follow-up plan included: port flushing, blood testing, and computerized tomography until the next visit, and intravenous administration of iron and intramuscular administration of vitamins during the next visit.

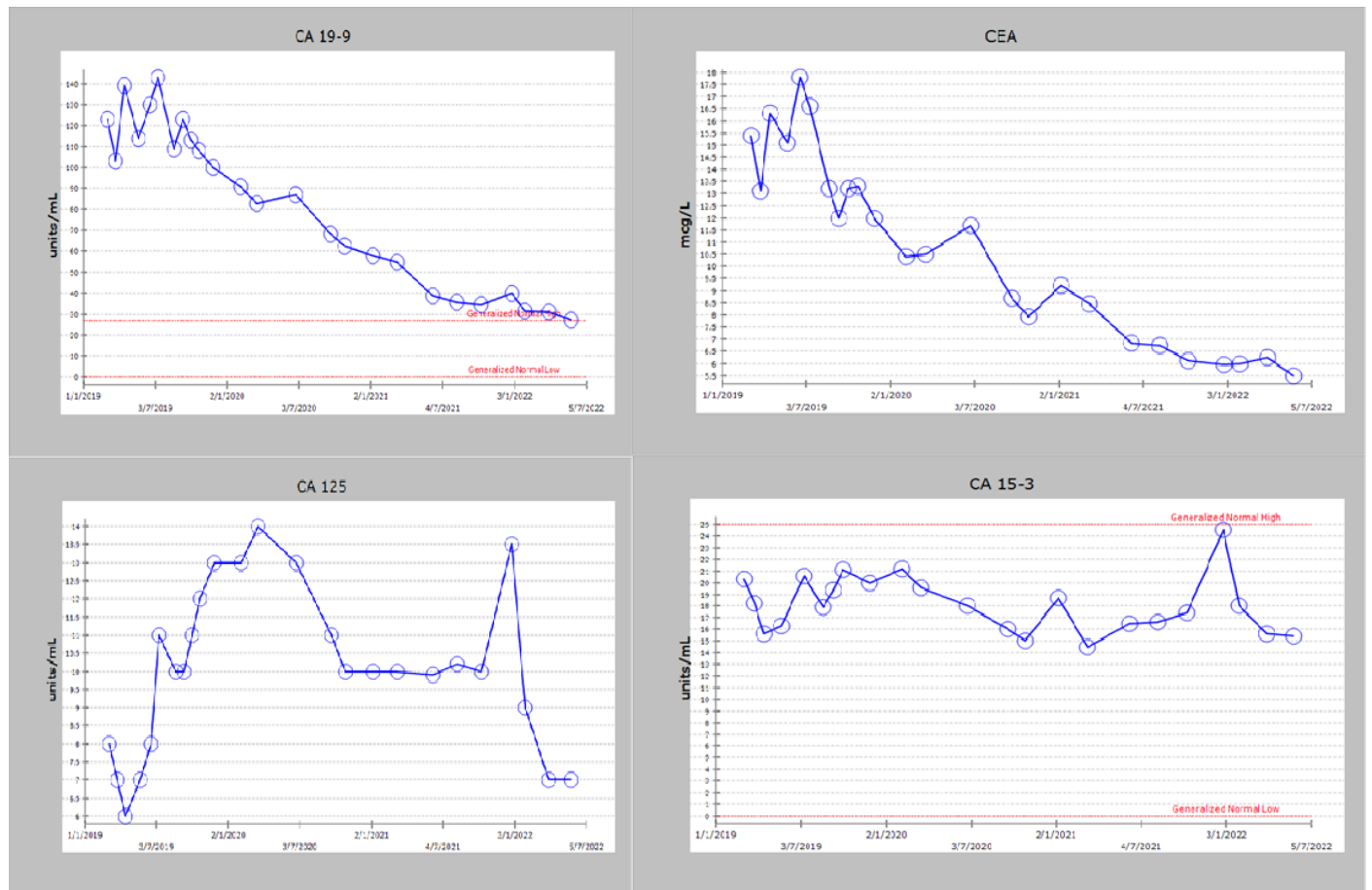


Figure 1: Changes in serum tumor marker levels before and after treatment.

CT of the chest, abdomen, and pelvis with contrast (17/6/2021) and (22/6/2022)

Chest

Previously noted inflammatory nodular densities in the medial segment of the right middle lobe have almost completely resolved with mild residual change and mild bronchiectasis change.

Appearances have improved.

- Scattered bullae were seen in the right middle lobe.
- Few scattered 2-3 mm nodules in the right lower lobe unchanged from the previous CT scan.
- No sizable pulmonary nodule.
- No mass lesions were found.
- Normal appearances of the mediastinum.
- No significant enlarged mediastinal lymph node.
- Normal appearances of the axilla.
- No enlarged nodes.

Abdomen and Pelvis

- Unchanged pneumobilia is secondary to previous Whipple surgery.
- No focal liver lesions.
- Nearly complete atrophy of the pancreas.
- Normal appearances of the spleen, glands, and kidneys.
- Multiple surgical clips were noted in the retroperitoneal region.
- Few sub-centimeter (short axis) retroperitoneal lymph nodes, no sizable lymph nodes.
- No mass lesions.
- Bilateral lower quadrant stoma in place.
- No evidence of bowel obstruction.
- No free fluid.
- No peritoneal nodules.

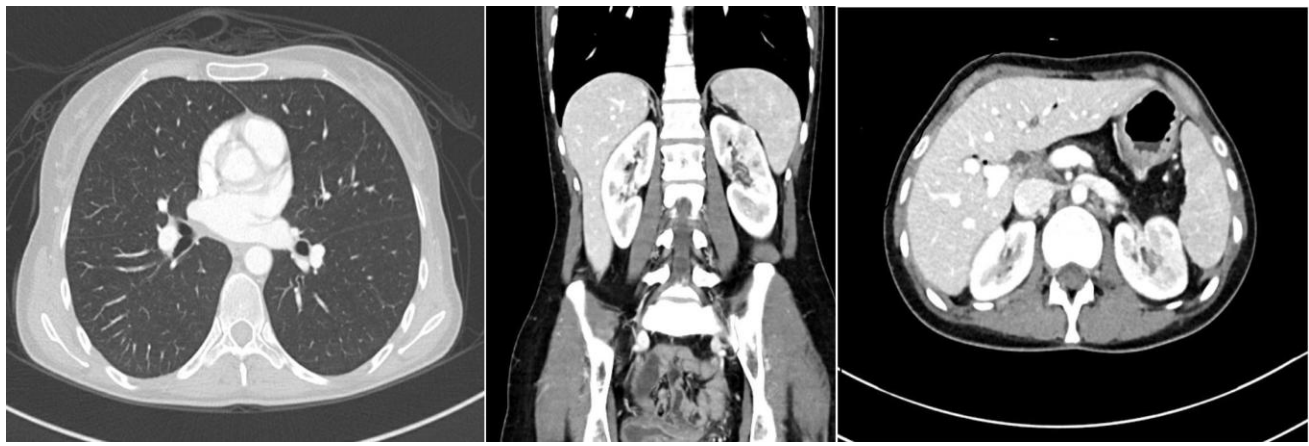

Figure 2: CT chest and abdomen after treatment.

Table 1: Yearly treatment plan.

Year	Treatment Plan
2003	Left colon cancer S/P hemicolectomy and FOLFOX chemotherapy
2004	Duodenal cancer S/P Whipple procedure
2005	Benign polyposis, under regular, follow up
2014	Polyps benign - low grade - became malignant. S/P total colectomy followed by adjuvant FOLFOX chemotherapy (Right sided Colon cancer)
2015	Left Ovarian cancer S/P left salpingo-oophorectomy with neoadjuvant and adjuvant-carbo-taxol chemotherapy
2016	Peritoneal deposits of ovarian primary Post laparotomy and chemotherapy
2017	Uterine Serous cancer S/P TAH and right salpingo-oophorectomy, Reluctant to chemotherapy. Olaparib 400 mg PO BID started.
2018	Relapse/progression in peritoneum of ovarian primary. Stopped taking Olaparib, and started taking pembrolizumab at the end of the year.
2019	Took pembrolizumab for a whole year and then stopped taking it.
2020	On follow-up

2021	On follow-up
2022	On follow-up

Discussion

Colon cancer is a prevalent malignant digestive neoplasm(8). Familial polyposis and genetic non-polyposis colorectal cancer (HNPCC) are the most frequently occurring hereditary colorectal cancer susceptibility syndromes. HNPCC syndrome, often known as LS, is mostly caused by DNA MMR mutations (PMS2, MSH2, MLH1, and MSH6). Ninety percent of cases of Lynch syndrome are caused by mutations in MSH2 and MLH1genes, ten percent by MSH6 mutations, and six percent by PMS2 mutations(9). In previous investigations, MLH1 and MSH2 mutations have been observed often, and only a few cases of MSH6 mutations and PMS2 have been reported (10). This report is a unique presentation of the germline mutation in the PMS2 gene in Lynch syndrome from which the women suffered from for 18 years.

In the past, it was believed that PMS2 mutation carriers have a weak family history and later age of presentation(11). Some cases, such as ours, may still show at a younger age. Our patient was first diagnosed with cancer at the age of 16, suggesting variable penetrance. However, there was no family history of cancer. This may indicate that the present screening recommendations are insufficient, supporting the case for universal tumor screening for all new cases of colon cancer. Future research could validate a lower starting age for colon cancer screening. Even in the absence of family history, screening may be required to identify individuals at higher risk of developing colon carcinoma.

Additionally, tumor testing or genetic testing is performed to diagnose Lynch syndrome(12). One such technique is MSI genetic testing. MSI has a 90 percent specificity in patients with

MMR mutations(13). The detection sensitivity ranges from 80 percent to 91 percent in individuals with MLH1 or MSH2 gene mutations and from 55 percent to 77 percent in patients with MSH6 or PMS2 gene mutations. The sensitivity and specificity of IHC in MR mutation patients are 83 percent and 89 percent, respectively(13). It is suggested that patients undergo genetic testing when the findings of MSI and IHC tests show a very suspicious LS diagnosis. In our case, MSI was found to be high, which indicated a loss of the PSM2 gene on chromosome 7. The treatment options for our patient included S/P hemicolectomy and FOLFOX chemotherapy in 2003, Whipple procedure due to duodenal carcinoma in 2004, S/P Total colectomy followed by adjuvant FOLFOX chemotherapy in 2014, S/P left salpingo-oophorectomy with neoadjuvant and adjuvant carbo-taxol chemotherapy in 2015, Peritoneal Mets post laparotomy and chemotherapy in 2016, S/P right salpingo-oophorectomy Olaparib in 2017. She started taking Olaparib 400 mg PO BID but stopped medication by herself in 2018. Then, at the end of the year, she started taking Pembrolizumab, which is an anti-cancerous drug reported to have a 72 percent survival rate(14). This was the first time she started taking Pembrolizumab immunotherapy, which was stopped by the end of 2019. The intriguing fact is that all her disease cleared up and she has been living a normal life for almost three years after stopping immunotherapy and she is in complete remission. Also, all her tumor markers have dropped down and normalized. This is contrary to another study in which the patient was given Pembrolizumab and survived for only two years(14). Our patient is alive, it's been three years free of disease, and is under strict follow-up.

Conclusion

Lynch syndrome is a potentially life-threatening condition that places a person at higher risk of

developing multiple cancers, for example, ovarian cancer, colorectal cancer, and endometrial cancer. Lynch syndrome is connected to mutations in DNA MMR genes, which enhance susceptibility to cancers, including colorectal carcinoma. Although the National Comprehensive Cancer Network (NCCN) provides screening recommendations for colon and endometrial cancers in persons with Lynch syndrome, thorough surveillance for small bowel malignancies remains restricted. However, developments in intestinal imaging and MSI gene detection may aid in early diagnosis. In addition, a deeper understanding of the molecular variables linked with colon cancer and other solid tumors may reveal their significance in prognosis and targeted chemotherapy. Moreover, in our study, where other treatment procedures and medications failed, Pembrolizumab therapy was found to be the best treatment option for the patient. However, future studies need to be conducted to confirm this treatment plan.

Ethical Approval:

As per international standard or university standard written ethical approval has been collected and preserved by the author(s).

Consent

As per international standard or university standard, patients' written consent has been collected and preserved by the author(s).

References

1. Cohen SA, Pritchard CC, Jarvik GPJArog, genetics h. Lynch syndrome: from screening to diagnosis to treatment in the era of modern molecular oncology. 2019;20:293-307.

2. Gray PN, Tsai P, Chen D, Wu S, Hoo J, Mu W, et al. TumorNext-Lynch-MMR: a comprehensive next-generation sequencing assay for the detection of germline and somatic mutations in genes associated with mismatch repair deficiency and Lynch syndrome. *2018;9(29):20304.*
3. Duraturo F, Liccardo R, De Rosa M, Izzo PJOI. Genetics, diagnosis, and treatment of Lynch syndrome: Old lessons and current challenges. *2019;17(3):3048-54.*
4. Li L, Zhao Z, Dong L, Jia J, Su K, Bai H, et al. Case Report: A New Subtype of Lynch Syndrome Associated With MSH2 c.1024_1026 Identified in a Chinese Family. *2022;9.*
5. Lynch HT, Snyder CL, Shaw TG, Heinen CD, Hitchins MP. Milestones of Lynch syndrome: 1895–2015. *Nature Reviews Cancer. 2015;15(3):181-94.*
6. Jenkins MA, Baglietto L, Dowty JG, Van Vliet CM, Smith L, Mead LJ, et al. Cancer Risks For Mismatch Repair Gene Mutation Carriers: A Population-Based Early Onset Case-Family Study. *Clinical Gastroenterology and Hepatology. 2006;4(4):489-98.*
7. Møller P, Seppälä TT, Bernstein I, Holinski-Feder E, Sala P, Gareth Evans D, et al. cancer risk and survival in carriers by gene and gender up to 75 years of age: a report from the Prospective Lynch Syndrome Database. *2018;67(7):1306-16.*
8. Song XJ, Liu ZL, Zeng R, Ye W, Liu CW. A meta-analysis of laparoscopic surgery versus conventional open surgery in the treatment of colorectal cancer. *Medicine. 2019;98(17):e15347.*
9. Borràs E, Pineda M, Cadiñanos J, Del Valle J, Brieger A, Hinrichsen I, et al. Refining the role of PMS2 in Lynch syndrome: germline mutational analysis improved by a comprehensive assessment of variants. *Journal of medical genetics. 2013;50(8):552-63.*
10. Cui MH, Zhang XW, Yu T, Huang DW, Jia Y. PMS2 germline mutation c.1577delA (p.Asp526Alafs*69)-induced Lynch syndrome-associated endometrial cancer: A case report. *Medicine. 2019;98(51):e18279.*
11. Gulati S, Gustafson S, Daw HA. Lynch Syndrome Associated With PMS2 Mutation: Understanding Current Concepts. *Gastrointestinal cancer research: GCR. 2011;4(5-6):188-90.12.*
van Leerdam ME, Roos VH, van Hooft JE, Balaguer F, Dekker E, Kaminski MF, et al. Endoscopic management of Lynch syndrome and familial risk of colorectal cancer: European Society of Gastrointestinal Endoscopy (ESGE) Guideline. *2019;51(11):1082-93.*

13. Piñol V, Castells A, Andreu M, Castellví-Bel S, Alenda C, Llor X, et al. Accuracy of revised Bethesda guidelines, microsatellite instability, and immunohistochemistry for the identification of patients with hereditary nonpolyposis colorectal cancer. *Jama*. 2005;293(16):1986-94.
14. Le DT, Durham JN, Smith KN, Wang H, Bartlett BR, Aulakh LK, et al. Mismatch repair deficiency predicts response of solid tumors to PD-1 blockade. *Science (New York, NY)*. 2017;357(6349):409-13.