

## Case report

**“BENIGN FIBROUS HISTOCYTOMA OF SOFT TISSUE : A CASE REPORT AND REVIEW OF LITERATURE”.**

ABSTRACT :

---

Benign fibrous histiocytoma (BFH) is a heterogenous group of mesenchymal tumors , composed of fibroblasts & histiocytes. Most commonly occurs in fifth decade with male predilection . Most common site is on skin of extremities. Intraorally, BFHs are most common in soft tissues of buccal mucosa, gingiva, lips, soft palate & floor of mouth. The objective of this case report to report a case of Benign Fibrous Histiocytoma in a 9 year old female patient, complaining of a painless swelling in the lower left back gum region for about six months. Considering unusual site of tumor as in this case, immunohistochemistry was performed to confirm for final diagnosis.

**Keywords:** Benign fibrous histiocytoma, mandible , storiform pattern

INTRODUCTION :

---

“Benign fibrous histiocytoma (BFH) is a mesenchymal tumor composed of fibroblasts and histiocytes , arising in cutaneous and non cutaneous soft tissues . Cutaneous BHF originates in sun exposed areas of skin , while non cutaneous BFH comprises 1 % of all BFH”.<sup>7</sup> “It was first described by Stout and Lattes in the year 1967 as a soft-tissue neoplasm, most commonly seen in the skin as solitary,

slow-growing nodule, which targets mid-adult life age group”.<sup>1</sup> “We report such case of BFH occurring in the left mandibular region in a 9-year-old female which was asymptomatic since 6 months”.<sup>4</sup>

## CASE REPORT :

---

A 9 year old female patient was reported to the outpatient department (OPD) of Department of Oral Pathology , with chief complaint of painless swelling in the left lower back gum region for 5-6 months. The swelling was of gradual onset, slowly progressive and was not associated with pain or discharge. Medical history revealed congenital acynotic heart disease. General physical examination and family history was not contributory . There was no history of trauma to the jaw, any recent dental procedures.

Extraoral examination showed no abnormality . Intraorally , well-defined swelling of size 2 cm × 1 cm on left side of the mandible , extending from mesial side of mandibular first premolar to retromolar pad . Mucosa over swelling appears stretched, shiny and pinkish color as that of normal mucosa . Also , obliteration of lingual vestibule was noted (Fig.1). On palpation, swelling was slightly tender, firm in consistency, pedunculated which is noncompressible and nonfluctuant. The involved tooth did not show any signs of mobility or tenderness. A provisional diagnosis was epulis , pyogenic granuloma .

Cone beam computed tomography ( CBCT ) radiograph which showed bone loss in 34 , 35 and 36 regions displaced and incomplete root. (Fig.2) Incisional biopsy was advised for diagnosis . Histopathology showed , H&E stained section of the single soft tissue exhibited a fibrocellular stroma with cellular proliferation of spindle shaped cells , arranged in intersecting fascicles , whorled and storiform pattern with few hyalinised areas . Moderate degree of chronic inflammatory cell infiltrate with few foamy histocytes . Hence , final diagnosis of “Benign Fibrous Histiocytoma” was given ( Fig.3

). Considering the unusual location and age of the patient , immunohistochemistry was performed to confirm the diagnosis. It revealed strong positivity for CD 68, SMA & negativity for S 100 (Fig. 4 ). The positivity for CD68 indicated that the lesion was composed of histiocytic cells and fibroblast-like cells. Positivity for SMA indicated that the lesion was composed of alpha actin smooth muscle cells due to location of SFH and the neurogenic tumors could be differentiated due to S-100 negativity . Thus confirmed final diagnosis as Benign Fibrous Histiocytoma . After surgical treatment and follow up revealed no signs of local recurrence of lesion .

## DISCUSSION

---

“Benign Fibrous Histiocytoma (BFH) represents a diverse group of neoplasms which exhibit both fibroblastic and histiocytic cell differentiation. In 1967 , Stout and Lates first described the term Benign Fibrous Histiocytoma”.<sup>2</sup> “It is a mesenchymal tumor and commonly occurs on the skin of extremities as a solitary, slowly growing nodule in early to mid-adult life”.<sup>4</sup> Primary BFH of the bone is rare, 1% of all benign bone tumors.<sup>5</sup> “As per review of literature of BFH involving oral region, occurrence of this tumor in the jaw bone is rare as only 2 cases of maxilla and 7 cases of the mandible has been reported”.<sup>2</sup>

The age of the patients in the cases reviewed ranged from 8 to 62 years, with the average of 33.8 years. Among the eighteen case reports summarized in Table 1, the incidence was slightly more in males ( n = 10) compared to females ( n = 8 ), with a male: female ratio of 1.25:1. In our case, patient was a 9-year-old female. According to the previous reports, the most common location for BFH was mandibular posterior region followed by the maxillary posterior region and the mandibular anterior region.<sup>13</sup> In the present case, the affected site is mandibular posterior region. In six cases, it had affected the left side, whereas right side was affected in three cases . Swelling alone was the most

common symptom in the reviewed cases, followed by pain , while in two cases, the patients were asymptomatic. While painless swelling was evident in present case . Radiographic appearance in the cases reviewed varied from well-defined, ill-defined unilocular radiolucency to well-defined multilocular radiolucency with or without reactive hyperostotic border. In the present case, it showed , ill -defined multilocular radiolucency without hyperostotic border .

Immunohistochemical staining was done in six cases in which tumor cells showed were positivity for vimentin , CD68 ,  $\alpha$ -1-antitrypsin and  $\alpha$ -1-antichymotrypsin and negativity for SMA , S-100 protein, cytokeratin , desmin , and CD34. The positive staining for CD68 and vimentin indicated that the lesion was composed of histiocytic cells and fibroblast-like cells , and negativity for SMA and S-100 showed that the lesion could be differentiated from leiomyosarcoma and neurogenic tumors.<sup>13</sup> In the present case immunohistochemical staining demonstrated strong positive for CD68 in moderate number of cells . Positivity for SMA showed that the lesion was composed of alpha actin smooth muscle cells due to location of SFH and the neurogenic tumors could be differentiated due to S-100 negativity.<sup>4</sup>

According to the WHO histological classification of the tumors, primary BFH of the bone is defined as a benign lesion composed of spindle-shaped fibroblasts arranged in a storiform pattern with a variable admixture of small, multinucleated osteoclast-like giant cells. Also, Foamy cells (xanthoma), chronic inflammatory cells, stromal hemorrhages, and hemosiderin pigment are also commonly present.<sup>13</sup> In our case, it showed spindle-shaped fibroblasts arranged in a storiform pattern, histiocytes, and giant cells .

“According to Cale et al., BFH and the metaphyseal fibrous defect together constitute the benign fibrohistiocytic lesions of bone. Though BFH lesions may occur at any age, they are most common in adults and are frequently associated with pain even in the absence of fracture. BFH occurs in non-long bones, or even if in a long bone there is lack of metaphyseal involvement”.<sup>5</sup> In our case, it was a painless soft tissue lesion occurring in non-long bone (mandible ) without bone fracture.

**Differential diagnosis of BFH :** MFH , Fibrosarcoma , Solitary fibrous tumor , Angiomatoid fibrous histiocyoma , Leiomyoma.<sup>1</sup>

“MFH was excluded from BFH due to lack of pleomorphic sarcomatous cells, lack of typical and atypical mitotic figures, and lack of bizarre giant cells, necrosis, and prominent areas of haemorrhage. Fibrosarcoma was excluded by showing the lack of malignant features, invasive margins, and the characteristic herring-bone pattern. SFT was excluded as they appear as monomorphic spindle cells organised into interlacing fascicles and ‘pattern-less’ pattern with hemangiopericytoma-like vascular spaces. AFH was excluded as it predominantly showed sheets of histiocytic cells arranged in serpentine pattern having cystic areas of haemorrhage. Leiomyoma was excluded it showed distinct fascicular arrangement with blunt-ended plumper nucleus and cytoplasm showing longitudinal striations corresponding to myofilamentous material”.<sup>12</sup>

The prognosis for BFH seemed to be excellent , with low recurrence rate of BFH .<sup>16</sup> The follow-up period in the reviewed cases ranged from 1 to 3 years and no recurrence had been found. In our case, follow up for 1 years showed no recurrence . Considering young age as in present case , further followup is required . Normally, the treatment plan for BFH consists of a wide surgical resection as mentioned in the literature, but considering the age of the patient and location of the lesion . It was decided to curette out the lesion instead of resection of the affected area for the best outcomes.

CONCLUSION :

---

Benign fibrous histiocyoma is a mesenchymal tumor composed of characteristic cells like fibroblast and histiocytes. This tumor is rare and presents a clinical and histopathological challenge. Proper diagnosis and treatment plan with long-term follow-up is important in the management and prevent recurrence of these tumors.<sup>7</sup>

**Table 1: Summary of case reports of benign fibrous histiocytoma in either jaw in chronological order**

First author	Year	Age/sex	Site	Duration	Side	Symptoms	Radiographic appearance	Immunohistochemical findings
Cale	1989	13/M	Post maxilla	Unknown	L	Asymptomatic	Ill-defined unilocular radiolucency	Not done
Dardo et al. [14]	1998	44 year/M	Floor of mouth					
Dardo et al. [14]	1999	34 year/M	Tongue					
Ertas[8]	2003	13/F	Ant mandible	NR	L	Swelling	Well-defined unilocular radiolucency	Not done
Heo[1]	2004	42/M	Post mandible	8 years	L	Swelling	Well-defined multilocular radiolucency with hyperostotic border	Positivity for CD68, vimentin Negativity for SMA, S-100
Tetsuo Shimoyama	2004	32/F	Palate	2 years	R	Hard nonulcerated mobile polypoid mass	Not done	Immunopositive for vimentin. negative for S-100 protein, smooth muscle actin, desmin, CD68.
Kishino[5]	2005	49/F	Post mandible	NR	L	Swelling and pain	Well-demarcated soap-bubble	Positivity for vimentin, CD68, $\alpha$ -1-

							appearance without sclerotic rim	antitrypsin, $\alpha$ -1-antichymotrypsin Negativity for SMA, S-100 protein, desmin, cytokeratin, CD34
Skoulakis et al. [4]	2007	19 /M	Cheek					
Katagiri[3]	2008	48/M	Mandible-condyle	Unknown	R	Asymptomatic	Ill-defined unilocular radiolucency Without sclerotic rim	Positivity for vimentin, CD68 Negativity for cytokeratin, SMA, S-100 protein, CD34
Bage and Bylappa [15]	2010	51 /F	Buccal mucosa					
Paraskevi	2010	36 /M	Buccal mucosa					
Wagner[6]	2011	41/M	Post mandible	NR	R	Swelling	Well-demarcated multilocular radiolucient lesion with a reactive hyperostotic border	Positivity for vimentin, CD68 Negativity for cytokeratin, SMA, S-100 protein, desmin
Gupta[2]	2011	24/F	Post mandible	NR	L	Swelling	Well-defined unilocular radiolucency	Not done
Pia et al.	2011	8 /F	Tongue					

[17]								
Saluja, et al.	2012	23/F	Post maxilla	8 months	L	Pain and swelling	Well-demarcated multilocular radioluculent lesion without a reactive hyperostotic border	Positivity for CD68, $\alpha$ -1-antichymotrypsin Negativity for SMA
Himanshu et al. [19]	2012	62/F	Buccal mucosa					
Narendra et al. [20]	2013	26 /M	Tongue					
Pradipta et al. [21]	2013	45 /M	Submandibular space					

## Consent

As per international standard or university standard, patients' written consent has been collected and preserved by the author(s).

## REFERENCES:

1. Salve S, Bhavthankar J, Mandale M. Benign Fibrous Histiocytoma of Mandible: A Pathogenetic & Diagnostic Perspective.
2. Mohanty A, Mishra P, Kumar H, Panda A. A rare presentation of benign fibrous histiocytoma in the maxilla. Journal of Oral and Maxillofacial Pathology: JOMFP. 2020 Feb;24(Suppl 1):S73.
3. Brantes MF, Azevedo RS, Oliveira SP, Gouvêa AF, Takahama Jr A. Benign fibrous histiocytoma of the tongue: a case report. Brazilian Dental Science. 2017 Jun 28;20(2):152-8.
4. Saluja H, Kasat VO, Rudagi BM, Dehane V, Kalburge JV, Nikam A. Benign fibrous histiocytoma of the maxilla: a case report and review of literature. Indian J Dent Res. 2014 Jan-Feb;25(1):115-8.

5. Shoor H, Pai KM, Shergill AK, Kamath AT. Benign fibrous histiocytoma: A rare case involving jaw bone. *Contemporary clinical dentistry*. 2015 Sep;6(Suppl 1):266.
6. Pattamparambath M, Sathyabhama S, Khatri R, Varma S, Narayanan NM. Benign fibrous histiocytoma of mandible: a case report and updated review. *Journal of Clinical and Diagnostic Research: JCDR*. 2016 Jun;10(6):24.
7. Nagaraja Anand RK, Saxena S, Bhardwaj N. Benign fibrous histiocytoma of the lower lip. *Journal of oral and maxillofacial pathology: JOMFP*. 2020 Feb;24(Suppl 1):97.
8. Shimoyama T, Horie N, Ide F. Solitary fibrous tumor of the palate: a case report and review of the literature. *Journal of oral and maxillofacial surgery*. 2004 Jul 1;62(7):895-7.
9. Srikanth D, Devi V, Polishetty N, Singh D. Subcutaneous Benign Fibrous Histiocytoma: Rare Presentation on Cheek—Case Report and Review of Literature. *Journal of maxillofacial and oral surgery*. 2016 Jul 1;15(2):282-6.
10. Ganly I, Patel SG, Stambuk HE, Coleman M, Ghossein R, Carlson D, Edgar M, Shah JP. Solitary fibrous tumors of the head and neck: a clinicopathologic and radiologic review. *Archives of Otolaryngology–Head & Neck Surgery*. 2006 May 1;132(5):517-25.
11. Gray PB, Miller AS, Loftus MJ. Benign fibrous histiocytoma of the oral/perioral regions: report of a case and review of 17 additional cases. *Journal of oral and maxillofacial surgery*. 1992 Nov 1;50(11):1239-42.
12. Kumar DP, Rathi T, Jain V. Benign fibrous histiocytoma: A rare case report and literature review. *Journal of maxillofacial and oral surgery*. 2016 Mar 1;15(1):116-20.

13. Gleason BC, Fletcher CD. Deep “benign” fibrous histiocytoma: clinicopathologic analysis of 69 cases of a rare tumor indicating occasional metastatic potential. *The American journal of surgical pathology*. 2008 Mar 1;32(3):354-62.
14. Soman S, Das TA, Thomas AM, Aslam S, Thomas T, Vijayakumar D. Benign fibrous histiocytoma of the maxilla: A rare case report. *International Journal of Preventive and Clinical Dental Research*. 2021 Jan 1;8(1):27.
15. Singh Chauhan JP, Kumar A, Porwal PK, Thakur RK, Mittal K, Singh H. Benign fibrous histiocytoma of the maxilla: A rare case report and literature review. *Natl J Maxillofac Surg*. 2020 Jul-Dec;11(2):298-301.
16. Heo MS, Cho HJ, Kwon KJ, Lee SS, Choi SC. Benign fibrous histiocytoma in the mandible. *Oral Surg Oral Med Oral Pathol Oral Radiol Endod* 2004;97:276-80.

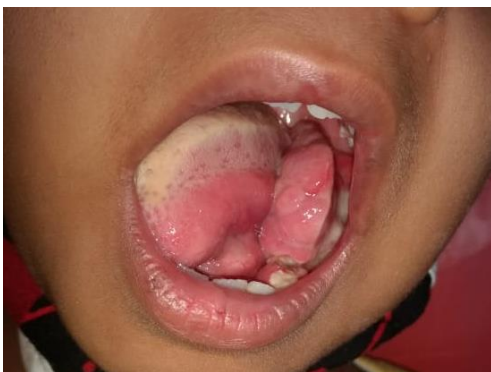

Fig.1: Intraorally , well-defined solitary swelling in the left posterior mandible .

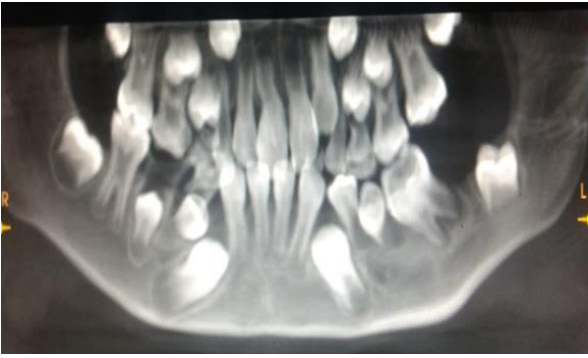

Fig.2: Radiographic examination in cone beam computed tomography ( CBCT ) radiograph -showed bone loss in 34,35,36 region . Displaced and incomplete root with 34,35,36 . Erupting and incomplete and erupting root formation with 33

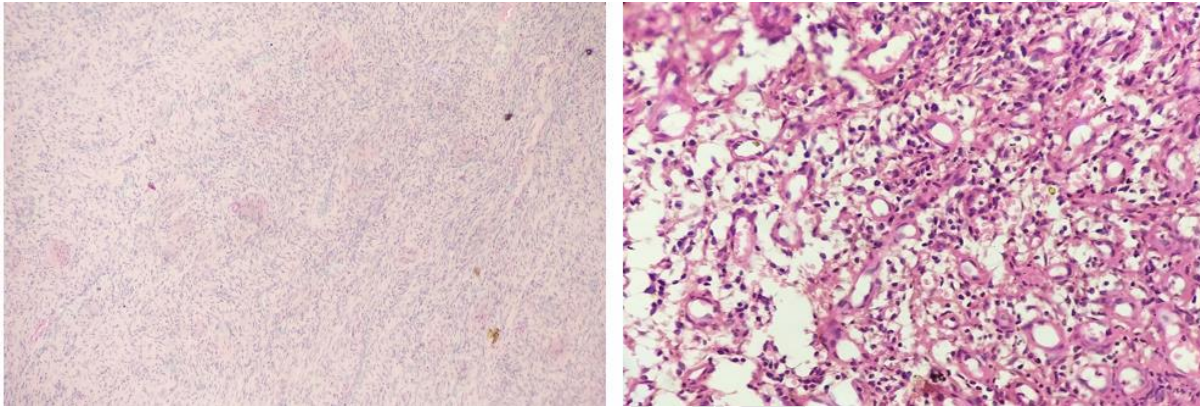


Fig.3 : Histological images showing fascicular & storiform arrangement of spindle cells, scattered histiocytes & touton type giant cells respectively .

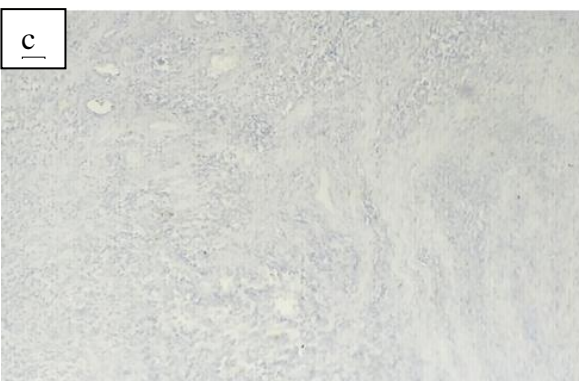
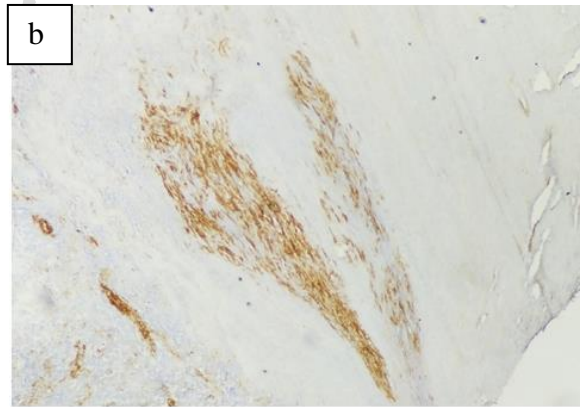
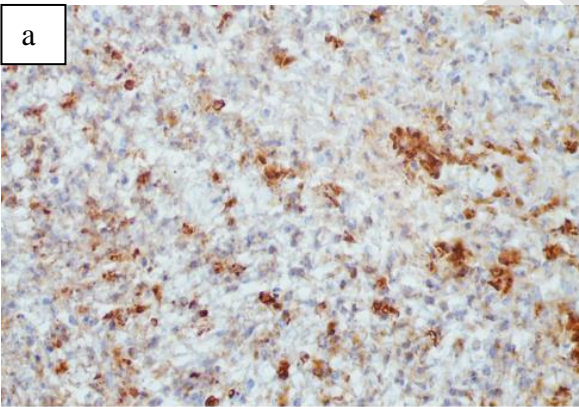


Fig.4 : Immunohistochemical images showing positivity a) , b) CD 68, SMA & c)negativity for S 100

UNDER PEER REVIEW