

Case study

TITLE: Hyperferritinemia in a case of Soft Tissue Sarcoma

Abstract-

An elderly male presented with symptoms suggestive of anemia .During workup for the same he was found to have very high levels of serum Ferritin along with a normocytic, normochromic peripheral blood film and no other apparent cause for hyperferritinemia .A swelling which incidentally found on his shin was further investigated by FNAC confirmed presence of soft tissue sarcoma.

Keywords-

Anemia,Hyperferritinemia,Soft tissue sarcoma

Introduction -

Anemia is the most common hematological abnormality in cancer patients.it has been assumed that over 40% of all cancer patients are anemic at the time of diagnosis and rate increases up to 80% in patients with advanced disease. ⁽¹⁾ The reason for cancer related anemia is multifactorial as it can occur due to dysfunction of iron metabolism, inadequate production of the erythropoietin, bone marrow suppression due to infiltration, peripheral red blood cell destruction.⁽²⁾

Ferritin is an iron storage protein, small amount of which is found in blood called serum ferritin.it is a surrogate marker of stored iron. its level increases with age, liver disease and malignancies.⁽³⁾Ferritin levels are raised in a variety of malignancies presumably as a result of stromal reaction, oxidative stress inflammation and rarely production by cancer cells as in neuroblastoma.

The authors are hereby presenting a case of an elderly man presenting with painless swelling, anemia and high levels of serum Ferritin who was later diagnosed with soft tissue sarcoma.

Case report

A 70 year old male presented with complaints of exertional dyspnea and generalized weakness from past 6 months, were of gradual onset and progressive course. He was a known case of Hypertension on erratic treatment and had a history of bleeding from external hemorrhoids and had received one unit of blood transfusion in last one year but there was no active bleed per rectum since then .There was no history of fever ,joint pains ,rashes ,bony tenderness, hypertension ,Diabetes Mellitus ,jaundice, any other overt blood loss, melena or aspirin intake.

On general physical examination patient was averagely built and poorly nourished .Pallor was present while there was no icterus ,lymphadenopathy ,edema or clubbing .An ill-defined

,round , swelling was present over the right thigh on the medial aspect just below the inguinal region .It was 5cmX 5cm in size ,hard in consistency ,non-tender and non-mobile .According to the patient this swelling had been present since 2 years but had progressively increased to current size .Another swelling was observed on right shin (image 1) dorsum of right foot .Pulse -72bpm,BP-170/90mm Hg,RR-15bpm. .Systemic Examination was normal except for a soft systolic murmur in the pulmonary area.

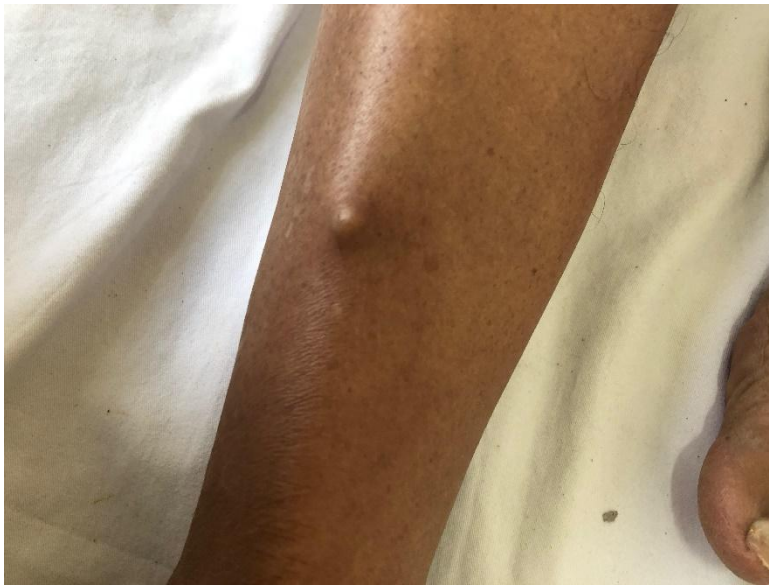

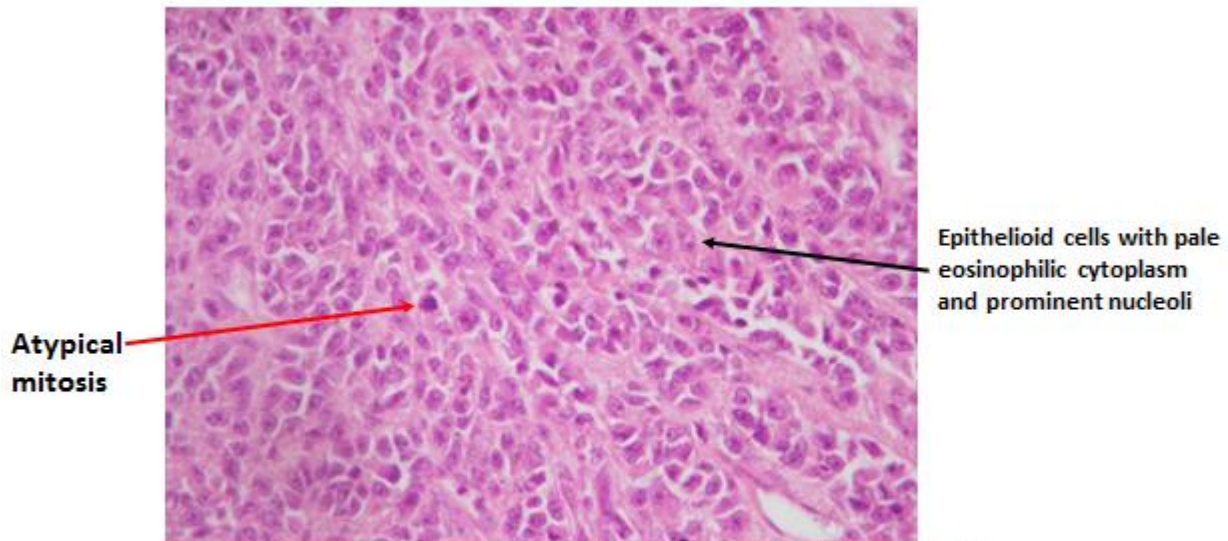
IMAGE 1.Small nodule present over the right shin

Investigations :Patient had a Hemoglobin of 5.6gm%,TLC -8400/cmm with DLC-P68%L30%,E00%,M02%.Platelet count -2,04000/cmm.TRBC-1.79million/cmm,PCV-17.4%,MCV-88.3FL,MCH-28.4Pg,MCHC-32.2gm%.RDW-SD 53.2FL,RBS-98mg%.KFT-blood Urea 43mg%.s creatinine-1.32mg%.LFT-T Bil-0.21mg%,direct-0.13mg%SGOT12U/L,SGPT16U/L. Serum Alkaline phosphatase 286IU/ml, Total protein-6.8gm%,Albumin-1.6gm%.HIV,HBsAG,HCV antibody was negative .PBF-RBCs Normocytic and normochromic .No hemoparasites ,no immature cells .Urine r/e was showing1 + albumin .Stool was negative for ova ,cyst and occult blood .Iron studies-Serum Iron-27mcg/dl,TIBC-110mcg/dl, Transferrin saturation24%.Serum Ferritin-1650 ng/ml.PSA-0.39g%

FNAC -taken from lump on right thigh and also right shin-similar cytopathological features with moderate to highly blood mixed smears showing tumor cells arranged in dispersed pattern with focal areas of clustering and pseudoacinar pattern. The cells were large and round with irregular nuclear margins and coarse chromatin having prominent macronuclei and fragile scant cytoplasm .Large bizarre multilobulated cells with intranuclear inclusions and a background of necrotic debris .Impression-poorly differentiated Ca /malignant melanoma/NHL.

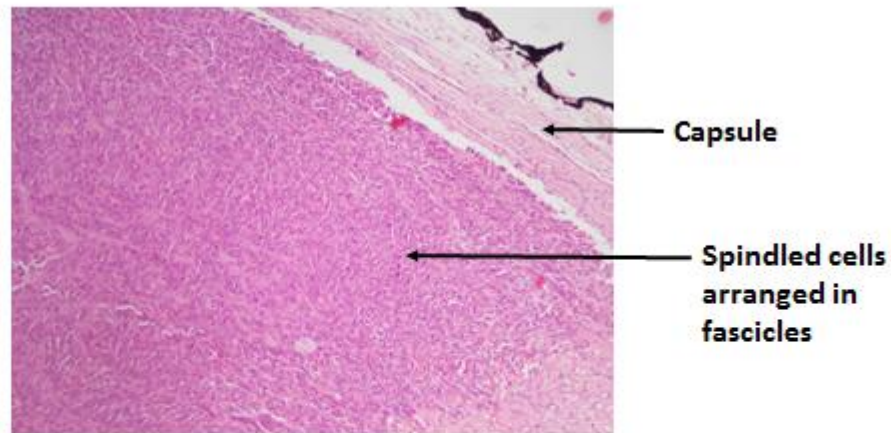
Histopathology sections of biopsy from the site revealed partially encapsulated tumor with spindle cells arranged in fascicles and intervening areas showing sheets of epithelioid cells with moderate amount of pale eosinophilic cytoplasm and prominent nucleoli .Tumor was reaching up to the capsule .Atypical mitosis(>30/hpf) and multiple areas of necrosis were noted .Impression :high grade sarcoma.(Images 2,3)

Image2



Photomicrograph of tumor showing sheets of epithelioid cells with moderate amount of pale eosinophilic cytoplasm and prominent nucleoli (H&E 40X). Foci of atypical mitosis also seen (red arrow)

Image3



Photomicrograph showing partially encapsulated tumor consisting of spindled cells arranged in fascicles (H&E 10X)

DISCUSSION

Sarcomas are a rare and heterogeneous group of malignant tumors of mesenchymal origin that comprise less than 1 percent of all adult malignancies and 12 percent of pediatric cancers. Approximately 80 percent of new cases of sarcoma originate from soft tissue, and the rest originate from bone.

Ferritin is an iron storage protein which is abundantly present intracellularly with a small amount circulating in blood. Normal level of serum Ferritin is 10-400ng/ml. A markedly elevated serum ferritin level > 1000ng/ml has been associated with iron overload, inflammatory conditions such as adult-onset Still's disease, systemic juvenile idiopathic arthritis, and hemophagocytic lymphohistiocytosis /macrophage activation syndrome and malignancy⁽³⁻⁸⁾. Hyperferritinemia has been reported in a variety of malignancies in the absence of iron overload. Inflammation and oxidative stress is hypothesized to be the basis of high ferritin in the setting of malignancy. Although anaemia is a common feature of soft tissue sarcomas literature search revealed only one case of hyperferritinemia reported in association with Liposarcoma^(9,10). Hence the reported case is likely the second case of hyperferritinemia associated with a sarcoma.

CONCLUSION

The authors present a rare case of anaemia with hyperferritinemia in association with soft tissue sarcoma, possibly the second to be reported in medical literature.

Consent Disclaimer:

As per international standard or university standard, patient's consent has been collected and preserved by the authors.

BIBLIOGRAPHY

1. Ludwig H, Fritz E. Anemia in cancer patients. *Semin Oncol*. 1998 Jun; 25(3 Suppl 7):2-6. PMID: 9671322.
2. Macciò A, Madeddu C, Gramignano G, Mulas C, Tanca L, Cherchi MC, Floris C, Omoto I, Barracca A, Ganz T. The role of inflammation, iron, and nutritional status in cancer-related anemia: results of a large, prospective, observational study. *Haematologica* 2015 Jan; 100(1):124-32. doi: 10.3324/haematol.2014.112813. Epub 2014 Sep 19. PMID: 25239265; PMCID: PMC4281325.
3. Song, A., Eo, W., Kim, S., Shim, B., & Lee, S. (2018). Significance of serum ferritin as a prognostic factor in advanced hepatobiliary cancer patients treated with Korean medicine: A retrospective cohort study. *BMC Complementary and Alternative Medicine*, 18(1), 1–10. <https://doi.org/10.1186/s12906-018-2240-7>.
4. Richardson DR. Iron and neoplasia: serum transferrin receptor and ferritin in prostate cancer. *J Lab Clin Med*. 2004 Oct;144(4):173-5. doi: 10.1016/j.lab.2004.05.016. PMID: 15534986.
5. Deshpande UR, Nadkarni GD, Samuel AM. Serum ferritin in thyroid cancer. *Thyroid* : Official journal of the American Thyroid Association 1993 Vol; 3(4):301-3. PMID: 8118224
6. Lorenzi M, Lorenzi B, Vernillo R. Serum ferritin in colorectal cancer patients and its prognostic evaluation. *Int J Biol Markers*. 2006 Oct-Dec; 21(4):235-41. doi: 10.5301/jbm.2008.2954. PMID: 17177162.

7.Kuvibidila SR, Gauthier T, Rayford W. Serum ferritin levels and transferrin saturation in men with prostate cancer. J Natl Med Assoc. 2004 May;96(5):641-9. PMID: 15160979; PMCID: PMC2640669.

8.Zhang XZ, Su AL, Hu MQ, Zhang XQ, Xu YL. Elevated serum ferritin levels in patients with hematologic malignancies. Asian Pac J Cancer Prev. 2014;15(15):6099-101. doi: 10.7314/apjcp.2014.15.15.6099. PMID: 25124580.

9.Grimer R, Gaston C, Carter S, Tillman R, Abundu A, Jeys L. The relationship between pretreatment anaemia and survival in patients with adult soft tissue sarcoma. Journal of Orthopedic Science. Nov 2013;18(6):987-993.

10.Fletcher R, Raw J, Datta-Chaudhury M. A massive myxoid liposarcoma with hyperferritinemia. J Postgrad Med 2007; 53:273-4

UNDER PEER REVIEW