

### **Hepatocellular Recovery of Chronic Paraquat Induced Liver Toxicity in Vitamin E and C Treated Male Wistar Rats.**

#### **Abstract**

Paraquat is an organic compound also known as methyl viologen, a chemical herbicide or weed killer with highly toxic effect on ingestion or exposure. Vitamin E and C are powerful antioxidants that act as initial responder against oxygen reactive species called free radicals which attack and destroy the tissues. The aim of this study was to determine a short term therapeutic effect of vitamin E and C combination on liver enzymes parameters of paraquat induced liver toxicity in male albino rats. 200 male albino rats were used for the study. The 200 rats were divided into four main groups (A, B, C, D) consisting of 50 rats in each group. The Groups were further divided into two subgroups having 25 rats in each subgroup. "A" group was not induced with paraquat while "B", "C" and "D" groups were induced with increasing dose of 0.02g, 0.04g and 0.06g of paraquat respectively. "A" group had two subgroups; "A<sub>0</sub>" and "A<sub>VEC</sub>" which represented the sub-group not treated with Vit E and the subgroup treated with Vit E (500mg) respectively. This also applied to group "B", "C" and "D" paraquat was administered every fourth night followed by treatment with the vitamins for one month. Blood samples were collected and analysed for liver function (SGOT, SGPT, ALT And GGT). There was a significant increase in the level of the liver enzymes among the "A<sub>0</sub>", "B<sub>0</sub>", "C<sub>0</sub>" and "D<sub>0</sub>", p-value<0.05 and also among the "A<sub>VEC</sub>", "B<sub>VEC</sub>", "C<sub>VEC</sub>" and "D<sub>VEC</sub>", p-value<0.05. The result also showed that there were significant differences in intra-group comparison in all the liver enzyme parameters, p-value<0.05 while there was no significant difference among the A<sub>0</sub> and A<sub>VEC</sub> subgroups for all parameters. This study has shown that vitamin E and C combination has a therapeutic effect in male albino rats on one month of weekly treatment. Therefore, a weekly treatment with Vit E and C may treat liver disease toxicity associated with paraquat toxicity in rats.

**Keyword:** *Vitamin E and C, paraquat, rat, antioxidant, liver enzymes.*

#### **1.0 Introduction**

Vitamin E is a fat soluble vitamin found among a category of eight lipid-soluble compounds that have antioxidant properties and the ability to shield cells and tissues from oxidative stress [1,2]. These eight groups are subdivided into two groups of tocopherols (they have many vitamin activity) and tocotrienols [2].The tocopherols are subdivided further into the alpha-, beta-, delta-, and gamma-tocopherols with each having a unique quality. Alpha ( $\alpha$ )-tocopherol is the chemical form of vitamin E good for human nutrition as well as the most active form of vitamin E [3].  $\alpha$ -tocopherol have different roles in the human body which include neutralization of free radicals which induces oxidative damages, the protection of the cells against damages and the maintenance of cell membrane integrity by preventing protein oxidation and fat peroxidation [3].other functions of the alpha form of vitamin E include gene control, participate in neurological performance, inhibition of platelet aggregation, and enhancement of vasodilation [3]. Natural sources of vitamins include foods like seeds, nuts, some vegetables, and fortified products. It can also be gotten from dietary supplement [4].

Vitamin C (Ascorbic acid) is a water soluble vitamin that is needed for collagen and intracellular materials formation and hence for the development of cartilage, bone and for wound healing [1,5].

Paraquat is an organic compound also known as methyl viologen, it is a chemical herbicide or weed killer that is highly toxic to human when ingested or on exposure [6,7,8]. Gotter (2022), stated that paraquat is also known by the common name gramoxone, a poison that is very toxic [7]. National Center for Biotechnology and Information, (2022) reported that a concentrated solution of paraquat causes skin irritation including other damages such as nail shedding and cracking, and delayed wounds and cut healing [6]. Thomas (2018), also cited that exposure to paraquat can be confirmed through urinary dithionite test [8]. It was discovered from several studies that paraquat poisoning alters the levels of certain biochemical parameters [9,10]. Zhou et al. (2016) in their research highlighted the toxic impact of paraquat in both survivors and non-survivors where it led to significant alteration in the concentrations of some biochemical parameters [10].

Epidemiological studies have shown that when there is chronic exposure to pesticides such as paraquat and other environmental toxins it can bring about progression of Parkinson's disease [11,16]. For example, it has been reported that a dose-dependent lifetime cumulative exposure to paraquat increases the risk for development of Parkinson's disease [17,18,19]. This can be because the chemical structure of paraquat looks like that of MPTP (1-methyl-4-phenyl- 1,2,3,6-tetrahydropyridine), a neurotoxin that causes Parkinson's disease in humans and animals [18,20]. Also, when paraquat is administered to mice it causes selective degeneration of dopaminergic neurons in the substantia nigra, consequently showing one primary pathological characteristics of Parkinson's disease [21,22]. Other studies have shown that administration of paraquat causes very high fatality rate (30–70%) [23,24]. Paraquat brings about the formation of Reactive Oxygen Species (ROS). These ROS are produced continuously in the body to carry out biological reactions. But when they are overproduced it can lead to damage of cell membranes through the peroxidation of membrane polyunsaturated fatty acids. The mechanisms of paraquat toxicity involve the generation of ROS that leads to oxidative stress and in an imbalanced state of ROS and scavenging by antioxidant. The ROS reacts with polyunsaturated fatty acids that lead to the production of toxic aldehyde metabolites, of the principle end products of lipid peroxidation. The primary enzymatic defence system are made up SOD and catalase [16-17]. Paraquat is therefore considered to be a highly toxic; pro-oxidant that causes multi-organ failure including that of the heart via generation of ROS. Paraquat has been shown to alter myocardial survival and contractile function which led to cardiopulmonary failure [23-24].

Several previous studies have shown that antioxidants like vitamins have a protective effect against paraquat-induced biochemical toxicity in albino rats [11]. The beneficial effects of these antioxidants against OPS-induced hepatotoxicity and ultrastructural changes in rats have also been demonstrated [13]. Also, Vitamin E and C combination had a protective effect against malathion-induced testicular toxicity in male Wistar rats [14], however, their effect on liver enzyme parameters has not been studied in this area. It is therefore necessary to carry out such study.

## **2.0 Material and Methods**

### **2.1 Study Area/Population**

The study was carried out in the Medical Laboratory Science Departmental Laboratory of Rivers State University, Port Harcourt, Nigeria. It was a biological trial study with Wistar rats. Two hundred (200) healthy mature male albino rats with a mean weight of  $0.2 \pm 0.02$  kg were used in this study. The rats were gotten from the Animal House, Department of Biology, Rivers State University and were transported to the study site. They were allowed to acclimatize for two weeks before they were used for the study. The rats were housed in conventional wire mesh cages under standard laboratory conditions and were fed with water and feed throughout the experiment.

## 2.2 Grouping and Treatment of Animals

Two hundred (200) male Albino Rats were used for this research and were divided according to their body weight into 4 groups of fifty (50) Rats each.

**Group A:** Control group. (with no paraquat induction)

**Group B:** 0.02g of paraquat per kg of rat was induced into rats in this group for three months.

**Group C:** 0.04g of paraquat per kg of rat was induced into the rats in this group for three months.

**Group D:** 0.06g per kg of paraquat was induced into rats in this group for three months.

Each of the main groups had subgroups. "A" group had "Ao" and "Avec" subgroups; "B" group had "Bo" and "B<sub>VEC</sub>" subgroups; "C" group had "Co" and "C<sub>VEC</sub>" subgroups; "D" group had "Do" and "D<sub>VEC</sub>"

**"Ao", "Bo", "Co" and "Do" subgroups:** were not treated with vitamin E and C combination

**"A<sub>VEC</sub>", "B<sub>VEC</sub>", "C<sub>VEC</sub>" and "D<sub>VEC</sub>" subgroups:** were treated orally with 500mg of vitamin E and 2000mg/dl of Vitamin C every week for one month.

After one month of weekly treatment with Vit E and C, the rats were sacrificed and their blood samples were collected via cardiac puncture and analyzed for liver parameters [25].

## 2.3 Procedure for Administration of Toxicant

Administration of toxicant was via oral gavage route. The rats were held at the skin over the head and turned so that the mouth was faced upward and the body lowered towards the holder. The syringe needle bevel was then placed into the mouth of the rat a bit laterally in a way to avoid the teeth which are located centrally. The content in the syringe was then emptied into the mouth of the rat gradually. [25]

## 2.4 Sample Collection

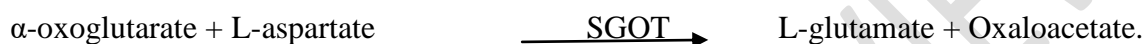
Blood sample collection was via cardiac puncture from the animals and sacrificed under

70% chloroform anesthesia into lithium heparin specimen bottle and used for analysis of liver enzyme parameters. [25]

## 2.5 Laboratory analysis

### **Serum glutarate-oxaloacetate-aminotransferase (AST/SGOT) method by Reitman and Frankel [26].**

Principle: AST catalyzes the transfer of the amino group from aspartate to ketoglutarate, forming oxaloacetate and glutamate when AST is incubated at 37<sup>0</sup>C for exactly 60 minutes in a pH 7.5 buffered substrate containing aspartate and  $\alpha$ -ketoglutarate. The oxaloacetate produced reacts with 2, 4-dinitrophenylhydrazine to form 2, 4-dinitrophenylhydrazone which gives a red-brown colour in alkaline medium. The absorbance of the colour produced is measured at 540nm spectrophotometrically



Procedure: 0.5ml of buffered-L- aspartate and  $\alpha$ -oxoglutarate solution was each added to two glass tubes labeled 'Reagent Blank' and 'Test', followed by 0.1ml each of distilled water and sample to their respective tubes, mixed and incubated for exactly 30 minutes at 37<sup>0</sup>C. After which, 0.5ml of 2, 4-dinitrophenylhydrazine (2mmol/L) solution was added to each of the test tubes, mixed again and allowed to stand for exactly 20 minutes, at 20 – 25<sup>0</sup>C. Then 5.0mls of Sodium hydroxide (0.4mol/L) was added in order to enhance colour development at alkaline pH. The tubes were mixed and the absorbance of 'Test' ( $A_{\text{Test}}$ ) read against that of the 'Reagent blank' after 5 minutes. The activity of the enzyme AST was then obtained in the serum from the table of values previously plotted against activities.

### **Serum glutarate-pyruvic-aminotransferase (SGPT) by Reitman and Frankel [26]**

Principle: ALT catalyzes the transfer of the amino group from alanine to ketoglutarate, forming pyruvate and glutamate when incubated at 37<sup>0</sup>C for exactly 60 minutes in a pH 7.5 buffered substrate containing L-alanine and  $\alpha$ -ketoglutarate. The pyruvate formed reacts with 2, 4-dinitrophenylhydrazine to form 2, 4-dinitrophenylhydrazone which in alkaline medium gives a red-brown colour. The absorbance of the colour produced is measured at 540nm in a spectrophotometer



Procedure: 0.5ml of buffered-L- alanine and  $\alpha$ -oxoglutarate solution was each added to two glass tubes labelled as 'Reagent Blank' and 'Test', then 0.1ml each of distilled water and sample were added to their respective tubes, mixed and incubated for exactly 30 minutes at 37<sup>0</sup>C. After which, 0.5ml of 2, 4-dinitrophenylhydrazine (2mmol/L) solution was added to each test tube, mixed again and allowed to stand for exactly 20 minutes, at 20 – 25<sup>0</sup>C. After which 5.0mls of Sodium hydroxide (0.4mol/L) was added to enhance the development of colour at alkaline pH. The tubes were mixed and the absorbance of 'Test' ( $A_{\text{test}}$ ) read against that of the 'Reagent blank' after 5 minutes.

Calculation: The activity of the enzyme ALT was obtained in the serum from the table of values previously plotted against activities.

### **Alkaline phosphatase (ALP) method by Englehardt *et al.* [27]**

Principle: ALP is measured by monitoring the concentration of p-nitrophenol formed with p-nitrophenolphosphate. This is an optimized standard method.

Procedure: A new Gain calibration in flow cell mode was performed using fresh double distilled water (ddH<sub>2</sub>O). This zero's the equipment from previous sample run. ALP was selected in the Run Test Screen and a water blank test run was carried out, after which 0.02ml of sample and 1.0 ml of reagent (Diethanolamine buffered p-nitrophenylphosphate) was dispensed into a test tube and mixed for 2 minutes. The mixture was then aspirated into the Rx Monza. After 2 minutes the result of the test sample was then printed out from a printer connected to the machine.

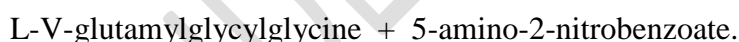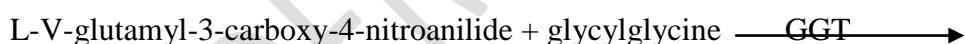The advantage of this machine procedure is that up to 200 samples can be processed and results produced within one hour in S.I. unit = IU/L.

Manual calculation: To calculate the ALP activity, using the manual method, the following formula was utilized:  $IU/L = 2760 \times \Delta A / 405 \text{ nm/min}$ .

### **Gamma-Glutamyltransferase (GGT) method by Szasz and Bergmeyer [28]**

#### **Principle**

5-amino-2-nitrobenzoate was produced by the conversion of the substrate L-V-glutamyl-3-carboxy-4-nitroanilide, in the presence of glycylglycine in the sample. This was then measured at 405nm in a spectrophotometer.



#### **Procedure:**

0.1ml of sample and 1.0ml of reagent (Buffered Glycylglycerine and L-gammaglutamyl-3-carboxy-4-nitroanilide) were dispensed into a cuvette, mixed and the initial absorbance read at 400 – 420nm with simultaneous timer initiation. The absorbance was read again after 1, 2 and 3 minutes.

**Calculation:**  $IU/L = 1158 \times \Delta A / (405\text{nm/minute})$ .

## **2.6 Statistical Analysis**

The data obtained from the study were analysed using SPSS 23.0 for descriptive statistics and inferential statistics, ANOVA (analysis of variance). P-value<0.05 was considered significant

## **3.0 Results**

The results of this study as shown in Table 1 reveals that the mean levels of liver enzymes (SGOT, SGPT, ALT and GGT) after three months dose-dependent treatment with paraquat in A<sub>0</sub>, B<sub>0</sub>, C<sub>0</sub> and D<sub>0</sub> groups were statistically significant  $p < 0.05$ . The result showed that there was a significant increase in concentrations of the SGOT, SGPT, ALT and GGT level among the groups (D<sub>0</sub>>C<sub>0</sub>>B<sub>0</sub>>A<sub>0</sub>),  $p$ -value<0.05

**Table 1: Changes in Liver enzymes levels after three months paraquat treatment**

Subgroup	SGOT (IU/L)	SGPT (IU/L)	ALP (IU/L)	GGT (IU/L)
A <sub>0</sub>	2.20 ± 0.04	2.52 ± 0.08	11.25 ± 0.30	13.63 ± 0.38
B <sub>0</sub>	15.35 ± 0.22 <sup>a</sup>	10.95 ± 0.09 <sup>a</sup>	53.44 ± 1.12 <sup>a</sup>	32.00 ± 0.56 <sup>a</sup>
C <sub>0</sub>	66.22 ± 1.68 <sup>a</sup>	134.88 ± 2.34 <sup>a</sup>	82.00 ± 1.75 <sup>a</sup>	42.67 ± 0.99 <sup>a</sup>
D <sub>0</sub>	99.50 ± 2.43 <sup>a</sup>	155.67 ± 3.69 <sup>a</sup>	318.17 ± 3.90 <sup>a</sup>	65.00 ± 1.37 <sup>a</sup>

a: significant difference among the groups (A<sub>0</sub>, B<sub>0</sub>, C<sub>0</sub> and D<sub>0</sub>).

Table 2 below shows the changes in liver enzymes after one month treatment period with vitamin E and C combination therapy. The result showed that there was a significant increase ( $p$ -value<0.05) in SGOT, SGPT, ALT and GGT levels in an increasing pattern (D<sub>VEC</sub>>C<sub>VEC</sub>>B<sub>VEC</sub>>A<sub>VEC</sub>).

**Table 2: Changes in Liver enzymes after one month vitamin E and C treatment**

Subgroup	SGOT (IU/L)	SGPT (IU/L)	ALP (IU/L)	GGT (IU/L)
A <sub>VEC</sub>	4.65 ± 0.11	2.27 ± 0.05	13.04 ± 0.17	10.33 ± 0.23
B <sub>VEC</sub>	11.38 ± 0.22 <sup>b</sup>	11.83 ± 0.22 <sup>b</sup>	26.78 ± 0.51 <sup>b</sup>	18.50 ± 0.28 <sup>b</sup>
C <sub>VEC</sub>	36.33 ± 0.56 <sup>b</sup>	68.40 ± 0.69 <sup>b</sup>	29.33 ± 0.51 <sup>b</sup>	23.33 ± 0.39 <sup>b</sup>
D <sub>VEC</sub>	67.67 ± 1.15 <sup>b</sup>	86.48 ± 1.35 <sup>b</sup>	297.67 ± 6.15 <sup>b</sup>	31.50 ± 0.41 <sup>b</sup>

$p$ -value<0.05

b: significant difference among the groups (A<sub>vec</sub>, B<sub>vec</sub>, C<sub>vec</sub> and D<sub>vec</sub>).

Table 3 below shows the changes in some biochemical parameters after one month treatment period. The result showed that there was a significant increase in concentrations of SGOT, SGPT, ALT and GGT when an intergroup comparison was carried out among subgroups A<sub>O</sub>, B<sub>O</sub>, C<sub>O</sub> and D<sub>O</sub>,  $p$ -value<0.05. The result also showed a significant increase in concentrations of SGOT, SGPT, ALT and GGT when an intergroup comparison was carried out among the subgroups; A<sub>VEC</sub>, B<sub>VEC</sub>, C<sub>VEC</sub> and D<sub>VEC</sub>. There was also a significant decrease in levels of SGOT, SGPT, ALT and GGT when intragroup comparisons were made among B<sub>O</sub> and B<sub>VEC</sub>, C<sub>O</sub> and C<sub>VEC</sub>, and D<sub>O</sub> and D<sub>VEC</sub>. There was however no significant difference in the levels of all the parameters between A<sub>O</sub> and A<sub>VEC</sub>.

**Table 3: Changes in Liver enzymes biochemical data after one month treatment period.**

Subgroup	Treatments (4 Rats in each subgroup) Mean $\pm$ SEM			
	SGOT (IU/L)	SGPT (IU/L)	ALP (IU/L)	GGT (IU/L)
A <sub>0</sub>	2.20 $\pm$ 0.04	2.52 $\pm$ 0.08	11.25 $\pm$ 0.30	13.63 $\pm$ 0.38
A <sub>VEC</sub>	4.65 $\pm$ 0.11	2.27 $\pm$ 0.05	13.04 $\pm$ 0.17	10.33 $\pm$ 0.23
B <sub>0</sub>	15.35 $\pm$ 0.22 <sup>a</sup>	10.95 $\pm$ 0.09 <sup>a</sup>	53.44 $\pm$ 1.12 <sup>a</sup>	32.00 $\pm$ 0.56 <sup>a</sup>
B <sub>VEC</sub>	11.38 $\pm$ 0.22 <sup>a,b</sup>	11.83 $\pm$ 0.22 <sup>a,b</sup>	26.78 $\pm$ 0.51 <sup>a,b</sup>	18.50 $\pm$ 0.28 <sup>a,b</sup>
C <sub>0</sub>	66.22 $\pm$ 1.68 <sup>a</sup>	134.88 $\pm$ 2.34 <sup>a</sup>	82.00 $\pm$ 1.75 <sup>a</sup>	42.67 $\pm$ 0.99 <sup>a</sup>
C <sub>VEC</sub>	36.33 $\pm$ 0.56 <sup>a,b</sup>	68.40 $\pm$ 0.69 <sup>a,b</sup>	29.33 $\pm$ 0.51 <sup>a,b</sup>	23.33 $\pm$ 0.39 <sup>a,b</sup>
D <sub>0</sub>	99.50 $\pm$ 2.43 <sup>a</sup>	155.67 $\pm$ 3.69 <sup>a</sup>	318.17 $\pm$ 3.90 <sup>a</sup>	65.00 $\pm$ 1.37 <sup>a</sup>
D <sub>VEC</sub>	67.67 $\pm$ 1.15 <sup>a,b</sup>	86.48 $\pm$ 1.35 <sup>a,b</sup>	297.67 $\pm$ 6.15 <sup>a,b</sup>	31.50 $\pm$ 0.41 <sup>a,b</sup>

Statistical significance: P-value < 0.05

- Index (a) = represents a statistically significant difference observed in intergroup comparison (A<sub>0</sub>, B<sub>0</sub>, C<sub>0</sub> and D<sub>0</sub>) and (A<sub>VEC</sub>, B<sub>VEC</sub>, C<sub>VEC</sub> and D<sub>VEC</sub>).
- Index (b) = represents a statistically significant difference observed in intragroup comparison (A<sub>0</sub> vs A<sub>VEC</sub>, B<sub>0</sub> vs B<sub>VEC</sub>, C<sub>0</sub> vs C<sub>VEC</sub> and D<sub>0</sub> vs D<sub>VEC</sub>)

#### 4.0 Discussion

This study was carried out to evaluate the effects of Vitamin E and C combination therapy on paraquat-induced toxicity on liver enzyme parameters of albino rats. Different subgroups of the test subjects were treated with paraquat, with an inter- and intra- comparative analysis. Paraquat is a highly toxic chemical and organic compound for weed control, with records of toxic effect when exposed to the cells or other parts of the living tissues [10,11,12].

Groups B<sub>0</sub>, C<sub>0</sub>, and D<sub>0</sub> were compared against the control group A<sub>0</sub> for the effect of paraquat on liver parameters SGOT, SGPT, AST and GGT. The result of this study showed a significant increase in the levels of SGOT, SGPT, AST and GGT among the subgroups under consideration. This indicates possible impaired integrity of hepatocellular membrane due to paraquat toxicity and this could lead to liver dysfunction. This study is in agreement with those carried out by McCormack *et al.*, and Ahmad *et al.* [29,30]

The second intergroup comparison that was made was among A<sub>VEC</sub>, B<sub>VEC</sub>, C<sub>VEC</sub> and D<sub>VEC</sub>. Recall that these groups were induced with paraquat in the respective doses, 0.00g, 0.02g, 0.04g and 0.06g. After the induction, they were treated with vitamin E. In the previous paragraph, it was reported that the level of hepatotoxicity after induction was high with increasing paraquat dosage administration. Treatment with Vitamin E and C combination showed some degree of hepato-repair but the hepatocellular repair achieved was significantly decreased with increasing toxicity. The pattern of serum liver enzyme was as follows; B<sub>VEC</sub>>C<sub>VEC</sub>>D<sub>VEC</sub>, this maybe a sign of hepato-repair. That finding may suggest that B<sub>VEC</sub> liver enzymes were lowest compared to C<sub>VEC</sub> and D<sub>VEC</sub> while C<sub>VEC</sub> was lower than D<sub>VEC</sub>. On the other hand, D<sub>VEC</sub> had the highest level of liver enzyme. This may be due to the fact that paraquat dosage in D<sub>VEC</sub> was highest when compared to the other groups. This finding is in

line with the work done by Okolonkwo and his team in 2022 [25] who reported that increasing paraquat dose increases liver toxicity and possible hepato-repair by vitamin treatment is dependent on the degree of liver damage.

Finally, an intragroup comparison was made between the control groups A<sub>0</sub> and A<sub>VEC</sub> and the test subgroups B<sub>0</sub> and B<sub>VEC</sub>, C<sub>0</sub> and C<sub>VEC</sub>, D<sub>0</sub> and D<sub>VEC</sub> to determine the difference in the levels of the parameters under study, between the test groups administered with various doses of paraquat without vitamin E and C combination treatment, and the groups given paraquat with vitamin E and C combination treatment. It was observed that there was a significant decrease in the levels of SGOT, SGPT, ALT and GGT of subgroups B<sub>VEC</sub>, C<sub>VEC</sub>, and D<sub>VEC</sub>, a result which confirms the ability of vitamin E and C combination to correct the toxic effect of paraquat on the parameters under consideration. This is in line with the study carried out by McCormack *et al.* and Ahmad *et al.* [29,30]. There was however no significant difference in all the parameters between subgroup A<sub>0</sub> and A<sub>VEC</sub>. This implies that Vitamin E and C does not have any effect on healthy livers of rats. Since the reduction of paraquat generates free radical, it can be said that increase in serum activities of the liver enzymes may have resulted from free radical mediated oxidative hepatocellular damage in the rats. However, reduced activities of liver enzymes observed after vitamin E and C treatment indicates protective role of vitamin E and C combination therapy in paraquat-induced toxicity and its amelioration of liver damage.

### **Conclusion**

Vitamin E and C combination therapy may have ameliorative effect on paraquat induced hepatotoxicity in male albino rats as revealed in the pattern of serum liver enzymes over a month of weekly treatment. More work will be required over a longer period to help confirm this finding so as to authenticate vitamin E and C combined treatment as an antidotal therapy for paraquat poisoning.

### **Ethical Approval**

Animal Ethic committee approval has been taken to carry out this study.

Animal Ethic committee approval has been collected and preserved by the author(s)

### **References**

1. York-Morris, S. (2020). The Truth About Vitamin E Oil. <https://www.healthline.com/health/food-nutrition/truth-about-vitamin-e-oil> Retrieved on 14/4/22
2. Traber, M. G. & Bruno, R. S. (2020). "Vitamin E". In BP Marriott, DF Birt, VA Stallings, AA Yates (eds.). *Present Knowledge in Nutrition, Eleventh Edition*. London, United Kingdom: Academic Press (Elsevier). pp. 115–36. ISBN 978-0-323-66162-1.

3. National Center for Biotechnology Information (2022). PubChem Compound Summary for CID 15939, Paraquat. Retrieved March 17, 2022 from <https://pubchem.ncbi.nlm.nih.gov/compound/VitaminE>. Retrieved on 14/4/2022
4. Kubala,J.(2022). 8 Unique Benefits of Vitamin E. <https://www.healthline.com/health/all-about-vitamin-e#1.-May-reduce-markers-of-oxidative-stress-and-improve-antioxidant-defenses> Retrieved 17/3/22
5. Kuramoto, T., Nakanishi, S., Ochiai, M., Nakagama, H., Voigt, B. & Serikawa, T. (2012) Origins of Albino and Hooded Rats: Implications from Molecular Genetic Analysis across Modern Laboratory Rat Strains. PLoS ONE 7(8): e43059. <https://doi.org/10.1371/journal.pone.0043059>
6. National Center for Biotechnology Information (2022). PubChem Compound Summary for CID 15939, Paraquat. Retrieved April 14, 2022 from <https://pubchem.ncbi.nlm.nih.gov/compound/Paraquat>.
7. Gotter, A. (2022). What is paraquat?<https://www.healthline.com/health/paraquat-poisoning#:~:text=Paraquat%20is%20a%20chemical%20herbicide,control%20weed%20and%20grass%20growth>. Accessed 14/4/22
8. Thomas, S. H. L. (2018). Poisoning.*Davidson's Principles and Practice of Medicine*, 7, 131-150. ISBN-13: 978-0702070280; ISBN-10: 0702070289
9. Hashemi, R. ,Jaddi, Y. , Sadeghi, M. , Ghiamati, S. & Motazedi, M. (2017) Study of Toxicology Effects of Herbicide Paraquat on Heamatological Parameters of Mesopotamichthyssharpeyi. Open Journal of Marine Science, 7, 258-270. doi: 10.4236/ojms.2017.72018.
10. Zhou, D. C., Zhang, H., Luo, Z. M., Zhu, X. Q. & Zhou, F. C. (2016). Prognostic value of hematological parameters in patients with paraquat poisoning. Sci Rep 6, 36235 (2016). <https://doi.org/10.1038/srep36235>
11. Ambali, S. F., Akanbi, D.O., Shitu, M., Giwa, A., Oladipo, O. O. & Ayo J. D (2010) Chlorpyrifos-induced clinical haematological and biochemical changes in Swiss albino mice: mitigating effect by co-administration of vitamins C and E. *Life Science Journal*, 7(3), 37-44.
12. Chakrabrty, D., Bhattacharyya, A., Mujumdar, K., Chatterjee, K., Chatterjee, S, Sen, A. & Chatterjee, G.C. (1976). Studies of L-ascorbic acid metabolism in rats under chronic toxicity due to organophorous insecticides. *Journal of Nutrition*, 108, 973-980.
13. El-Shenawy, N. S., Al-Eisa, A. R. A., El-Samy, F & Salah, O. (2009). Prophylactic effect of vitamin E against hepatotoxicity, nephrotoxicity, haematological indices and histopathology induced by diazinon insecticide. *Current Zoology*. 55 (3), 219-226.
14. Uzun, F. G., Kalender, S.K., Durak, D., Demir, F., Y. & Kalender, Y. (2009). Melathion-induced testicular toxicity in male rats and the protective effect of vitamins C and E. *British Journal of Toxicology*, 123, 231-243.
15. Sato, K. E., Niki, E. & Shimasaki, A. (1990). Free radical mediated oxidation of low-density lipoprotein and its synergistic inhibition by Vitamin C. *Archives of Biochemistry and Biophysics*, 279, 402-405.

16. Cicchetti F, Drouin-Ouellet J, Gross RE (2009) Environmental toxins and Parkinson's disease: what have we learned from pesticide-induced animal models? *Trends Pharmacol Sci* 30: 475–483.
17. Liou, H.H., Tsai, M.C., Chen, C.J., Jeng, J.S. & Chang, Y.C. (1997) Environmental risk factors and Parkinson's disease: a case-control study in Taiwan. *Neurology*, 48, 1583–1588.
18. Di-Monte, D.A. (2003). The environment and Parkinson's disease: is the nigrostriatal system preferentially targeted by neurotoxins? *Lancet Neurology*, 2(9), 531–538.
19. Dinis-Oliveira, R.J., Remiao, F., Carmo, H., Duarte, J.A. & Sanchez, N.A. (2006). Paraquat exposure as an etiological factor of Parkinson's disease. *Neurotoxicology*, 27, 1110–1122.
20. Przedborski, S. & Ischiropoulos, H. (2005) Reactive oxygen and nitrogen species: weapons of neuronal destruction in models of Parkinson's disease. *Antioxidative Redox Signal*, 7 (5–6), 685–93.
21. McCormack, A.L., Thiruchelvam, M., Manning-Bog, A.B., Thiffault, C. & Langston, J.W. (2002). Environmental risk factors and Parkinson's disease: selective degeneration of nigral dopaminergic neurons caused by the herbicide paraquat. *Neurobiological Diseases*, 10(2), 119–127.
22. McCormack, A.L., Atienza, J.G., Johnston, L.C., Anderson, J.K. & Vu, S. (2005) Role of oxidative stress in paraquat-induced dopaminergic cell degeneration. *Journal of Neurochemistry*, 93, 1030–1037.
23. Lee, H.L., Lin, H.J., Yeh, S.T., Chi, C.H., & Guo, H.R. (2008). Presentations of patients of poisoning and predictors of poisoning-related fatality: findings from a hospitalbased prospective study. *British Medical Compendium of Public Health*, 8, 7.
24. Cristovao, A.C., Choi, D.H., Baltazar, G., Beal, M.F., & Kim, Y.S. (2009). The role of NADPH oxidase 1-derived reactive oxygen species in paraquat-mediated dopaminergic cell death. *Antioxidative Redox Signaling*, 11, 2105–2118.
25. Okolonkwo, B. N., Amadi, C. F., Chikwubike, U. O and Nyenke, C. U. (2022). The comperative effects of vitamin E + C on the chronic toxicity of paraquat in albino rats (*Rattus norvegicus*). *European Journal of Medicinal Plants*, 33(6),7-13
26. Reitman, S. and Frankel, S. (1957). Colorimetric method for the determination of serum glutamic oxaloacetic and glutamic pyruvic transaminase. *American Journal of Clinical Pathology*, 28, 56 – 63.
27. Englehardt, A. (1970). Measurement of alkaline phosphatase enzyme. *Aerztliche Laboratorium*, 16, 42 – 45.
28. Szasz, G. and Bergmeyer, H.U. ed. (1974). Estimation of Gamma-glutamyl transaminase in human serum and plasma. *Method of Enzymatic analysis*. 2nd edn. Weinheim Verlag Chemie, 1, 443 – 444.
29. McCormack, A.L., Atienza, J.G., Johnston, L.C., Andersen, J.K. & Vu, S. (2005) Role of oxidative stress in paraquat-induced dopaminergic cell degeneration. *Journal of Neurochemistry* 93, 1030-1037.
30. Ahmad, I., Shukla, S., Kumar, A., Singh, B.K.. & Kumar, V. (2013) Biochemical and molecular mechanisms of N-acetyl cysteine and silymarin-mediated protection against

maneb- and paraquat induced hepatotoxicity in rats. *Chemistry and Biological Interaction*, 201, 9-18.

UNDER PEER REVIEW