

### **Rare case of cardiac hydatitosis and review of the literature**

#### **Abstract:**

Hydatid disease or hydatid cyst results from the tissue development of the hydatid larva of an echinococcus taenia. It is an endemic disease in certain regions of the world such as the Mediterranean basin. We report here the observation of a 39 year old patient with no particular pathological history admitted for pericardial effusion revealing a cardiac hydatid. After clinical and biological explorations we made the diagnosis of a cardiac hydatid located on the inter ventricular septum. The patient was put under medical treatment because of the refusal of the surgery.

**Key words:** Tamponnade, Hydatid cyst, left ventricle.

#### **INTRODUCTION**

Hydatitosis results from the tissue development of the hydatid larva of a taenia echinococcus. Several cases have been reported in developing countries, particularly in the Mediterranean basin. Cardiac and especially pericardial involvement remains rare, in the order of 0.03 to 1.1% according to the WHO (1-2). Its diagnosis is difficult because of the absence of specific clinical signs(3) . We report the observation of a cardiac hydatid revealed by a pericardial effusion

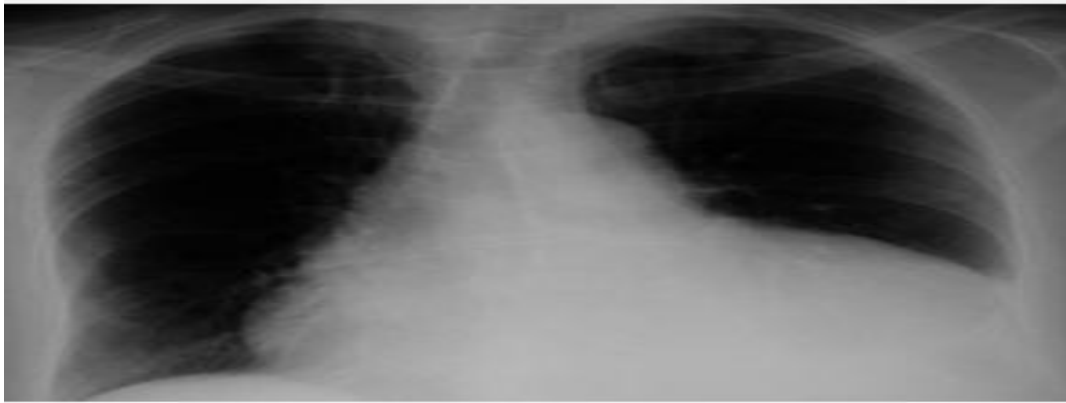
#### **Case Presentation**

MR, 39 years old, with no particular pathological history, consulted for NYHA stage II dyspnea. Clinical examination: Patient conscious, BP=114/73 mmHg, HR=108bpm Cardiovascular examination: Muffled heart sounds with spontaneous turgor of the jugular vein. The rest of the examination was unremarkable.

Biological workup: hyperleukocytosis with eosinophilic predominance at 21% with a biological inflammatory syndrome and anemia at 10 g/dl inflammatory, hydatid serology positive.

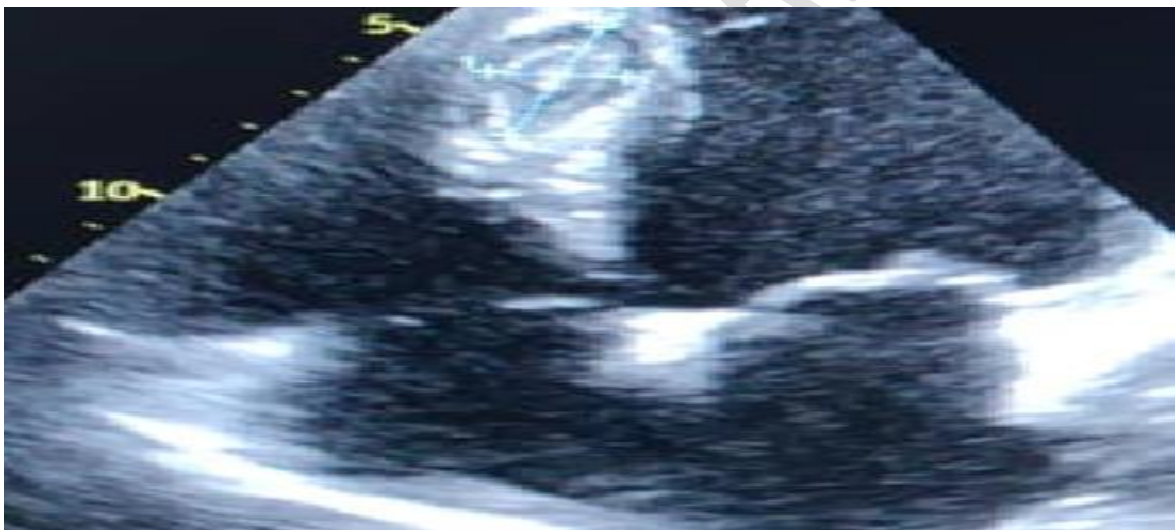ECG: RRS at 98bpm fixed PR at 0.16s, fine QRS with diffuse micro voltage.

Chest X-ray: cardiomegaly with bulging of the left inferior arch.



**Image 1:** Front view of the chest showing a bulge in the left lower arch

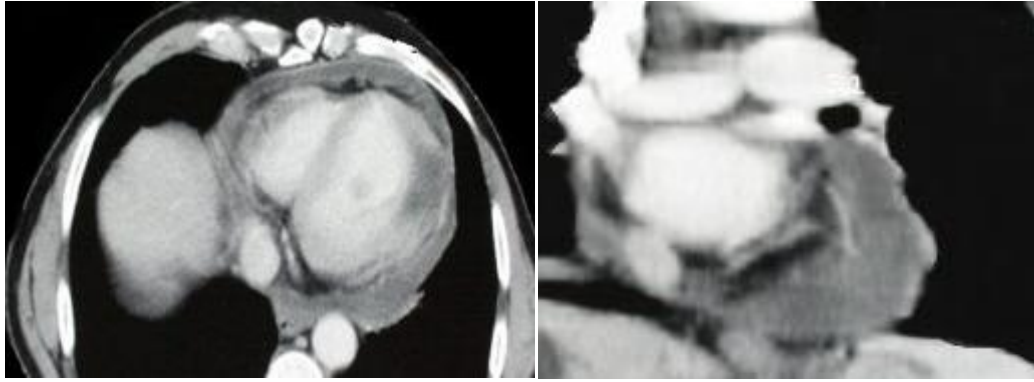
**Trans thoracic echocardiography:** the presence of a large pericardial effusion in pre-tamponade, with an image of cystic appearance appended to the interventricular septum, measuring 12 x 7 mm



**Image 2:** Cystic-like image of the interventricular septum

**An emergency pericardial** puncture was indicated - resulted in the removal of 1130 ml of exudative citrine yellow fluid.

**Thoraco-abdominal CT** showed a type 3 hydatid cyst involving the upper part of the left ventricle



**Image 3:** CT scan section showing a type 3 multivesicular cyst located in the left ventricle

The patient was put on medical treatment (Albendazole®), and referred to surgery for management but the patient refused surgery so we left him on antiparasitic medical treatment

## **DISCUSSION**

Hydatid cysts of the heart are rare. The review of the literature has shown the predominance of the left ventricular location of hydatid cysts, i.e. 60%, which is explained by the importance of the muscular mass and the rich vascularization of the left ventricle (4-5). The larvae arrive at the heart through the right cavities and pass into the systemic circulation by crossing the pulmonary filter and arrive at the myocardium through the coronary circulation. The interventricular septum is affected in 9 to 20% of cases, while the right ventricle and right atrium are affected in 4 to 17% and the interatrial septum in 2% (6) In our case, fissuring of the ventricular cyst is the cause of the pericardial involvement. The symptomatology varies according to the number, location and integrity of the cysts. In some cases, a coronary picture is found, due to the passage of the larvae into the coronary circulation, giving a coronary syndrome due to compression of the coronary arteries(7). The complications represented mainly by a pulmonary embolism, systemic, cerebral, ischemic syndrome or arrhythmia by compression of small coronary vessels and conduction tissue or a rupture in the pericardium as in the case of our patient. Echocardiography is a non-invasive and easily reproducible examination and remains the key examination for the diagnosis of cardiac hydatidosis. Cross-sectional imaging, in particular CT or MRI, allows a more precise topographical analysis and

the study of the relationships with adjacent structures and an assessment of the extension of the cysts to all organs (8-9).

The curative treatment of cardiac hydatidosis is exclusively surgical (10). It is systematic and must be done as early as possible in order to prevent the occurrence of complications, failing which medical treatment with ALBENDAZOLE can be used(11).

## **CONCLUSION**

Despite its rarity, hydatidosis is not negligible in developing countries. It is serious and formidable because of its complications. The therapeutic management is delicate and often of partial effectiveness, hence the interest to privilege the preventive treatment.

### **Ethical Approval:**

**As per international standard or university standard written ethical approval has been collected and preserved by the author(s).**

### **Consent**

**As per international standard or university standard, patients' written consent has been collected and preserved by the author(s).**

### **DISCLAIMER:**

**Authors have declared that no competing interests exist. The products used for this research are commonly and predominantly use products in our area of research and country. There is absolutely no conflict of interest between the authors and producers of the products because we do not intend to use these products as an avenue for any litigation but for the advancement of knowledge. Also, the research was not funded by the producing company rather it was funded by personal efforts of the authors.**

### **References:**

- 1- ORHAN et al, Surgery of cardiac hydatid cysts: Thirty-nine years of experience, Annals of cardiology and angiology, 2008, n°57,58-61.
- 2- Tamponade revealing an intrapericardial hydatid cyst, M. Elhat. Elkarimia,, N. Ouldalgadiab, H. Gacema, Z. Zouizrab, D. Boumzebrab, B. Blelaabidiactaouiaa; Annals of Cardiology and Aneiology 63 (2014) 267-270

- 3- Cardiac hydatid cysts: report of 10 cases Elhattaoui M, Charei N, Bennis A, Tahiri A, Chraibi N, Haddani J, Mehadji BA. Arch Mal Coeur Vaiss. 2006 Jan;99(1):19-25.
- 4- Radioclinic profile of cardiopericardial hydatid cyst: about 17 cases. Mrad Dali, K; Tlili, K; Ly, M; Romdhani, N; Bakir, D; Gharbi, H; Ennabli, K; Jeddi, M. Ann Cardiol Angeiol (Paris) 49(7): 414-22, 2000 Oct
- 5- Ben khalfallah A , Ben slima H ; the hydatid cyst of the heart; which imaging modality for an accurate diagnosis? Ann cardio-Angiology. April 2017; 66: 102-8
  
- 6- Ben Jmaa H, Abdennadher M, Dammak A, Kallel S, Abid L, Msaad S, Masmoudi S, Frikha I. Traitement chirurgical d'un kyste hydatique duseptum inter-auriculaire. Journal de Chirurgie Thoracique et Cardio-Vasculaire 2012;16(2):118-120.
- 7- Kar SK, Ganguly T. Current concepts of diagnosis and management of pericardial cysts. Indian Heart Journal 2017;69(3):363-70. <https://doi.org/10.1016/j.ihj.2017.02.021> PMID:28648435  
PMCID:PMC5485391
- 8- Elhattaoui M, Charei N, Bennis A, Tahiri A, Chraibi N, Haddani J *et al.* Cardiac hydatid cysts: report of 10 cases. Arch Mal Coeur Vaiss. 2006 Jan;99 (1):19-25. **PubMed | Google Scholar**
- 9- Mrad DK, Tlili K, Ly M, Romdhani N, Bakir D, Gharbi H *et al.* Profil radioclinique du kyste hydatique cardiopéricardique: à propos de 17 cas. Ann Cardiol Angeiol (Paris). 2000 Oct;49(7):414-22.
- 10- Oncel D, Oncel G. A rare right atrial mass: Hydatid cyst. European Journal of Radiology Extra 2007;61(3):87

11-Mrad DK, Tlili K, Ly M, Romdhani N, Bakir D, Gharbi H *et al.* Profil radioclinique du kyste hydatique cardiopéricardique: à propos de 17 cas. *Ann Cardiol Angeiol (Paris)*. 2000 Oct;49(7):414-22.

UNDER PEER REVIEW