

Diagnostic Difficulty of Cornual Pregnancy: A Case Report

Abstract

Objective: To report a rare case of cornual pregnancy that we diagnosed during the antenatal period; and to provide a further review of diagnostic difficulty, based on appropriate literature and guidelines available.

Methods: A Case Report

Case: A 25-year old primigravida woman was diagnosed with cornual pregnancy (17-18th weeks of gestation) and intra-uterine singleton live fetus via ultrasonography. The patient experienced progressively severe abdominal pain which radiated throughout the whole abdomen with acute onset of fewer than 24 hours. Abdominal examination revealed distended abdomen, pain with a muscular defense on palpation throughout the whole abdominal regions, and decrease intestinal sound. Vaginal examination revealed motion tenderness on cervical palpation, the uterine cavity was difficult to evaluate due to pain, and no rectovaginal pouch enlargement was noted. Due to unstable progression of the patient's condition, laparotomy surgery was performed, in which left *cornual resection* with wedge resection technique was performed followed by bleeding control.

Conclusion: Cornual pregnancy is a part type of ectopic pregnancy that is often difficult to diagnose, due to its similarity with normal intrauterine pregnancy on transabdominal ultrasonography. Adequate history taking, physical examination, and additional diagnostic modalities are necessary to establish the diagnosis. Routine antenatal care with ultrasonography in the early trimester, can potentially reduce maternal mortality and increase the maternal quality of life.

Keywords: Diagnostic Difficulty, Cornual Pregnancy

Abstrak

Tujuan: Untuk melaporkan kasus langka kehamilan kornu yang kami diagnosa selama periode prenatal; dan untuk memberikan tinjauan lebih lanjut tentang kesulitan diagnostik, berdasarkan literatur dan pedoman yang tersedia.

Metode: Laporan kasus

Kasus: Seorang wanita primigravida berusia 25 tahun didiagnosis dengan kehamilan kornu (kehamilan 17-18 minggu) dan janin hidup tunggal intra-uterin melalui ultrasonografi. Pasien mengalami nyeri perut yang semakin parah yang menyebar ke seluruh perut dengan onset akut kurang dari 24 jam. Pemeriksaan abdomen didapatkan abdomen distensi, nyeri dengan pertahanan otot pada palpasi seluruh regio abdomen dan penurunan bising usus. Pemeriksaan vagina mengungkapkan nyeri tekan pada palpasi serviks, rongga rahim sulit dievaluasi karena nyeri, dan tidak ada pembesaran kantong rektovaginal. Karena perkembangan kondisi pasien yang tidak stabil, operasi laparotomi dilakukan, di mana dilakukan *cornual resection* kiri dengan teknik *wedge resection* diikuti dengan kontrol perdarahan.

Kesimpulan: Kehamilan kornualis merupakan bagian dari kehamilan ektopik yang seringkali sulit didiagnosis, karena kemiripannya dengan kehamilan intrauterin normal pada ultrasonografi transabdominal. Anamnesis yang memadai, pemeriksaan fisik dan modalitas diagnostik tambahan diperlukan untuk menegakkan diagnosis. Pemeriksaan antenatal care rutin dengan ultrasonografi pada trimester awal, berpotensi menurunkan angka kematian ibu dan meningkatkan kualitas hidup ibu.

Kata kunci: Kesulitan Diagnostik, Kehamilan Kornual

INTRODUCTION

Interstitial or cornual pregnancies are both considered rare and potentially precarious forms of ectopic pregnancies, which comprise approximately 2-4% of all ectopic pregnancy cases.^{1,2} Based on the definition, the term 'cornual pregnancy' is used to describe pregnancy cases in which the implantation and development of the gestational sac occur on the upper lateral segment of the uterus.^{3,4} The uterine interstitial area is approximately less than 0.7 mm in width and 1-2 mm in length, along with the surrounding myometrial layer allows the possibility of pregnancy growth until the second trimester; nevertheless, the risk of rupture is often inevitably high, which consequently causes severe bleeding and mortality in approximately 2% of all ectopic pregnancy cases.^{1,2} Ectopic pregnancy diagnosis triad includes acute amenorrhea, acute abdominal pain, and vaginal bleeding, which are often found in 40% of all cases. However, clinically differentiating cornual with intrauterine or other types of ectopic pregnancy cases while subjectively relying on clinical symptoms-signs and sonographic imaging modalities can be complicated; this is in part due to the proximity of cornual pregnancy locations.^{5,6,7} Despite its difficulty, clinically differentiating types of ectopic pregnancy cases is fundamental in determining proper management approach, especially in the recent development of conservative surgical management for cornual pregnancy cases, which gives better outcomes in fertility preservation.^{8,9,10} Therefore, we considered discussions regarding this matter relevant and potentially useful in the field of obstetrics and gynecology. In this paper, we reported a case of cornual pregnancy, which we prenatally diagnosed and managed in our obstetrics and gynecology emergency department.

CASE REPORT

A 25-year-old primigravida woman (G1P0) on her 17th week of gestation visited our obstetrics and gynecology emergency department. The patient experienced progressively severe abdominal pain with acute onset of fewer than 24 hours. The pain radiated throughout the whole abdominal including the epigastric region. The patient denied experiencing vaginal bleeding or discharge throughout pregnancy. The patient had her first and only previous antenatal check-up conducted in a primary health clinic with no previous abnormalities suspected. Her last menstrual period was on June 11th, 2021, with unremarkable menstrual history. The patient had two consecutive previous marital histories, the first three years of marriage ended in 2013, at the age of 18; while the second less than a year marriage ended in 2019, at the age of 24. She recalled having no history of any contraceptive use. She was a non-smoker, non-alcoholic, and has no history of drug abuse. She has neither personal nor family history of congenital abnormalities, diabetes, hypertension, and other diseases.

Initial general examination revealed the patient in severe pain with a *visual analog score* (VAS) of 8-9, with intact consciousness and unremarkable vital signs. Abdominal examination revealed distended abdomen, pain with a muscular defense on palpation throughout the whole abdominal regions, and decrease intestinal sound; while shifting dullness was difficult to evaluate due to severe pain. Vulva-vaginal inspection and speculum examinations were within normal limits of pregnant women. Vaginal examination revealed motion tenderness on cervical palpation, the uterine cavity was difficult to evaluate due to pain, and no rectovaginal pouch (*Douglas Pouch*) enlargement was noted.

Transabdominal sonography revealed a questionable singleton intrauterine pregnancy with the posteriorly implanted placenta; positive fetal heart and fetal movements; biometric assessment of biparietal diameter (BPD) and abdominal circumference (AC) was within normal limits of 16th-17th weeks of gestation pregnancy; the amniotic fluid index was within normal limits and no free fluid collection was noted. Initial complete blood count was taken with a slightly low hemoglobin level of 9,6 g/dL noted. Based on the first overall impression of the examinations conducted, appendicitis rupture was suspected followed by a ruptured ectopic pregnancy. The patient was initially stabilized hemodynamically, with vital signs and pain evaluation observed periodically.

The patient complained of increasingly progressive abdominal pain within the next four hours, and the second complete blood count examination revealed a significantly decreased hemoglobin level of 6,3 g/dL, and acute abdominal bleeding was suspected, henceforth laparotomy was decided to be done along with blood transfusion. Laparotomy surgery revealed a fetus covered with an amniotic membrane inside the abdominal cavity, the membrane was ruptured revealing slightly cloudy amniotic fluid. Further abdominal exploration revealed rupture of the left uterine *cornu* (horn), in which left cornual resection was performed using wedge resection technique followed by mattress and continuous suture with chromic no.2 for bleeding control. Right hydrosalpinx was also found on abdominal exploration, in which right salpingectomy was performed followed by bleeding control and abdominal fluid irrigation to remove excess blood clots. (Figure 1) The surgery was ended with an intraabdominal drain installed. Post-surgical evaluation and blood transfusion were performed throughout the next few days, and maternal condition improvement was significantly noted.

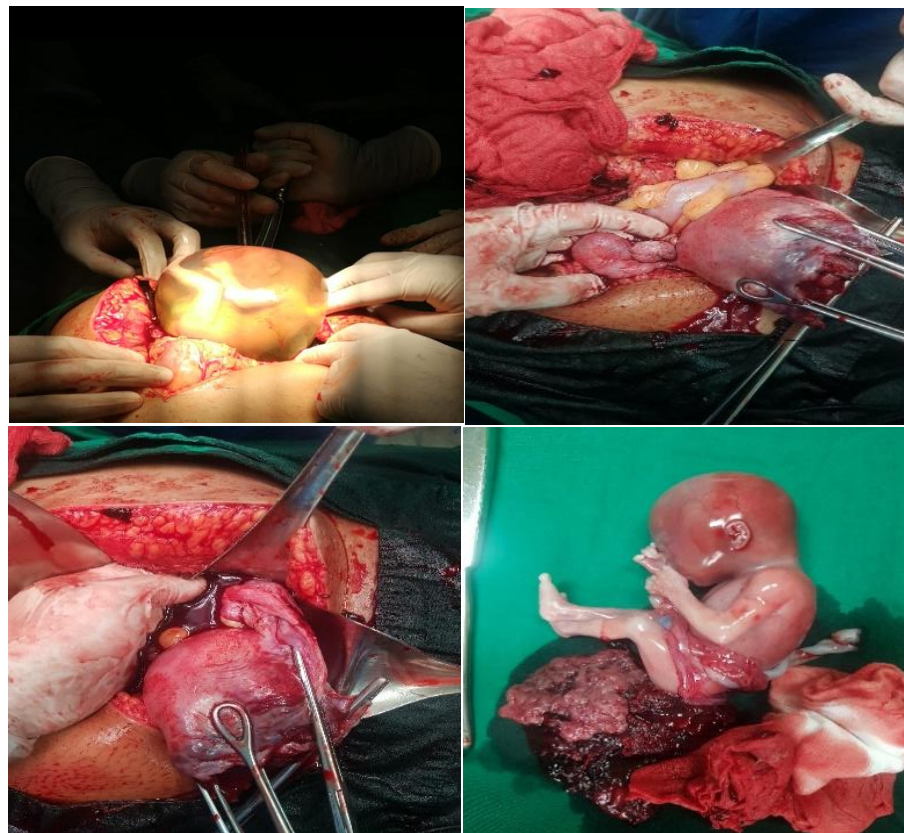


Figure 1: (A) Explorative laparotomy revealed fetus covered in amniotic membrane with slightly cloudy amniotic fluid. (B, C) Rupture of the left uterine cornu and right hydrosalpinx (D) 17-18th week fetus post-surgery

DISCUSSION

Diagnostic Difficulty

Cornual pregnancy is a potentially precarious variant of ectopic pregnancy. Determining proper early diagnostic modality and management remains a challenge for medical personnel, especially for those working in the field of obstetrics and gynecology. Ruptured ectopic pregnancy is considered an obstetrical emergency, which contributes to maternal mortality. Early diagnosis of ruptured ectopic pregnancy can be obtained through complete history taking, general physical examinations, gynecological examinations, additional laboratory examinations, and imaging modalities.¹

Ruptured ectopic pregnancy diagnostic triad includes acute amenorrhea or late periods, acute lower abdominal pain, and vaginal bleeding.⁷ Based on the history taking conducted from our patient, the patient had progressive severe lower abdominal pain with a history of late menstruation [11-13].

General and vital signs examinations of the patient were rather unremarkable, however, abdominal examinations revealed tenderness with a muscular defense on palpation, and pelvic examinations revealed cervical motion pain. Additional supporting diagnostic modalities performed in this case are transabdominal sonography and complete blood examinations. The initial hemoglobin level is 9,6 g/dL. Continuous evaluation of hemoglobin level is essential in ruptured ectopic pregnancy cases. A significant decrease of hemoglobin levels within less than 24 hours indicates severe blood loss in need of prompt hemodynamic stabilization.

Ultrasonography is fundamental in identifying pregnancy and its complications including ruptured ectopic pregnancy. The presence of a gestational sac surrounded by the myometrium layer is the hallmark of intrauterine pregnancy. The diagnosis of ectopic pregnancy especially in cornual or interstitial location variants remains a challenge, just as seen in our case in which no ectopic pregnancy was suspected at first.¹

The sonographic criterion of interstitial pregnancy includes an empty uterine cavity, the gestational sac located far lateral from the uterine cavity, and the myometrial layer surrounding the gestational sac.⁴ “Interstitial line sign” can also be identified in which there is an extension of the upper uterine region into the boundaries between the intramural region and the fallopian tube.⁵ In our case, cornual pregnancy was proven following laparotomy. After the initial sonographic examination, suspicion of ectopic pregnancy was shifted to peritonitis.

Unlike an ectopic pregnancy, peritonitis is an inflammatory response of the peritoneum, which can be caused by intraabdominal organ infection, perforation, or penetration wound of the abdomen.⁸ General manifestation of peritonitis includes fever, acute abdominal pain, and abdominal muscular defense. Both acute abdominal pain and muscular defense were identified in our case, however, no sign of fever was identified.

Management

The principle of ruptured ectopic pregnancy management includes initial hemodynamic stabilization and surgery to identify the bleeding source and to control bleeding. Management can be classified further into medication and non-medication management.⁹

Surgical management was considered in this case due to a significant decrease in hemoglobin levels from 9,6 to 6,3 g/dL after periodical evaluation, and the patient appeared pale on physical examination. Surgical management can be performed in both ruptured or non-ruptured ectopic pregnancies depending on the patient’s clinical conditions. Possible surgical management option for cornual pregnancy (cornual resection) includes conservative surgery using wedge resection technique in which tubal integrity is maintained and radical surgery in which the fallopian tube is excised. Conservative surgery is further classified into salpingostomy and salpingotomy. Cornual resection was performed on the left fallopian tube of our patient, and salpingectomy was performed on the right fallopian tube of our patient with hydrosalpinx. After surgery, the patient was evaluated and observed for several days with improving clinical conditions.¹⁰

Prognosis

The patient’s clinical condition significantly improves after surgery, this is in part due to the early onset of management given. The patient was re-evaluated for adequate recovery. The

patient was also given proper education for surgical wound management before being discharged home. One possible complication this patient might have is infertility due to radical removal of the right fallopian tube (salpingectomy).^{9,10}

CONCLUSION

Cornual pregnancy is a part type of ectopic pregnancy that is often difficult to diagnose, due to its similarity with normal intrauterine pregnancy on transabdominal ultrasonography. Adequate history taking, physical examination, and additional diagnostic modalities are necessary to establish the diagnosis. Routine antenatal care with ultrasonography in the early trimester, can potentially reduce maternal mortality and increase the maternal quality of life.

Ethical Approval:

As per international standard or university standard written ethical approval has been collected and preserved by the author(s).

Consent

As per international standard or university standard, patients' written consent has been collected and preserved by the author(s).

REFERENCES

1. Alkatout I, Honemeyer U, Strauss A, Tinelli A, Malvasi A, Jonat W et al. Clinical Diagnosis and Treatment of Ectopic Pregnancy. *Obstetrical & Gynecological Survey*. 2013;68(8):571-581.
2. Zou S, Li X, Feng Y, Sun S, Li J, Egecioglu E et al. Comparison of the diagnostic values of circulating steroid hormones, VEGF-A, PIGF, and ADAM12 in women with ectopic pregnancy. *Journal of Translational Medicine*. 2013;11(1).

3. Larraín D, Marengo F, Bourdel N, Jaffeux P, Aublet-Cuvelier B, Pouly J et al. Proximal ectopic pregnancy: a descriptive general population-based study and results of different management options in 86 cases. *Fertility and Sterility*. 2011;95(3):867-871.
4. Bollig K, Schust D. Refining Angular Pregnancy Diagnosis in the First Trimester. *Obstetrics & Gynecology*. 2019;135(1):175-184.
5. Siow A, Ng S. Laparoscopic Management of 4 Cases of Recurrent Cornual Ectopic Pregnancy and Review of Literature. *J Minim Invasive Gynecol*. 2011;18:296-302.
6. Moawad NS, Mahajan ST, Moniz MH, et al. Current diagnosis and treatment of interstitial pregnancy. *Am J Obstet Gynecol*. 2010; 201:15-29.
7. Taylor H, Pal L, Seli Emre. Ectopic Pregnancy In Sperrof's Clinical Gynecologic Endocrinology and Infertility, 9th ed. Philadelphia. Lippincott William & Wilkins, 2011, pp 3298-3359
8. Brunicardi F, Andersen D, Billiar T. Intraabdominal Infections In Schwartz's Principles Of Surgery, 10th Ed. New York. Mc Graw-Hill Education, 2015. pp 149-150.
9. Jones H, Rock J. Ectopic Pregnancy. In Te Linde's operative gynecology. 11th ed. Philadelphia. Walters Kluwer. 2014, pp 1384-1426.
10. Cunningham FG, Leveno KJ, Bloom SL, et. al. Ectopic Pregnancy. In: Spring CY, Jody SD, Hoffman BL, editor. *Williams Obstetrics*. Ed 24. New York: Mc Graw Hill, 2014. Pp 377-391.
11. Mansour M, Hamza A, AlMarzook A, Kanbour IM, Alsuliman T, Kurdi B. A ruptured cornual pregnancy successfully managed in a patient with a history of oophorectomy and salpingectomy: A rare case report. *Clinical Case Reports*. 2021 Oct;9(10):e04934.
12. Ranaei-Zamani N, Palamarchuk T, Kapoor S, Kaler MK, Atueyi F, Allen R. Diagnostic Challenges of an Abdominal Pregnancy in the Second Trimester. *Case Reports in Obstetrics and Gynecology*. 2021 Aug 3;2021.
13. Suoseg DP, Seidu AS, Koray U, Iddrisu S, Mohammed M, Baba SM, Titigah AB, Charadan AM. Ruptured Interstitial Ectopic Pregnancy at 18 Weeks: How Failure of Early Detection Resulted in a Maternal Near-miss. *Journal of Gynecology and Obstetrics*. 2021;9(4):125-7.

