

Chronic Granulomatous Schistosomal Cholecystitis in Non-Endemic Zone, A Rare one: A Case Report

ABSTRACT

Background: - Moynihan's aphorism that "gall stone is a tomb stone erected in the memory of the organism with in it" is true even today. This case could be an example to reemphasise the forementioned axiom. **Here is a case of Chronic** Granulomatous Schistosomal cholecystitis which is an unusually rare cause of Cholecystitis and cholelithiasis, that too in a non-endemic area. The patient has never ever visited the known endemic zones of Schistosomiasis or Bilharziasis areas in India. In a way it could be the first case report of schistosomiasis in this area.

Case presentation:

A 59-year-old female patient presented to the Out-patient department of SMS&R, Sharda university, with right hypochondriac region pain and dyspepsia of six months duration. Investigation revealed Chronic Cholecystitis with Cholelithiasis.

After a thorough workup the patient was taken up for Laparoscopic cholecystectomy, which was converted to open cholecystectomy due to adhesions and to prevent any iatrogenic injury to the biliary tree. Histopathological examination revealed Chronic Granulomatous Schistosomal Cholecystitis with Cholelithiasis. Patient did well in the post-operative period with anti-helminthic treatment.

Conclusion:

Literature is still undecided whether the Schistosomal eggs deposition in the gallbladder can cause an episode of acute cholecystitis. However, a lithogenic outcome of schistosomiasis secondary to the induction of chronic granulomatous and fibrocalcific changes of the gallbladder and biliary ducts wall, seems probable.

Keywords: Gall bladder, Cholecystectomy, Schistosomiasis, Bilharziasis

BACKGROUND

Schistosomiasis is one of the commonest parasitic infestations on the worldwide basis after Malaria [1]. It is caused by flat parasite i.e., trematode of helminthic family. It is an important healthcare burden in many resource poor countries. It affects almost 240 million people worldwide and causes more than 200 deaths per year [1]. Urinary bladder and large intestine being the common predilection. Uncommonly liver involvement may be seen. This is usually because of Mansoni species. Gall bladder is extremely rare abode and therefore makes clinical detection difficult [8].

CASE PRESENTATION

A 59-year-old female Noida resident presented to us in the surgery OPD of Sharda Hospital with complaints of chronic right sided hypochondriac region pain and heaviness which was insidious in onset, episodic in nature, mild in intensity, dull aching type of pain., with associated occasional nausea and vomiting more after heavy meals. No other significant positive history was obtained.

Patient was taking regular medication for hypertension from outside for last 15 years since she was diagnosed to be hypertensive. She has had blood pressure within normal limits on examination. Patient has had no history of any chronic illnesses like tuberculosis diabetes, jaundice in the past. Patient has undergone lower segment caesarean section twice in the past with 2 alive children. Also, patient has undergone laparoscopic tubal ligation done more than 20 years back outside.

There was no pallor, icterus, clubbing or any lymphadenopathy.

On abdominal examination, there was old well healed surgical scars with soft protuberant abdomen, but no palpable lump, no organomegaly.

Patient was admitted and investigated.

Whole abdomen Ultrasound revealed multiple Gall bladder calculi largest ~ 12.5mm, thickened gall bladder wall, with normal Common Bile Duct diameter and multiple small renal calculi ~ 4mm. Rest scan was unremarkable.

Blood investigations done were essentially unremarkable except for renal functions (**Serum Creatinine-2mg/dl and Blood Urea-76mg/ dl.**)

In view of left renal calculus ,deranged renal parameters and hypertension, patient was advised for Diethyl Triamine Pentacetic Acid (DTPA) scan.

DTPA revealed bilateral kidneys having mildly reduced function with non-obstructed disease.

Collectively aforesaid concluded to the diagnosis of chronic calculous cholecystitis with poor pre-existing renal functions (chronic kidney disease CKD) with hypertension.

Stenting surgery advised for renal problem was refused by the patient as poor renal functions were well tolerated by her and hence only gall bladder surgery was done on patient request. After optimization patient was posted for elective laparoscopic cholecystectomy under informed consent.

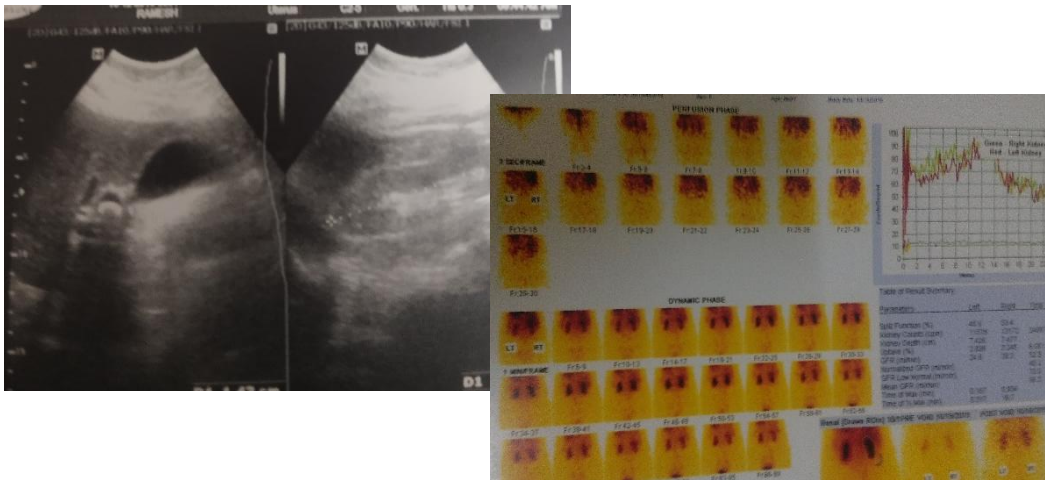


Figure 1: (a) preoperative ultrasound showing thick-walled Gall bladder with stone, (b) DTPA scan showing poor left renal functions

Per-Op:

Per op. -Gall bladder distended, thick walled, **dense** Calot's adhesions, between omentum and Gall bladder body. Multiple small discrete white patches seen on bowel surfaces. Dilated Hartmann pouch with impacted stones seen.

Laparoscopic cholecystectomy was therefore converted to open cholecystectomy due to adhesions and to prevent any iatrogenic injury to the biliary tree.

Post-Op:

Post-operative period was uneventful. Drain was removed on 2nd post-operative day. Patient was discharged on 3rd post-operative day with symptomatic treatment advice.

Histopathology Report:

Gross specimen of Gall bladder was ~ 6x3 cm with outer surface congested and glistening. On cut section the mucosa is congested with focal atrophied areas. Wall thickness ~ 3mm. Single large calculus ~ 12mm laminated spherical dirty yellowish in colour with irregular surface seen.

Biopsy revealed apart from chronic calculus cholecystitis, a chronic schistosomal infestation of gall bladder. Gall bladder shows atrophic mucosa with dense chronic inflammation with wall showing calcific deposits and numerous basophilic ova entrapped in the fibrous tissue. Few of the ova were calcified.

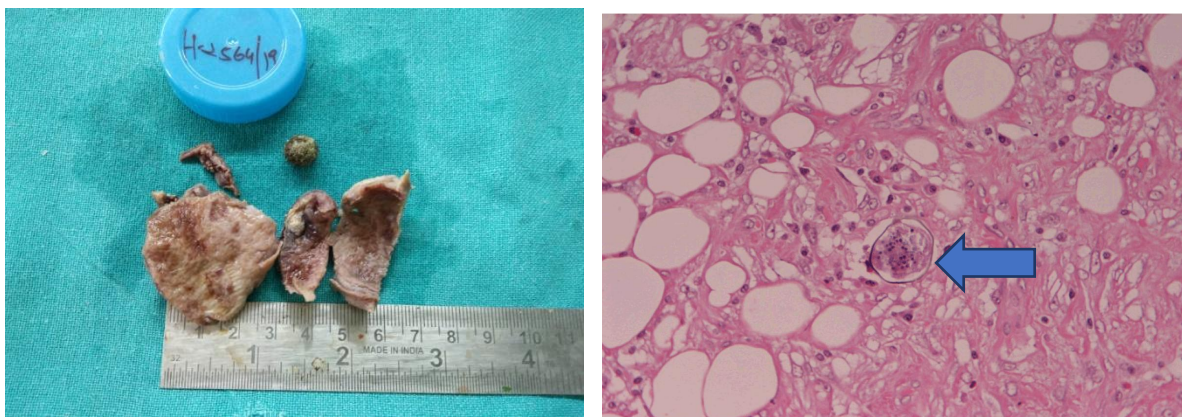


Figure 2: (a) Opened up excised Gall bladder, stone (b) High power view showing hyaline walled eggs (dark blue arrow), occasional calcification in Gall bladder wall

Follow up:

Patient fared well with Anti helminthic (Tablet Praziquental) treatment and related symptomatic medication in the follow-up. At 12 months post-operative period patient has no new symptoms or any evidence suggestive of urinary bladder or digestive tract involvement.

DISCUSSION

Other than malaria, schistosomiasis remains one of the important causes of parasitic infestation in major parts of the world including the tropical countries. It affects almost 240 million people worldwide and causes more than 200 deaths per year [1]. Urinary bladder and large intestine being the common predilection. Uncommonly liver involvement may be seen. Gall bladder is extremely rare abode. Schistosomiasis seconds malaria in economical and societal burden in terms of parasitic infestation on a worldwide basis. It is caused by a flatworm i.e., trematode of helminthic family [2]. Its larva enters the body via skin contact with contaminated water having parasite eggs. Once inside, the larva matures into adult schistosomes that reside in blood vessels where females will lay eggs. Most of the eggs are excreted via stools except a few that manage to remain in the human body tissues, which are responsible for clinical manifestations of schistosomiasis [1, 2, 3]. Out of the three well known species of *Schistosoma* responsible for human infestation, *Schistosoma japonicum* is the most virulent and difficult to treat because of its zoonotic nature. It has the capability to invade almost any organ, but it has inclinations specifically for colon, urinary bladder, and ureter [1]. The most plausible reason for this is the variability in the venous drainage of different organs, the higher is the number of veins, the more likely the female worms are to lay eggs [4,5]. Clinical presentation is due to the granulomatous immune response of the body to eggs of schistosomes. Granulomatous inflammation explains the pathogenesis of chronic schistosomiasis. In cases where the female enters the mesenteric veins and lays eggs which may later embolize to hepatic area through portal vein. This leads to a granulomatous inflammatory response in liver, causing hepatic

fibrosis and consequent portal hypertension [10]. This hepatic fibrosis can be seen in involved cases in endemic zone, which in neglected cases may present as hepatic pseudo tumour appearance making diagnosis difficult [11]. Few studies have found an association between Schistosomiasis and biliary tract malignancies like cholangiocarcinoma [12]. Neglected or untreated cases may develop hepatic, gastrointestinal, splenic and even cerebral complications in later stages [9].

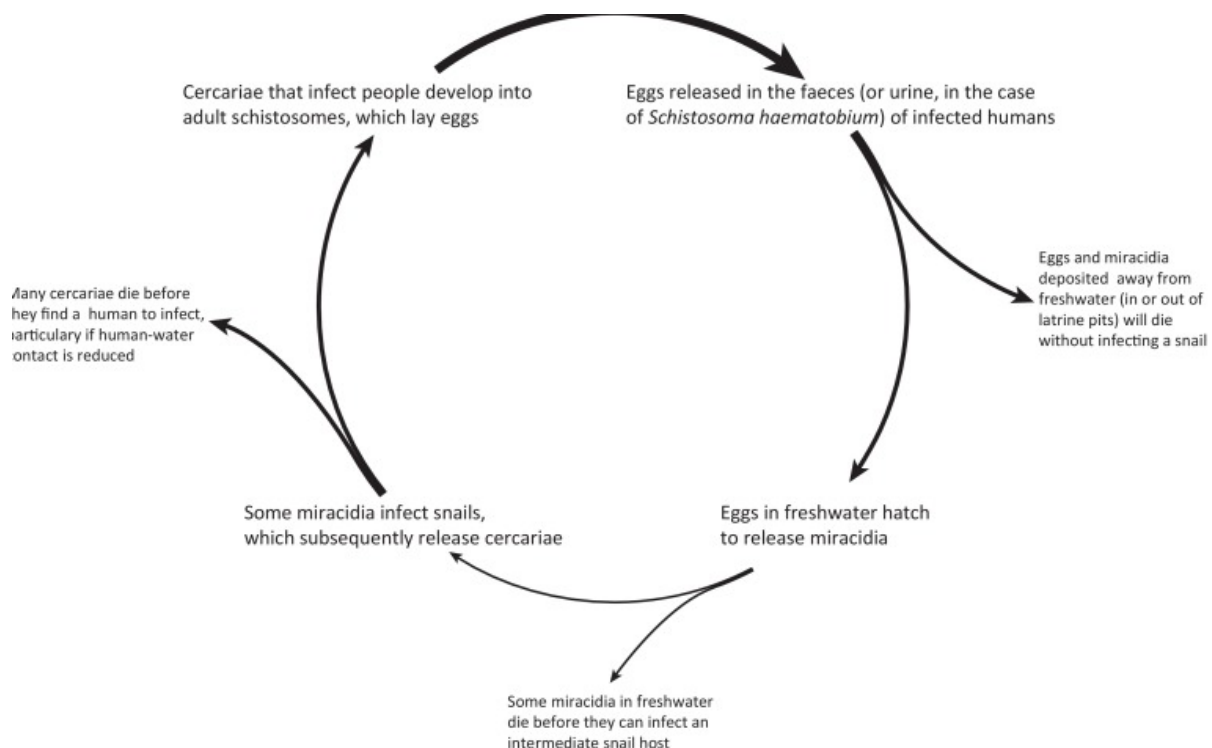

Fig.-Lifecycle of schistosomiasis

Schistosomiasis is public health concern in resource poor countries with scarcity problems of clean & safe drinking water and sanitation. Endemic areas usually encounter cases with urinary affliction. *Per se* gall bladder involvement is extremely rare and probably occurs in late stages of disease. Total cases of gall bladder schistosomiasis reported so far are within two digits number worldwide. First such case was reported by Rappaport in 1975 [5]. A series of 6 cases were reported from Iraq in 1983 [6]. One case was reported from Saudi Arabia in 1996 [7].

Involved cases will show thickening of the gall bladder wall with evidence of chronic inflammation and schistosomal eggs and ova in the wall and associated fibrocalcific changes. There have been no classical clinical sign symptoms associated with it. Neither is there any typical radiological findings for confirmation. Consequently, the gall bladder schistosomiasis is always a histological diagnosis, post-surgery.

CONCLUSION

A past middle aged female presented with chronic right sided hypochondriac region pain and heaviness, more after heavy meals was found to be having chronic calculous cholelithiasis. Subsequent workup revealed poor renal functions well tolerated by the patient. After thorough workup and informed consent, cholecystectomy was done.

Uncommon combination of chronic calculous cholecystitis with poor pre-existing renal functions with chronic asymptomatic schistosomiasis is an extremely rare combination, probably never reported till date which was diagnosed post operatively by meticulous histopathological examination in our case.

Literature is still undecided whether the Schistosomal eggs deposition in the gallbladder can cause an episode of acute cholecystitis. However, a lithogenic outcome of schistosomiasis secondary to the induction of chronic granulomatous and fibrocalcific changes of the gallbladder and biliary ducts wall, seems probable.

Gall bladder schistosomiasis being an extremely rare disease, one should have a high index of suspicion in patients coming from endemic zones and Noida is not endemic for Schistosomiasis; a very high index of suspicion should also be made when patients having travel history to endemic zone arrive with gallbladder problems on ultrasound having atypical or usual gall bladder affliction [13]. It is a disease with non-classical symptomatology that may remain silent even and discovered histopathologically in post-operative period. Patients usually fare well with Anti helminthic treatment and related symptomatic medication in the follow-up.

Ethical Approval:

As per international standard or university standard written ethical approval has been collected and preserved by the author(s).

Consent

As per international standard or university standard, patients' written consent has been collected and preserved by the author(s).

REFERENCES

1. Gryseels B, Polman K, Clerinx J, Kestens L. Human schistosomiasis. *The Lancet*. 23 Sept 2006; 368(9541): 1106-18. PubMed | Google Scholar
2. Alam K, Maheshwari V, Jain A, Siddiqui F, Haq M, Prasad S et al. Schistosomiasis: a case series, With Review Of Literature. *The Internet Journal of Infectious Diseases*. 2009; 7(1).
3. Marcial MA, Marcial-Rojas RA. Cholecystitis due to *Schistosoma mansoni*, fact or fancy. *Boletin Asoc Medica PR*. Mai 1989; 81(5): 178-9. Google Scholar
4. Chitsulo L, Engels D, Montresor A, Savioli L. The global status of schistosomiasis and its control. *Acta Trop*. 23 Oct 2000; 77(1): 41-51. PubMed | Google Scholar
5. Rappaport I, Albukerk J, Schneider IJ. Schistosomal cholecystitis. *Arch Pathol*. Avr 1975; 99(4): 227- 8. PubMed | Google Scholar
6. al-Saleem T, al-Janabi T. Schistosomal cholecystitis: report of six cases. *Ann R Coll Surg Engl*. Nov 1989; 71(6): 366- 7. PubMed | Google Scholar

7. Sharara AI, Abi-Saad G, Haddad M, Mansour A, Tawil A. Acute granulomatous schistosomal cholecystitis. *Eur J Gastroenterol Hepatol*. Août 2001; 13(8): 1001-3. PubMed | Google Scholar
8. Majrashi SA, Al Amoodi OM. Schistosomiasis as a cause of acute cholecystitis. *Saudi Med J* 2018;39(7):725–8. *Radiology Case Reports* 15 (2020) 1394–1397 1397
9. Nelwan ML. Schistosomiasis: life cycle, diagnosis, and control. *Curr Ther Res Clin Exp* 2019;91:5–9.
10. Elliott DE. Schistosomiasis. Pathophysiology, diagnosis, and treatment. *Gastroenterol Clin North Am* 1996;25(3):599–625.
11. Ghimire P, Wu GY, Zhu L. Atypical clinico-radiological presentation of hepatic schistosomiasis as pseudotumor and pyogenic abscess. Two case reports. *Eur J Radiol Extra* 2011;78(3):e125–e1e7.
12. Andoh H, Yasui O, Kurokawa T, Sato T. Cholangiocarcinoma coincident with schistosomiasis japonica. *J Gastroenterol* 2004;39(1):64–8.
13. Richter J, Azoulay D, Dong Y, Holtfreter MC, Akpata R, Calderaro J, et al. Ultrasonography of gallbladder abnormalities due to schistosomiasis. *Parasitol Res* 2016;115(8):2917–24