

**Optical Coherence Tomography Angiography and Fundus Fluorescein
Angiography in Myopic Choroidal Neovascularization**

Abstract:

Background: High myopia refers to an axial length of the eye greater than 26 mm or by having a refractive error of more than - six diopters. The most frequent cause of Choroidal neovascularization (CNV) in patients less than 50 years old is pathologic myopia. CNV is a serious lesion of the retina and choroid leading to vision loss or blindness due to subretinal or intraretinal fluid, hemorrhage, and lastly scar.

Fundus biomicroscopy, fundus fluorescein angiography (FFA), and optical coherence tomography (OCT) are the most common methods used to diagnose myopic CNV. Optical coherence tomography angiography (OCTA) shows both the retinal and choroidal vasculature, so it is used to diagnose choroidal neovascular membrane.

Aim: Study the role of OCTA in the diagnosis of choroidal neovascularization in myopia and compare it with the findings of fundus fluorescein angiography (FFA).

Patient and Methods: our study included twenty eyes of twenty patients **who** had active myopic CNV in the Ophthalmology Department, Tanta University.

Results: Spherical Equivalent ranged from - 6.5 to - 16.0 diopters. The vessel density (VD) had a statistical significance higher in OCTA, compared to FFA ($p < 0.001$). The CNV area was significantly less in OCTA, compared to FFA ($P = 0.012$). There was Statistical significance between BCVA as regard CNV site on FFA ($P = 0.002$). The BCVA is less in subfoveal CNV than in juxtafoveal CNV.

Conclusion: OCTA is a new imaging technique, non-invasive and safe with rapid image acquisition. The recent gold standard for the assessment of myopic CNV is FFA, where the existence of CNV is detected by dye leakage; although, FFA is invasive and may be accompanied by nausea, urticaria, and very rarely anaphylaxis.

For the diagnosis and follow-up of myopic CNV, OCTA is still frequently used in combination with FFA.

Keywords: Myopic Choroidal Neovascularization, Optical Coherence Tomography Angiography.

Abbreviations

BCVA : Best Corrected Visual Acuity.

CNV : Choroidal Neovascularization

FFA : fundus Fluorescein Angiography

OCTA : Optical Coherence Tomography Angiography.

VDZ : Vascular Density Zone.

Introduction:

Pathological myopia is defined as myopia associated with degeneration in the retinal pigment epithelium, choroid, and sclera leading to deterioration and impairment of visual function. ⁽¹⁾

Myopic CNV is a common vision-threatening consequence of myopia and pathological myopia. ⁽²⁾ Fundus biomicroscopy, FFA, and OCT are the usual diagnostic procedures for diagnosing myopic CNV in conjunction with color photos and clinical examination. FFA evaluated the existence, type, size, and activity of myopic CNV, and helps to rule out other diseases. ^(2, 3, 4) A time-consuming, invasive approach that demands an intravenous infusion of dye. ⁽⁵⁾ However, the use of FFA is restricted by rare adverse effects like nausea and even allergy, and it is generally contraindicated in individuals with cardiac or renal problems. ⁽⁶⁾

The recently developed optical coherence tomography angiography (OCTA) could solve some of the limitations of FFA because it is a non-invasive and quick method. OCTA can image the en-face retinal and choroidal vasculature by estimating the flow of erythrocytes in blood vessels with time. ⁽⁷⁾

OCTA is non-invasive using motion contrast rather than intravenous(IV) dye, which gives accurate size and localization ⁽⁷⁾ and three-dimensional imaging of the lesion. ⁽⁸⁾

Patients and Methods:

This prospective randomized study was done in the outpatient retina clinic at the Ophthalmology Department of Tanta University in Egypt, from September 2019 to December 2020. This study included twenty eyes of twenty patients who had active myopic CNV.

There were no risks for the subjects who participated in this study.

Patients' privacy was respected by hiding their names from data files and investigations using codal numbering.

Exclusion criteria:

- Patients who have dense media opacity or narrow pupils interfere with the accuracy of imaging procedures.
- Patients who have neurological conditions that interfere with proper detection of the OCTA image, such as Parkinsonism or poor fixation.
- Patients who have other causes of diminished visual acuity, optic atrophy.
- Systemic conditions in which fluorescein angiography is contraindicated, or risky, such as pregnancy, or renal failure.
- History of intraocular surgery within the last 6 months.
- Patients with the previous injection of anti-VEGF or laser photocoagulation.
- History of diabetic retinopathy
- History of glaucoma
- Other causes of CNV: AMD, Angioid streaks, Choroiditis and Traumatic choroidal ruptures.

Procedure

After history taking, the routine full ophthalmic examination was done; including BCVA, The VA was converted from Snellen to Decimal notation, anterior and posterior segment examination, FFA, OCT, and OCTA imaging. For facilitating imaging, tropicamide 1 percent was used in each case to dilate the pupils.

After an IV injection of five ml of 10% sodium fluorescein dye (Heidelberg Engineering, Germany), FFA was done by the Heidelberg Retinal Angiogram.

OCT and OCTA imaging were taken by a DRI OCT Triton and a swept-source OCT (Topcon Corp., Japan).

OCTA imaging on the fovea was performed by 3 x 3 mm and 6 x 6 mm. The macular scans were automatically divided into 4 'en face' OCT slabs by the OCTA software: (1) superficial capillary plexus (SCP): which involves the area from the inner border of the internal limiting

membrane (ILM) to the inner border of the inner plexiform layer (IPL). (2) Deep capillary plexus (DCP): involves the area from the outer border of IPL to the outer border of the inner nuclear layer (INL). (3) Outer retina: stretched from outer plexiform layer (OPL) to retinal pigment epithelium (RPE). (4) Choriocapillaris: start 10 mm below RPE – Bruch's membrane which are 20 µm thick slab.

Two parameters were applied to quantify the OCTA results in the macula: CNV area in mm² and vascular density zone (VDZ) (%).

CNV dimensions were calculated by outlining the CNV membrane in the outer retina images by the observer and the region was estimated by the device.

Vascular Density Zone (VDZ) is considered the percentage of the area occupied by vessels in the segmented area, which is a 3 x 3 mm² scanned area centered on the fovea. By utilizing image J software (Image J 1.48v; National Institutes of Health, Bethesda, Maryland, USA), VDZ was quantified after transforming the images obtained into binary formats.

To enable comparison and analysis, FFA data were aligned to the OCTA images using retinal vascular landmarks and cropped to the corresponding dimensions (3 mm × 3 mm). The freehand selection option of the Prime ruler application was used to manually measure the CNV area in the early FFA. (Android, 2v Masyukovsch, china str., Minsk). Image J was used to quantify the vascular density of CNV in the early stage of FFA and OCTA (outer retina).

Statistical analysis:

The statistical presentation and analysis of this study use the mean, standard deviation, paired t-test, linear correlation coefficient, and variance analysis (ANOVA) test of the statistical package of Social Science version 20 (SPSS© v. 20.0, SPSS Inc., Chicago, IL, USA). The linear correlation coefficient was used to show the correlation between two quantitative variables in a group. Significance levels were accepted with p-values less than 0.05.

Results:

The study included twenty eyes of twenty patients; seven males (35%) and thirteen females (65 %). Their age ranged from 38 to 60 years with a mean of 49.4 years (SD \pm 5.6). Spherical Equivalent ranged from - 6.5 to - 16.0 diopters (table 1). BCVA (decimal) ranged from 0.02 to 0.1 with a mean of 0.05 ± 0.02 . According to FFA: in thirteen patients (65%), CNV was subfoveal and juxtafoveal in seven patients (35%). According to OCT: CNV is associated with subretinal fluid only in ten patients (50%), subretinal & intraretinal fluid in seven patients (35%), and intraretinal fluid only in three patients (15%) as in (table 2). OCTA revealed an interlacing vascular network of CNV as 75% of patients (15) were organized interlacing neovascular patterns and 25% of patients (5) were disorganized neovascular loops patterns. The VD was significantly higher in OCTA, compared to FFA ($p < 0.001$) as in (table 3). The CNV area was significantly less in OCTA, compared to FFA ($P = 0.012$) as in (table 4). There was no statically significance between BCVA as regards VD in OCTA (%) and in early FFA (%). There was no statically significance between BCVA as regards CNV area in OCTA (%) and in early FFA (%).

There was a significant correlation between BCVA as regards the CNV site on FFA ($P = 0.002$) as in (table 5). The BCVA is less in subfoveal CNV than in juxtafoveal CNV. There was a significant correlation between BCVA as regards the presence of intraretinal & subretinal fluid ($P = 0.005$). There was a significant correlation between CNV sites as regard CNV area in OCTA (mm^2)

Discussion:

In our present study, the mean age was 49.4 years (SD \pm 5.6) which was similar to the results of Saksoukh et al., 2021⁽⁹⁾ study which reported that the mean age was 56.60 years (SD \pm 14.66)

Regarding the gender of the patients, the results of the study confirmed that more females than males were affected by myopia CNV. This was reported by Bruyère et al, 2017⁽¹⁰⁾, Querques et al, 2017⁽¹¹⁾, Mohsen and Kisk, (2019) Study⁽¹²⁾ Therefore, myopia will be observed more often in women, and myopia CNV will be more often seen in women.⁽¹³⁾In the current study, Spherical Equivalent(SE) ranged from - 6.5 diopters to - 16.0 diopters with a mean of $- 10.98 \pm 2.87$ diopters which is consistent with Sakhsoukh et al., 2021⁽⁹⁾ who found that mean SE refraction was $- 12.72 \pm 4.75$. Also in another study by LI et al., 2020⁽¹⁴⁾ the mean spherical equivalent refraction was -11.71 ± 4.80 D.

In the study done by Wang et al., 2021⁽¹⁵⁾; the overall pattern of high-flow neovascular networks can be divided into two phenotypes: organized interlacing pattern (83.87%) and disorganized vascular loops pattern (16.13%) which agreed with our results.

According to VD, it ranged from 60.24 - 86.25 % with a mean \pm SD was 73.09 ± 6.07 in OCTA (the outer retina) which corresponds to the results of Wang et al., 2021⁽¹⁵⁾ who noticed that the mean VD of 74.49 ± 1.69 . The mean VD was 42.24 ± 5.9 in the study done by Mao et al., 2019⁽¹⁶⁾

In our study, the CNV area in OCTA (the outer retina) ranged from 0.3 - 4.2 mm² with a mean \pm SD was 1.4 ± 1.1 . While CNV area in early FFA ranged from 0.3– 7.8 mm² with a mean \pm SD was 2.5 ± 2.0 while in the study done by LI et al., 2020⁽¹⁴⁾ CNV area in OCTA (the outer retina) ranged from 0.23 to 1.26 mm² with a mean \pm SD was 0.62 ± 0.58 . While CNV area in early FFA ranged from 0.02 to 1.17 mm² with a mean \pm SD was 0.30 ± 0.43 .

We reported that the CNV area was significantly less in OCTA, compared to FFA which agrees with Chhablani et al., 2015⁽¹⁷⁾. It supports FFA with more consensus among clinicians for diagnosing myopia CNV. This is similar to previously reported studies in cases of CNV secondary to age-related macular degeneration and myopia CNV.⁽¹⁸⁾ Milani et al, 2013⁽¹⁹⁾ reported that the overall observer agreement for FFA in the eye with myopia CNV was 0.53

Conclusion

FFA is the gold standard for the diagnosis of myopic CNV in which the presence of CNV is indicated by leakage of the dye; although FFA is invasive and may be accompanied by nausea, urticaria, and anaphylaxis.

OCTA is a non-invasive, safe new imaging technique, with quick image acquisition.

In routine practice, OCTA is still combined with FFA for the diagnosis and follow-up of myopic CNV.

Ethical Approval and Consent

All the patients were informed and provided their written consent. The study was accepted by the local research ethical committee of the medicine faculty in Tanta University in Egypt.

The ethical approval date: 11/2017, The approval code: 31947/11/17

Recommendations:

Further studies are necessary to understand the possibility of noninvasive OCTA to completely replace conventional dye tests, avoiding their unpredictable side effects.

Larger studies with long-term follow-up are needed to determine the prognostic value of OCTA.

Due to the invasiveness of FFA, FFA cannot be performed on all visits, and active myopic CNV can be misdiagnosed on the basis of FFA alone. Therefore, in patients with myopic CNV, both OCT and OCTA may serve as non-invasive alternatives for monitoring CNV and making treatment decisions during follow-up.

Limitations

Motion artifacts can reduce the image quality of OCTA. For large edema and/or bleeding, an automatic segmentation fault occurs. In such cases, we had to resort to manual segmentation by the operator.

Financial support and sponsorship: Nil.

Conflicts of interest:

There are no potential conflicting interests.

References:

1. **Ren P, Lu L, Tang X, Lu H, Zhao Y, Lou D, Han W.** Clinical features of simple hemorrhage and myopic choroidal neovascularization associated with lacquer cracks in pathologic myopia. *Graefe's Archive for Clinical and Experimental Ophthalmology*. 2020 Dec; 258(12):2661-9.
2. **Neelam K, Cheung CM, Ohno-Matsui K, Lai TY, Wong TY.** Choroidal neovascularization in pathological myopia. *Prog Ret-in Eye Res* 2012; 31:495–525
3. **Soubrane G.** Choroidal neovascularization in pathologic myopia: recent developments in diagnosis and treatment. *Surv Ophthalmol* 2008;53:121–38.
4. **Y. Jia, S.T. Bailey, J.D. Wilson, et al.,** Quantitative optical coherence tomography angiography of choroidal neovascularization in age-related macular degeneration, *Ophthalmology* 121 (2014) 1435e1444.
5. **Spaide RF, Klancnik JM, Cooney MJ.** Retinal vascular layers imaged by fluorescein angiography and optical coherence tomography angiography. *JAMA Ophthalmol*. 2015; 133(1):45–50
6. **de Carlo TE, Bonini Filho MA, Chin AT, et al.** Spectral-domain optical coherence tomography angiography of choroidal neovascularization. *Ophthalmology* 2015; 122:1228–1238
7. **De Carlo TE, Romano A, Waheed NK, Duker JS.** A review of optical coherence tomography angiography (OCTA). *International Journal of Retina and Vitreous*. 2015 Dec 1; 1(1):5.

8. **Coscas GJ, Lupidi M, Coscas F, Cagini C, Souied EH.** Optical coherence tomography angiography versus traditional multimodal imaging in assessing the activity of exudative age-related macular degeneration: a new diagnostic challenge. *Retina*. 2015 Nov 1; 35(11):2219-28.
9. **Medhat Sakhsoekh M, M Youssef A, Ibrahim Abd El-Ghany AE.** Optical coherence tomography angiography changes in myopic choroidal neovascularization before and after intravitreal ranibizumab injection. *Al-Azhar Medical Journal*. 2021 Apr 1; 50(2):1169-86
10. **Bruyère E, Miere A, Cohen SY, Martiano D, Sikorav A, Popeanga A, Semoun O, Querques G, Souied EH.** Neovascularization secondary to high myopia imaged by optical coherence tomography angiography. *Retina*. 2017 Nov 1; 37(11):2095-101.
11. **Querques L, Giuffrè C, Corvi F, Zucchiatti I, Carnevali A, De Vitis LA, Querques G, Bandello F.** Optical coherence tomography angiography of myopic choroidal neovascularisation. *British Journal of Ophthalmology*. 2017 May 1; 101(5):609-15
12. **Mohsen TA, Kishk HM.** Optical coherence tomography angiography in the diagnosis of choroidal neovascular membrane. *Journal of the Egyptian Ophthalmological Society*. 2019 Jul 1; 112(3):108
13. **Mushiga Y, Minami S, Uchida A, Nagai N, Suzuki M, Kurihara T, Sonobe H, Ban N, Watanabe K, Shinoda H, Tsubota K.** Hyperreflective Material in Optical Coherence Tomography Images of Eyes with Myopic Choroidal Neovascularization May Affect the Visual Outcome. *Journal of Clinical Medicine*. 2020 Aug; 9(8):2394
14. **Li S, Sun L, Zhao X, Huang S, Luo X, Zhang A, Chen C, Wang Z, Liu C, Ding X.** Assessing the activity of myopic choroidal neovascularization: comparison between optical coherence tomography angiography and dye angiography. *Retina (Philadelphia, Pa.)*. 2020 Sep;40(9):1757-64.

- 15. Wang Y, Hu Z, Zhu T, Su Z, Fang X, Lin J, Chen Z, Su Z, Ye P, Ma J, Zhang L.** Optical Coherence Tomography Angiography-Based Quantitative Assessment of Morphologic Changes in Active Myopic Choroidal Neovascularization During Anti-vascular Endothelial Growth Factor Therapy. *Frontiers in Medicine*. 2021 May 7; 8:586.
- 16. Mao J, Shao Y, Liu C, Zhang C, Chen Y, Zhang Y, Xu Z, Shen L.** Optical coherence tomography angiography of myopic choroidal neovascularization treated by anti-VEGF therapy. *Research Square*.2019;1-13
- 17. Chhablani J, Deepa MJ, Tyagi M, Narayanan R, Kozak I.** Fluorescein angiography and optical coherence tomography in myopic choroidal neovascularization. *Eye* 2015 Apr; 29(4):519-24.
- 18. Mokwa NF, Ristau T, Keane PA, Kirchof B, Sadda SR, Liakopoulos S.** Grading of age-related macular degeneration: comparison between color fundus photography, fluorescein angiography, and spectral domain optical coherence tomography. *J Ophthalmol*. 2013; 385915.
- 19. Milani P, Massacesi A, Setaccioli M, Moschini S, Mantovani E, Ciaccia S, Bergamini F.** Sensitivity of fluorescein angiography alone or with SD-OCT for the diagnosis of myopic choroidal neovascularization. *Graefes Arch Clin Exp Ophthalmol* 2013; 251 (8): 1891-1900

Table (1): Spherical Equivalent

Spherical Equivalent	Patient (n=20)
Mean ± SD	-10.981 ± 2.866
Range	(- 6.5) – (-16)

n: number

Table (2): OCT finding

OCT finding		
	N	%
Subretinal fluid	10	50
Intraretinal fluid	3	15
SRF & IRF	7	35
Total	20	100

N: number

SRF: subretinal fluid

IRF :intraretinal fluid

Table (3): Vessel density (%) in patients

	Vessel density			Differences		Paired Test	
	Range	Mean	± SD	Mean	SD	t	P-value
VD in OCTA (%)	60.24 - 86.252	73.093	± 6.069	20.336	11.693	7.778	<0.001*
VD in early FFA (%)	36.234 - 76.378	52.757	± 11.167				

SD: standard deviation

**: statistically significant*

t: independent samples t-test

Table (4): Area of CNV (mm²) in patients

	Area of CNV			Differences		Paired Test	
	Range	Mean	± SD	Mean	SD	t	P-value
Area of CNV in OCTA (mm²)	0.3 - 4.2	1.411	± 1.119	-1.085	1.741	-2.786	0.012*
Area of CNV in early FFA(mm²)	0.29 - 7.79	2.496	± 2.027				

**: statistically significant*

SD: standard deviation.

t: independent samples t-test

Table (5): Correlation between BCVA and CNV site

	CNV site on FFA						T- Test	
	Subfoveal			Juxtafoveal				
	Mean	±	SD	Mean	±	SD	t	P-value
BCVA (decimal)	0.044	±	0.014	0.070	±	0.018	-3.525	0.002*

*: statistically significant SD: standard deviation. t: independent samples t-test

Case (1):

Female patient, 47 years old, with negative medical history. Complain: dropping of vision in her right eye.

Refraction is -9.00 D. Her BCVA was 0.05 decimal.

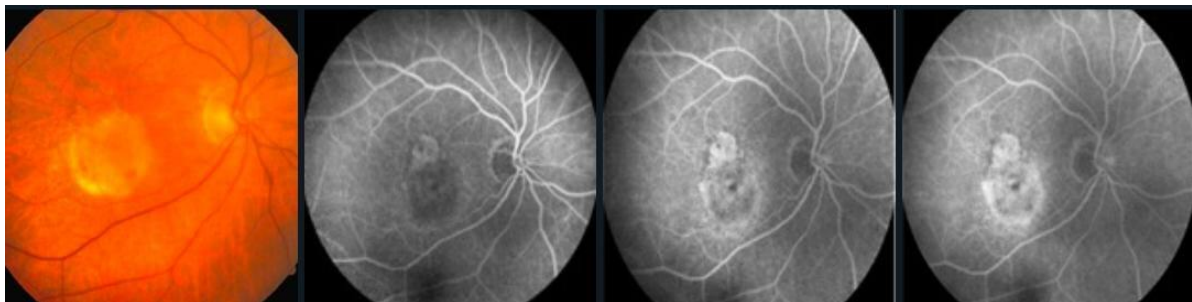


Figure 1: Color fundus photograph shows tessellated fundus in a high-myopic patient with macular lesion. FFA shows hyper fluorescent lesion and increasing hyperfluorescence along phases of angiogram associated with late dye leakage. Indicating the presence of an active subfoveal myopic CNV.

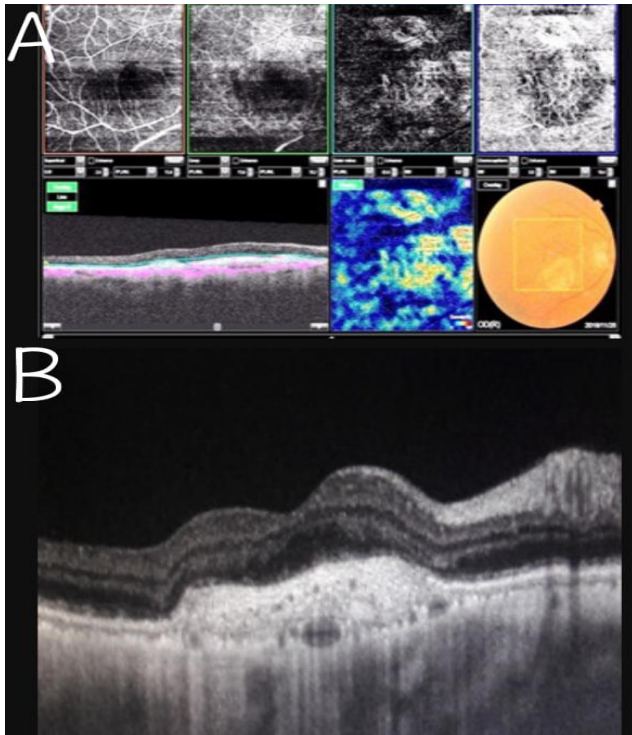


Figure 2: (A):OCTA(3x3mm) showing sharply defined, dense organized interlacing neovascular network in Outer retina. Correspond to active myopic type II CNV.

(B): Spectral-domain OCT show a hyper-reflective lesion with subretinal & intraretinal fluid.Suggestive of an active typeII CNV.

Case (2):

Male myopic patient, 55 years old, with history of hypertension since 7 years.Complain: dropping of vision in his left eye.Refraction - 6.50 D. BCVA was 0.085 decimal.

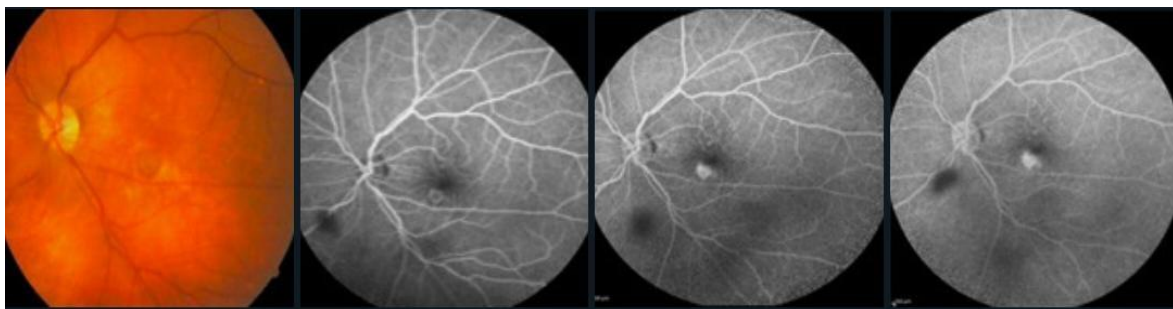


Figure 3: Color fundus photograph shows macular lesion. FFA shows early hyperfluorescence in early phase with minimal leakage in the late phase. Indicating the presence of an active myopic juxtafoveal CNV.

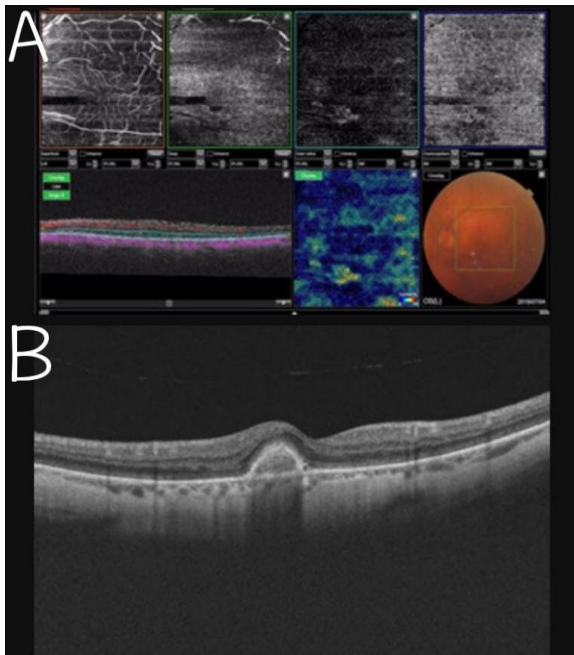


Figure 4:(A): OCTA(3x3mm)showing sharply defined, small,disorganized vascular loop showing irregular blood flow and a small tree bud shape. Correspond to active typeII CNV.

(B): OCT Spectral-domain show a hyper-reflective lesion with a small amount of intraretinal fluid. Suggestive of active typeII CNV.