

# **Glaucoma: Diagnosis and Treatment**

## **Abstract**

Background: In the United States, glaucoma is the second most prevalent cause of official blindness. Open-angle glaucoma is an asymptomatic, progressive optic neuropathy marked by increased optic disc cupping and vision loss. Patients over the age of 40, whites over the age of 65, and those with a family history of glaucoma or a personal history of diabetes or acute myopia are all at high risk for open glaucoma. Although high intraocular pressure is a major and variable risk factor for open glaucoma, it is not a diagnostic factor. Normal intraocular pressure is present in some glaucoma patients (i.e., normal pressure glaucoma), and most patients with high intraocular pressure do not have glaucoma (i.e., suspected glaucoma). Physicians who treat glaucoma patients do not recommend using a conventional measurement of intraocular pressure. Adults with open-angle glaucoma are commonly diagnosed during routine eye exams. Ophthalmologists and ophthalmologists collaborate on the ultimate diagnosis and therapy. The basic foundation for the diagnosis and therapy of glaucoma is the systemic area of visual acuity (perimetry). Beta-blockers are commonly given as eye drops in the form of intravenous or prostaglandin analog drops, and they are frequently the first treatment to lower intraocular pressure. Laser therapy and surgery are often reserved for individuals who have failed to respond to other treatments. Open-angle glaucoma can cause irreparable visual loss if not treated.

Conclusion: Glaucoma is a disease that poses difficulty to many people. Many kinds of glaucoma have core pathogenesis that we don't fully understand.

*Keywords: Glaucoma, Chronic disease, Intraocular pressure, Primary Angle Closure Glaucoma.*

## **Introduction**

Glaucoma is a collection of eye diseases that cause damage to the optic nerve, which is necessary for clear vision. Extremely high pressure in your eye usually causes this damage. One of the primary causes of blindness in persons over the age of 60 is glaucoma. It can strike anyone at any age, but it is more frequent among adults. The majority of glaucoma types have no warning signals. The effect is so subtle that you won't notice a shift in your eyesight until the crisis reaches its peak. Because glaucoma does not cause repeated vision loss, it is critical to have regular eye exams, which should include measures of your eye pressure, to receive an early diagnosis and treatment. Vision loss can be decreased or avoided if glaucoma is discovered early. You will almost always need treatment for the rest of your life if you have this illness (1).

## **Causes and Risk Factors**

The injury to the optic nerve causes glaucoma. Blind spots appear in your eyes as these sensors fail. This form of nerve injury is frequently accompanied by increased ocular pressure

for reasons that doctors do not completely understand. The production of fluid (aqueous humor) moving into your eye causes high ocular pressure. The trabecular meshwork at the intersection of the iris and the cornea is where this internal fluid is normally secreted. Fluid cannot go beyond its normal range if it is utilized excessively or if the drainage mechanism is not working properly, and ocular pressure rises. Glaucoma tends to run in families. Scientists have discovered genes linked to excessive eye pressure and optic nerve injury in some people. High intraocular pressure (IOP), over 60, opacity, Asian or Spanish, having a family history of glaucoma, certain health problems, such as diabetes, heart disease, high blood pressure, and sickle cell anemia, the thin cornea in the middle, too much or too far vision, eye injuries or certain types of eye surgery, and corticosteroids, especially eyed, are all risk factors (2).

### **Pathophysiology**

The processes that cause glaucoma are yet unknown. In many clinical circumstances, an increase in IOP occurs without pain, which can cause severe damage to the optic nerve and loss of vision. Glaucoma with theoretical mechanical strength (in the juxtacanalicular network) is a type of glaucoma that is prescribed. Collagen changes in the trabecular meshwork (TM), endothelial cell dysfunction in the TM, decreased membrane stiffness, glycosaminoglycan deposition, decreased intertrabecular gaps, and/or Schlemm's duct collapse are all possibilities. Progressive IOP can cause optic nerve injury, such as primary open-angle glaucoma (POAG), according to experimental and clinical investigations, implying that IOP plays a role. The role of optic nerve perfusion and vascular risk factors may be crucial. The extracellular matrix of the lamina cribrosa, as well as the blood supply to the optic nerve and the metabolism of axonal or ganglion cells, may all have a role. This is especially important for a small group of people with chronic low-voltage glaucoma despite an IOP below 21 mm Hg (3).

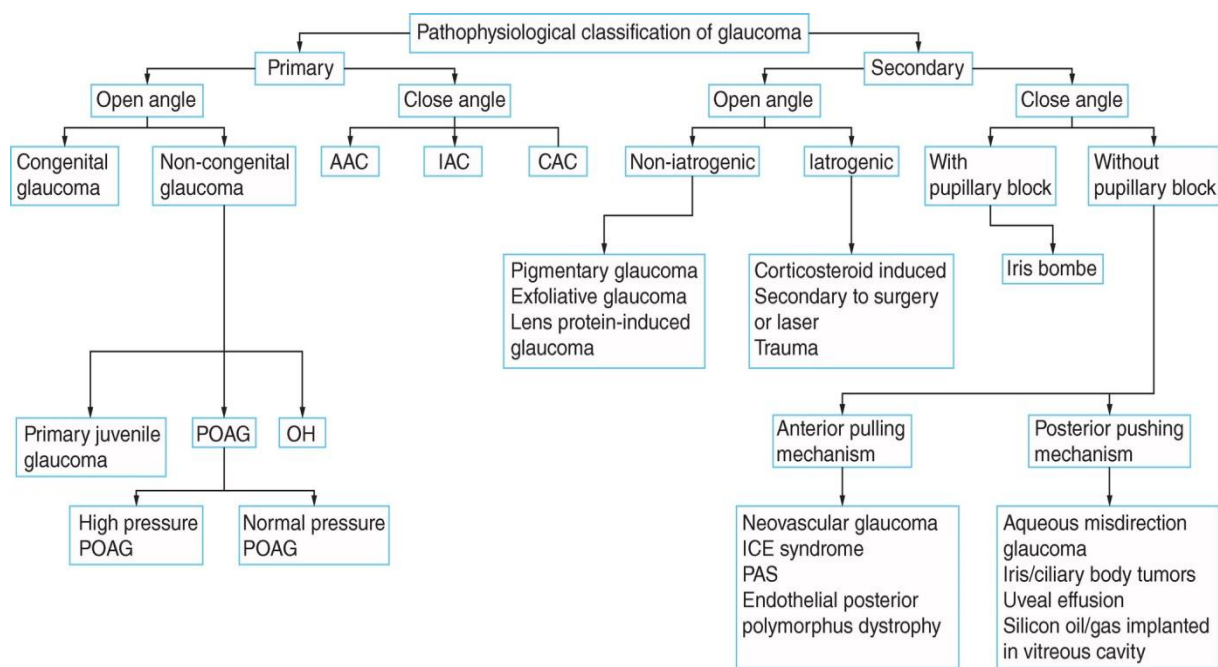
Optic nerve injury occurs at different rates in different people. It is dependent on the level of IOP, in addition to other risk factors. Age, race, family history, and eye history are only a few of the historical and demographic characteristics that have been linked to the condition. The sleeping environment is also important; typical sleeping positions have been linked to greater IOP levels in people with pigmentation. Patient observations and eventual glaucoma diagnosis could be the result of birth abnormalities, particularly optic nerve or concomitant vascular insufficiency. There must be a sense of continuity (4).

### **Classification**

The following are several forms of glaucoma: The most prevalent type of glaucoma is angle-closure glaucoma. The trabecular meshwork is partially obstructed, yet the drainage angle formed by the cornea and iris remains open. The pressure on your eyes will progressively build as a result of this. The optic nerve is harmed by this pressure. It happens at such a leisurely pace that you may lose sight of the issue before you realize it. Angle-closure glaucoma occurs when the iris ruptures further, reducing or blocking the drainage angle formed by the cornea and iris. As a result, the fluid in the eye cannot flow, and the pressure in the eye rises. Angle-closure glaucoma is more common in patients who have a small drainage angle. Angle-closure glaucoma can develop suddenly (acute angle-closure glaucoma) or

gradually (phased angle-closure glaucoma) (chronic angle-closure glaucoma). Glaucoma with acute angle loss is a life-threatening condition. Normal-tension glaucoma occurs when the optic nerve is injured despite the intraocular pressure being within normal limits. No one knows why this is the case. You may have damaged optic nerves or a lack of blood circulation to the optic nerves. Atherosclerosis, the accumulation of fat (plaques) in the arteries, or other impeding blood flow can cause this limited blood flow (5).

Glaucoma in children: Glaucoma can affect infants and children. It might appear at birth or within the first few years of life. Fluid retention or poor health might cause damage to the optic nerve. Pigment granules in the iris form in the waterways of the eye in pigmentary glaucoma, decreasing or restricting fluid entrance into the eye. Race can shift pigment granules, putting them in the trabecular meshwork and occasionally putting extra pressure on them (figure 1) (6).



**Figure 1 Classification of Glaucoma (6)**

### Signs and Symptoms

The symptoms of glaucoma differ based on the type of glaucoma you have. If you observe any signs of glaucoma, you should consult a doctor very once. It's also crucial to have your eyes checked regularly, as open-angle glaucoma normally doesn't cause symptoms until the damage has already been done. Open-angle glaucoma symptoms include: Symptoms of open-angle glaucoma do not appear until you have lost your vision. Vision loss normally starts on the edges of your field of vision, progresses to tunnel vision, and then extends to the center. Angle or acute glaucoma symptoms include: Angle-closure glaucoma is characterized by a rapid onset of symptoms. Sometimes any of these symptoms can be very serious: abdominal pain (vagus nerve stimulation), eye pain, halos visible near lights, headache associated with

eye symptoms, loss of vision or visual disturbances, nausea or absence of vomiting, redness, pain in the eyes (bloody eyes) (7).

**Congenital Glaucoma Symptoms:** Congenital glaucoma is present at birth, however, symptoms usually do not develop for several months. The following are symptoms of secondary glaucoma: clear corner hair loss (front of the eye), increased sensitivity to light, redness, sore eyes (bleeding from the eyes), swelling of one or both eyes, and general secondary glaucoma symptoms: Open eyes are a symptom of secondary glaucoma. Depending on the cause, the closure of angle glaucoma: certain drugs, medical procedures, or other medical problems might cause secondary glaucoma. Symptoms of a serious ailment include: Acute narrow-angle glaucoma is a dangerous disorder that requires rapid medical attention. If you have any of the following dangerous symptoms: blurred vision, eye pain, visual halos, headache, loss of vision, nausea with or without vomiting, call your doctor right once (8).

### **Complications**

Glaucoma does not have any deadly effects. Glaucoma, on the other hand, if left untreated, can cause major vision issues, even blindness. By seeking quick medical attention and adhering to your unique treatment and care plan, you can help lower the chance of serious problems. Chronic glaucoma (vision loss), moderate or partial (partial) vision loss and vision loss or blurred visions are all glaucoma complications. Different symptoms are possible. Adults suffering from glaucoma: Sensitivity to light, hazy cornea, huge eye (disease can be detected in the photo before discovery), acute stress, and vision loss are all symptoms of pediatric glaucoma. Some youngsters may be affected by this system in addition to eye-related problems. Symptoms include restlessness, a dislike for food, and sometimes vomiting. These symptoms are linked to angle closure and can be alleviated by lowering ocular pressure. Symptoms of congenital glaucoma (from birth) can appear as soon as the baby is 1 month old (9).

Blinking, sorrow, and fear of light are all chronic symptoms of congenital glaucoma. Congenital glaucoma develops when the eye's fluid supply is inadequate and requires treatment. traumatic glaucoma, traumatic glaucoma, traumatic glaucoma It can affect anyone, but it is most commonly associated with sports. Blunt trauma can also cause eye hemorrhage if the ball or bat hits someone in the eye. Plasma and other remnants can obstruct the eye's fluid system, raising intraocular pressure. Glaucoma can develop slowly after an eye injury. At first, the pressure may be minimal, but when the wound closes, it swells and the pressure rises, resulting in glaucoma. Trauma can cause a rupture in the gap between the iris and the cornea, a tissue they are familiar with, resulting in a reduction in glaucoma and, eventually, glaucoma. Acute glaucoma can develop after 10 to 20 years or more if an eye injury is not reported to an ophthalmologist. Symptoms normally do not develop until vision is lost if medication is given too late. Bra discomfort, nausea, vomiting, and sudden loss of vision are all symptoms to be aware of. These issues can appear right after an accident or years afterward. The presence of symptoms indicates an increase in intraocular pressure, which needs rapid medical intervention (10).

## Diagnosis

The eyes should be examined regularly. At the age of 40, you should get a basic eye examination. In recent years, the first signs of eye disease and alterations in vision may have appeared. According to the doctor, patients should have follow-up testing based on the findings of the initial exams. If they have glaucoma risk factors such as diabetes, high blood pressure, or a family history of glaucoma, consult an eye doctor right away to find out how often they should examine their eyes (11).

## Tonometry

Tonometry is a test that determines the pressure inside the eye. To identify the eye during tonometry, ocular drops are used. The internal pressure in the eye is then measured using a tonometer by the doctor or ophthalmologist. A tiny gadget or an air heater is used to apply light pressure to the eye. The normal range of pressure is 12-22 mmHg. ("mmHg." Blood pressure is usually higher than 20 mmHg in glaucoma patients. At 12-22 mmHg, however, some people can develop glaucoma. The amount of pressure in the eyes varies from person to person (figure 2) (12).

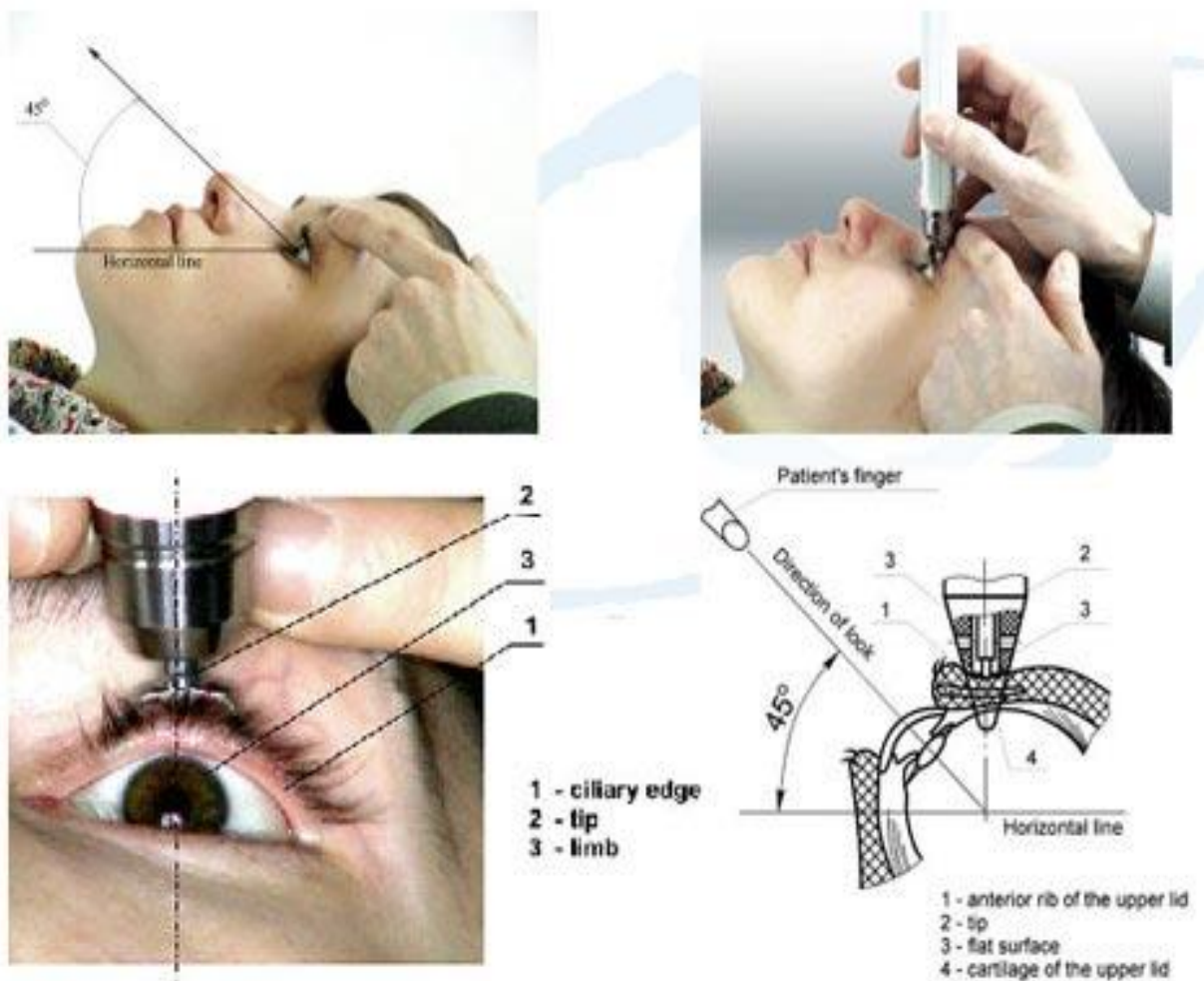
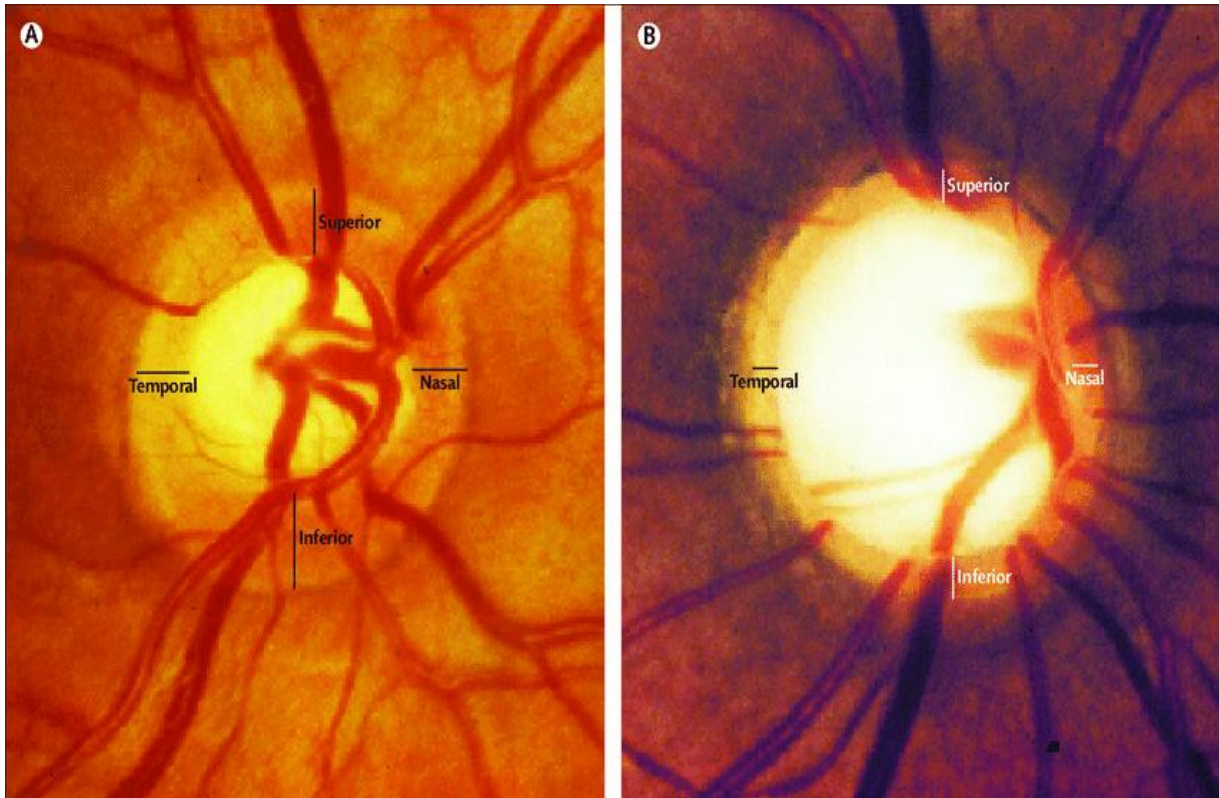


Figure 2 Tonometry (12)

## Ophthalmoscopy

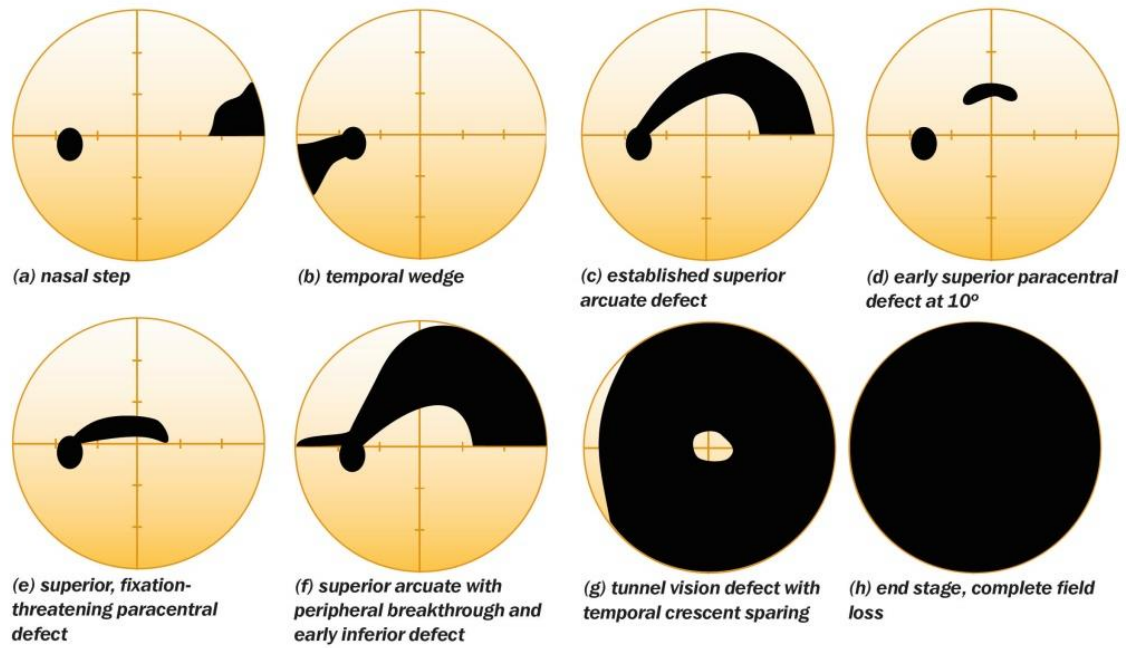
This diagnostic process allows the doctor to check for glaucoma damage in the optic nerve. The doctor will use eye drops to widen the reader so that he or she may assess the size and color of the optic nerve. The doctor will then brighten and enlarge the optic nerve with a tiny light instrument. If the intraocular pressure (IOP) is high or the optic nerve appears abnormal, the doctor may order one or both of the following glaucoma tests: perimetry and gonioscopy (figure 3) (13).



**Figure 3** The right eye was used to take ophthalmoscopic pictures of healthy optic discs and glaucomatous optic discs. (A) The neuroretinal rim of a healthy optic disc has a normal form, with the subcutaneous area being the widest, followed by the upper and lower nasal regions, and lastly the temporal region. (B) The neuroretinal margin of a glaucomatous optic disc is surprisingly thinner than in a healthy optic disc, and the optic cup is wider and deeper (13)

## Perimetry

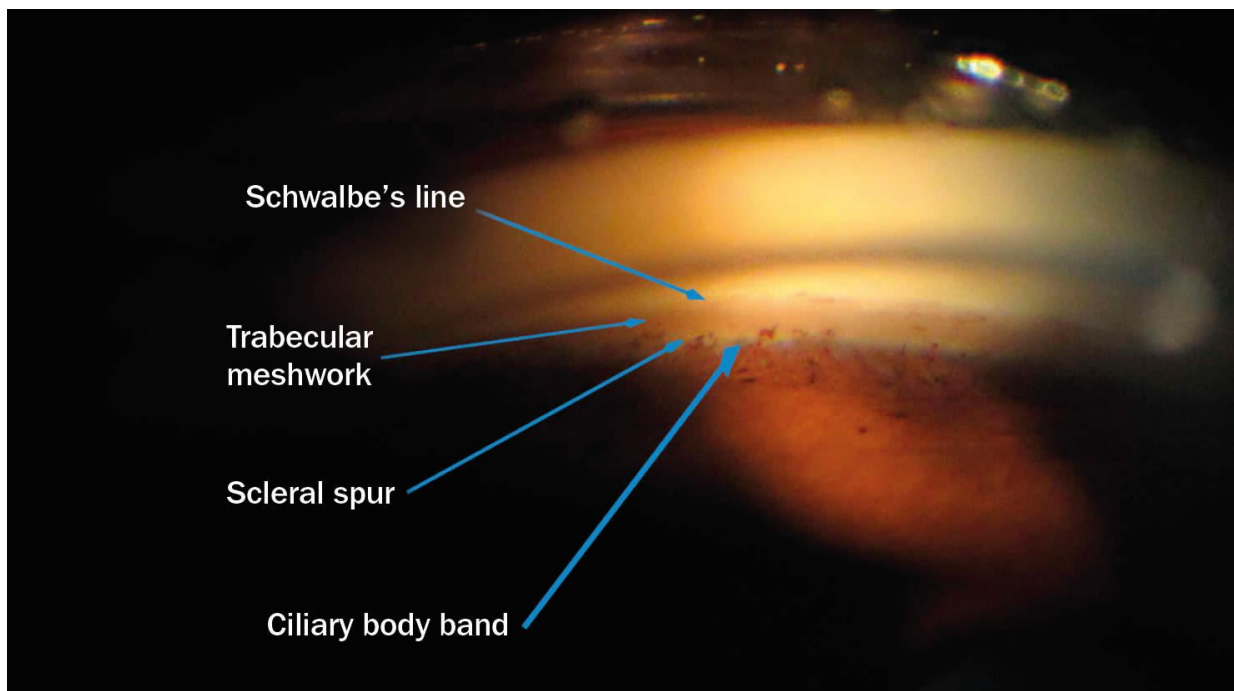
A visual field test called perimetry maps the full visual field. This test will assist the doctor in determining whether or not patients have glaucoma. Bright dots occur repeatedly in different locations of the side view during this exam and are urged to look forward to them. It aids in the creation of a mental "map." Don't be concerned if the blind spot or the light surrounding it is delayed. This is completely natural and does not indicate that the vision is affected. Relax and try to be as accurate as possible during the test. Visual aids are commonly used once or twice a year after a glaucoma diagnosis to monitor for vision changes (figure 4) (14).



**Figure 4 Perimetry (14)**

### Gonioscopy

This test determines if the angle at which the iris cornea meets the cornea is open and wide or narrow and closed. Eye drops are used to numb the eye during the test. The contact lens is softly put over the eye with a hand-held device. This contact lens has a mirror that allows the doctor to see if the angle between the iris and the cornea is closed and closed (an indication of acute glaucoma) or wide and open (a sign of chronic glaucoma) (figure 5) (15).



**Figure 5 Gonioscopy (15)**

## Pachymetry

Pachymetry is a painless procedure for determining the thickness of the cornea, the transparent window in front of the eyes. The thickness of the cornea is measured using a pachymeter, which is lightly placed in front of you. Because the size of the cornea can affect the study of intraocular pressure, pachymetry is important for diagnosis. The doctor will be able to better understand the IOP readings and establish the best treatment plan for patients if they continue to do so. The process to evaluate both eyes takes only 1 minute (figure 6) (16).

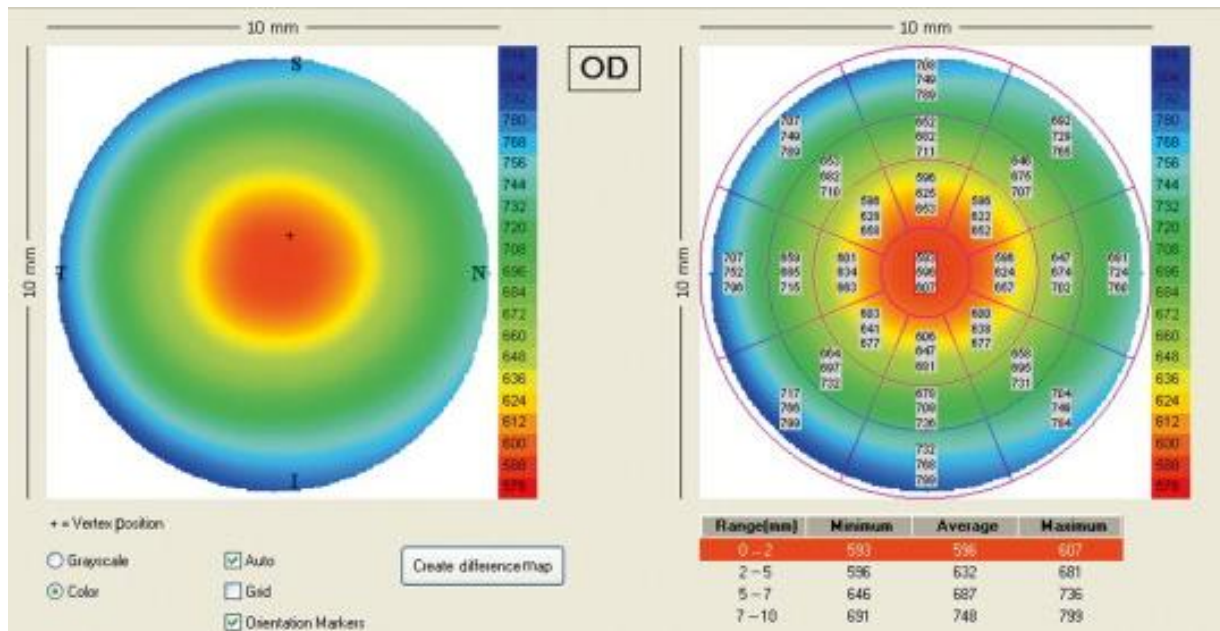


Figure 6 Pachymetry (16)

## Treatment

Glaucoma causes irreparable damage. Regular treatment and testing, especially if patients have an early infection, can help postpone or avoid visual loss. The intraocular pressure is reduced to treat glaucoma (intraocular pressure). Eye drops, oral drugs, laser treatment, surgery, or a combination of these may be recommended by the doctor, depending on the condition. Glaucoma treatment typically starts with eye medications recommended by a doctor. This aids in the reduction of intraocular pressure by increasing the flow of fluid out of the eye or decreasing the amount of fluid produced by the eye. Low intraocular pressure may necessitate the use of multiple eye drops. The following eye drops are available on prescription. Prostaglandins: These lower intraocular pressure by increasing the flow of water from the eye (aqueous humor). Latnoprost, travoprost, tefluprost, bimatoprost, and letanoprostin bonodo are all drugs in this group. Possible side effects include mild redness and itching of the eyes, darkening of the iris, darkening of the eyelids or eyelid skin, and hazy eyes. This range of drugs is used once daily (17).

Beta-blockers: This lowers eye pressure by reducing the production of water in the eye (intraocular pressure). Timolol and betaxolol are two examples. Shortness of breath, low heart

rate, low blood pressure, weakness, and malaise are all possible side effects. Depending on your situation, this kind of medication may be administered once or twice daily. Agonists of the alpha-adrenergic system: These inhibit the generation of aqueous humor while increasing the discharge of water from the eyes. Applaclonidine (iopidine) and brimonidine are two examples (Alphagan P, qoliana). Arrhythmia, elevated blood pressure, malaise, redness, itching, and swelling of the eyes and mouth are all possible adverse effects. This group of drugs is normally recommended twice daily, but it can also be taken three times a day. Organic anhydrase inhibitors: These medications stop the eye from producing water. Dorzolamide (Trusopt) and brinzolamide are two examples (Azopt). Iron taste, pollakiuria, and tingling fingers and toes are all possible adverse effects. This group of drugs is normally recommended twice daily, but it can also be taken three times a day. Rho-kinase inhibitors: This medication lowers intraocular pressure by inhibiting the Rho-kinase enzymes that cause water retention. Netarsudil (Rhopressa) is a once-daily medication available as netarsudil (Rhopressa). Redness in the eyes, irritation in the eyes, and corneal formation are all possible adverse effects (18).

Agents that accelerate the flow of fluid through your eye are known as miotic or cholinergic agents. Isopto carpine is a good example. Headache, blurred vision, tiny pupils, possible or blurred vision, and blurred vision are some of the side effects. This family of medications is often prescribed four times per day. These medications are no longer advised due to the potential for negative effects and the requirement for daily use. Patients may suffer side effects that have nothing to do with their eyesight since some eye drops reach their circulation. To minimize absorption, patients should close their eyes for one to two minutes after injecting. By gently pushing the corner of the eye near the nose, patients can stop the crying canal for a minute or two. Remove any unused drops from the brows. If patients have been given many eye drops or need to utilize artificial tears, they should wait at least five minutes between each type of drop. If the eye drop does not reduce the eye pressure to the desired level, the doctor may prescribe oral drugs, which are usually carbonic anhydride inhibitors. Frequent urination, tingling fingers and toes, sadness, upset stomach, and kidney stones are all possible adverse effects (18).

Surgery and other treatments: Laser therapy and different surgical procedures are two more therapeutic choices. The following treatments are designed to increase fluid outflow within the eye, hence lowering pressure (19):

### **Laser therapy**

For open glaucoma, a type of laser trabeculoplasty: This procedure is carried out in the doctor's office. A tiny laser is used by the doctor to open closed channels in the trabecular meshwork. It may take many weeks for the procedure's effects to become apparent (19).

### **Filtering surgery**

A trabeculectomy is a surgical treatment that involves opening the white area of the eye (the sclera) and removing part of the trabecular meshwork (figure 7) (19).

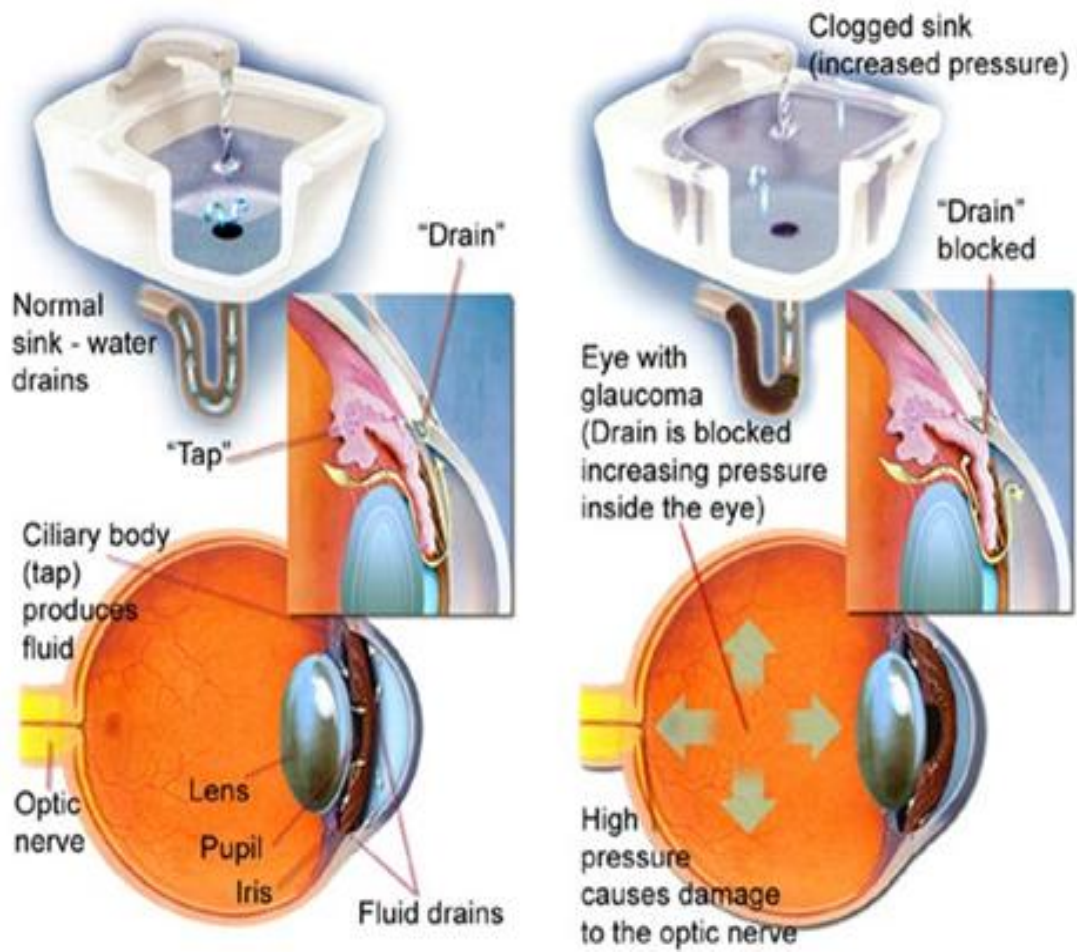


Figure 7 Filtering Surgery for Glaucoma (19)

### Drainage tubes

A tiny tube is inserted into the eye by the surgeon to drain excess fluid and lower intraocular pressure (figure 8) (20).

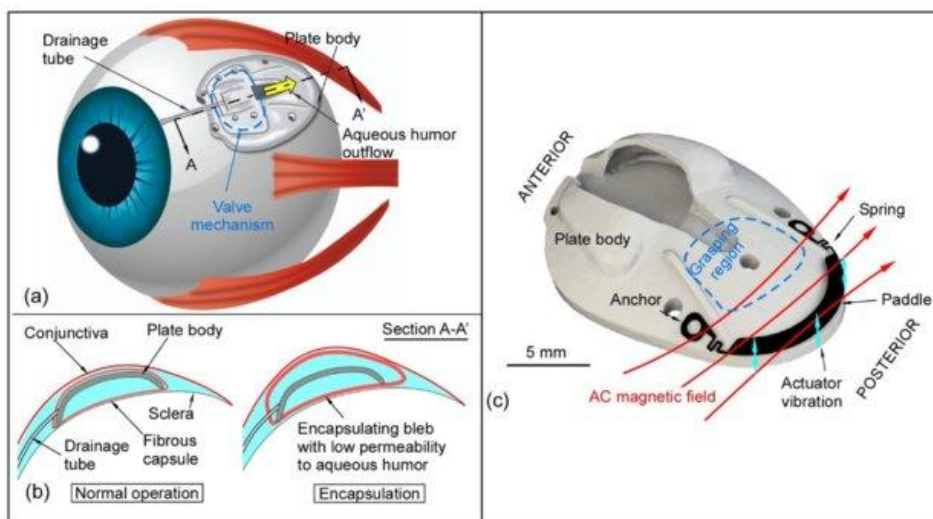
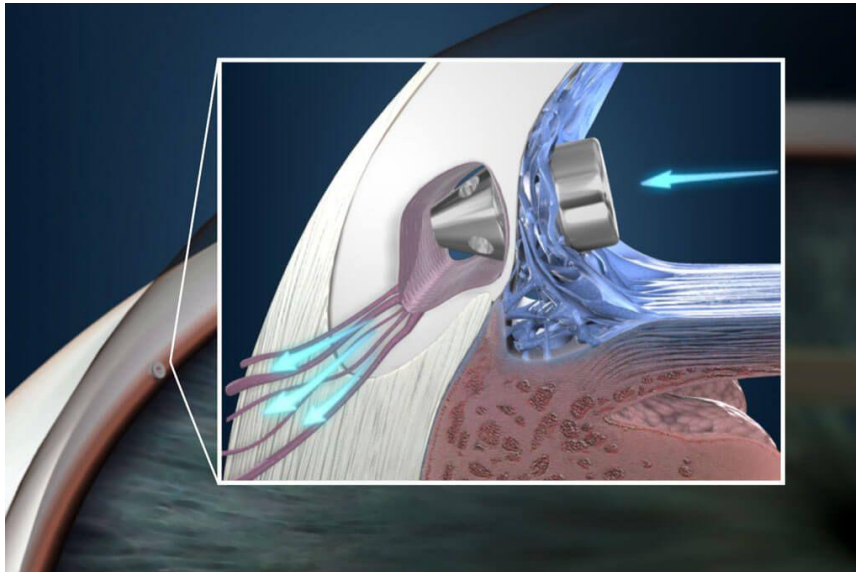


Figure 8 Drainage tubes (20)

## **Minimally invasive glaucoma surgery (MIGS)**

A MIGS procedure may be recommended by your doctor to assist lower the intraocular pressure. Compared to trabeculectomy or implantation, these techniques usually require less care and danger right after surgery. They're frequently used in conjunction with cataract surgery. There are several MIGS techniques to choose from, and the doctor will discuss which one is ideal for patients. Following the operation, patients will need to see their doctor for follow-up exams. Finally, if the eye pressure rises or other abnormalities in the eye occur, patients may require additional operations (figure 9) (21).



**Figure 9 Minimally invasive glaucoma surgery (MIGS) (21)**

Acute angle-closure glaucoma treatment: Glaucoma with acute angle-closure is a medical emergency. If patients have been diagnosed with this illness, they will require therapy right away to relieve the pressure in the eye. Medication and laser or other surgical procedures are frequently required. Laser peripheral iridotomy is a technique in which a doctor uses a laser to produce a small hole in the iris. This permits the fluid (aqueous humor) to circulate freely, relieving ocular pressure (21).

## **Prevention**

These self-care techniques can help patients detect glaucoma early on, which is critical for preventing or slowing vision loss. Get their eyes checked regularly. Regular general eye exams can help diagnose glaucoma in its early stages before it causes major damage. A comprehensive eye exam is recommended by the American Academy of Ophthalmology every five to ten years if they are under 40; every two to four years if they are 40 to 54 years old; every one to three years if they are 55 to 64 years old; and every two years if they are over 65. They will need to be examined more frequently if they are at risk for glaucoma. Request that the doctor suggest a testing regimen that is appropriate for them. They should be aware of their family's eye health history. Glaucoma is a disease that runs in families, so if they are at high risk, they should have regular eye exams. Exercise in a safe manner: By

lowering ocular pressure, regular, moderate exercise can help prevent glaucoma. They should consult the doctor about the best workout program for them. They should use eye drops daily. Glaucoma is caused by excessive pressure in the eye. Even if they don't have any symptoms, they should take eye drops daily as advised by their doctor. Protect their eyes by wearing sunglasses. Glaucoma is caused by severe eye damage. When utilizing powerful equipment or playing high-speed racing games on the court, the patient should wear eye protection (21).

## **Discussion**

Glaucoma refers to a group of disorders that cause damage to the optic nerve, usually as a result of increased eye pressure that causes fluid (aqueous humor) to drain from the eye. With normal eye anatomy (open-angle glaucoma) or structural issues in the fluid, there may be limited water movement (angle-closure glaucoma). Glaucoma damage to the optic nerve often affects your lateral vision, leading to tunnel vision, which then slows down to include your central vision. Open-angle or chronic glaucoma is the most prevalent type of glaucoma, and it is caused by a steady build-up of pressure in the eye over time. Normal-tension glaucoma is an uncommon type of open-angle glaucoma in which the optic nerve is damaged despite normal eye pressure. Narrow-angle glaucoma, also known as acute glaucoma, is a kind of glaucoma in which fluid builds up and eye pressure rises suddenly. Glaucoma may be present at birth (congenital glaucoma) or maybe the result of medications, medical conditions, or surgery (secondary glaucoma) (22).

Although anybody can develop glaucoma, it is most typically diagnosed in persons over 60. Furthermore, African Americans are five times more likely than other individuals to get glaucoma, which can strike at any age. Finally, persons with a glaucoma family history are more prone to develop the disease. Glaucoma usually advances slowly and without symptoms until it causes considerable harm. Regular eye exams are therefore essential, particularly if they are Native American or have a family history of glaucoma. Glaucoma can be slowed or stopped with prompt treatment. Glaucoma can cause lifelong vision loss or blindness if left untreated. Glaucoma is not harmful to one's health, but it can cause major vision difficulties. In the majority of cases, considerable losses occur over time. However, angular or acute closed glaucoma can occur suddenly and cause permanent damage to the eye or loss of vision if not treated immediately (22).

## **Conclusion**

Many disorders are made more difficult by glaucoma. Many kinds of glaucoma have core pathogenesis that we don't fully understand. Recent developments in medical treatment, laser and incision surgery, and imaging of the optic/retinal nerve fiber layers have altered the practice and pattern of procedures. Many obstacles remain, including properly identifying people with glaucoma, ensuring appropriate long-term follow-up and therapy after diagnosis, and developing safe, effective, and widely used medicines. Given the changing demographics and the current economic climate, it will be critical to promote and develop glaucoma specialists and medical professionals. While there are many challenges, there are also many opportunities. It will allow patients with glaucoma to gain perspective by cultivating a creative and collaborative atmosphere and creating diagnostic and therapeutic approaches.

## Conflict of Interest

There is nothing to disclose

## References

- 1) Andreoli CM, Miller JW. Anti-vascular endothelial growth factor therapy for ocular neovascular disease. *Curr Opin Ophthalmol*. 2007 Nov. 18(6):502-8.
- 2) Cheng Y, Liu XH, Shen X, Zhong YS. Ahmed valve implantation for neovascular glaucoma after 23-gauge vitrectomy in eyes with proliferative diabetic retinopathy. *Int J Ophthalmol*. 2013. 6(3):316-20.
- 3) Costa VP, Jimenez-Roman J, Carrasco FG, Lupinacci A, Harris A. Twenty-four-hour ocular perfusion pressure in primary open-angle glaucoma. *Br J Ophthalmol*. 2010 Oct. 94(10):1291-4.
- 4) Czudowska MA, Ramdas WD, Wolfs RC, Hofman A, De Jong PT, Vingerling JR, et al. Incidence of Glaucomatous Visual Field Loss: A Ten-Year Follow-up from the Rotterdam Study. *Ophthalmology*. 2010 Sep. 117(9):1705-12.
- 5) De Moraes CG, Juthani VJ, Liebmann JM, Teng CC, Tello C, Susanna R Jr, et al. Risk factors for visual field progression in treated glaucoma. *Arch Ophthalmol*. 2011 May. 129(5):562-8.
- 6) Ehlers JP, Spirn MJ, Lam A, Sivalingam A, Samuel MA, Tasman W. Combination intravitreal bevacizumab/panretinal photocoagulation versus panretinal photocoagulation alone in the treatment of neovascular glaucoma. *Retina*. 2008 May. 28(5):696-702.
- 7) Eid TM, Radwan A, el-Manawy W, el-Hawary I. Intravitreal bevacizumab and aqueous shunting surgery for neovascular glaucoma: safety and efficacy. *Can J Ophthalmol*. 2009 Aug. 44(4):451-6.
- 8) Falavarjani KG, Modarres M, Nazari H. Therapeutic effect of bevacizumab injected into the silicone oil in eyes with neovascular glaucoma after vitrectomy for advanced diabetic retinopathy. *Eye (Lond)*. 2009 May 1.
- 9) Gupta V, Jha R, Rao A, Kong G, Sihota R. The effect of different doses of intracameral bevacizumab on surgical outcomes of trabeculectomy for neovascular glaucoma. *Eur J Ophthalmol*. 2009 May-Jun. 19(3):435-41.
- 10) Hasanreisoglu M, Weinberger D, Mimouni K, Luski M, Bourla D, Kramer M, et al. Intravitreal bevacizumab as an adjunct treatment for neovascular glaucoma. *Eur J Ophthalmol*. 2009 Jul-Aug. 19(4):607-12.
- 11) Higashide T, Murotani E, Saito Y, Ohkubo S, Sugiyama K. Adverse events associated with intraocular injections of bevacizumab in eyes with neovascular glaucoma. *Graefes Arch Clin Exp Ophthalmol*. 2012 Apr. 250(4):603-10.
- 12) Higashide T, Ohkubo S, Sugiyama K. Long-Term Outcomes and Prognostic Factors of Trabeculectomy following Intraocular Bevacizumab Injection for Neovascular Glaucoma. *PLoS One*. 2015. 10 (8):e0135766.
- 13) Ishibashi S, Tawara A, Sohma R, Kubota T, Toh N. Angiographic changes in iris and iridocorneal angle neovascularization after intravitreal bevacizumab injection. *Arch Ophthalmol*. 2010 Dec. 128(12):1539-45.

- 14) Kotecha A, Spratt A, Ogunbowale L, et al. Intravitreal bevacizumab in refractory neovascular glaucoma: a prospective, observational case series. *Arch Ophthalmol.* 2011 Feb. 129(2):145-50.
- 15) Lee SJ, Lee JJ, Kim SY, Kim SD. Intravitreal bevacizumab (Avastin) treatment of neovascular glaucoma in ocular ischemic syndrome. *Korean J Ophthalmol.* 2009 Jun. 23(2):132-4.
- 16) Li XJ, Yang XP, Li QM, Wang YY, Lyu XB. Ranibizumab Plus Combined Surgery for Treatment of Neovascular Glaucoma with Vitreous Hemorrhage. *Chin Med J (Engl).* 2015 Aug 5. 128 (15):2078-83.
- 17) Luke J, Luke M, Grisanti S. [Antiangiogenic treatment for neovascular glaucoma and after filtering surgery]. *Ophthalmologe.* 2009 May. 106(5):407-12.
- 18) Lüke J, Nassar K, Lüke M, Grisanti S. Ranibizumab as adjuvant in the treatment of rubeosis iridis and neovascular glaucoma-results from a prospective interventional case series. *Graefes Arch Clin Exp Ophthalmol.* 2013 Oct. 251(10):2403-13.
- 19) Martinez-Carpio PA, Bonafonte-Marquez E, Heredia-Garcia CD, Bonafonte-Royo S. [Efficacy and safety of intravitreal injection of bevacizumab in the treatment of neovascular glaucoma: systematic review]. *Arch Soc Esp Oftalmol.* 2008 Oct. 83(10):579-88.
- 20) Rao HL, Kumar AU, Babu JG, Senthil S, Garudadri CS. Relationship between Severity of Visual Field Loss at Presentation and Rate of Visual Field Progression in Glaucoma. *Ophthalmology.* 2011 Feb. 118(2):249-53.
- 21) Takihara Y, Inatani M, Fukushima M, Iwao K, Iwao M, Tanihara H. Trabeculectomy with mitomycin C for neovascular glaucoma: prognostic factors for surgical failure. *Am J Ophthalmol.* 2009 May. 147(5):912-8, 918.e1.
- 22) Wakabayashi T, Oshima Y, Sakaguchi H, Ikuno Y, Miki A, Gomi F, et al. Intravitreal bevacizumab to treat iris neovascularization and neovascular glaucoma secondary to ischemic retinal diseases in 41 consecutive cases. *Ophthalmology.* 2008 Sep. 115(9):1571-1580.