

# Biliary Fistula: An analysis of two case reports with review of literature.

Dubey R.D., Singh S., Chalotra V., Gupta V.

**Corresponding author**

Dr Rishab Dev Dubey

Department of Surgery, Guru Gobind Singh Medical College and Hospital, Faridkot  
Punjab, India

## **Abstract**

Biliary fistulas are entities whose etiology can be diverse ranging from iatrogenic to infectious. The site of origin of fistula can be from small biliary radicals to larger biliary ducts. Surgical treatment of fistulas are often difficult owing to small size of radicals and sectoral biliary ducts and many a time the location of the injury is high up in the hilum.

**Aim:** The present case studies of two patients aim to discuss the management of persistent biliary fistula resulting from infectious liver disease.

**Presentations of case:** The two cases discussed pertain to biliary fistula. In case A the fistulous tract developed post operatively after drainage of amebic liver abscess. In case B bile stained cystic fluid was noted intraoperatively.

**Discussion:** Biliary fistulas are described as persistent biliary leakage for more than 10 days. They can arise due to injury to bile duct during cholecystectomy, hepatic trauma, hydatid cyst or liver abscess. Endoscopic sphincterotomy with stenting allowed the defect to heal at a hastened pace.

**Conclusion:** Despite a varied etiology of biliary fistulae, diversion of biliary flow from fistulous site via endoscopic procedure is a safe and effective method.

## **Key Words**

Biliary fistulas, Hydatid cyst, Amebic Liver Abscess

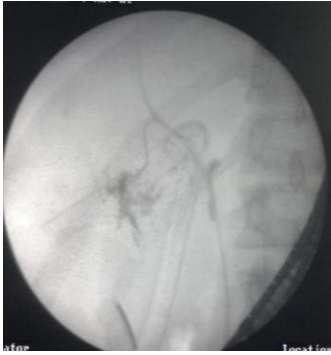## **Introduction**

Biliary fistulas are a major cause of morbidity in patients. These fistulas can be classified as either primary or secondary biliary fistulas. Primary biliary fistulas arise due to lithiasis,

neoplasias, parasitic infestation whereas secondary biliary fistulas arise due to iatrogenic injuries to the biliary tree. In absence of proper external or internal drainage, these fistula may lead to accumulation of bile leading to formation of biloma(encapsulated collection of bile outside biliary cavity) or abscess or biliary peritonitis. Failure of these fistulas to heal spontaneously after conservative management necessitates surgical or endoscopic measures. However surgical interventions are associated with high morbidity and mortality[1]. Endoscopic procedures help reduce transpapillary pressure gradient and improve transpapillary flow, thereby reducing fistula output and expediting the healing process, without causing much morbidity to the patient. The following segment contains the case reports followed by discussion and conclusion.

### **Case Report A**

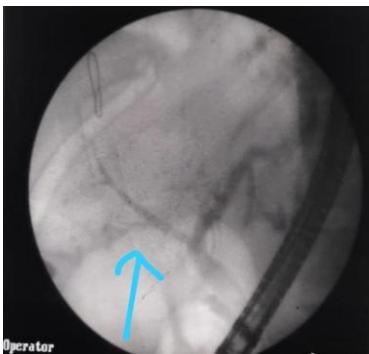
A 36 years old male presented with complaints of pain in the right hypochondrium and fever along with tenderness in the right 6th intercostal space. Ultrasound showed two well defined heterogeneous lesions in both lobes of the liver. Larger one measuring 8.3X9.2X10.4 (420 ml) in the right lobe and another in the left lobe measuring 2.7X5X3.8 (28ml). USG guided percutaneous drainage resulted in drainage of merely 10ml of content, owing to thick viscosity of the pus. The pus was sent for culture and analysis which was negative. Serum Anti-Amebic Antibody analysis was positive. Thus a diagnosis of Amebic liver abscess with superinfection was made, which failed to be managed conservatively. Thus the patient was taken for laparotomy. Intraoperatively two abscesses were found in the right lobe of the liver. One near the porta hepatis (8X10cm approximately) and other in the seventh(VII) and eighth(VIII) lobe posteriorly (5X6 cm approximately). The abscesses were drained adequately. Drains were placed in the abscess cavity near the porta hepatis, sub hepatic space and pelvic space. The patient's condition gradually improved. However the drain had a daily output of 600ml of bilious fluid in subhepatic and intra cavitory drain. The patient was started on Hyoscine and was kept under observation for 14 days. The drain output was persistent and did not decrease in volume. The patient was subjected to ERCP which revealed a normal CBD (3mm) with leak of contrast from Right Posterior Hepatic duct into the abscess cavity. A 7frX7cm double pigtail stent was placed into the right ductal system for draining bile(Figure 1). Gradually the amount of bilious content in the drain reduced in next 24 hours with subsequent amount being <100ml per day. Patient had no further episode of fever, was tolerating oral diet with resolution of abnormal laboratory parameters upon discharge.



(Fig.1):Leak of contrast in Right posterior sectoral duct

### **Case report B**

A 48 years female presented with complaints of pain and mass in the epigastric region. Initial ultrasound revealed single cystic swelling in the right lobe of liver. Contrast enhanced computed tomographic scan and serum IgE antibodies established the diagnosis of Hydatid cyst. The patient was prepared adequately for laparotomy. Bile stained Hydatid fluid was noted, cysts opened. Scolicidal agent was not instilled in the Hydatid cavity. Upon deroofting the cyst, multiple daughter cysts were encountered, which were removed. The wound was closed after placing an abdominal drain in intra cavitory and subhepatic space of morrison along with a drain in pelvic space. Patients had a persistent bilious output in sub hepatic drain and intra cavitory drain amounting to 400ml on an average. The patient underwent ERCP where an injury in the Right Posterior sectoral duct was detected. Sphincterotomy was done with subsequent placement of stent (Figure 2). Gradually the fistulous output decreased and the patient was discharged under satisfactory conditions.



(Fig.2) Leakage in biliary radical

### **Discussion**

Biliary fistulas are described as persistent biliary leakage for more than 10 days.They can arise due to injury to bile duct during cholecystectomy, with an incidence ranging from 0.25% to 0.74% for major bile duct injuries, and 0.28% to 1.7% for minor bile duct injuries. It tends to be associated more frequently with minor injury as compared to major injury [2].Intraoperative cholangiogram is an indispensable modality that helps to delineate intraoperative biliary anatomy and thus decreases the risk of inadvertent biliary injury. It may also develop in cases with major hepatic trauma with an incidence of 0.5 to4.5 [3,4]. The biliary communication of amebic liver abscess is seen in nearly 27% of reported cases [5]. In hydatid cyst disease, post operative biliary fistula develops in 1-25% of cases [6,7]. Two

theories have been proposed to explain pathogenesis of biliary fistula in cases of abscesses and hydatid cyst. The first school of thought theories that progressive pressure necrosis on biliary duct walls due to cystic space occupying lesions results in cysto biliary communication. The second theory implies that small biliary radicals get entrapped in the pathologic lesions and consecutively become atrophied [8]. The intra cystic pressure in an intact cyst exceeds that of the sphincter of oddi, thus the bile flows preferentially along the gradient. when Therefore upon commencement of operative procedures when these cyst/abscess are drained, the pressure gradient reverses and biliary leak occurs. Occult cyctobiliary communications (<5mm communication) are challenging to find preoperatively solely based on radiological investigation [9]. Low output fistula (<300ml/day) tends to close spontaneously as compared to high output fistula (>300ml/day) which usually warrants active surgical and endoscopic intervention[10]. The median recovery period post endoscopic sphincterotomy is 4 days (1-35 days) [11]. In both of our cases, the patients developed postoperative high output biliary fistulas. In both scenarios conservative management was unsuccessful and patients underwent ERCP. Endoscopic sphincterotomy with stenting allowed the defect to heal at a hastened pace without the significant risk of developing serious complications such as peritonitis, if managed appropriately. However it should be noted that endoscopic intervention is not without its own risks The immediate complications of endoscopic sphincterotomy include pancreatitis, hemorrhage, perforation and cholangitis. There are also reports of the long term adverse effects of the destruction of the sphincter of Oddi[12]

### **Conclusion**

Biliary fistulas may arise from diverse etiology, but the management of small biliary fistulas that fail to resolve with conservative management revolves around diverting biliary flow away from the biliary fistula allowing the defect to heal. This can be easily achieved by endoscopic sphincterotomy and stent placement.[13,14]

**Conflict of Interest:** None

**Financial support received:** None

**Author's Contribution:** 'Dubey R.D.' wrote the first draft of the manuscript. 'Singh S.' and 'Chalotra V.' managed the analyses of the study. 'Gupta V.' managed the literature searches..... All authors read and approved the final manuscript."

### **References**

1. Stefanini P, Carboni M, Patrassi N, Basoli A, de Bernardinis G, Negro P. Roux-en-Y hepaticojejunostomy: a reappraisal of its indications and results. *Ann Surg*. 1975;181(2):213-219. doi:10.1097/00000658-197502000-00016
2. Nuzzo G, Giuliani F, Giovannini I, et al. Bile Duct Injury During Laparoscopic Cholecystectomy: Results of an Italian National Survey on 56 591 Cholecystectomies. *Arch Surg*. 2005;140(10):986–992. doi:10.1001/archsurg.140.10.986
3. .Silvio-Estaba L, Madrazo-González Z, Ramos-Rubio E. Current treatment of hepatic trauma. *Cir Esp*. 2008;83(5):227-34.

4. Trunkey DD, Shires GT, McClelland R. Management of liver trauma in 811 consecutive patients. *Ann Surg.* 1974;179(5):722-8.
5. Agarwal DK, Baijal SS, Roy S, Mittal BR, Gupta R, Choudhuri G, et al. Percutaneous catheter drainage of amebic liver abscesses with and without intrahepatic biliary communication: A comparative study. *Eur J Radiol* 1995;20:61- 4
6. Sozuer E, Akyuz M, Akbulut S. Open surgery for hepatic hydatid disease. *International Surgery.* 2014;99(6):764-769
7. Demircan O, Baymus M, Seydaoglu G, Akinoglu A, Sakman G. Occult cystobiliary communication presenting as postoperative biliary leakage after hydatid liver surgery: are there significant preoperative clinical predictors?. *Can J Surg.* 2006;49(3):177-184.
8. Ramia JM, Figueras J, De la Plaza R, García-Parreño J. Cysto-biliary communication in liver hydatidosis. *Langenbecks Arch Surg.* 2012;397(6):881-887. doi:10.1007/s00423-012-0926-8
9. Atli M, Kama NA, Yuksek YN, et al. Intrabiliary rupture of a hepatic hydatid cyst: associated clinical factors and proper management. *Arch Surg.* 2001;136(11):1249-1255. doi:10.1001/archsurg.136.11.1249
10. Ramia JM, Figueras J, De la Plaza R, García-Parreño J. Cysto-biliary communication in liver hydatidosis. *Langenbecks Arch Surg.* 2012;397(6):881-887. doi:10.1007/s00423-012-0926-8
11. Hii MW, Gyorki DE, Sakata K, Cade RJ, Banting SW. Endoscopic management of post-cholecystectomy biliary fistula. *HPB (Oxford).* 2011;13(10):699-705. doi:10.1111/j.1477-2574.2011.00353.x
12. Misra SP, Dwivedi M. Complications of endoscopic retrograde cholangiopancreatography and endoscopic sphincterotomy: diagnosis, management and prevention. *Natl Med J India.* 2002;15(1):27-31.
13. Smith AC, Schapiro RH, Kelsey PB, Warshaw AL. Successful treatment of nonhealing biliary-cutaneous fistulas with biliary stents. *Gastroenterology.* 1986;90(3):764-769. doi:10.1016/0016-5085(86)91136-4
14. Sharma BC, Agarwal N, Garg S, Kumar R, Sarin SK. Endoscopic management of liver abscesses and cysts that communicate with intrahepatic bile ducts. *Endoscopy.* 2006;38(3):249-253. doi:10.1055/s-2005-921117

### **Abbreviations used**

ERCP: Endoscopic retrograde cholangiopancreatogram

CBD: Common Bile Duct

DPT: Double pigtail stents