

The usefulness of endoanal endoscopic ultrasound in anal disease

ABSTRACT

Introduction: Anal disease encompasses various disorders including sphincter defects, anorectal fistulas and abscesses, unexplained chronic anal pain, and anal cancers. The aim of this study is to evaluate the diagnostic contribution of endoscopic ultrasound (EUS) in anal disease.

Materials and methods: 56 patients underwent radial EUS examination, from March 2015 to March 2022. No sedation was needed for EUS examination. All EUS were performed using a flexible radial EUS probe with or without a linear probe and an ultrasound processor.

Results: Mean age was 42,4 years, 71,42% were female. The main clinical indication of anal EUS was the evaluation of anorectal suppuration, fecal incontinence (FI) and perineal crohn disease (CD). Anorectal suppurations were identified in 35,71% of cases. In patients with perineal CD, fistulas were found in 46.15% of CD cases. Anovaginal or rectovaginal fistulas (ARVFs) unrelated to CD were visualized in 8.93% of all cases. In patients presenting with FI, EUS identified internal and external anal sphincter defects.

Conclusion: EUS is a sensitive technique in the evaluation of anal anatomy and the diagnosis of benign and malignant anal disease.

Keywords: Endoscopic ultrasound, Anal disease, Anal fistula, Rectovaginal fistula, Crohn disease

INTRODUCTION

EUS is a sensitive tool in the evaluation of proctologic pathologies, it allows identification of sphincter defects, anoperineal fistulas and abscesses, exploration of perineal CD and staging of anorectal cancers. The results of anal EUS can greatly influence the therapeutic management of various anorectal disorders, making EUS an essential examination tool in the pre-therapeutic assessment of various anoperineal conditions.

We report the clinical indications and results of endoanal EUS conducted in 56 patients.

MATERIALS AND METHODS

A monocentric study included 56 patients with various proctological symptom, from January 2015 to March 2022. The medical records of the patients were reviewed to conduct the study. No sedation was needed for EUS examination.

No oral bowel preparation was required, patients were prepared using a cleansing enema 2 hours before the procedure.

All EUS were performed using a flexible radial EUS probe with or without a linear probe (Pentax®) and an ultrasound processor (Aloka-Hitachi®). All EUS examinations were performed by experienced endoscopists. Rectal tumors were excluded from our study.

We excluded from the study poorly prepared patients and patients with rectal tumor.

RESULTS

The mean age was 42.4 years [range :11-90 years]. The sex ratio was M:F 0.4 (71.42% female. 28.57% male).

The most common proctological symptoms were FI and/or anal pain (figure 1).

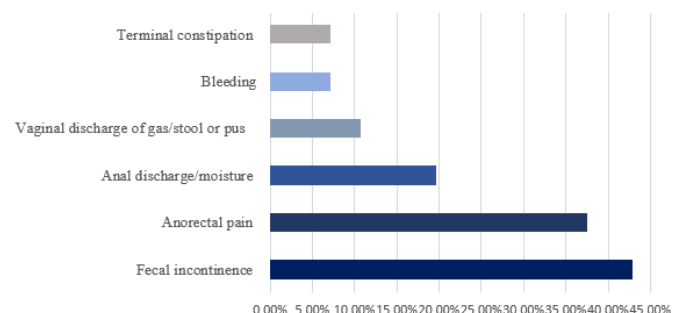


Figure 1: Clinical symptoms experienced by the

patients in our study

The Mean age of patients presenting with FI was 50.45 years (19-90 years), predominately females (Fig.2).

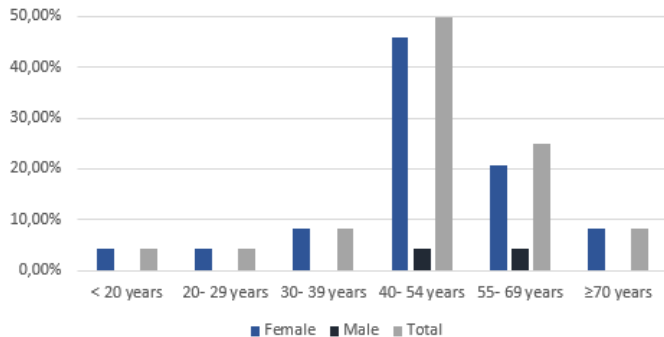


Figure 2: Overall frequency of FI by age and sex

45,83% of patients had a history of perianal surgery and among the women 27.27 % were multiparous. EEA showed internal anal sphincter (IAS) defect in 41.66% of cases, and external anal sphincter (EAS) defect in 20.83% (figure 3, figure 4).

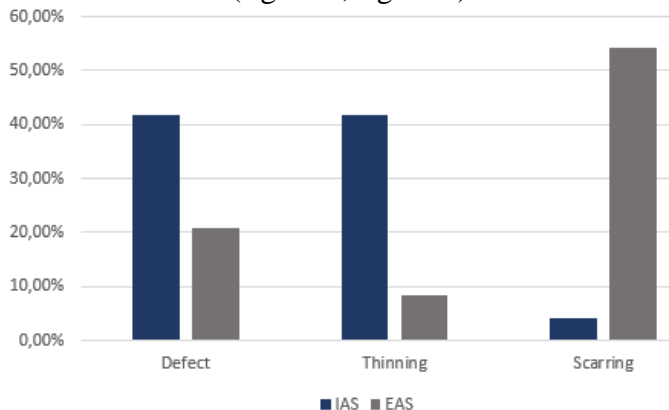


Figure 3: EES findings in cases of FI

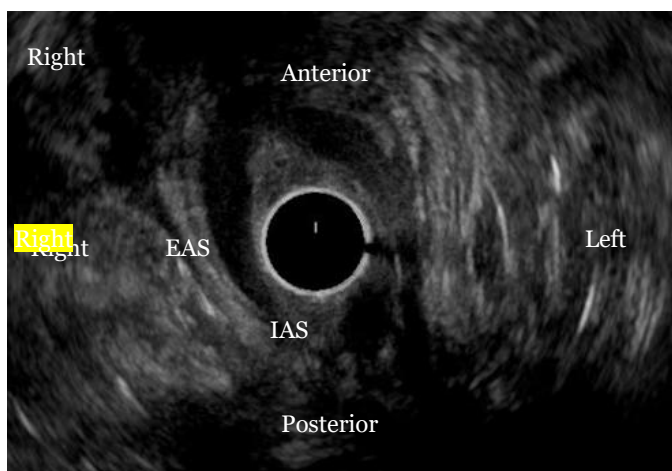


Figure 4: Endoanal ultrasound image showing a posterior defect of IAS and both thinning and scarring of EAS

50% of incontinent patients underwent anorectal

manometry (ARM). Manometric finding were hypotonic sphincter in 91.66% of cases, dyssynergia in 66.66% of cases and loss of voluntary contractions in 33.33% of cases.

Anorectal suppurations were identified in 35.71% of all cases. In our study, 23.21% of patients had a CD. Their mean age was 36.30 years (24-76 years), 53.84% men and 41,15% women. EUS visualized fistulas in 46,15% of cases (figure 5), abscesses in 30.76% and sphincter lesions in 38.46%. EUS guided the drainage of a pelvic abscess, identified in 7.69 % cases of perineal CD. The procedure was performed using a 19-gauge needle.

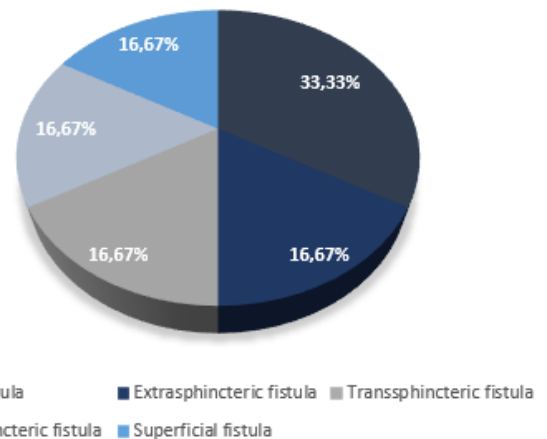


Figure 5: Type of fistulas identified by EUS in patients with perineal CD

Nonspecific anal fistulas were found in 12.5% of cases (figure 6). Their mean age was 41.2 years (19-66 years), 57.14% % men and 42,85% women.

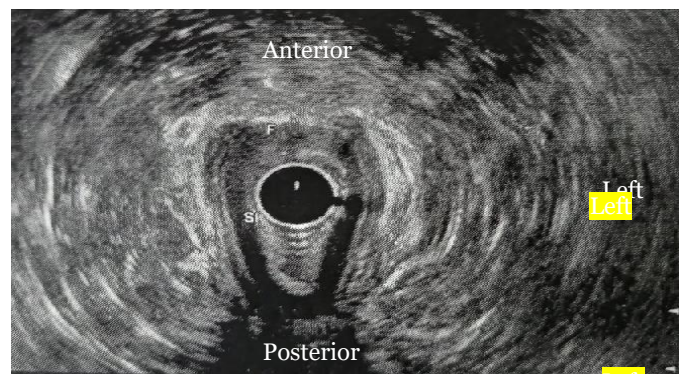


Figure 6: Endoanal ultrasound image showing a low transsphincter fistulas (F) with IAS defect (SI)

ARVFs unrelated to CD were objectified in 8.93% of cases. Their mean age was 33.80 years (26-36 years). 80% had a history of obstetrical trauma. EES identified anovaginal fistulas in 60% of cases and rectovaginal fistulas in 40% of cases, associated anal sphincters lesions were found in all cases.

Endoanal EUS identified an anal tumor in 1.78% of

cases and allowed the exclusion of an organic cause of terminal constipation in 3.57% of cases. The anal tumor was visualized in a 76-year-old female, presenting with anal pain and bleeding. EES showed an anal tumor invading the mucosae and submucosae, with no adjacent lymph nodes involvement and no anal sphincter complex invasion (figure 7).

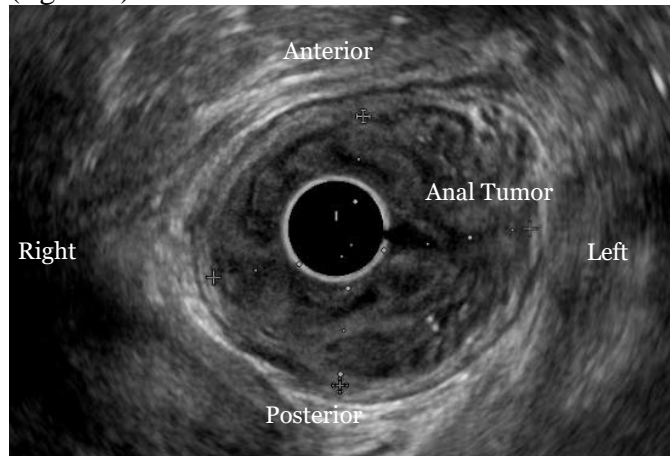


Figure 7: Endoanal ultrasound image showing an anal tumor measuring 39×31mm, invading the mucosae and submucosae

There were no abnormal finding in EUS in 28.57% of cases.

The limitations of our study were the small sample size and the lack of comparison to other imaging techniques.

DISCUSSION

Endoanal EUS is a sensitive tool in the evaluation of proctologic pathologies [1] such as FI, perineal CD, anal fistulas and abscesses, ARVFs and anal tumors.

FI is a highly prevalent problem, that severely impacts a patient's life [2]. In an American study, FI was prevalent among women in all age groups, particularly after the seventh decade followed by the age group of 55-69 years [3]. In women, obstetrical trauma is the main cause of anal incontinence, and a history of proctologic surgery is frequently reported in patients with FI [4]. In our study FI was prevalent among women, particularly in 40-54 years age group. 45.83% of patients had a history of perianal surgery and 27.27% of the women were multiparous

Endoanal ultrasonography is considered the gold standard for sphincter evaluation in FI with most studies revealing a 100% sensitivity in identifying

sphincter defects [2]. In our study 42.8% patients presented with FI and EUS identified IAS defect in 41.66% of these cases, and EAS defect in 20.83%.

Abscesses and anorectal fistulas are one of the main diseases diagnosed in adults [5]. In our study, anorectal suppurations were identified in 35.71% of cases, related to CD in 23.21% and unrelated to CD in 12.5% of cases.

Anal fistulas are common and typically associated with pain, FI, impaired quality of life and work incapacity. They occur with more frequently in men than in women with an average age of 40 years. In 80% of cases, anal fistulas are cryptogenic: secondary to an infection of the Hermann and Desfosses anal glands [6]. The results of our study were in accordance with a mean age of 41.2 years and anal fistulas occurring more frequently in men.

Endoanal EUS visualizes the detailed anatomy of the fistula and is particularly well suited for the identification of internal opening. 3D EUS provides an excellent view of fistula tracts with image reconstructions in various planes. This helps distinguish between low transsphincter, high transsphincter, or suprasphincter fistula tracks [7].

Perianal CD has a variable incidence ranging from 3.8 to 80% [8]. It has been reported that perineal CD is more frequent in patients with CD younger than 35 years old and that anal lesions can precede the onset of intestinal symptoms [9].

Anal EUS is one of the key examinations in perianal CD, particularly in complex and recurrent fistulas as indicated by the European Crohn's and Colitis Organization and the American Gastrointestinal Association guidelines [10]. In our study fistulas were found in 46.15% cases of perineal CD cases, abscesses in 30.76% and sphincter lesions in 38.46%. A meta-analysis reported a sensitivity and specificity for endoanal ultrasound of 0.87 and 0.43 respectively for fistula detection in perianal CD [11]. Anal EUS can also be used to guide therapy, assess therapeutic response, and follow patients until resolution of inflammatory activity of CD [12]. In our study, EUS-guided drainage was performed in a case of perirectal abscess.

ARVFs are relatively rare, accounting for about 5% of all anorectal fistulas [13]. Obstetric trauma is the most prevalent cause of trauma-related and likely all

ARVFs followed by CD [14]. In our study 28.57% of ARVFs were related to CD and 57.14% to obstetric trauma. Endoanal EUS - particularly contrast-enhanced EUS-can identify the location and characteristics of the ARVFs tracks and evaluate internal and external anal sphincters [15]. Anal EUS with anorectal manometry should be performed in all ARVFs related to obstetric trauma, to assess the integrity of the anal sphincters [16].

Anal cancer is relatively uncommon, accounting for 2.4% of all digestive system malignancies. Squamous cell carcinoma is the most frequent subtype [17].The median age at diagnosis is approximately 60 years [17]. Anal cancer is more common in women [18]. The most common symptom at presentation is anorectal bleeding [17].

Endoanal EUS is a useful technique in anal cancer. It evaluates local tumor invasion and lymph node metastasis and, thereby, establishes the staging of anal cancer [19]. In our study, anal EUS allowed the diagnosis and evaluated the extension of an anal tumor in 1.78% of all cases.

CONCLUSION

Endoanal EUS is a sensitive technique in the diagnosis of benign and malignant anal disease, by visualizing anal canal anatomy, identifying the lesions, evaluating the extension of anal cancer and helping to determine the need for surgical procedures. EUS had a great diagnostic contribution in our study, was well-tolerated and related proctological symptoms to various anal disorders.

REFERENCES

1. Bhatia V, Tajika M, Hijioka S. Radial-scanning flexible EUS of the anorectum and pelvis. *Endosc Ultrasound*. 2019Sept-Oct;8(5):288-97.
2. Albuquerque A. Endoanal ultrasonography in fecal incontinence. Current and future perspectives. *World J Gastrointest Endosc*. 2015Jun;7(6):575-81.
3. Ditah I, Devaki P, Luma HN, et al. Prevalence, trends, and risk factors for fecal incontinence in United States adults, 2005-2010. *Clin Gastroenterol Hepatol*. 2014Apr;12(4):636-43.
4. Saldana Ruiz N, Kaiser AM. Fecal incontinence - Challenges and solutions. *World J Gastroenterol*. 2017Jan; 23(1):11-24.
5. Abcarian H. Anorectal infection: abscess-fistula. *Clin Colon Rectal Surg*. 2011Mar; 24(1):14-21.
6. Dubois A, Carrier G, Pereira B, et al. Therapeutic management of complex anal fistulas by installing a nitinol closure clip: study protocol of a multicentric randomised controlled trial--FISCLOSE. *BMJ Open*. 2015 Dec;5:009884.
7. Sharma A, Yada v , Sahu M, et al. Current imaging techniques for evaluation of fistula in ano: a review. *Egypt J Radiol Nucl Med*. 2020Jul;51:130.
8. Safar B, Sands D. Perianal Crohn's disease. *Clin Colon Rectal Surg*. 2007Nov; 20:282-93.
9. Pescatori M, Interisano A, Basso L, et al. Management of perianal Crohn's disease. Results of a multicenter study in Italy. *Dis Colon Rectum*. 1995 Feb; 38:121-4.
10. Molteni RA, Bonin EA, Baldin JA, et al. Usefulness of endoscopic ultrasound for perianal fistula in Crohn's disease. *Rev Col Bras Cir*. 2019Jan;45(6):e1840.
11. Siddiqui MR, Ashrafian H, Tozer P, et al. A diagnostic accuracy meta-analysis of endoanal ultrasound and MRI for perianal fistula assessment. *Dis Colon Rectum*. 2012May;55(5):576-85.
12. Schwartz DA, White CM, Wise PE, et al. Use of endoscopic ultrasound to guide combination medical and surgical therapy for patients with Crohn's perianal fistulas. *Inflamm Bowel Dis*. 2005Aug;11(8):727-32.
13. Gurland BH, Vogel JD. Rectovaginal Fistula. *The ASCRS Textbook of Colon and Rectal Surgery*. Springer Cham;2022.
14. Saclarides TJ. Rectovaginal fistula. *Surg Clin North Am*. 2002 Dec;82(6):1261-72.
15. Sudol-Szopińska I, Jakubowski W, Szczepkowski M. Contrast-enhanced endosonography for the diagnosis of anal and anovaginal fistulas. *J Clin Ultrasound*. 2002 Mar-Apr;30(3):145-50.
16. Manaouil D, Dumont F, Regimbeau JM, et al. Fistules rectovaginales acquises de l'adulte. *Gastroentérologie Clinique et Biologique*. 2004;28(12):1267-79.
17. Cattelan L, Ghazawi FM, Le M, et al. Investigating epidemiologic trends and the geographic distribution of patients with anal

squamous cell carcinoma throughout Canada.
Curr Oncol. 2020Jun;27(3):e294-306

18. Babiker HM, Kashyap S, Mehta SR, et al. Anal Cancer. StatPearls [Internet. Treasure Island (FL): StatPearls Publishing; 2022 Jan. Available: <https://www.ncbi.nlm.nih.gov/books/NBK441891/>
19. Kim MJ. Transrectal ultrasonography of anorectal diseases: advantages and disadvantages. Ultrasonography. 2015Jan; 34(1):19-31.