

## Original Research Article

# **The frequency of congenital and acquired alopecia among infants and children**

### **Abstract**

#### **Background:**

Hair loss in children is commonly encountered complaint in the dermatology clinics. It can be physiological or pathological, and, in the latter, congenital or acquired.

#### **Objective**

To shed light on the different causes of hair loss in infants and children with ages that ranged from 0-12 years in Baghdad city.

#### **Patients and Methods:**

This is a hospital-based observational cross-sectional study performed at the Center of Dermatology, Baghdad Teaching Hospital, Medical City, Iraq during the period from January 2016 to the end of October 2017. One hundred twenty nine patients with ages of not more than 12 years complaining of hair loss were included in this study.

#### **Results:**

There were 71 (55%) males and 58 (45%) females presenting with hair loss. Acquired alopecia was recognized in 112 (86.8%) patients while 17 (13.2%) patients had been presented with congenital/hereditary alopecia. Alopecia areata was the most frequent cause, affecting 47 (36.4%) patients followed by tinea capitis 39 (30.2%), telogen effluvium of newborn 11(8.5%), traction alopecia 7(5.4%), posttraumatic alopecia 5(3.9%) and trichotillomania 3(2.3%). While the congenital/hereditary alopecia was consisting of hidrotic ectodermal dysplasia in 4(3.1%), hypohidrotic ectodermal dysplasia in 3 (2.3%), monilethrix 3(2.3%), nevus sebaceous 5 (3.9%) and epidermal nevi 2 (1.6%).

#### **Conclusion:**

Hair loss in infants and children encompassed both congenital (13.2%) and acquired disorders (86.8%). The commonest causes of childhood alopecia in Baghdad community were mainly acquired with alopecia areata was the most frequent cause followed by tinea

capitis and telogen effluvium of newborn while the congenital/hereditary types are also important causes of hair loss.

**Keywords:** Hair loss, Alopecia areata, Tinea capitis, Telogen effluvium, congenital alopecia, traction alopecia, trichotillomania.

## Introduction

Hair has no vital function in humans, yet its psychological impact is very important[1]. Essential functions of hair are protection and communication [2]. Each individual hair follicle encounters three stages: anagen (growth), catagen (involution) and telogen (rest) [3].

Hair loss is not uncommon skin problem among infants and children .It occurs in a broad range of conditions that may be congenital or acquired [4]. Hair loss can be classified into non scarring and scarring[5].

1.Non scarring disorders which include: telogen effluvium, alopecia areata, trichotillomania , androgenetic alopecia, and anagen effluvium [5].

In children, telogen effluvium is less frequent than in adults [4] and on examination, the scalp is normal with absence of inflammatory signs [6]. Alopecia areata is a non-cicatricial alopecia that is presumed to be a hair specific autoimmune disease[5] and it is the most common form of hair loss in children[7]. Trichotillomania is defined by patient's repetitive and self-induced hair pulling as a part of obsessive compulsive neurosis[4] and can affect preschool age children, preadolescents to young adults, and adults[8]. Endocrine evaluation is highly recommended if pre pubertal child was diagnosed with androgenetic alopecia[9]. While anagen effluvium is usually follows the administration of major anticancer drugs and it is usually reversible [10].

2.Scarring disorders which can be classified into a 'primary' condition or a 'secondary' event[11]. Hair loss in children is almost always non scarring[12].

Hair shaft abnormalities could be classified into two broad categories; those associated with increased hair fragility e.g monilethrix (beaded hair) and those not associated with increased hair fragility like loose anagen hair syndrome and wooly hair[5].

Ectodermal dysplasias are a rare group of heterogeneous inherited disorders that identified by congenital defects in development of two or more ectodermal structures[13].

On examination, there may be sparse, dry, light-pigmented, and brittle hair. Anhidrotic /hypohidrotic form and hidrotic form representing the two major types[14].

Ringworm of scalp (Tinea capitis) is infection of the scalp as a result of invasion of the hair shafts by a dermatophyte fungus. Partial or diffuse hair loss with varying degrees of inflammation are the cardinal features of tinea capitis or could be seen as a moth eaten alopecia with scaly scalp [15]. Kerion as a severe inflammation of scalp, may be followed by scarring and permanent alopecia[16]. So, the aim of the present work to shed light on

the causes of hair loss and to provide a guide for the evaluation of the common causes of alopecia in children under the age of 12 years in Baghdad governorate.

### **Patients and Methods:**

One hundred twenty-nine patients under the age of 12 complaining of various forms of hair loss were included in this hospital-based observational cross-sectional study performed at the Center of Dermatology and Venereology, Baghdad Teaching Hospital, Medical City, Iraq during the period from January 2016 to the end of October 2017. The study followed the Declaration of Helsinki Principles and informed consent was obtained from each patient's parents after explanation of the nature of the study. The gleaned data included age, gender, and clinical presentations (focal or global hair loss, involved site, involvement of hairy sites other than the scalp). In addition, a thorough history was taken from every patients/parents regarding age of onset whether congenital or acquired, onset of hair loss like sudden or insidious, progression of the problem, associated cutaneous symptoms / diseases, associated systemic illnesses, family history of similar problem or other autoimmune diseases, hair style, drug history, and traumatic history. Social history regarding animal contact, crowded environment and sharing personal fomites were also gathered from patients/parents.

Each patient was examined carefully regarding assessment of the pattern of hair loss whether it is patchy or diffuse and the eyebrows, eyelashes, and body hair were also examined for hair loss. Scalp's skin was examined for the presence of scaling, erythema, crusting, pustules, and the presences or absence of follicular ostia. The clinical examination also involved the nails, teeth, palms and soles, and other sites were also examined in selected cases as part of searching for any associated cutaneous diseases or syndromes.

Diagnosis was based primarily on the clinical presentation together with the clinical examination and the associated symptoms, and this was considered as a guide for the evaluation of hair loss. Hair pull test by grasping 50 to 60 hairs between thumb, index, and middle fingers in frontal, occipital, and both temporal regions of the scalp was performed and the test was considered positive if  $\geq 6$  hairs pulled. Potassium hydroxide (KOH) examination of the scales and /or plucked hair was done in doubtful cases for tinea capitis, microscopic examination of the hair shaft was performed for specific diagnostic purposes, and other laboratory investigations were performed in selected cases where it's necessary.

For patients with alopecia areata, the severity of disease was defined as follow: <sup>(17)</sup>

1. Mild:  $3 \leq$  alopecic patches with a widest diameter of  $\leq 3$ cm or the disease limited to the eyebrows and eyelashes.
2. Moderate: existence of  $> 3$  alopecic patches or a patch  $> 3$  cm at the widest diameter without alopecia totalis or alopecia universalis.
3. Severe: alopecia totalis or alopecia universalis.

Digital photography was taken using SONY® Cyber-Shot 16.1- megapixel(MP).

## Statistical analysis

Statistical package for social science (SPSS) version 23 was used for data input and analysis. Data were statistically described in terms of mean, frequencies (no. of cases), standard deviation (SD), male to female ratio and percentage (%).

### Results:

One hundred twenty nine patients complaining of hair loss [71 (55%) males; 58 (45%) females]. The age of patients at presentation was ranged from 2 months to 12 years with mean  $5.79 \pm 2.81$  years. Correlation of the causes of hair loss identified in this study with age and gender of patients was shown in table (1).

Of 129 child patients in this study, 112 (86.8%) patients had been presented with acquired alopecia while congenital/hereditary alopecia was observed in the remaining 17 (13.2%) patients (Figure.1).

Alopecia areata was the most frequent cause; affecting 47 (36.4%) patients (Figure.2) with twenty six (55.3%) males and twenty one (44.7%) females. The mean age at presentation was  $6.89 \pm 2.46$  years with a lower mean age in the girls ( $6.29 \pm 2.7$  years) as compared to the boys ( $7.38 \pm 2.1$ ). The earliest age observed in this study was 2.6 years. Patients were categorized into mild, moderate, and severe disease. Twenty seven (57.4%) patients had mild disease, moderate disease in 18 (38.3%) patients, and severe disease was seen in 2 (4.3%) patients presented with alopecia universalis. The nail changes were documented in 11 (23.4%) patients. Pitting was the most common abnormality seen in 10 (91%) patients. Severe onychodystrophy was noted in 1 (9%) patient. Family history of alopecia areata was positive in 2 (4.3%) patients. The associated diseases in the alopecia areata patients were atopic dermatitis in 9 (19.1%) patients, asthma in 3 (6.4%) patients, and vitiligo in 2 (4.3%) patients, Down syndrome in 3 (6.4%) patients and diabetes mellitus in 1 (2.1%) patient.

Tinea capitis was the second commonest cause of hair loss in this study, affecting 39 (30.2%) children. Males were particularly affected more than females [males 25 (64.1%) cases, females 14 (35.9%) cases]. The mean age at presentation was  $6.12 \pm 1.60$  years. The presentation was commonly as scaly alopecic patches, solitary or multiple, some with irregular patches of hair loss so called moth eaten alopecia (Figure. 3 A&B). Kerion formation with some elements of scarring was also seen (Figure.3 C). KOH scrapping was done to confirm the diagnosis in doubtful cases yielding positive result and showed hyphae and spores. Correlation of the risk factors with tinea capitis were as the following: history of animal contact was observed in 15 (38.5%) patients, 12 (30.8%) patients had intra-family history of other member affected, 21 (53.8%) patients were live in crowded environment and all the 39 (100%) patients had history of sharing other personal fomites.

Telogen effluvium of the newborn (physiologic telogen effluvium) was also observed in 11 (8.5%) patients in this study. Five males and six females with mean age of  $2.90 \pm 1.04$  months. Three patients had mild diffuse hair shedding while eight patients presented as circumscribed patch of hair loss over the occipital region (neonatal occipital alopecia), (Figure.4), while pathological telogen effluvium was not observed.

Traction alopecia was seen in 7 (5.4%) patients. All patients were females with mean age of  $7.28 \pm 1.60$  years. The earliest observed age was 4 years. The patients presented with minimal hair thinning at the anterior (fronto-temporal) and to lesser degree posterior scalp. All cases were presented in early stages, no inflammation nor **scarring** been observed.

Posttraumatic alopecia was seen in 5 (3.9%) patients. The mean age at presentation was  $5.80 \pm 1.30$  years. The 5 patients (4 males and 1 female) presented with single or multiple, small (1-2 cm) linear alopecic patch on the scalp (Figure. 5). Traumatic history was elucidated in 2 patients while the parents denied any obvious trauma in the other 3 patients.

Trichotillomania was also observed in three (2.3%) female patients with mean age of  $7.66 \pm 3.05$  years presented with single patchy hair loss, broken and variable length hair were seen in alopecic patches (Figure. 6). History of hair pulling was conducted from the patients/parents in 2 children.

Congenital/hereditary alopecia accounted for 13.2% of the causes of hair loss in this study. The onset of the diseases in all 17 patients was at the birth or in the first year of the life. Hidrotic ectodermal dysplasia was observed in 4 (3.1%) patients with mean age of  $6.50 \pm 3.41$  years; three of them (2 males and 1 female) were from the same family. All 4 patients (2 males and 2 females) were presented with short, curly, dry and slowly growing sparse hair. Positive family history was revealed in the family with three members affected and negative in the fourth patient. An associated palmoplantar keratoderma, thick and dystrophic fingers and toenails were found in all patients. Poor oral hygiene resulting in teeth abnormalities in form of teeth decay and cavities were found in all patients but no specific teeth shape aberration (Figure. 7. A&B). The all 4 patients were normally sweat and they did not specifically presented for evaluation of their hair problem rather they referred to dermatology clinic by pediatrician for treatment of the associated palmoplantar keratoderma.

Hypohidrotic (anhidrotic) ectodermal dysplasia had been recognized as one of causes of hair loss in this study (Figure 7.C). Three (2.3%) male patients with mean age of  $5 \pm 1$  year were presented with sparse scalp hair. Limited involvement of the eyebrows was found in one patient. No noticeable nail involvement with exception of punctate leukonychia affecting few finger nails in one patient. In all three patients, teeth shape abnormalities in form of small and conically shaped teeth, in addition to missed teeth were found. One patients had positive family history while the other 2 patient failed to show any other affected family member. Two patients had associated atopic dermatitis, one of those 2 patients had asthma. All three patients were intolerant to heat and in all of them, sweating was absent in winter and summer. All of three patient referred to dermatology clinic by

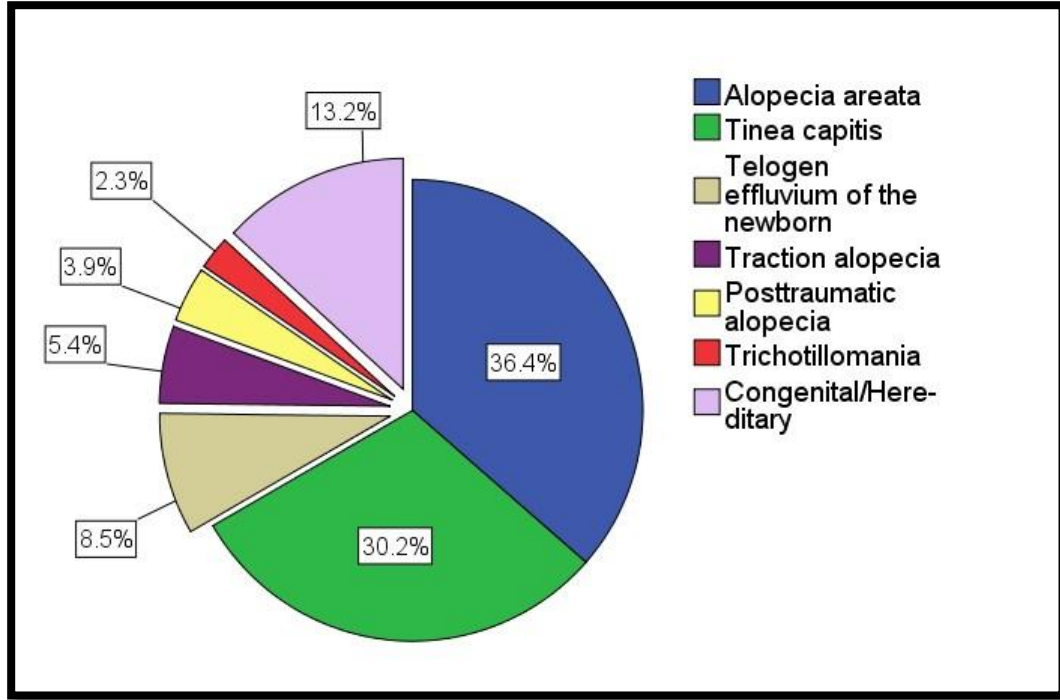
pediatrician for evaluation of an associated eczematous lesion (in 2 patients) and sparse hair in one patient.

Other congenital causes of hair loss observed in the present study were monilethrix in 3 (2.3%) patients presented with diffuse hypotrichosis of the scalp, and with follicular keratotic papules observed clearly in 2 patients, in addition to keratosis pilaris involving the extensor aspect of arms and thighs (Figure. 8. A,B,C ), nevus sebaceous in 5 (3.9%) patients and epidermal nevus in 2 (1.6%) (Figure.9).

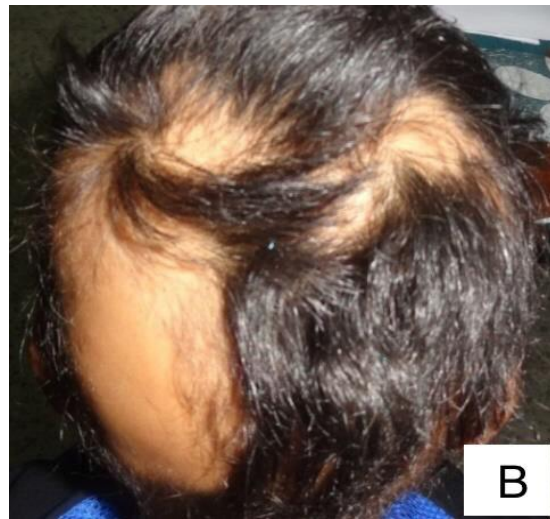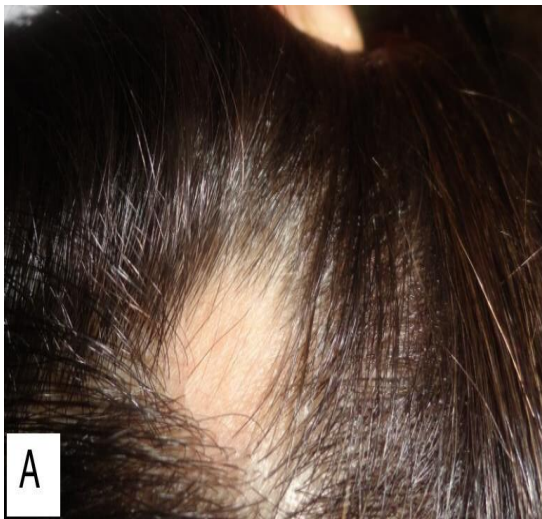**Table (1):** Correlation of the causes of hair loss identified in this study with age and gender of the patients.

Age groups	Causes of hair loss	Number of patients		Total number(%)
		Male	Female	
0-3 Years	Telogen effluvium of the newborn	5	6	18 (14%)
	Alopecia areata	-	3	
	Monilethrix	2	1	
	Nevus sebaceous	1	-	
>3- 6 Years	Alopecia areata	7	7	39(30.2%)
	Tinea capitis	8	5	
	Nevus sebaceous	2	1	
	Hidrotic ectodermal dysplasia	1	1	
	hypohidrotic ectodermal dysplasia	2	-	
	Posttraumatic alopecia	1	1	
	Traction alopecia	-	1	
	Trichotillomania	-	1	
Epidermal nevi	1	-		
>6 - 9	Alopecia areata	11	6	50 (38.8%)

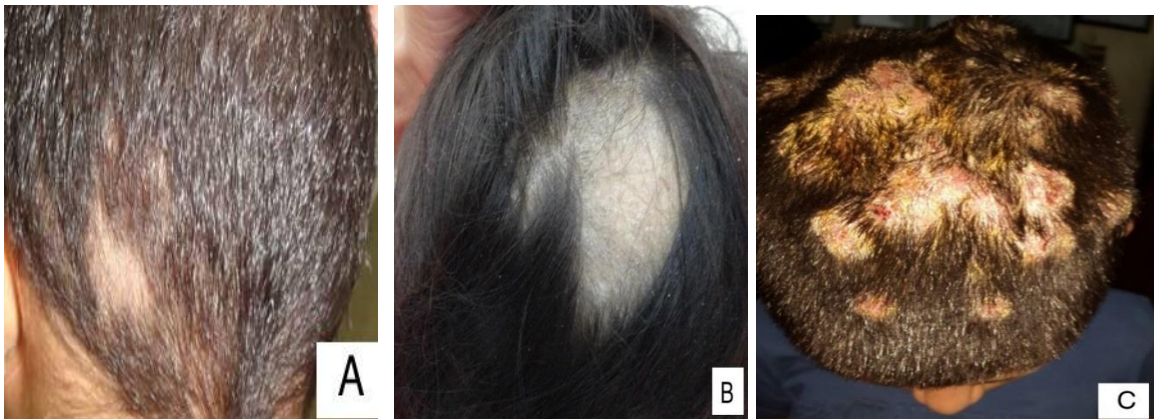Years	Tinea capitis	14	7	
	Traction alopecia	-	5	
	Posttraumatic alopecia	3	-	
	Trichotillomania	-	1	
	Hidrotic ectodermal dysplasia	1	-	
	hypohidrotic ectodermal dysplasia	1	-	
	Nevus sebaceous	-	1	
>9 - 12 Years	Alopecia areata	8	5	22 (17 %)
	Tinea capitis	3	2	
	Traction alopecia	-	1	
	Trichotillomania	-	1	
	Hidrotic ectodermal dysplasia	-	1	
	Epidermal nevi	-	1	
Total		71	58	129 (100%)



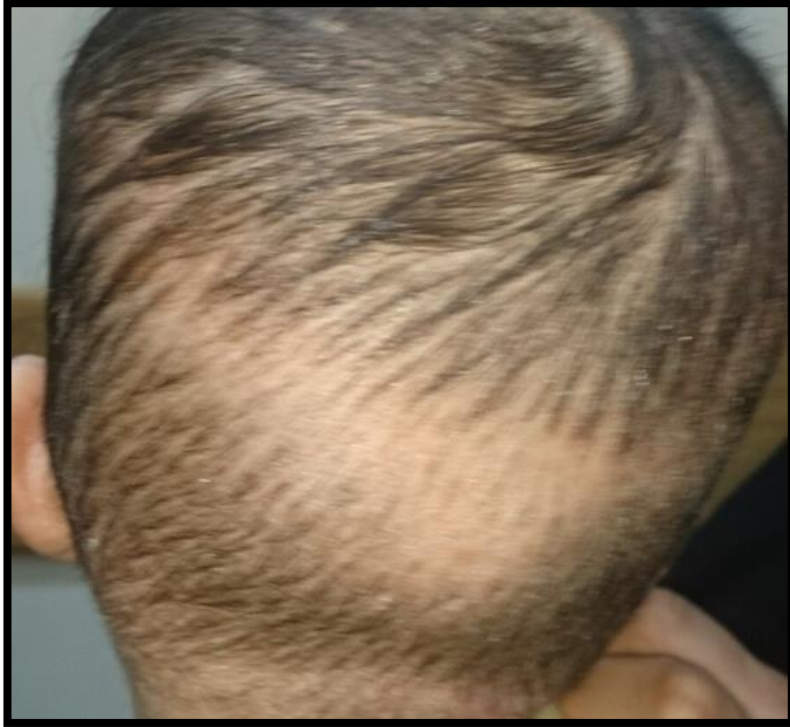**Figure (1):** Profile of hair loss in children in Baghdad governorate.



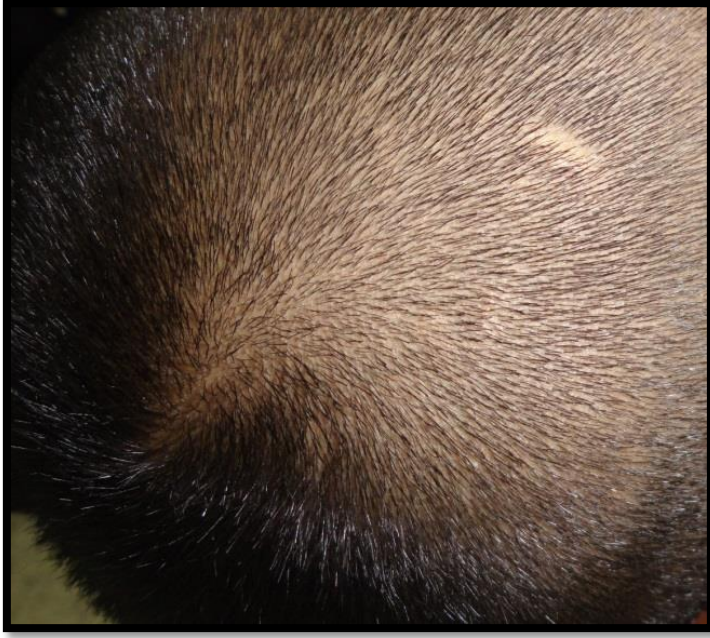**Figure (2):** Alopecia areata.( A )Asymptomatic smooth patch of alopecia areata in a 4 year-old girl with mild disease and (B) multiple large areas of alopecia areata in a 7 year-old boy with moderate disease.



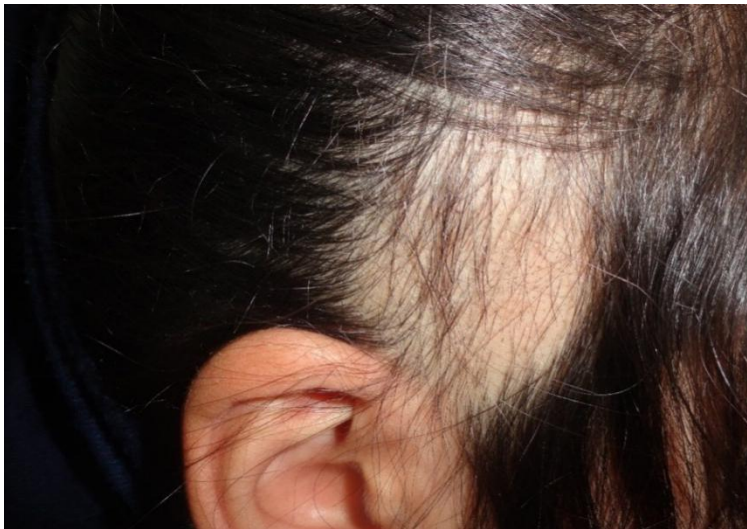**Figure (3):** Tinea capitis with varying degrees of hair loss. (A and B) Scaly non inflamed scalp in tinea capitis in a 6year- old boy and a 4 year- old girl and (C) kerion in a 3 year- old patient.



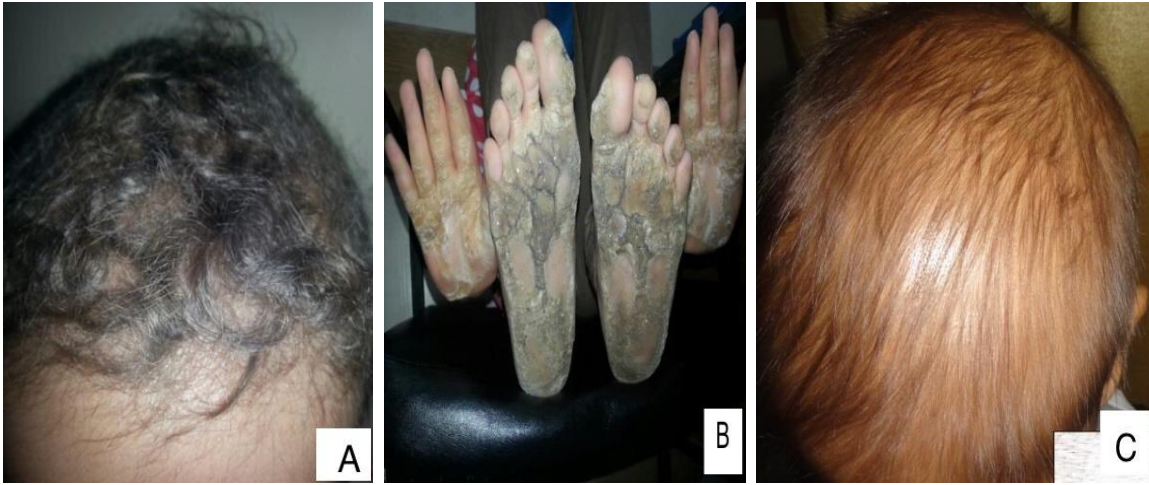**Figure (4):** Neonatal occipital alopecia in a 2 month-old infant.



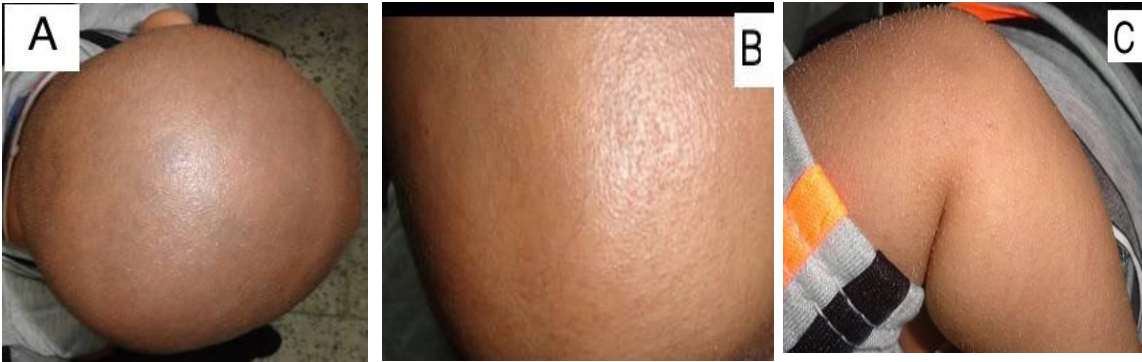**Figure (5):** Posttraumatic alopecia in a 6 year- old boy.



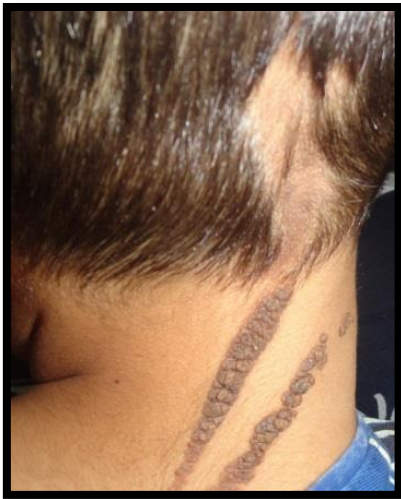**Figure (6):** Trichotillomania in a 9 year- old girl.



**Figure (7):** Ectodermal dysplasia.( A and B) Hidrotic ectodermal dysplasia in 11year-old girl with short ,curly hair in (A) and the associated palmoplantar keratoderma in (B). (C) Hypohidrotic ectodermal dysplasia with thinning of scalp hair.



**Figure (8):** Monilethrix. (A) diffuse hypotrichosis of the scalp in fifth months old male infant , (B) closed up view of scalp showed up sparse short hair with follicular papules and (C) extensive keratosis pilaris involving the thigh of same patient.



**Figure (9):** Epidermal nevus involving the scalp in a 5 year-old boy.

**Discussion:**

Hair, especially scalp hair, represents the fundamental part of beauty and the vital aspect of self-image[18]. Hair loss, even in children, has significant psychological impact on the child and /or their parents as older children with alopecia were more anxious, secluded, and depressed [19].

Unfortunately, no extensive studies exist regarding epidemiology of causes of hair loss in children[20].

In the present work, the mean age of the presenting patient was  $5.79 \pm 2.81$  years; 69 % of them were in between >3- 9 years of age. These findings are comparable to another study by Moneib et al.[21].

Alopecia areata is a common autoimmune disease with 40-50% of patients are younger than 21years[6].

In the present study, alopecia areata was the most frequent cause of hair loss (36.4%). This finding is in agreement with another report[20] and it's inconsistent with other studies done in Egypt and southeast Nigeria where tinea capitis was the most common cause of hair loss in children[21,22]. This is probably due to larger population, overcrowding, and humid environment of both countries, all these factors will encourage the transmission of fungal infection. The present study showed male: female ratio of 1.2:1 and this is comparable to previous study[23]. The mean age of presenting patients in the present study was  $6.89 \pm 2.46$  with slightly lower mean age in the girls as compared to the boys and these findings are in line with another study[24]. In the present study, mild disease was more common than moderate and severe disease. This agrees with another study[25].

Nail changes recorded in 26.5%<sup>(24)</sup>, 3.7% [22] and 8.4 % [23] of children with alopecia areata. In the present study, nail involvement was observed in 23.4% with pitting was the most common finding. This finding falls within the range of the previously mentioned studies[22-24].

A positive family history was revealed in 4.3% of alopecia areata patients in the present study, the finding that falls within the range of what previously reported[22-25].

Concerning the associated diseases with the alopecia areata patients in the present study, atopic dermatitis and asthma were identified in 19.1% and 6.4% of patients respectively. These findings are comparable to previous studies[23,24]. Vitiligo and diabetes mellitus were noted in 4.3% and 2.1% of patients with alopecia areata respectively and these findings concur well with previous study[26]. In addition, Down syndrome was observed in 6.4% of patients with alopecia areata. This finding seems comparable to what previously reported[24].

Tinea capitis is a dermatophyte infection of the hair shaft on the scalp. It is a primarily disease of a preadolescent children[27]. In the present study, tinea capitis was the second commonest cause of hair loss. This is inconsistent with other studies[21,22]. In Iraq ,the overall prevalence rate was decreased from 2.4% during 2000 in primary school children by Fathi et al.[28] to 0.8% by Al-Rubiay et al.[29] and 0.1% by khalifa et al.[30] during 2004 .These variations may be attributed to social, socioeconomic and geographical variations[31]. Also, it may reflect improvement in socioeconomic status and health education. Boys were affected more than girls. This is in agreement with other studies in the world[21,22,30]. The mean age in the present study was  $6.12 \pm 1.60$  years and this is comparable to a previous study[32]. This period correlates with increased child contact with other children while playing or studying. In the present study, animal contact was recorded in 38.5% which is highly lower than the reported by Fathi et al. as they included many rural village in their study while Intra family history and living in crowded environment was comparable to what previously reported by Fathi et al.[28].

In the present study, telogen effluvium of the newborn was observed in 8.5% with mean age of  $0.23 \pm 0.08$  year ( $2.90 \pm 1.04$  months) .This observation is comparable to another study[22]. Telogen effluvium develops frequently in newborns and is mostly overlooked. A transient circumscribed alopecic patch at the occiput may also occurs in many infants [33]. Surprisingly, pathological telogen effluvium was not seen in the present study. This finding is in contradiction with a prior study[22]. The reason for this contradictory result is not wholly clear, but there are two possible rationalizations. Firstly, as the hair loss in this condition is global rather than focal, so it can easily be missed by the parents.

Secondly, as most cases of telogen effluvium are subclinical,[34] then it doesn't pay attention of the parents.

Traction alopecia is a common cause of hair loss particularly in people of African descent. Progressive hair loss where the traction is applied is the usual clinical presentation[35]. The present study showed 7 (5.4%) females children presented with minimal hair thinning at the anterior and to lesser degree posterior hair lines, and this is in congruous with hair styling necessitated as a school girl rules in our society. Neither bald areas nor evidence of follicular inflammation were seen. This observation is comparable to what previously reported [22].

Five cases (3.9%) of posttraumatic alopecia with mean age of  $5.80 \pm 1.30$  years were observed in the present study. This finding is comparable to another study[20]. Striae distensae like lesions of scalp, a condition described by Sharquie et al., might explain the absence of obvious traumatic history in 3 present patients. They supposed mild non obvious blunt trauma ,that could be missed or neglected by patients/parents, might cause sudden stretch to the skin with resultant damage to the collagen and rupture of the dermal tissue with apparently normal epidermis similar to the pathogenesis of striae distensae which manifested clinically as single or multiple linear patchy hair loss[36].

In the present work, trichotillomania was observed in 3(2.3%) patients and this is in consonance with previous study [21]. All patients were females, a finding agrees with previous report by Sharquie et al., where females were predominately affected[37].

Congenital/hereditary alopecia accounted for 13.2% of hair loss in the present study. This finding is slightly higher than the reported by Nnoruka et al [22]. In this context, it's worthwhile to consider the underlying concept that the endogamy marriage, which is a common tradition in Iraqi population, may explain, at least in part, the higher frequency of congenital /hereditary alopecias in the present work. Consanguinity had been recorded in 49.4% of 83 Iraq patients with genodermatosis[38].

In present study, hidrotic and hypohidrotic ectodermal dysplasia were observed in 3.1% and 2.3% of patients respectively. This finding is higher than the reported in another study[21]. Nevus sebaceous was observed in (3.9%) and this finding is in agreement with

another study[32]. Monilethrix was seen in 2.3% and this is comparable to previous study[22].

### **Conclusions:**

Hair loss in children is a common problem and it's of major concern for children and/ or their parents. Profile of hair loss in Iraqi children was variable and it's mainly acquired. The commonest causes were alopecia areata followed by tinea capitis, telogen effluvium of the newborn, traction alopecia, posttraumatic alopecia and trichotillomania. The dermatologist and pediatrician should also keep in mind the congenital /hereditary causes of hair loss. While the pathological telogen effluvium was not recorded.

### **Ethical Approval:**

As per international standard or university standard ethical approval has been collected and preserved by the authors.

### **References:**

1. Messenger AG, Sinclair RD, Farrant P, Berker DA. Acquired disorders of hair. In: Griffiths C, Barker J, Bleiker T, Chalmers R, Creamer D (eds.) .Rook's Textbook of Dermatology,9<sup>th</sup>ed. Singapore, Blackwell Science Ltd., 2016; 89:2-11.
2. Randall VA. Hormonal regulation of hair follicles exhibits a biological paradox. *Semin Cell Dev Biol.* 2007; 18:274–285.
3. Cotsarelis G, Botchkarev V. Biology of hair follicles. In:Goldsmith LA,Kataz SI,Gilchrest BA, Paller SA,Leffell DJ,Wolf K (eds.). Fitzpatrick's Dermatology in General Medicine,8<sup>th</sup> ed. New York, McGraw –Hill Company,2012;86:960-969.

4. Ioannides D, Tosti A (eds): Alopecias – Practical Evaluation and Management. *Curr Probl Dermatol.* 2015; 47: 55–66.
5. Sperling LC, Sinclair RD, Caelen LE. Alopecias. In: Bologna JL, Jorizo JL, Schaffer J V (eds). *Textbook of Dermatology*, 3<sup>rd</sup>ed. China, Elsevier, 2012; 11, 69:1093-1112.
6. Harrison S, Sinclair R: Optimal management of hair loss (alopecia) in children. *Am J Clin Dermatol.* 2003; 4:757-770.
7. Otberg N, Shapiro J. Hair Growth Disorders. In: Goldsmith LA, Kataz SI, Gilchrist BA, Paller SA, Leffell DJ, Wolf K (eds.). *Fitzpatrick's Dermatology in General Medicine*, 8<sup>th</sup> ed. New York, McGraw Hill, 2012; 88:988-1001.
8. Sah DE, Koo J, Price VH: Trichotillomania. *Dermatol Ther.* 2008; 21:13–21.
9. Tosti A, Iorizzo M, Piraccini BM. Androgenetic alopecia in children: report of 20 cases. *Br J Dermatol.* 2005; 152: 556–559.
10. Trüeb R. Chemotherapy-induced Hair Loss. *Skin Therapy Lett.* 2010; 15: 5-7.
11. Rongioletti F, Christana K. Cicatricial (Scarring) Alopecias. *Am J Clin Dermatol.* 2012; 13 (4): 247-260.
12. Cohen BA, Bender AM. Disorders of the hair and nails. In: Cohen BA (eds.). *Pediatric Dermatology*, 4<sup>th</sup>ed. China, Saunders Elsevier, 2013; 8: 211-215.
13. Itin PH. Ectodermal dysplasia: thoughts and practical concepts concerning disease classification – the role of functional pathways in the molecular genetic diagnosis. *Dermatology.* 2013; 226:111–14.
14. Rossi A, Miraglia E, Fortuna MC, Calvier S, Giustini S. Topical cetirizine and oral vitamin D: a valid treatment for hypotrichosis caused by ectodermal dysplasia. *J Eur Acad Dermatol Venereol.* 2016; 1-4.
15. Hay RJ, Ashbee HR. Fungal infections. In: Griffiths C, Barker J, Bleiker T, Chalmers R, Creamer D (eds.). *Rook's Textbook of Dermatology*, 9<sup>th</sup>ed. Singapore: Blackwell science Ltd., 2016; 32:38-39.

16. James WD, Elston DM, Berger TG (ed). Diseases Resulting from Fungi and Yeasts. In: Andrews' Diseases of the Skin, Clinical Dermatology, 12<sup>th</sup> ed. Philadelphia, Elsevier, 2016;15:286-288.
17. Kavak A, Baycal C, Ozarmagan G, Akar U. HLA in alopecia areata. *Int J Dermatol.* 2000;39:589-592.
18. Sardesai VR, Prasad S, Agarwal TD. A study to evaluate the efficacy of various topical treatment modalities for alopecia areata. *Int J Trichol* 2012;4(4):256-70.
19. Hunt N, McHale S. The psychological impact of alopecia. *Br Med J.* 2005 ;331:951–3
20. Conti R, Colucci R, Arunachalam M, Berti S, Fabroni C, De Martino M, Dragoni F, Lazzeri L, Pisaneschi L, Moretti S. Hair and Scalp Disorders in a Tuscan Pediatric Dermatological Outpatient Clinic: A Clinical and Epidemiological Evaluation. *Med Princ Pract.* 2016;25:67-71.
21. Moneib HA, El-Shiemy SMH, Saudi WM, El-Fangary MM, Nabil T, Mohy SM. Hair loss among a group of Egyptian children: a clinical and dermoscopic study. *J Egypt Women Dermatol Soc.* 2017; 14:9–24.
22. Nnoruka EN, Obiagboso I, Maduechesi C. Hair loss in children in SouthEast Nigeria: Common and uncommon cases. *Int J Dermatol* 2007;46:18-22.
23. Tan E, Tay YK, Giam YC. A clinical study of childhood alopecia areata in Singapore. *Pediatr Dermatol* 2002;19: 298-301.
24. Nanda A, Al-Fouzan AS, Al-Hasawi F. Alopecia areata in children: a clinical profile. *Pediatr Dermatol* 2002; 19:482–485.
25. Thomas EA, Kadyan RS. Alopecia areata and autoimmunity: A clinical study. *Indian J Dermatol.* 2008; 53(2): 70–74.
26. Tan E, Tay YK, Goh Ch-L, Giam YC. The pattern and profile of alopecia areata in Singapore – a study of 219 Asians. *Int J Dermatol.* 2002; 41: 748– 753.

27. Patel GA, Schwartz RA. Tinea capitis: still an unsolved problem? *Mycoses*. 2011;54:183-188.
28. Fathi HI, Al-Samarai AM. Prevalence of tinea capitis among school children in Iraq. *East Mediterr Health J*. 2000; 6: 123 – 137.
29. Al-Rubaiy KK, Habib OS, Ebrahim S. Pattern of skin disease among primary school children in Basrah, Southern of Iraq. *M J BU*. 2004; 1-2: 40 – 42.
30. Khalifa KA, Al-Hadithi TS, Al-Lami FH, Al-Diwan JK. Prevalence of skin disorders among primary school children in Baghdad governorate, Iraq. *East Mediterr Health J*. 2010,16 (suppl 2):209-3.
31. Hignis EM, Faller LC, Smith CH. Guidelines for the management of Tinea capitis. *Br J Dermatol*. 2000; 143: 53 – 58.
32. Al-Refu K. Hair loss in children: common and uncommon causes; clinical and epidemiological study in Jordan. *Int J Trichol*. 2013; 5:185–189.
33. Chang MW. Neonatal, pediatric, and adolescent dermatology. In: Goldsmith LA, Katatz SI, Gilchrist BA, Paller SA, Leffell DJ, Wolf K (eds.). *Fitzpatrick's Dermatology in General Medicine*, 8<sup>th</sup> ed. New York, McGraw-Hill, 2012;107: 1190.
34. Grover C, Khurana A. Telogen effluvium. *Indian J Dermatol Venereol Leprol*. 2013; 79:591-603.
35. Khumalo NP, Ngwanya RM, Jessop S, Gumedze F, Ehrlich R. Marginal traction alopecia severity score: development and test of reliability. *J Cosmet Dermatol*. 2007;6:262-9.
36. Sharquie KE, Al-Waiz MM, Al-Nuaimy AA. Striae distensae-like lesions. A cause of scarring alopecia among children. *Saudi Med J*. 2002; 23:1489-91.
37. Sharquie KE, Noaimi A A, Younis M S, Al-Sultani B S. The Major Psychocutaneous Disorders in Iraqi Patients. *Journal of Cosmetics, Dermatological Sciences and Applications*. 2015; 5:53-61.

38. Al-Hamami HR, Al -Noaimi AA, Al-Waiz MM, Al-Kabraty AS. Frequency of genodermatosis among Iraqi patients. IASJ. 2010; 9(1):62-7.