

**Dr.Mohamed Eltaieb Ali<sup>1</sup>, Dr. Ashraf Alakkad<sup>2</sup>**

- 1- Internal Medicine department, Madinat Zayed Hospital, UAE**
- 2- Internal Medicine department, Madinat Zayed Hospital, UAE**

**Correspondence:**

**Dr.Ashraf ALakkad**

**Internal Medicine department, Madinat Zayed Hospital, UAE**

**CASE STUDY - AN INTERESTING CASE OF COVID19 INDUCED  
FULMINANT MYOCARDITIS**

## **Abstract**

A young patient, aged 31 years old, initially presented to other facility with complaints of mild fever, throat pain, and generalized myalgia. His COVID19 test came out positive, confirming that the patient was suffering from COVID19. Since the patient's chest CT scan was normal and without any consolidations characteristic of COVID19, he was prescribed antibiotics and an antipyretic, instructed to follow strict home isolation, and then sent home.

The same patient reported to the Emergency Department once again. This time, his symptoms were severe. He was experiencing extreme shortness of breath, an exaggerated cough, and above all, extreme fatigue and exhaustion which was evident from his overall general appearance. The patient appeared to be severely ill, and had both tachycardia and tachypnea. His oxygen saturation levels were 85%, which is low, and he required oxygen support immediately.

Furthermore, his neck veins were severely congested and he had a raised JVP. He had distant heart sounds, and his chest auscultation revealed bibasilar crackles. The left lobe of the liver was palpable. There was, however, no indication of any ascites, or fluid retention anywhere else in the body. His ECG reports revealed that he was suffering from sinus tachycardia. There was evident ST-segment elevation on the ECG, which was persistent with the diagnosis of myocardial ischemia. The chest x-ray, which was initially normal, showed cardiomegaly in the preceding x-ray. The findings were consistent with the conclusion that the heart was definitely part of the equation.

It was later diagnosed that this was a classic presentation of acute fulminant myocarditis which occurs secondarily due to COVID19. The diagnosis took time, but fortunately, the patient had

presented to the Emergency in time and this led to him getting admitted, evaluated, and treated within the period before any other complication took place.

Although patients with pre-existing or a predisposition to developing heart conditions are more inclined towards such outcomes, it can affect almost anyone owing to the complicated nature of the virus itself.

Key words: Myocarditis, Fulminant, Coronavirus, COVID-19

## **INTRODUCTION**

Severe Acute Respiratory Syndrome-Coronavirus-2 (SARS-CoV-2) continues to pose a constant challenge for humanity. This virus does not only have a confusing nature, the long list of complications and diseases that are now arising because of the disease are becoming a source of concern for doctors and experts who are working to completely eliminate the virus from society.

Cases of COVID19-associated myocarditis were being reported occasionally, but it is now an established fact that COVID19 can cause myocarditis of varying degrees in recovering or suffering patients.<sup>[1]</sup>

Although explaining myocarditis in terms of COVID19 might sound like a difficult idea, it is postulated that it should be diagnosed and evaluated on the same grounds as before. The only addition is that now it occurs in association with COVID19 and not alone.

COVID19-associated myocarditis is seen to occur due to a series of events that can follow the initial viral injury, when the resultant immune response causes damage to the cardiac walls and muscle.

Acute fulminant myocarditis is a rare event that occurs due to the inflammation of the cardiac muscle. When it occurs, it significantly reduces the ability of the heart to pump blood efficiently. This failure of the heart to function properly means that the acute fulminant myocarditis has higher than normal mortality rates, ranging from 40-70%.<sup>[2]</sup>

Cases of Fulminant Myocarditis are classified on the basis of their histological appearance into lymphocytic, giant cell myocarditis, eosinophilic, or sarcoid heart disease. The lymphocytic form is the most deeply-studied one, and is further subdivided into infective and non-infective forms. Where the confirmation of a viral etiology was not possible, a cardiac muscle biopsy is done. This has helped to confirm that approximately 78% of all cases of fulminant myocarditis have occurred because of a viral etiology.<sup>[3]</sup>

## CASE STUDY

A 31 year-old patient presented to the hospital with complaints of a mild fever, a sore throat along with throat pain, and generalized myalgia in his body for the last few days. No other systematic problems or abnormalities were reported. As part of the new hospital treatment protocols, the patient was ordered to get a COVID19 test. This test came out to positive and thus, the patient was ordered to go directly into home isolation. Since the patient was stable, well-oriented and had no other respiratory symptoms to complicate his case, it was decided not to admit him to the hospital. Moreover, his CT chest scan was clear, which meant that his COVID19 infection was mild and had not involved the lungs or the respiratory system. Therefore, the patient returned home with an antipyretic and antibiotics to treat his sore throat, pain, and fever.

However, the patient returned within two days, this time to the Emergency department. By then, the patient had developed severe symptoms. He had a severe cough, extreme shortness of breath, and severe fatigue. This condition required a complete and detailed examination of the patient.

### Examination

On examination, the patient appeared to be extremely fatigued and withdrawn from his surroundings. He had tachypnea and tachycardia.

The following points were noted during his systemic examination:

● <b>Blood Pressure</b>	● 104/70 mm of Hg
● <b>Pulse Rate</b>	● 120/min
● <b>Temperature</b>	● 39.6 C

<ul style="list-style-type: none"> <li>● <b>Respiratory Rate</b></li> </ul>	<ul style="list-style-type: none"> <li>● 26/min</li> </ul>
<ul style="list-style-type: none"> <li>● <b>O<sub>2</sub> Saturation</b></li> </ul>	<ul style="list-style-type: none"> <li>● 85%</li> </ul>
<ul style="list-style-type: none"> <li>● <b>Systemic Examination</b></li> </ul>	<ul style="list-style-type: none"> <li>● The patient had congested neck veins,</li> <li>● His jugular venous pressure was increased,</li> <li>● Faint heart sounds were heard on auscultation,</li> <li>● Chest auscultation revealed bibasilar crackles,</li> <li>● The left lobe of the liver was tender and palpable,</li> <li>● There were no evidence of any ascites or organomegaly appreciated,</li> <li>● The patient was noticed to have positive symmetrical pitting lower limb edema,</li> <li>● There was neither any skin rash nor any neurological involvement.</li> </ul>

## Investigations

The entire investigation along and its findings could be summarized below:

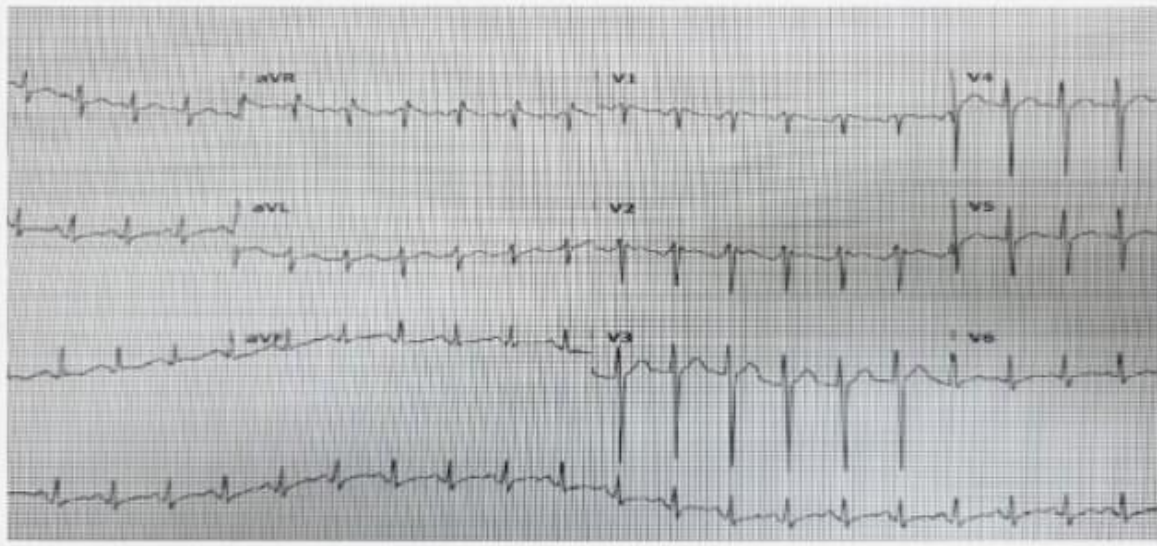
### CBC Report:

<b>HB</b>	14.6 g/dl dropped to 10.6 g/dl
<b>PLT</b>	68,000
<b>TWBC</b>	16,700
<b>MCV</b>	73
<b>MCH</b>	26

## Serum/Electrolytes Investigations

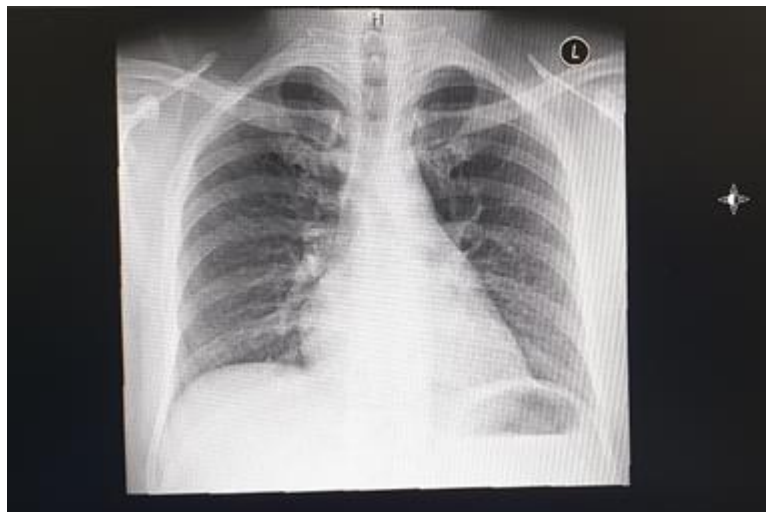
<b>Urea</b> (0-8.3)	16 mmol/lit
<b>Creatinine</b> (62-106)	272 micromol/lit
<b>Na ions</b> (135-145)	133 mmol/lit
<b>K ions</b> (3.6-5.1)	4.0 mmol/lit
<b>CRP</b> (<=5)	435 mg/lit
<b>Troponin</b> (<=14)	237 ng/lit, increased next day to 78480 ng/lit
<b>CPK</b> (39-308)	4752 IU/Lit
<b>Serum Ferritin</b> (30-400)	1866 microg/lit, increased next day to 5988 microg/lit
<b>BNP</b> (0-85)	29400 pg/ml
<b>D-Dimer</b> (0.19-0.50)	70mg/dl
<b>COVID 19 PCR</b>	Still positive
<b>Procalcitonin</b> (>0.5)	More than 100 ng/ml
<b>Interleukin-6</b> (less than 7)	259 pg/mL

Imaging studies gave the following results:

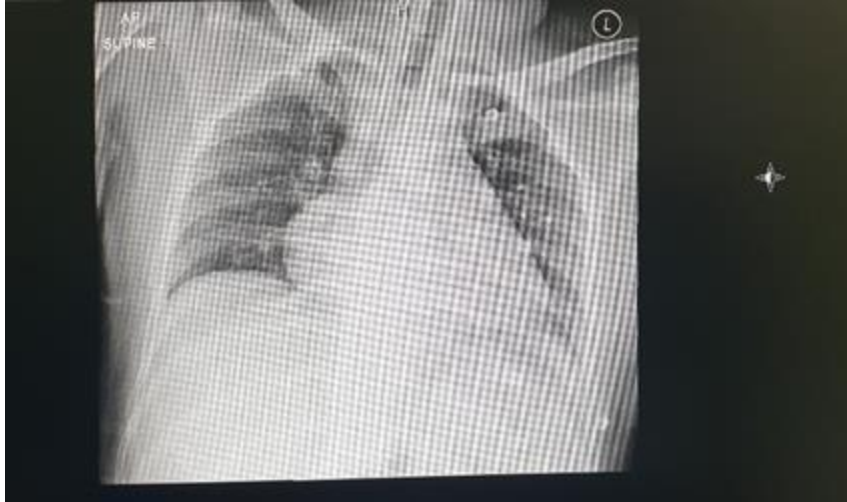

**ECG = Sinus Tachycardia**

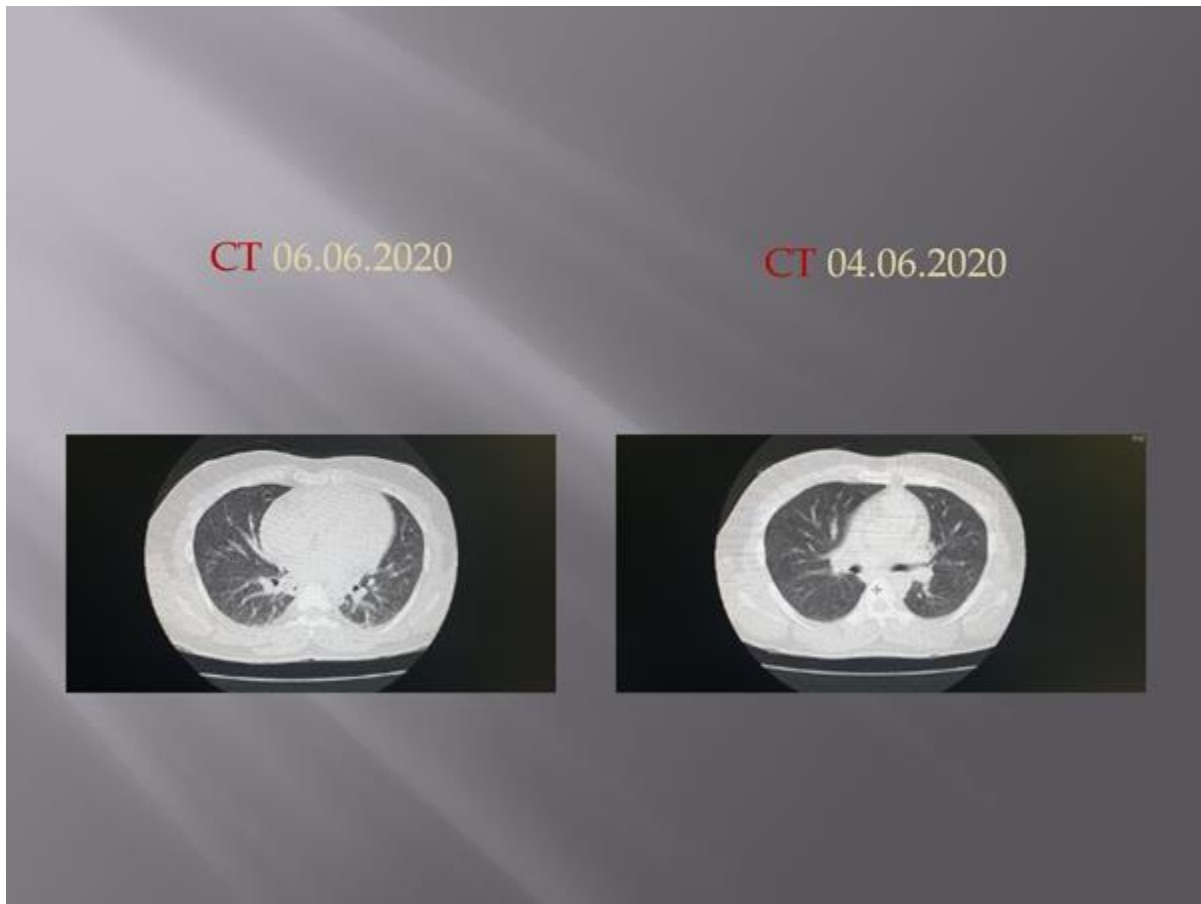
**Findings consistent with mild ST-segment elevation on the ECG (Elevated troponin levels mimicking myocardial ischemia, elevation of leads)<sup>[4]</sup>**



**Normal chest x-ray (first presentation)**



**CXR = Cardiomegaly**



**CT HR Chest = No lung involvement**

It is worthy of noting that the CT Chest PET Scan was done to rule out Pulmonary Embolism because of the shortness of breath and tachycardia that the patient had developed.

However, no evidence of pulmonary embolus could be appreciated, and there was sufficient contrast opacification of pulmonary arteries, thus ruling out the diagnosis.

### **Differential Diagnosis:**

Based on all the investigations and the examinations done, it was evident that the heart was involved in this scenario. Therefore, keeping all the findings in mind, the following differential diagnosis were prepared:

- COVID19-induced fulminant myocarditis
- Acute coronary syndrome
- Sepsis-related cardiomyopathy

After observing the patient's cardiac involvement, a bed in the cardiac ICU was ordered for him. The patient was started on parenteral furosemide along with constant oxygen support, which led to some hopeful improvements in symptoms.

### **Diagnosis & Management:**

The patient was admitted to the ICU directly, where he was confirmed as a case of COVID19-induced myocarditis. After this confirmation, the patient was started on a targeted therapy consisting of furosemide, inotropes, and vasopressors (dobutamine and norepinephrine).

An echocardiogram done at that time revealed global dyskinesia with an ejection fraction of 20%, along with heart failure secondary to acute myocarditis.

On day two, the patient was immediately intubated because he was distressed, tachypnic,

tachycardic, and hypotensive, along with suffering severe heart failure. Patient was treated with a therapeutic enoxaparin dose.

The patient's existing medication regimen was upgraded to camostat and favipiravir along with methylprednisolone for three days.

The echo was repeated on day six. It was revealed EF 55%, with normal heart size.

Some days later, the patient was extubated when he was deemed stable. He remained on an oxygen support (2 L/min) for two more days, and then was finally discharged in a healthy state.

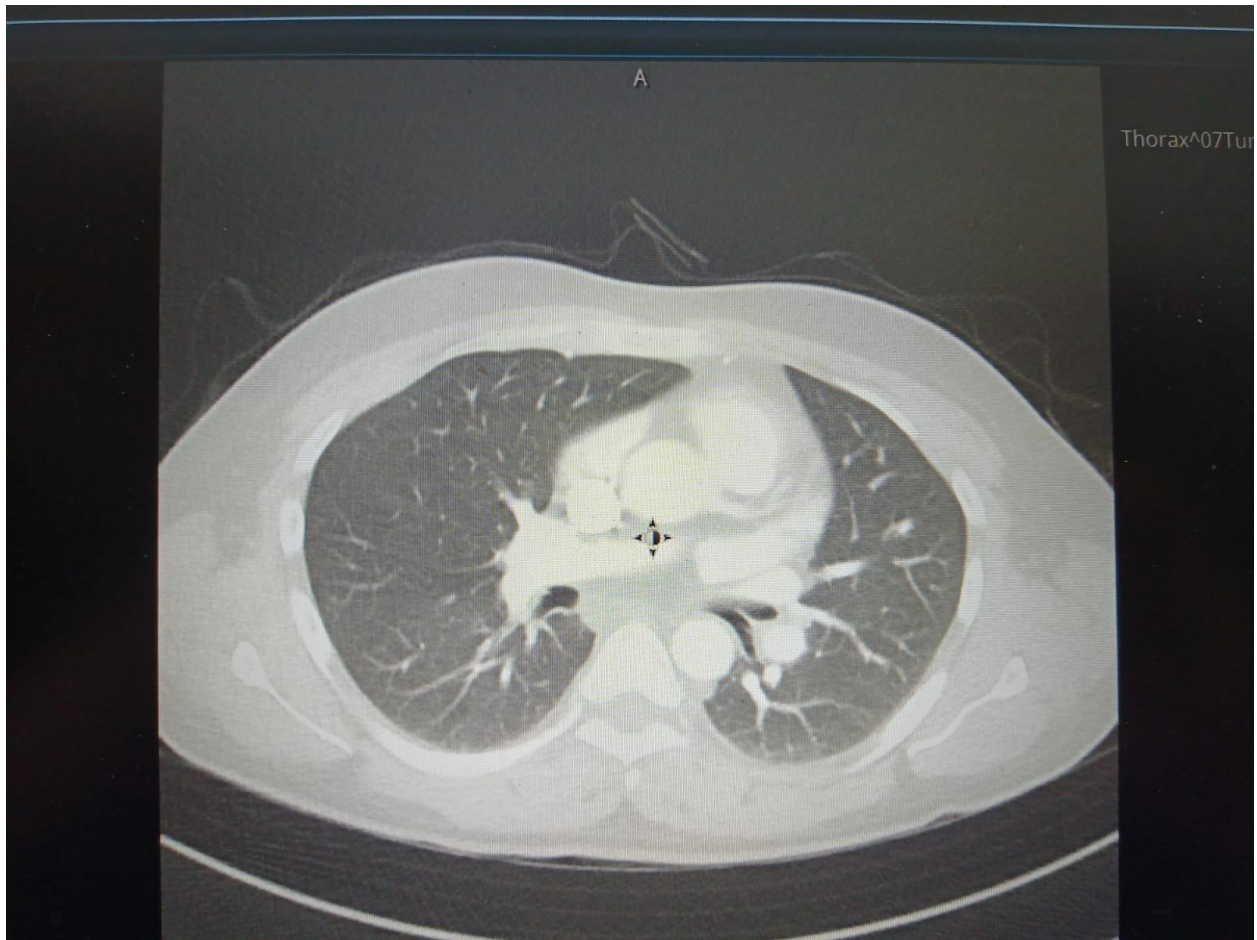
### **Discharge Summary**

An exclusive overview of the patient's history on discharge has been summarized as follows:

### **Lab Reports**

On discharge, the following lab investigations were obtained:

<b>WBC</b>	14,800
<b>Hb</b>	13.6 g/dl
<b>PLT</b> (150,000 - 450,000)	406,000
<b>Urea</b> (0-8.3)	6.3 mmol/lit
<b>Serum Creatinine</b> (62-106)	83 micromol/litre
<b>Na</b> (135-145)	133 mmol/lit
<b>K</b> (3.6-5.1)	4.2 mmol/lit
<b>ALT (29-33)</b>	181 IU/Lit
<b>Procalcitonin</b> (<0.5)	0.55 ng/ml
<b>Ferritin</b> (24 -336)	1145 microg/lit
<b>CRP</b> (<=5)	23.9 mg/lit



**Patient's HR-CT on discharge: shows visible decrease in cardiomegaly with decrease in total area of the shadow that was covering the heart area in the previous x-ray**

### **Discharge Medications**

Since the patient had already developed a heart-related condition, it was obvious that his heart-related and other functions would take time to normalize. Therefore, a regimen was prescribed to the patient on discharge, which was as follows:

- Multivitamin with minerals (Tablet 1 tab, PO, daily)
- Lactulose (15 mL, PO, TID PRN)
- Esomeprazole (Oral 20 mg, 1 tab, PO, Daily AC)

- Bisoprolol (1.25 mg daily)
- Enoxaparin (40 mg subcutaneously daily)

## **DISCUSSION**

COVID19-induced fulminant myocarditis has recently been added to the list of diseases that have been occurring due to the COVID19 infection.<sup>[5]</sup>

The COVID19 virus has been seen to have a significant impact on cardiovascular health as a whole. The involvement of the heart can occur in cases of COVID19, irrespective of whether there are any significant respiratory symptoms or not. Similarly, viral diseases were found to be the prevailing causes for heart-related conditions such as myocarditis, myopericarditis, pericarditis, etc.<sup>[6]</sup>

Specifically, a cardiac injury accompanied by significant troponin leakage is found to be responsible for a proportion of mortalities associated with COVID19. Up to 7-8% of the deaths due to COVID19 were found to occur due to myocarditis arising as a secondary complication.<sup>[7]</sup>

The relevant labs of the patient also revealed that she had elevated D-dimer levels as well as creatinine phosphokinase levels. Such lab elevations point towards hematological disturbances, which are commonly seen in COVID19 positive patients. Although the white blood cell count could be normal in these patients, like this patient, there could be uncommon symptoms in the patients such as headaches, palpitations, abdominal pain, etc. The reason behind these activities could be capability of the COVID19 virus to affect the bone marrow cells, thus inhibiting hematopoiesis, which ultimately leads to a reduction in platelet production, or the ability of the COVID19 virus to increase the levels of immune complexes and autoantibodies in the body which causes the platelets to be destructed.<sup>[8]</sup>

In the light of this pathophysiology, a viral infection that may affect the myocardium now due to

the lowered immune responses and the resultant attack on these infected cardiomyocytes by the immune complexes leads to extensive myocardial damage, which ensues in the form of inflammation, necrosis, and apoptosis of these damaged cardiomyocytes. Though there might be other factors responsible for the pathogenesis of the myocarditis, the immune system response is considered to be the best considered one. <sup>[9]</sup>

Myocarditis in COVID19 patients can occur due to several reasons. An exaggerated immune response may give rise to a cytokine storm, which may then cause increased vascular permeability, apoptosis, and T-cell and antibody responses. Along with these responses, a rise in the cardiac biomarkers was also noticed, which means that the heart was equally involved in the series of changes taking place. It was also hypothesized that the hypoxia which could have occurred due to COVID19 infection could have given rise to cardiac damage which was a significant cause of myocarditis. <sup>[10]</sup>

The clinical features or the presentation of the patient varies based on the severity of the damage done. The patient could be asymptomatic, or he could be in a state of cardiogenic shock. The symptoms are also seen to mimic those of acute or long-standing heart failure.

Fatigue, chest pain with or without exertion, elevated jugular venous pressure, right upper-quadrant abdominal discomfort, and peripheral edema were seen to occur in patients, mimicking right-sided heart failure. The patient discussed above had similar presentation.

The diagnosis protocol is the same as for any viral disease. The clinical presentation of the patient is very important. In addition, a record of travel history and exposure to sick or previously-diagnosed contacts, a thorough physical examination, and laboratory tests including COVID-19 PCR and inflammatory and cardiac markers need to be obtained to reach a conclusive diagnosis.<sup>[11]</sup>

As far as treatment is concerned, a proper regimen needs to be formulated for this condition. Presently, only supportive treatment is available to the patient. NSAIDs, colchicine, corticosteroids, intravenous immunoglobulin (IVIG), and plasma exchange therapy are the standard mode of treatment for patients.<sup>[12]</sup>

With the emergence of new data and statistics, a definite solution to put the myocarditis to rest will surely arise.

## **CONCLUSION**

The COVID19 virus has presented a new sort of mystery to the world. It changes its nature day by day and this complicates things as time progresses. The association of myocarditis with COVID19 was only a suspicion at first, but it has now been confirmed through a series of case reports, irrespective of whether they were predisposed to it or not.

Myocarditis may present either asymptotically or with a wide range of symptoms. As the association with COVID19 is a new addition to the characteristics of this disease, its diagnosis currently relies on a detailed history and physical examination and on different investigations later on.

The treatment protocol also varies from person to person since every patient has a different presentation. So far, many patients have been successfully treated and sent home with no other ensuing complications.

#### **Consent**

As per international standard or university standard, patients' written consent has been collected and preserved by the authors.

#### **REFERENCES:**

1. Chen, C., Zhou, Y., & Wang, D. W. SARS-CoV-2: a potential novel etiology of fulminant myocarditis. *Herz*, (2020) 45(3), 230–232. <https://doi.org/10.1007/s00059-020-04909-z>
2. Cooper LT., Jr. Myocarditis. *N Engl J Med*. 2009;360(15):1526–1538. doi: 10.1056/NEJMra0800028
3. Kuhl U, Pauschinger M, Noutsias M, et al. High prevalence of viral genomes and multiple viral infections in the myocardium of adults with “idiopathic” left ventricular dysfunction. *Circulation*. 2005;111(7):887–893. doi: 10.1161/01.CIR.0000155616.07901.35

4. Zhang, T., Miao, W., Wang, S., Wei, M., Su, G., & Li, Z. (2015). Acute myocarditis mimicking ST-elevation myocardial infarction: A case report and review of the literature. *Experimental and therapeutic medicine*, 10(2), 459–464. <https://doi.org/10.3892/etm.2015.2576>
5. Chen N, Zhou M, Dong X, et al. Epidemiological and clinical characteristics of 99 cases of 2019 novel coronavirus pneumonia in Wuhan, China: a descriptive study. *Lancet*. 2020 doi: 10.1016/S0140-6736(20)30211-7.
6. Kang M, An J. Viral Myocarditis. [Updated 2021 Aug 11]. In: StatPearls [Internet]. Treasure Island (FL): StatPearls Publishing; 2021 Jan-. Available from: <https://www.ncbi.nlm.nih.gov/books/NBK459259/>
7. Puntmann VO, Carerj ML, Wieters I, et al. Outcomes of cardiovascular magnetic resonance imaging in patients recently recovered from coronavirus disease 2019 (COVID-19). *JAMA Cardiol*. 2020;5(11):1265–1273.
8. Xu, P., Zhou, Q., & Xu, J. (2020). Mechanism of thrombocytopenia in COVID-19 patients. *Annals of hematology*, 99(6), 1205-1208.
9. Miyamoto, S., Ito, T., Terada, S. *et al.* Fulminant myocarditis associated with severe fever with thrombocytopenia syndrome: a case report. *BMC Infect Dis* 19, 266 (2019). <https://doi.org/10.1186/s12879-019-3904-8>
10. Tavazzi G, Pellegrini C, Maurelli M, Belliato M, Sciutti F, Bottazzi A et al Myocardial localization of coronavirus in COVID-19 cardiogenic shock. *Eur J Heart Fail* (2020) 22:911–915
11. Khatri, A., & Wallach, F. Coronavirus disease 2019 (COVID-19) presenting as purulent fulminant myopericarditis and cardiac tamponade: A case report and literature review. *Heart & lung: The Journal of Critical Care* (2020)., 49 (6), 858–863
12. Farina A, Uccello G, Spreafico M, Bassanelli G, Savonitto S. SARS-CoV-2 detection in the pericardial fluid of a patient with cardiac tamponade. *Eur J Intern Med*. 2020;76:100–101.