

Case study

“Hookworm infection in infant: A case study and review of literature”

Running Title: Hookworm infection in infant.

Abstract:

Background- Hookworms are nematode parasites belonging to Ancylostomatidae helminth family that causes variety of clinical problems. They are often termed as soil transmitted helminths (STH) because human infection occurs by ingestion of eggs and /or skin contact with contaminated soil. Hookworm infection is common in tropical countries and transmission is influenced by climatic and socio-economic conditions. Hookworm infection in neonatal and infantile period are rarely reported. Here, we describe a case of two months old infant with hookworm infection and review the relevant literature.

Case Presentation - A two-month-old institution delivered male baby on exclusive breastfeeding with no significant ante natal or post natal history referred to our hospital with complains of black tarry stool since birth and progressive paleness of body requiring multiple packed cell transfusion. On investigation, child has severe anaemia with eosinophilia and positive stool for occult blood. Upper gastrointestinal endoscopy revealed hookworm in duodenum. The child was treated with oral mebendazole and discharged in good condition.

Discussion -Hookworm is a major public health problem in tropical and sub tropical countries. Most of the cases are asymptomatic and rarely detected. Hookworm infection can lead to growth retardation, failure to thrive, cognitive impairment and other manifestations also. Most of the cases are reported in older children and very few cases are reported in newborns and infants. Mechanism of transmission of infected larvae in such young infant is unclear. Transmission may occur vertically either through trans-placental route or by breastfeeding. Hookworm infection should be considered in differential diagnosis newborns and infants presented with unexplained weight loss, melena, anaemia with eosinophilia. The disease can be managed effectively through simple and easily available medications and adverse outcome can be prevented.

Conclusion-Very young infants residing in helminth endemic area with low socioeconomic status and presenting with severe anaemia with melena and/or failure to thrive, one should consider possibility of hookworm infection.

Keywords: Hookworm, Endoscopy, melena, infant

1. Introduction

Hookworms are nematode parasites that cause a variety of clinical problems. They are members of the Ancylostomatidae helminthic family, which is part of the Strongyloidea superfamily. Because they are acquired by humans by the ingestion of eggs and/or skin contact with infected larvae in wet contaminated soil, they are referred to as soil-transmitted helminths (STH) in public health terms (1).

Ancylostoma duodenale and *Necator americanus* are the two most common intestinal parasites worldwide, however *Ancylostoma ceylanicum* has lately emerged as a major human parasite in a few places (2).

In tropical and subtropical regions, the incidence of hookworm infection is influenced by climatic and socioeconomic conditions, and it is a major public health concern (3). Infected persons number almost 472 million in poor rural nations, with the bulk of infections occurring in Southeast Asia and Sub-Saharan Africa (1, 4). According to simulation models, hookworm illness causes more than 4 million disability-adjusted life years (DALY) to be lost each year, costing over US\$100 billion each year (5).

Infantile hookworm illness is a separate clinical entity that has only been described seldom, mainly in China, Nigeria, Nepal, and Australia's aboriginal cultures (6–10). There have been a few cases of hookworm infections in Indian newborns; two of these reports are from Nepali infants (7–9, 11).

2. Case Presentation

A two month old male baby product of non consanguineous marriage delivered by vaginal route of primi mother at 40 weeks period of gestation with no significant ante natal or post natal history. Child cried immediately after birth and has received injection vitamin K at birth. Child was on exclusive breastfeeding. Child referred to tertiary care hospital in view of black tarry stool since birth with progressive paleness of body. Earlier family thought that this black tarry stool was normal in newborn and hence did not seek any medical attention. But they noticed progressive paleness of body for which they consulted to local practitioner where haemogram was done in which Haemoglobin was 2.8 gm% with TLC=10500 (differential count not known) and Platelet 1.72 lakhs. The child was transfused 2 units packed red cells. And post transfusion haemoglobin was 7.5 gm%. But parents noticed that paleness of body was persisting for which they again consulted to some other Hospital where haemogram shows haemoglobin of 4.8 gm% within a week of transfusion. So child referred to our hospital in view of persistence of black tarry stool with progressive decline in haemoglobin.

On admission in our Hospital, Heart rate =120/minutes with good palpable peripheral pulses, Respiratory rate=34/minutes, saturation =96-98% @ room air, temperature=99.3°F. There was severe pallor present, but infant was haemodynamically stable and not in heart failure. Abdomen was soft, Liver was just palpable with span of 6 centimetres and spleen was not palpable. Rest systemic examination was unremarkable. Weight of the infant was 4.5 kilograms (between -2 and -1 S.D.) with length of 53 cm (between -3 & -2 S.D.)

On investigation Haemoglobin was 4.2 gram% with leucocyte count of 31000/cu mm with eosinophilic leucocytosis (Eosinophil=740/cu.mm) and Platelets was 4.39 lakhs with peripheral smear showing normocytic normochromic anaemia with eosinophilic leucocytosis. CRP was positive. LFT, KFT, Coagulation profile, Ultrasound Abdomen, Meckel's Scan was normal. DCT was Negative, stool for occult blood positive. Child was transfused one unit packed red cell. Upper g.i. endoscopy was planned because black tarry stool was persisting reflecting bleeding proximal to ligament of Treitz (second part of duodenum) although abdomen was not distended, and spleen was not palpable with normal liver function test and ultrasound abdomen (No signs of liver failure). UGIE shows hookworm in second part of duodenum (Fig-1). Mother and Father stool were also sent for examination and mother's stool was positive for occult blood.

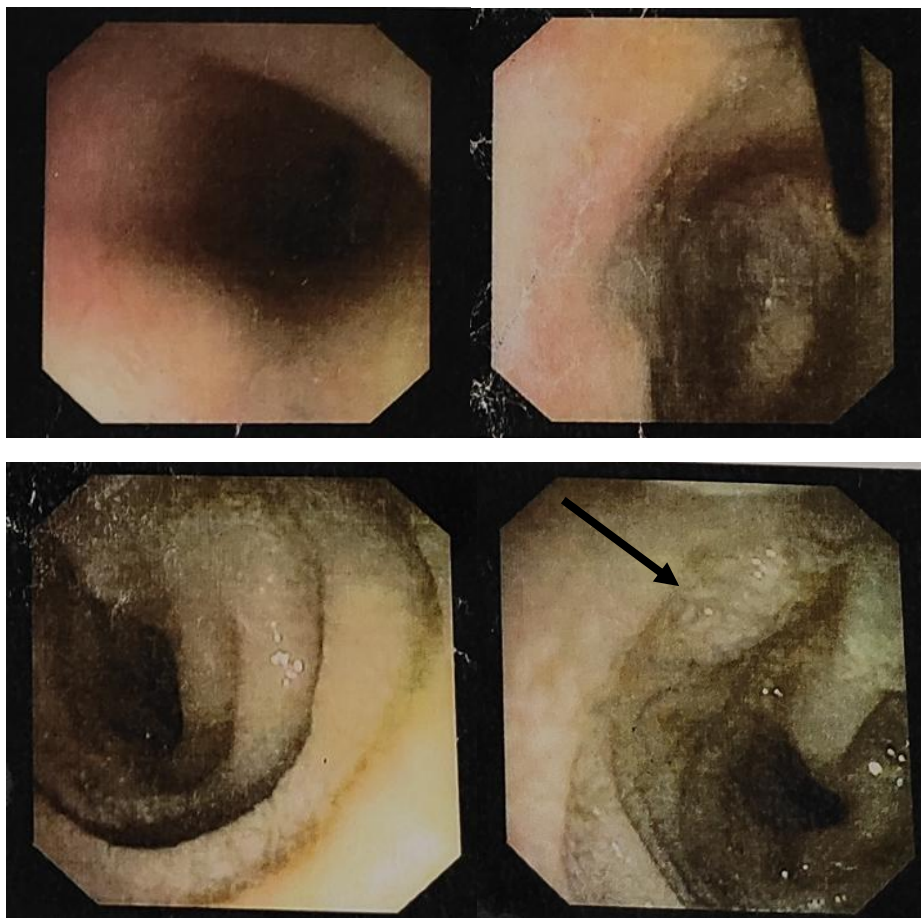


Figure-1 showing hookworm in duodenum (Upper G. I. Endoscopy)

The infant was treated with mebendazole 100 mg BD for 3 days and parents were also advised for Tablet Albendazole 400 mg OD for 3 days. After 2 days of giving mebendazole child's stool colour was changed from black to yellow although mother was not sure of passage of worms in stool. Child was discharged on haematinics and on follow up after one week Haemoglobin was 7.7 gm% and was passing yellow coloured stool.

3. Discussion

Human hookworm infestations are caused by infective larvae (L3) that enter the body through the skin (*A. duodenale* or *N. Americanus*) or by direct oral intake (*A. duodenale*). The larvae enter the trachea after migrating to the circulation and reaching the pulmonary alveoli. After piercing the pulmonary alveoli and traversing the trachea, the L3 reaches the stomach through the circulation. They moult twice here before becoming adult worms. In humans, the **prepatent**/incubation stage lasts roughly 5-8 weeks. In babies, this cycle is not well understood. Several routes of hookworm infection in babies have been proposed, but none have been proven. Infants that develop symptoms before the age of 5-8 weeks are frequently infected with *A. duodenale* and may have contracted the infection via the transplacental or transmammary routes (9, 10). Hookworms can also be obtained via contaminated soil, where newborns are typically placed by their mothers while working in fields, or through contaminated dirt sandbags/wheat-stem bundles used as diapers. In certain cases, infestations can be obtained by washing partly wet diapers in larva-infested ponds or canals and drying them on grassland (10). However, the exact mechanism by which large-scale hookworm infestations occur in small children is unknown and requires further research.

While most instances are asymptomatic, the infection can infrequently result in overt gastrointestinal bleeding and **melena**, which has been recorded in babies from endemic locations (7, 12). Bloody stools, melena, growing pallor, anorexia, listlessness, and edema are common signs of infantile hookworm illness (6–8, 10). Both iron deficiency anaemia and protein malnutrition have long-term repercussions, including growth stunting and impaired cognitive performance, particularly working memory (13).

Literature does not provide much information about the use of anthelmintic drugs under 24 months of age. Individual therapy with benzimidazoles (albendazole 400 mg single dose, mebendazole 500 mg single dose, or mebendazole 100 mg twice day for 3 days) is suggested globally (1), however more albendazole doses may be required to manage the infection (14). The most common side effects of these medications include stomach discomfort, nausea, and diarrhoea; however, the safety of these treatments in children under the age of 12 months has yet to be determined (1). Only a few studies have looked at the effects of mebendazole on newborns directly (15), although a recent investigation on the usage of mebendazole in 45 nursing women reported no detrimental effects in infants (16). According to current information, the incidence of benzimidazole drug-related adverse effects in young children is expected to be the same as in older children and adults (17).

The exact mechanism of infection in newborn and very young infant is still unclear and require further research. Infants who are infected in neonatal period, possibility of vertical transmission either through breast feeding or transplacentally cannot be ruled out. In our case as mother belongs to hook worm endemic area with low socioeconomic status and poor accessibility for sanitation with stool for occult blood positive therefore transmission of hookworm to newborn is most likely to be vertically transmitted either through breast feeding or transplacentally. Although stool was only positive for occult blood and no ova or cyst had been isolated. Sensitivity of stool examination can be increased from 58.6% to 95%

for picking ova and cyst by examining three stool samples (18). Therefore, in our case, if we would have examined the three stool samples, the need for invasive diagnostic test(endoscopy) can be omitted.

In our case, the only symptom was black tarry stool with progressive pallor, we have suspected portal hypertension, haematological disorder, Meckel's diverticulum, vascular malformation or cow's milk protein allergy. And to rule out the differentials, Ultrasonography abdomen, **Direct Coombs Test**, Meckel's Scan along with upper gastrointestinal endoscopy was planned.

4. Conclusion

Very young infants residing in helminth endemic area with low socioeconomic status and presenting with severe anaemia with Melena and/or failure to thrive, one should consider possibility of Hookworm infection. The disease can be managed effectively through simple and **easily** available medications. Although no standard guidelines for diagnosing and treating worm infection in such young infant has been established and further studies are needed for formation of clinical and diagnostic criteria and best clinical management of affected infants.

Funding-The authors did not received any financial support for the research, authorship, and/or publication of this article.

Patient consent statement

This is a single case report with no identifiable patient information/characteristics are included in this case report. Therefore, there is no need to obtain patient consent.

Ethical Approval:

As per international standard or university standard ethical approval has been collected and preserved by the authors.

Declaration of competing interest

The authors declare that they have no competing financial interest or personal relationship that could have appeared to influence the work reported in this paper.

References

1. Jourdan, P. M., P. H. L. Lamberton, A. Fenwick, and D. G. Addiss. Soil-Transmitted Helminth Infections. *The Lancet*.
2. Inpankaew, T., F. Schär, A. Dalsgaard, V. Khieu, W. Chimnoi, C. Chhoun, D. Sok, H. Marti, S. Muth, P. Odermatt, and R. J. Traub. High Prevalence of *Ancylostoma Ceylanicum* Hookworm Infections in Humans, Cambodia, 2012. *Emerging Infectious Diseases*, 2014. <https://doi.org/10.3201/eid2006.131770>.

3. Hotez, P. J., S. Brooker, J. M. Bethony, M. E. Bottazzi, A. Loukas, and S. Xiao. Hookworm Infection. *The New England journal of medicine*, Vol. 351, No. 8, 2004, pp. 799–807. <https://doi.org/10.1056/NEJMRA032492>.
4. Silver, Z. A., S. P. Kaliappan, P. Samuel, S. Venugopal, G. Kang, R. Sarkar, and S. S. R. Ajjampur. Geographical Distribution of Soil Transmitted Helminths and the Effects of Community Type in South Asia and South East Asia – A Systematic Review. *PLoS Neglected Tropical Diseases*, 2018. <https://doi.org/10.1371/journal.pntd.0006153>.
5. Bartsch, S. M., P. J. Hotez, L. Asti, K. M. Zapf, M. E. Bottazzi, D. J. Diemert, and B. Y. Lee. The Global Economic and Health Burden of Human Hookworm Infection. *PLoS Neglected Tropical Diseases*, 2016. <https://doi.org/10.1371/journal.pntd.0004922>.
6. Otaigbe, B. E., A. U. Eneh, and B. Oruamabo. Hookworm Infestation in a 3-Month Old Female. *Nigerian journal of medicine: journal of the National Association of Resident Doctors of Nigeria*, 2005. <https://doi.org/10.4314/njm.v14i1.37187>.
7. Budhathoki, S., D. Shah, K. K. Bhurtyal, R. Amatya, and A. K. Dutta. Hookworm Causing Melaena and Severe Anaemia in Early Infancy. *Annals of Tropical Paediatrics*, 2008. <https://doi.org/10.1179/146532808X375468>.
8. Singh, K., R. Singh, S. C. Parija, and M. M. A. Faridi. Infantile Hookworm Disease. *Indian journal of pediatrics*, Vol. 67, No. 3, 2000, p. 241. <https://doi.org/10.1007/BF02723673>.
9. Tiwari, L., J. James, S. Chowdhary, A. Sharma, and J. M. Puliyeel. Severe Anaemia Owing to Hookworm in a 12-Day-Old Nepalese Infant. *Annals of Tropical Paediatrics*, 2004. <https://doi.org/10.1179/146532804X10844>.
10. Yu Sen-Hai, Jiang Ze-Xiao, and Xu Long-Qi. Infantile Hookworm Disease in China. A Review. *Acta Tropica*, 1995. [https://doi.org/10.1016/0001-706X\(95\)00089-W](https://doi.org/10.1016/0001-706X(95)00089-W).
11. Kang, G., M. S. Mathew, D. P. Rajan, J. D. Daniel, M. M. Mathan, V. I. Mathan, and J. P. Muliylil. Prevalence of Intestinal Parasites in Rural Southern Indians. *Tropical Medicine and International Health*, 1998. <https://doi.org/10.1046/j.1365-3156.1998.00175.x>.
12. Walker, A. C., and S. P. Bellmaine. Severe Alimentary Bleeding Associated with Hookworm Infestation in Aboriginal Infants. *Medical Journal of Australia*, 1975. <https://doi.org/10.5694/j.1326-5377.1975.tb111802.x>.
13. Weatherhead, J. E., and P. J. Hotez. Worm Infections in Children. *Pediatrics in Review*.
14. Adegnika, A. A., J. F. Zinsou, S. Issifou, U. Ateba-Ngoa, R. F. Kassa, E. N. Feugap, Y. J. Honkpehedji, J. C. D. Agobe, H. M. Kenguele, M. Massinga-Loembe, S. T. Agnandji, B. Mordmüller, M. Ramharter, M. Yazdanbakhsh, P. G. Kremsner, and B. Lell. Randomized, Controlled, Assessor-Blind Clinical Trial to Assess the Efficacy of Single-versus Repeated-Dose Albendazole to Treat *Ascaris Lumbricoides*, *Trichuris Trichiura*, and Hookworm Infection. *Antimicrobial Agents and Chemotherapy*, 2014. <https://doi.org/10.1128/AAC.01317-13>.

15. Montresor, A., R. J. Stoltzfus, M. Albonico, J. M. Tielsch, A. L. Rice, H. M. Chwaya, and L. Savioli. Is the Exclusion of Children under 24 Months from Anthelmintic Treatment Justifiable? *Transactions of the Royal Society of Tropical Medicine and Hygiene*, Vol. 96, No. 2, 2002, pp. 197–199. [https://doi.org/10.1016/S0035-9203\(02\)90303-2](https://doi.org/10.1016/S0035-9203(02)90303-2).
16. Karra, N., R. Cohen, M. Berlin, N. Dinavitser, G. Koren, and M. Berkovitch. Safety of Mebendazole Use During Lactation: A Case Series Report. *Drugs in R and D*, 2016. <https://doi.org/10.1007/s40268-016-0142-z>.
17. Montresor, A., S. Awasthi, and D. W. T. Crompton. Use of Benzimidazoles in Children Younger than 24 Months for the Treatment of Soil-Transmitted Helminthiasis. 2003.
18. Nazer H, Greer W, Donelly K, Mohamed AE, Yaish H, Kagalwala A, et al. The need for three stool specimens in routine laboratory examinations for intestinal parasites. *By J Clin Pract* 1993; 47 : 76-78.