

Case report

Bowel gangrene in neonate born to COVID mother – Is it a manifestation of Multisystem Inflammatory Syndrome in Newborn?

ABSTRACT

Aims: Pregnant mothers with SARS-CoV2 infection are postulated to transfer anti-COVID-19 antibodies to their fetus, which may lead to cytokine storm and fetal inflammatory syndrome, similar to multisystem inflammatory syndrome in children (MIS-C). Manifestations of this newly emerging entity are not elucidated, but MIS in Newborn (MIS-NB) must be suspected whenever a neonate born to COVID positive mother is presenting with unusual symptoms.

Clinical description: We report a preterm, low birth weight, Monochorionic Diamniotic (MCDA) twin neonate born to COVID positive mother who developed abdominal distension in first few hours of life, initially suspected to have small bowel atresia. Baby had elevated inflammatory panel and given IVIG, suspecting MIS-NB. Intraoperatively the baby was noted to have gangrenous bowel, which required extensive surgical resection, but baby succumbed postoperatively.

Conclusion: This report highlights possible intestinal manifestations of possible COVID-19 related fetal inflammatory syndrome.

INTRODUCTION :

COVID-19, a rapidly spreading lethal pandemic across nations, has not spared the pregnant mothers or their new-borns from complications, with increased incidence of intrauterine infections being reported in medical literature.[1-3] New-borns born to COVID-19 mothers can exhibit multisystem symptoms secondary to passive transfer of antibodies similar to fetal inflammatory response syndrome (FIRS).[4,5] Gastrointestinal manifestations are seen either during the acute phase of COVID illness or in the post-viral inflammatory phase (MIS-C).[6,7] We describe a premature baby born to a SARS-CoV2 infected mother with acute gastrointestinal symptoms from first day of life. The baby was initially suspected to have small bowel atresia, but intraoperatively diagnosed with inflammatory colonic gangrene.

PRESENTATION OF CASE:

Second born male neonate who was appropriate for gestational age, MCDA twin with birth weight of 1.75kg. He was born to COVID-19 mother with moderate illness, at 32weeks of gestation via vaginal route. Mother is a known case of rheumatic heart disease with mild mitral stenosis, on oral metoprolol, frusemide and penicillin prophylaxis since past 1year. Twin gestation was confirmed in 1st trimester and all antenatal investigations were normal without any eventful history until she was diagnosed to have COVID-19. Pregnancy was terminated early in view of progressive worsening of maternal illness by induction of labour. Mother had fever for 3days and required Oxygen support (Non rebreathing mask 10L oxygen) for 8 days, which was gradually weaned off. At any point of time she did not require advanced respiratory support. She was given steroids and symptomatic treatment. The baby and its twin, received routine neonatal care at birth and were admitted to NICU for low birth weight and preterm care.

The baby was started with oro-gastric tube feeding, but noted to have abdominal distention at 6 hours of life. X-ray abdomen revealed multiple dilated bowel loops not suggestive of any specific conditions (Fig.1). Suspecting surgical abdomen, baby was kept nil by mouth. First day investigations revealed positive CRP (44mg/dL) with total leucocyte counts of 7000 with Absolute neutrophil count - 5600 and the baby was started on first line antibiotics..

With progressive distension of abdomen, respiratory distress was noted at 16hrs of life. Which required non-invasive continuous positive pressure support. Baby could pass meconium post rectal stimulation. Nasopharyngeal swab for SARS-CoV2 RT-PCR sent at 24hrs of life was negative. Subsequent x-rays showed multiple air fluid levels along with dilated bowel loops. Contrast barium enema confirmed distal dilated bowel loops with obstruction. (Fig. 2) Inflammatory panel was performed suspecting MIS-NB. Trial of IVIG at 2g/kg was given in view of elevated d-dimers (2361ng/mL) and S. Ferritin (456ng/mL). Total Anti-COVID-19 antibodies also turned out to be positive. Baby was taken up for emergency explorative laparotomy and intraoperatively found to have dilated gangrenous transverse colon. (Fig 3) Multiple clots were noted along the supplying vasculature suggestive of vascular insult. The gangrenous bowel of 6cm was surgically resected and colostomy was performed. Because of limited resources during COVID times could not send the sample for Histopathology. Baby was ventilated postoperatively and required multiple inotropes gradually. Baby succumbed at 20hours post-surgery inspite of extensive measures.

As the Twin 2 had stormy course, COVID inflammatory markers and antibodies to twin 1 were sent. No significant elevation in d-Dimer 452 ng/ml, CRP 1.2mg/dl and S.Ferritin 205ng/ml. Only Total Anti COVID 19 antibodies was positive. Baby remained asymptomatic throughout its NICU course. Preterm care was given, gradually stepped up feeds and was discharged after 10days.

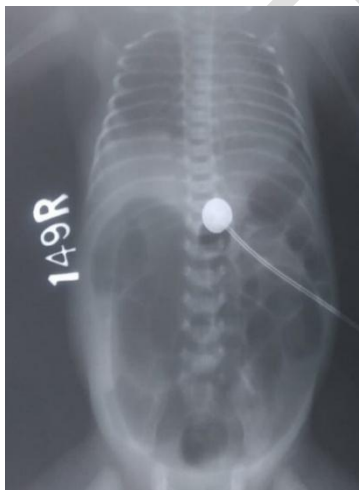


Fig 1 Xray Abdomen showing grossly dilated bowel loops

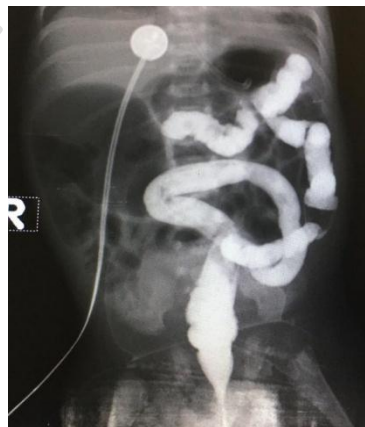

Fig 2 Barium contrast study suggestive of intestinal obstruction

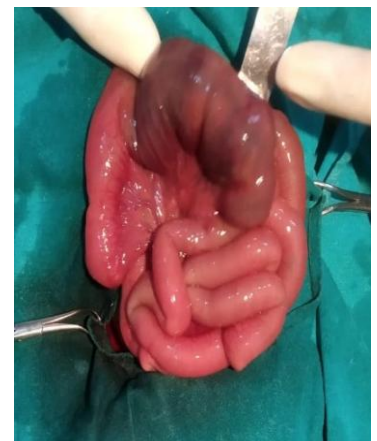

Fig 3 Intraoperative findings of gangrenous bowel loop

DISCUSSION

COVID-19 infection is **known** in causing vascular and thrombotic events in adults. It has been recently observed to cause isolated gastrointestinal involvement with minimal respiratory symptoms in adults as well as in pediatric population.[6-8] Although there is uncertainty regarding the extent of vertical transmission of SARS-CoV2 infection, COVID-19 has been reported to cause fetal inflammatory response syndrome (FIRS).[4,5]. Zeng H et al studied trans placental transfer of Antibodies in infants born to COVID 19 Mothers.[6].Also Gupta.K et al. Reported a case on Gastric perforation and Necrotising enterocolitis associated with COVID antibodies.[7]

The incidence of gastrointestinal manifestations in newborn of SARS-CoV2 mother is unknown. Hyper-coagulability induced by systemic inflammatory state, endothelial activation, hypoxia could lead to mesenteric vascular thrombosis or direct viral infection acting on ACE-2 receptor could cause bowel and vascular endothelial damage. **COVID-19 associated intestinal ischemia has been reported to occur with or without involvement of major arteries in adults.**[9] Kenchappa et al, reported a 10year old girl with acute abdomen, SARS-CoV2 RT-PCR positive, operated for small bowel gangrene.[8]

The baby described had gangrene of transverse colon which presented clinically as intestinal obstruction. Baby had elevated inflammatory markers suggestive of systemic coagulopathy and possible intrauterine fetal inflammatory syndrome resulting from maternal COVID-19. Kalyanshettar et al, have reported arterial thrombus and gangrene of lower extremity in a SARS-CoV2 positive newborn, treated with anticoagulants.[11]. Amulya GI et al reported a 10 day old neonate with Multisystem inflammatory syndrome with prenatal exposure to COVID 19.[12] Another study done on 29 COVID positive mothers and their babies showing Intestinal manifestation.[13] Being a novel entity, not much is known regarding the varied manifestations and treatment options available in newborns. Role of anticoagulants and IVIG in such cases of MIS-NB needs further validation.

CONCLUSION

We hope this case report draws attention towards intestinal gangrene could be a novel possible presentation of FIRS/MIS-NB in newborns born to COVID-19 Mothers.

Disclaimer regarding Consent and Ethical Approval:

As per university standard guideline, participant consent and ethical approval have been collected and preserved by the authors

REFERENCES

1. Dubey P, Reddy SY, Manuel S, Dwivedi AK. Maternal and neonatal characteristics and outcomes among COVID-19 infected women: An updated systematic review and meta-analysis. *Eur J Obstet Gynecol Reprod Biol.* 2020;252:490-501.
2. Dong L, Tian J, He S, Zhu C, Wang J, Liu C, Yang J. Possible Vertical Transmission of SARS-CoV-2 From an Infected Mother to Her Newborn. *JAMA.* 2020 May 12;323(18):1846-1848.
3. Sankaran D, Nakra N, Cheema R, Blumberg D, Lakshminrusimha S. Perinatal SARS-CoV-2 Infection and Neonatal COVID-19: A 2021 Update. *NeoReviews* May 2021, 22 (5) e284-e295
4. McCarty KL, Tucker M, Lee G, Pandey V. Fetal Inflammatory Response Syndrome Associated With Maternal SARS-CoV-2 Infection. *Pediatrics.* 2020 Oct 29:e2020010132.
5. Hofer N, Kothari R, Morris N, Müller W, Resch B. The fetal inflammatory response syndrome is a risk factor for morbidity in preterm neonates. *Am J Obstet Gynecol.* 2013 Dec;209(6):542.e1-542.e11.
6. Zeng H, Xu C, Fan J, et al. Antibodies in infants born to mothers with COVID-19 pneumonia. *JAMA.* 2020;323:1848–9.
7. Gupta K, Thakur A, Kler N, Garg P. Gastric Perforation and Necrotizing Enterocolitis Associated with COVID Antibodies. *Indian J Pediatr.* 2022 Jan;89(1):93.
8. Kenchappa Y, Hegde S, Kumar P, Lalitha AV, Bukelo M. Caught Off Guard with COVID-19 Bowel Gangrene: A Case Report. *Indian J Crit Care Med* 2020;24(12):1269–1271.
9. Lin L, Jiang X, Zhang Z, Huang S, Zhang Z, Fang Z, et al. Gastrointestinal symptoms of 95 cases with SARS-CoV-2 infection. *Gut* 2020;69(6):997–1001.
10. Varshney R, Bansal N, Khanduri A, et al. (April 26, 2021) Colonic Gangrene: A Sequela of Coronavirus Disease 2019. *Cureus* 13(4): e14687.
11. Kalyanshettar S., Charki S. Arterial Thrombosis and Gangrene in A Neonate With COVID-19 – A Case Report. *Iranian Journal of Neonatology IJN* 2021.

12. Amulya GI, Kaur A, Sharma M. Multisystem Inflammatory Syndrome in a Neonate with Prenatal Exposure to COVID-19. *Indian J Pediatr.* 2021 Sep 27:1

13. Wu Y-T, Liu J, Xu J-J et al. Neonatal outcome in 29 pregnant women with COVID-19: A retrospective study in Wuhan, China. *PLoS Med.* 2020;17:e1003195.

UNDER PEER REVIEW